



International Journal of
Cancer Research

ISSN 1811-9727



Academic
Journals Inc.

www.academicjournals.com

Study the Complications of Ct-guidance Fine Needle Biopsy in Intra-thoracic Masses

¹M. Davoudi, ²M.S.Z. Sharifi and ³F. Rahim

¹Department of Radiology, Imam Khomeini Hospital,
Ahvaz Jundishapur University of Medical Sciences, Ahvaz, Iran

²Radiology Residents, Imam Khomeini Hospital,
Ahvaz Jundishapur University of Medical Sciences, Ahvaz, Iran

³Physiology Research Center, Ahvaz Jundishapur University of Medical Sciences,
Ahvaz, Iran

Abstract: The purpose of this study was to observe the complications of needle biopsy of chest lesions guided by the CT scan among the patients studied. This is a descriptive epidemiologic study. All patients that referred to Imam Khomeini in Ahvaz from 2005 to 2007 and it was necessary to biopsy the chest lesions were studied. Snapshot files on lung CT scan lesion size and depth measurements and the biopsy samples obtained were sent to pathology. After the biopsy the patient CT scan was to act as the presence or absence of symptoms, proper action was made. Among 102 patients studied, 85 patients (83.4%) were uncomplicated, but 8 patients (7.9%) were suffered from pneumothorax. In the study were made between lesion size and depth of complications found no correlation, but between lesion location and complications caused there was statistically significant difference. The needle biopsy guided by CT scan due to low complications in many cases is a suitable diagnostic method.

Key words: Needle biopsy, pneumothorax, lesion size, depth of complications

INTRODUCTION

Fine-needle aspiration (FNA) or core biopsy of intra-thoracic masses that performed with ultrasound or Computed Tomography (CT) guidance, has become an increasingly popular technique owing to its distinct advantages of being sensitive and specific, expedient, economical and safe (Smith *et al.*, 1985). CT-guided sampling of thoracic lesions have been described and utilized in human medicine (Steil *et al.*, 2009; Geraghty *et al.*, 2003; Chojniak *et al.*, 2006). The specificity, sensitivity and accuracy of this technique vary depending on the target organ and the type of needle used. The accuracy of CT-guided sampling has been reported a values between 75 to 99% in patients (Kinoshita *et al.*, 2006; Wang *et al.*, 2009; Priola *et al.*, 2007; Van Rijn and Bossuyt, 2004).

Imaging-guided percutaneous core-needle biopsy has become the modality of choice for diagnosing mediastinal masses (De-Filippo *et al.*, 2008; Rodríguez-Fernandez *et al.*, 2007). The extrapleural parasternal approach with Computed Tomographic (CT) or ultrasonographic guidance is most appropriate for lesions that extend to the anterior chest wall lateral to the

Corresponding Author: Fakher Rahim, Physiology Research Center,
Ahvaz Jundishapur University of Medical Sciences, Ahvaz, Iran
Tel: +986113362411 Fax: +986113367562

sternum (Gupta *et al.*, 2005). Many complications co-exist with FNA of trans-thoracic sampling. The most commonly reported complications in humans, regardless of modality, are pneumothorax and hemorrhage. Pneumothorax is the most frequently encountered complication during CT-guided lung biopsy, with an incidence of 22-45% (Wallace *et al.*, 2002; Li *et al.*, 1996; Gianfelice *et al.*, 2000). Higher pneumothorax rates up to 64% for lesions 1.0 cm or smaller have been reported (Gatenby *et al.*, 1984). Hemothorax, pericarditis, body wall bruising, subcutaneous emphysema, air embolism and tumor or infection seeding along the needle tract have been reported, but are uncommon (Steil *et al.*, 2009; Kinoshita *et al.*, 2006).

This study aimed to evaluate the complication rate of FNA and CT-guided biopsy of intra-thoracic masses.

MATERIALS AND METHODS

Study Population

Between November 2007 and August 2008, a total of 102 CT-guided trans-thoracic diagnostic procedures (aspiration biopsy with fine or spinal needle or core biopsy) were carried out. FNA biopsy was performed in 39 (38.2%) female and 63 (61.8%) male patients. The study population comprised all subjects who underwent the surgical resection and non-surgical patients who had completed at least 12 months of follow-up (382 subjects). The population included 202 men and 180 women, with a mean age of 59.7 years (range 4-89 years). None of the patients had a history of bleeding tendency or alterations in blood parameters or coagulation profile. Subjects receiving anti-aggregant or anticoagulation agents discontinued treatment for 7 days prior to the biopsy. The analyzed variables included the age, chest wall thickness, lesion size and depth, type of the mass and the experience of the radiologist performing the biopsies. The study was approved by the University Hospital and Ahvaz Jundishapur University of Medical Sciences Ethics Committees and all subjects granted informed consent to participate.

Exclusion Criteria

The patients with following criteria have been excluded from the study: significant changes in blood-coagulation profile, contralateral pneumonectomy, patient's inability to maintain a lying position and/or to follow verbal or visual instructions.

Needle Type and Caliber

In all procedures, we used either a single needle (20-gauge Chiba needle; 18-gauge cutting needle with coaxial technique) or, in the event of multiple biopsies, a consecutive combination of different needles. The choice of the type of needle was based on parameters such as lesion size, clinical history and imaging data, operator's preferences and the presence of the cytopathologist.

Biopsy Protocol

The radiologist briefly reviewed the patient's history just before the procedure. At the time of each biopsy, a previous diagnostic CT scan was available for all patients. All biopsies were performed according to a standard protocol by the same interventional radiologist under CT guidance with an X vision/EX Toshiba- CTS scanner. The patient reposed on the CT table in prone, supine or lateral decubitus positions depending on lesion location. After having established the entry site and selection of the proper needles, the needle entry site

was anaesthetized (2% lidocaine), the needle, positioned and the patient instructed to hold his or her breath. At this point CT scans were obtained to visualize the needle tip in relation to the lesion. Biopsies were carried out by needle aspiration with a 20-gauge fine needle or by core biopsy with an 18-gauge cutting needle. To assess the presence of possible complications (pneumothorax, needle track bleeding), post-procedural CT scans were carried out 10-15 min after the procedure.

Statistical Analysis

Statistical analysis was conducted with the SPSS 15.0 and aimed at evaluating the accuracy of the procedure. Differences between proportions were analyzed with Chi-square tests or Student’s t test. Parameters considered significant in determining diagnostic accuracy were further stratified and correlated to accuracy with the aid of contingency graphs and tables. A p value<0.05 was taken as significant in all cases.

RESULTS

The patients were divided randomly to 5 groups based on the age criteria (Table 1), the most frequent age was 66 to 80-year group with related frequency of 42.2% (43/102). Of 102 CT-guided FNA biopsy procedures, 8(7.9%) were complicated by pneumothorax, with 2(1.9%) patients requiring thoracostomy tube placement. It showed subtle enhancement, which made the lesion indeterminate and a biopsy was advised. Using the traditional technique, the needle could be placed only along the side of the nodule; in some cases pneumothorax was presented (Fig. 1A, B) and mild parenchymal hemorrhage (Fig. 3A, B).

Table 1: Frequency distribution of patients in different age groups

Age groups (years)	No.	Percentage
<35	10	9.8
36-50	18	17.6
51-65	24	23.5
66-80	43	42.2
>80	7	6.9
Total	102	100.0

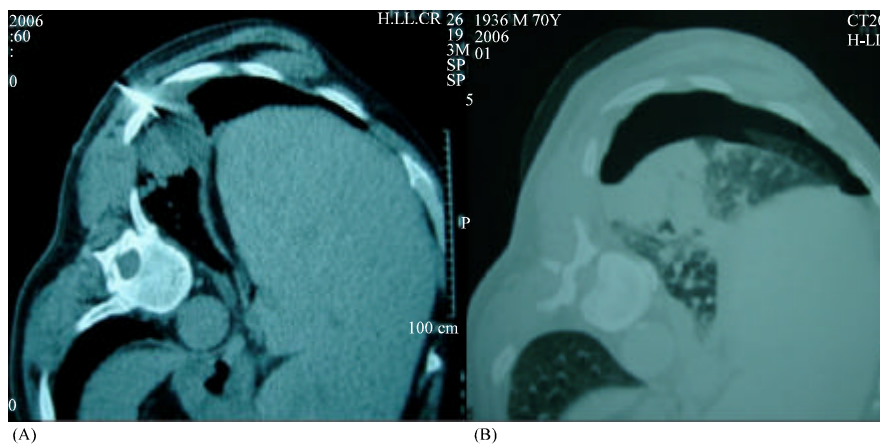


Fig. 1: (A) Needle biopsy from a sub-pleural lung nodule and (B) control CT shows pneumothorax

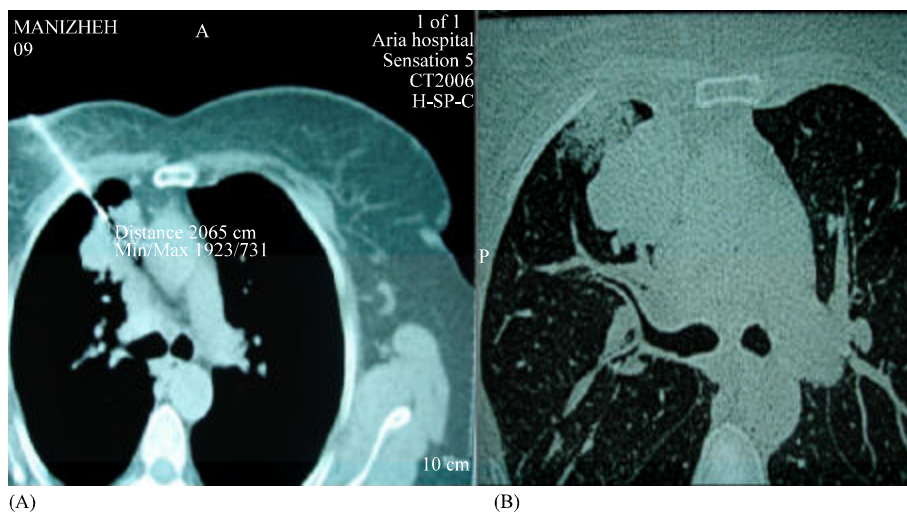


Fig. 2: (A) Needle biopsy from a right lung mass and (B) Control CT shows mild parenchymal hemorrhage

Table 2: Study of complications in patients

Complications	No.	Percentage
Pneumothorax	8	7.9
Hemothorax	4	3.9
Parenchymal hematoma	4	3.9
Hematoma	1	0.9
No. complication	85	83.4
Total	102	100.0

Table 3: Distance to the chest wall lesion desired

Distance to wall lesion (cm)	No.	Percentage
<3	45	44.1
3.1-6	52	51.0
>6	5	4.9
Total	102	100.0

In case of CT showing a right basal lung mass, needle biopsy confirmed bronchoalveolar cell carcinoma involving the right lower lobe. The control CT showed mild parenchymal hemorrhage (Fig. 2A, B).

The complications have been listed in Table 2, Chest wall thickness was varied in range from 0.75 to 10 cm (mean of 3.8 cm). The length between chest wall and lesion is summarized in Table 3; most frequent length was in range of 3.1- 6 cm among 52 patients (51%). There was no significant correlation between the size and depth of lesion with presence of the complications. In the case of the depth and position of the lesion, 53 (52%) of the patients have internal hemi-thorax and the rest 49 (48%) have external hemi-thorax. There was significant ($p < 0.05$) correlation between the position of the lesion. Out of 53 cases of internal hemi-thorax 14 (13.7%) were complicated by pneumothorax. Only 3 (2.9%) patients out of 49 external hemi-thorax cases were complicated by pneumothorax. A final diagnosis could be obtained for all 102 patients: 65.68% (67/102) of lesions were found to be malignant, 25.49% (26/102) were benign, whereas no reliable judgment could be made among the 9 (8.82%) cases (Table 4).

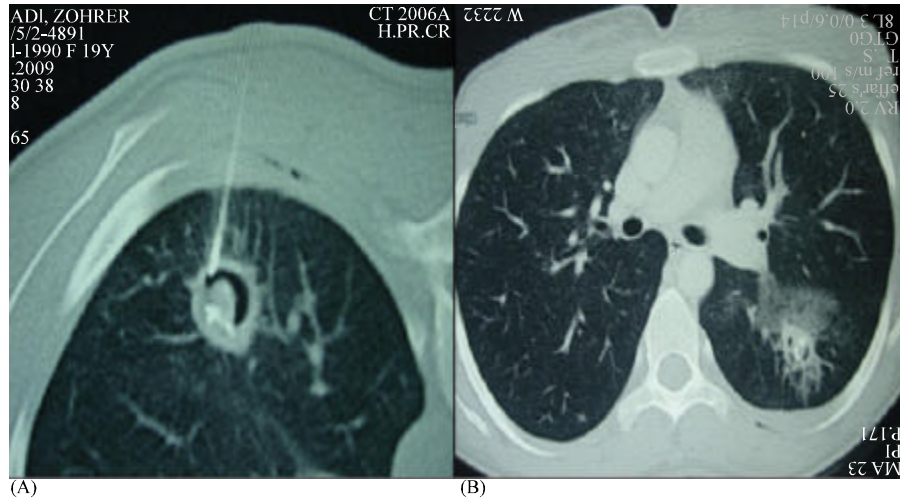


Fig. 3: (A) Needle biopsy from a lung nodule and (B) Control CT shows pleural effusion and mild parenchymal hemorrhage

Table 4: Type of lesion obtained in patients under study

Type of lesion	Male (%)		Female (%)		Total (%)	
	No.	%	No.	%	No.	%
Malignancy	43	42.15	24	23.52	67	65.68
Benign	13	12.74	13	12.74	26	25.49
Unexplained diagnosis tissue	4	3.90	5	4.90	9	8.82
Total	60	58.90	42	41.10	102	100.00

DISCUSSION

Review of the existing literature reveals variable rates of pneumothorax that range from 8 to 64%. However, pneumothorax remains the most common complication of CT-guided lung biopsy (Wallace *et al.*, 2002; Li *et al.*, 1996; Gianfelice *et al.*, 2000). Wallace *et al.* (2002) in a study on 61 patients (34 men and 27 women) 21-89 years old with lung nodules underwent CT-guided trans-thoracic FNA biopsy, reported 38 (62%) patients had pneumothorax, with 19 (31%) requiring thoracostomy tube placement. Recently, Ng *et al.* (2008) in a study on 55 patients using coaxial technique claimed that pneumothorax occurred in 29 (52.7%) patients, with five (9.1%) requiring thoracostomy tubes. In the study made by Topal and Ediz (2003), they have not found significant relationship between size and depth of lesions with complications, but were found statistically significant correlation between the location and complications. Our study show that lesions less than 2 cm have pneumothorax rate 11 times more waste than 4 cm, which may cause difficulty and increase exercise time of needle biopsy. Increasing depth of lesion was revealed bleeding lesions communication distance of more than 2 cm from the surface of pleural lesions compared with 10 times the risk of sticking to the pleural bleeding that can cause due to crowding and large vessels is more central areas. So, in this study reduce the risk of pleural effusion was accompanied with less bleeding. This is possible because of the negative pressure inside the space next to the effects of effusion and tamponade by delayed in diagnose the bleeding. This finding was in agreement with the results of a study conducted by Gohari and Haramati (2004).

The use of core biopsies as the first line technique for assessing diagnoses of pulmonary nodules is still debated. During the past 30 years, numerous studies have proved the accuracy and safety of radio-graphically guided trans-thoracic lung biopsy procedures (Tsukada *et al.*, 2000; Satoh *et al.*, 2005; Laurent *et al.*, 2000). According to the Massachusetts group the FNA should still be performed initially if a cyto-pathologist is available in the CT room and malignancy is suspected (McLoud, 1998). However, if a malignant diagnosis is obtained on review of the FNA, a core biopsy is not needed. Furthermore, if it is non-diagnostic or suggestive of a benign process, a core biopsy should then be performed (Boiselle *et al.*, 1997).

Many researches have been discussed the mortality due to applying this technique. Reports of death in the literature are very rare. Greene (1982), estimated mortality associated with fine needle aspiration to be 0.02%. Most deaths were attributed to fatal air embolism. Hirasawa *et al.* (2008) reported a case of cerebral air embolism which occurred during Computed Tomography (CT)-guided needle biopsy. In that case the air entering the aorta is depicted on CT-fluoroscopy images of the procedure. There was no reported death in our study as a complication of biopsy.

Hiraki *et al.* (2007) in study based on four cases of systemic air embolism complicating CT scan-guided trans-thoracic needle biopsy, which were encountered among 1010 procedures performed. In three patients without cardiac or cerebral symptoms, the presence of systemic air was confirmed on post-procedural CT scan images, which was resolved without causing morbidity after the immediate therapy. In this study there was no reported air embolism complicating CT scan-guided trans-thoracic needle biopsy.

CONCLUSIONS

Trans-thoracic CT-guided needle biopsy of pulmonary lesions is a highly accurate procedure, especially in malignant lesions. Considering the possible complications of anesthesia and thoracotomy and mediastenostomy admission and require several days of surgery mentioned above and the high cost biopsy guided by CT scan method is less invasive and the other hand, are cheaper and in many cases can be a suitable replacement for above mentioned surgeries.

ACKNOWLEDGMENT

The authors would like to thanks the patients and their family. The study was fully supported by the research deputy of Ahwaz Jondishapour University of Medical Sciences.

REFERENCES

- Boiselle, P.M., J.A., Shepard, E.J., Mark, W.M. Szyfelbein and C.M. Fan *et al.*, 1997. Routine addition of an automated biopsy device to fine-needle aspiration of the lung: A prospective assessment. *Am. J. Roentgenol.*, 169: 661-666.
- Chojniak, R., R.K. Isberner, L.M. Viana, L.S. Yu, A.A. Aita and F.A. Soares, 2006. Computed tomography guided needle biopsy: Experience from 1,300 procedures. *Sao Paulo Med. J.*, 124: 10-14.
- De-Filippo, M., M. Onniboni, M. Rusca, P. Carbognani and L. Ferrari *et al.*, 2008. Advantages of multidetector-row CT with multiplanar reformation in guiding percutaneous lung biopsies. *Radiol. Med.*, 113: 945-953.

- Gatenby, R.A., C.B. Mulhern, G.J. Jr. Broder and P.J. Moldofsky, 1984. Computed-tomographic-guided biopsy of small apical and peripheral upper-lobe lung masses. *Radiology*, 150: 591-592.
- Geraghty, P.R., S.T. Kee, G. McFarlane, M.K. Razavi, D.Y. Sze and M.D. Dake, 2003. CT-guided transthoracic needle aspiration biopsy of pulmonary nodules: Needle size and pneumothorax rate. *Radiology*, 229: 475-481.
- Gianfelice, D., L. Lepanto, P. Perreault, C. Chartrand-Lefebvre and P.C. Milette, 2000. Value of CT fluoroscopy of percutaneous biopsy procedures. *J. Vascular Interventional Radiol.*, 11: 879-884.
- Gohari, A. and L.B. Haramati, 2004. Complications of CT scan-guided lung biopsy: Lesion size and depth matter. *Chest*, 126: 666-668.
- Greene, R.E., 1982. Transthoracic Needle Aspiration Biopsy. In: *Interventional Radiology*, Athanasoulis, C.A., R.C. Pfister, R. Greene, R.E. Lambiase and L. Deyoe *et al.* (Eds.). Saunders, Philadelphia, PA., ISBN: 0-86577-286-X, pp: 587-634.
- Gupta, S., K. Seaberg, M.J. Wallace, D.C. Madoff and F.A. Morello *et al.*, 2005. Imaging-guided percutaneous biopsy of mediastinal lesions: Different approaches and anatomic considerations. *Radiographics*, 25: 763-786.
- Hiraki, T., H. Fujiwara, J. Sakurai, T. Iguchi and H. Gobara *et al.*, 2007. Nonfatal systemic air embolism complicating percutaneous CT-guided transthoracic needle biopsy: Four cases from a single institution. *Chest*, 132: 684-690.
- Hirasawa, S., H. Hirasawa, A. Taketomi-Takahashi, H. Morita and Y. Tsushima *et al.*, 2008. Air embolism detected during computed tomography fluoroscopically guided transthoracic needle biopsy. *Cardiovascular Interventional Radiol.*, 31: 219-221.
- Kinoshita, F., T. Kato, K. Sugiura, M. Nishimura and T. Kinoshita *et al.*, 2006. CT-guided transthoracic needle biopsy using a puncture site-down positioning technique. *AJR Am. J. Roentgenol.*, 187: 926-932.
- Laurent, F., V. Latrabe, B. Vergier, M. Montaudon, J.M. Vernejoux and J. Dubrez, 2000. CT-guided transthoracic needle biopsy of pulmonary nodules smaller than 20 mm: Results with an automated 20-gauge coaxial cutting needle. *Clin. Radiol.*, 55: 281-287.
- Li, H., P. Boiselle, J.O. Shepard, B. Trotman-Dickenson and T.C. McLoud, 1996. Diagnostic accuracy and safety of CT-guided percutaneous needle aspiration biopsy of the lung: comparison of small and large pulmonary nodules. *AJR Am. J. Roentgenol.*, 167: 105-109.
- McLoud, T.C., 1998. Should cutting needles replace needle aspiration of lung lesions? *Radiology*, 207: 569-570.
- Ng, Y.L., D. Patsios, H. Roberts, A. Walsham and N.S. Paul *et al.*, 2008. CT-guided percutaneous fine-needle aspiration biopsy of pulmonary nodules measuring 10 mm or less. *Clin. Radiol.*, 63: 272-277.
- Priola, A.M., S.M. Priola, A. Cataldi, L. Errico and M. Di Franco *et al.*, 2007. Accuracy of CT-guided transthoracic needle biopsy of lung lesions: Factors affecting diagnostic yield. *Radiol. Med.*, 112: 1142-1159.
- Rodriguez-Fernandez, A., M. Gomez-Rio, J.M. Llamas-Elvira, R.A. Sanchez-Palencia and M. Bellon-Guardia *et al.*, 2007. Diagnosis efficacy of structural (CT) and functional (FDG-PET) imaging methods in the thoracic and extrathoracic staging of non-small cell lung cancer. *Clin. Transl. Oncol.*, 9: 32-39.
- Satoh, S., S. Ohdama, O. Matsubara, Y. Okochi, R. Tanaka and Y. Kimula, 2005. CT-guided automated cutting needle biopsy by a combined method for accurate specific diagnosis of focal lung lesions. *Radiation Med.*, 23: 30-36.

- Smith, T.J., H. Safaii, E.A. Foster and R.B. Reinhold, 1985. Accuracy and cost-effectiveness of fine needle aspiration biopsy. *Am. J. Surgery*, 149: 540-545.
- Steil, S., S. Zerwas, G. Moos, F. Bittinger, T. Hansen, U. Mergenthaler and R., Weide, 2009. CT-guided percutaneous core needle biopsy in oncology outpatients: Sensitivity, specificity, complications. *Onkologie*, 32: 254-258.
- Topal, U. and B. Ediz, 2003. Transthoracic needle biopsy: Factors effecting risk of pneumothorax. *Eur. J. Radiol.*, 48: 263-267.
- Tsukada, H., T. Satou, A. Iwashima and T. Souma, 2000. Diagnostic accuracy of CT-guided automated needle biopsy of lung nodules. *AJR Am. J. Roentgenol.*, 175: 239-243.
- Van Rijn, J.C. and P.M. Bossuyt, 2004. Needle size in CT-guided transthoracic needle aspiration biopsy: Complications and accuracy. *Radiology*, 232: 305-306.
- Wallace, M.J., S. Krishnamurthy, L.D. Broemeling, S. Gupta, K. Ahrar, F.A. Morello and M.E. Jr. Hicks, 2002. CT-guided percutaneous fine-needle aspiration biopsy of small (or=1-cm) pulmonary lesions. *Radiology*, 225: 823-828.
- Wang, H.J., T.K. Leung, C.M. Lee and Y.Y. Chen, 2009. Three-step needle withdrawal method: A modified technique for reducing the rate of pneumothorax after CT-guided lung biopsy. *Chang Gung Med. J.*, 32: 432-437.