

Lungworm Infestation in Piglets in Different Parts of Mizoram, India

¹G. Patra, ²H. Prasad, ³Jonathan Lalsiamthara, ⁴J.L. Kataria, ⁵David Malsawmkima and
⁶H. Lalrinkima

¹Department of Veterinary Parasitology, ²Department of Veterinary Medicine,
College of Veterinary Sciences and Animal Husbandry, Central Agricultural University, Selesih, Aizawl,
Mizoram, India

³Division of Animal Biotechnology, ⁴Division of Veterinary Public Health, Indian Veterinary Research
Institute, Izatnagar, Bareilly, U.P., India

⁵Department of Veterinary Microbiology, College of Veterinary Sciences and Animal Husbandry,
Central Agricultural University, Selesih, Aizawl, Mizoram, India

⁶Division of Veterinary Parasitology, Indian Veterinary Research Institute, Izatnagar, Bareilly, U.P., India

ABSTRACT

To obtain data on the incidence of lungworm infestation in piglets in different parts of Mizoram of India a survey was conducted during the calendar year 2011-2012 based on clinical and postmortem findings and in addition some biochemical and histopathological changes of affected lungs associated with *Metastrongylus elongates* infection were performed. The percent prevalence of lung worm infection in young piglets (upto 4-6 months old) was 40%. Clinically, infected piglets were exhibiting chronic and paroxysmal coughing with generalized unthriftiness. Histologically, tips of the lungs were found to be hard and become grayish or whitish. Histopathological studies revealed pulmonary emphysema. The alveolar cellular reaction of the affected lungs showed epithelialization of alveoli with infiltration of round cells, eosinophils, giant cells, fibers and lungworm eggs. Biochemical analysis of serum from infected piglets showed a significant increase in serum Alanine Amino Transferase (ALT), serum glucose, inorganic chloride, potassium and magnesium with a decrease in serum albumin, total protein and alkaline phosphatase with insignificant changes in the serum sodium level. The pork consumption in Mizoram is very high and pigs under four to six months of age showed the highest mortality rate with respiratory signs in different parts of this area during the study period. There was a serious herd problem associated with hypoproteinaemia, hyperglycaemia and reduced growth rate.

Key words: Swine, lungworm infection, histopathology, alanine amino transferase, serum protein

INTRODUCTION

Lungworm infection is a major problem in swine production. With the development of confinement housing and subsequent lack of access to soil (and earthworms), lungworms infection has decreased in prevalence. However, pigs raised in the outdoors, lungworms infection still can be a serious problem. The percent prevalence of lungworm ranging from 50 to 100% infection in wild boars was reported by several workers (Solaymani-Mohammadia *et al.*, 2003; Morita *et al.*, 2007; Jarvis *et al.*, 2007; Yoon *et al.*, 2010). In infected premises pigs under four to six months of age show highest infection rates and up to 50-60% of lungs may be found to be affected. In general,

the disease entity is similar to that caused by *Dictyocaulus filaria*, but the pig lungworms are not as pathogenic as those which occur in ruminants (Soulsby, 1982). In young pigs a marked verminous bronchitis and pneumonia may sometimes be seen, these are possibly due to secondary bacterial infection. However, the parasites cause mainly loss of condition and retarded growth which is rather important in pigs. The parasites may sometimes die in the small bronchioles and give rise to the formation of nodules which must be differentiated from tuberculous nodules at autopsy or at meat inspection (Soulsby, 1982). Shope (1958) showed that the larva of swine lungworm can carry the virus of swine fever to pigs in a form which requires some form of stress to provoke this virus to pathogenicity. Mackenzie (1958) found that *M. elongatus* had a negligible effect on pigs experimentally infected with it, but that lesion resembling those of enzootic pneumonia could be produced. Studies of pigs with uncomplicated *Metastrongylus* infections have demonstrated pathology ranging from no gross lung lesion (Preston and Switzer, 1976; Stockdale, 1976) to bronchitis, bronchiolitis and pneumonitis (Mackenzie, 1959; Stockdale, 1976). Larval migration, adults in the bronchioles and discarded cuticles of developing larvae may cause these lesions in the postero-ventral margins of the diaphragmatic lobes. Parasites, mucus and debris that occlude bronchi or bronchioles may cause atelectasis (Stockdale, 1976). Blockage of airways may also lead to violent coughing (Mackenzie, 1958).

Present study was conducted to record the incidence of lungworm infections in young piglets in different parts of Mizoram of India and also to determine the histopathology and some selected biochemical parameters in piglets infected with lungworms.

MATERIALS AND METHODS

Method of the survey: The lungs with trachea and bronchi were removed intact from the carcass. Scissors were used to open the trachea and bronchi and smaller air passageways in the lungs. An animal was considered free from infestation if no adult lungworms were revealed by this dissection. Several specimens of lungworms were taken from the lungs of positive cases. A total of eighty piglets showing symptoms of chronic coughing were clinically examined and symptoms, morbidity and mortality were recorded.

Histopathological study: Histopathological studies were performed on the lungs of piglets died due to natural infection with lungworm. For histopathological changes morbid tissues from the lungs were collected and fixed in 10% formal saline solution. Tissues were then dehydrated in absolute alcohol, cleared in xylene and embedded in paraffin for preparation of fine blocks in paraffin wax. Sections were made at 5 mm thickness and slide were stained with haematoxyline and eosin stain as per the methodology of Lillie (1965).

Species identification: For species identification, the adult parasites were recovered from the lumen of bronchi with the help of a fine camel brush, placed in a petridish containing physiological saline, washed thoroughly and then put into another petridish containing lactophenol for subsequent morphological study.

Biochemical study: For biochemical study, 2 mL of blood was collected randomly from 10 piglets each from naturally infected with lungworms in a sterile test tube without anticoagulant and

allowed to clot. Serum was separated out and kept at -20°C till analysis. Serum was analyzed for glucose, albumin, total protein, urea, serum enzymes of viz., SGOT, SGPT and Alkaline phosphatase and some inorganic substances like sodium, potassium, chloride and magnesium. Serum samples were spectrophotometrically analyzed for the activities of Alanine Amino Transferase (ALT), Aspartate Amino Transferase (AST), Alkaline Phosphatase (ALP), glucose, protein and albumin as a biochemical indicators for liver function using commercially available diagnostic kits. Serum level of urea nitrogen, chloride, sodium, potassium and magnesium were used for evaluation of kidney function. The normal values of the above criterions were taken from the 10% apparently healthy piglets of the respective areas. The data were statistically analyzed.

Statistical analysis: The data generated were subjected to statistical analysis by employing ANOVA and Duncan post test for meaningful and accurate comparison and interpretation between infected and uninfected groups using SPSS Version 16.0.

RESULTS

Among the animals examined were 11 Champhai district. A lungworm incidence of 63% in piglets was observed in this district. Twenty six piglets were examined from Saiha district and an incidence of 19% was revealed. Piglets from these two districts were harboring highest and lowest lungworm infestations, respectively among all the districts of Mizoram shown in Table 1. Significant differences were noticed ($p \leq 0.05$). The result in Table 2 show significant increasing

Table 1: Prevalence of *Metastrongylus elongatus* in piglets in different parts of Mizoram, India

Place	No. of piglets examined	No. of piglets found positive for <i>Metastrongylus elongatus</i>	Percentage of infection (district wise)
Aizawl	35	22	62
Mamit	33	15	45
Lunglei	38	12	31
Saiha	26	5	19*
Serchhip	18	4	22
Kolasib	19	7	36
Champhai	11	7	63*
Lawngtlai	20	8	40
Total	200	80	

*Significant differences at $p \leq 0.05$

Table 2: Serum biochemical profile of pig infected with *Metastrongylus elongates*

Parameters	Methods	Normal value	Test sample
Glucose (mg dL ⁻¹)	GOD-PAP	85-150	203.76±23.96*
Total Protein (gm dL ⁻¹)	Biuret method	3.5-6.0	0.862±0.061*
Albumin (gm dL ⁻¹)	BCG method	1.9-2.4	0.53±0.07*
Urea (mg dL ⁻¹)	Berthelot method	10-30	11.49±1.47
ALP (unit L ⁻¹)	Reitman-Frankel	122-400	12.19±1.51*
Chloride (mmol L ⁻¹)	Thiocyanate-Hg	94-100	210.39±8.76***
Potassium (mmol L ⁻¹)	Colorimetric	4.7-7.1	8.37±0.44*
Sodium (mmol L ⁻¹)	Colorimetric	140-150	152.77±0.89
Magnesium (mg dL ⁻¹)	Calmagite	2.2-3.2	4.71±0.25*
SGPT/ALT (unit L ⁻¹)	Reitman-Frankelm	21-102	686.08 ±1.32*

*Significant differences at $p \leq 0.01$

Table 3: Number of pigs positive for swine fever virus infected with *Metastrongylus elongatus*

Place	No. of piglets found positive for <i>Metastrongylus elongatus</i>	No. of piglets found positive for swine fever virus tested with ELISA
Aizawl	22	2
Mamit	15	1
Lunglei	12	Nil
Saiha	5	Nil
Serchhip	4	Nil
Kolasib	7	1
Champhai	7	1
Lawngtlai	8	Nil

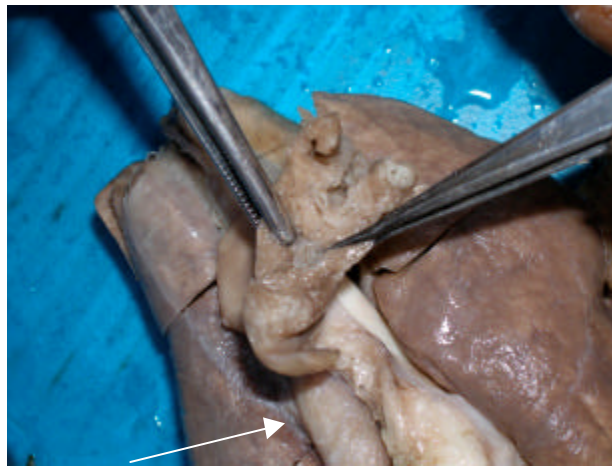


Fig. 1: Adult parasites (arrow) of *Metastrongylus elongatus* in the bronchi of apical lobes of lungs of a piglet

($p \leq 0.01$) in serum glucose ($203.76 \text{ mol L}^{-1}$), SGPT (686.08 U L^{-1}), chloride ($210.39 \text{ mmol L}^{-1}$), potassium (8.37 mmol L^{-1}) and magnesium (4.71 mg dL^{-1}) in infected animals in comparison with non infected animals. There is no change in serum urea in both infected animals and non infected animals. There is significant decreasing ($p \leq 0.01$) in total serum protein (0.862 g dL^{-1}), albumin (0.53 gm dL^{-1}) and ALP ($12.19 \text{ unit L}^{-1}$). Number of piglets positive for swine fever virus infected with *Metastrongylus elongatus* is presented in Table 3. Two infected piglets from Aizawl district were found positive for swine fever as detected by ELISA where as one piglet each from Mamit, Kolasib and Champhai was sero positive. The infected piglets from rest four districts of Mizoram were free from any swine fever virus. The finding of lung worm infection in association with swine fever strengthened the observation of Shope (1958) that the larva of *Metastrongylus elongatus* may carry the virus of swine fever in pigs.

On post-mortem examination, there was focal consolidation of lungs, trachea and bronchi and bronchioles were filled with frothy exudates. Several thread like worms were recovered from fine bronchioles. The average length of the worm was 30 cm. Figure 1 shows adult lungworm in the bronchi. On the basis of morphological feature, lung worm is identified as *Metastrongylus elongatus* (Soulsby, 1982). The worms were white in color and had six small lips around the mouth opening. Figure 2 shows the anterior part of *Metastrongylus elongatus* with prominent lips surrounding the oral aperture.




Fig. 2: Anterior end of the swine lungworm *Metastrongylus apri* showing prominent lips (4x)

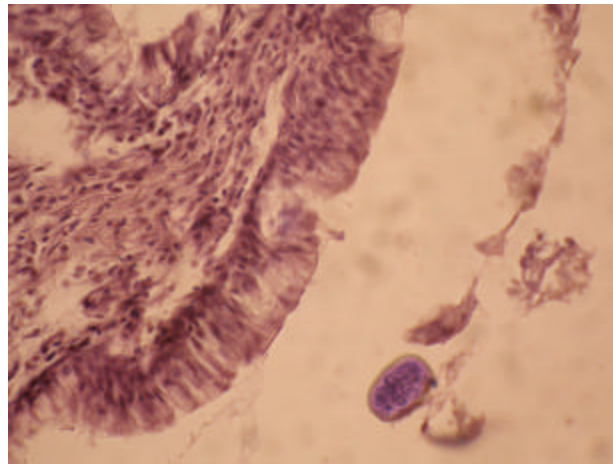


Fig. 3: Histopathological section of lung tissue showing embryonated egg (arrow) of *Metastrongylus elongatus*: H and E (10X)

Histologically, tips of the lungs were found to be hard and become grayish or whitish. Histopathological examination of the lung tissue exhibited extensive tissue reaction characterized by various degrees of cellular infiltration and fibrosis along with eggs of the parasites. Note the fully developed egg with thick shell in Fig. 3. Clinically, affected piglets showed a chronic and paroxysmal coughing with unthriftiness. Out of 80 infected piglets, 2 piglets died positively due to severe infection.

DISCUSSION

In the present study, a survey was conducted to find out lung worm infection of piglets in different parts of Mizoram, India. Clinically, out of 200 piglets examined, 80 piglets between

4-6 months were found to be infected which is 40% of the total piglets examined. Clinically, affected piglets showed a chronic and paroxysmal coughing with unthriftiness. Out of 80 infected piglets, 2 piglets died positively due to severe infection. The lungworm was identified as *Metastrongylus elongatus*. Records show that this species of lungworm is cosmopolitan in distribution. In domesticated and wild pigs, it is found in the bronchi and bronchioles; it had also been found infecting sheep, deer, ox and other ruminants (Monning and Lapage, 1956). It has been suggested that pigs below 1 year age had a greater rate of infection than did older pigs and two possible reasons could explain this age-dependent susceptibility: younger pigs consume larger amounts of animal matter than older pigs and are therefore more chance to pick up infection from consumption of earthworm intermediate hosts and acquired immunity is developed only after repeated contacts with the parasite (Humbert, 1991).

Histopathological examination of the lung tissue exhibited extensive tissue reaction characterized by various degrees of cellular infiltration and fibrosis along with eggs of the parasites. Histopathological lesions observed in the present investigation were similar to the findings observed by Subramaniam *et al.* (1967) and Rose (1973). Shope (1958) showed that the larva of swine lungworm can carry the virus of swine fever to pigs in a form which requires some form of stress to provoke this virus to pathogenicity. In the present study, out of 80 numbers. of piglets infected with *Metastrongylus elongates* five piglets were found to be positive for swine fever virus tested with ELISA. Four out of eight districts of Mizoram namely Aizawl, Kolasib, Mamit and Champhai showed sero-positiveness for swine fever. It has been seen that most of the piglets in these regions were kept in moist ground.

The analysis of biochemical parameters showed an increase in the serum glucose level and a decrease in the serum total protein and albumin. The increased serum glucose and decrease level of total protein observed in lungworm infected piglets suggested liver dysfunction secondary to circulatory disturbance. The activity of alanine aminotransferase significantly changed because of degeneration of cellular membrane, loss and collapse of diffuse tissue inflammation (Kaneko *et al.*, 1997). In the present study, there is no significant change in Aspartate Amino Transferase (AST) level in infected piglets due to lungworm infection. AST is not exclusively a hepatical enzyme, since there is also a muscular origin (Campbell and Coles, 1989). Alkaline phosphatase level was decreased significantly in the affected piglets which are indicative to damages to bone marrow with severe growth depression as ALP is known to rise during active growth (Reddy *et al.*, 1988a, b; Nagalakshmi *et al.*, 1996). The significantly higher serum chloride, potassium and magnesium and lower blood urea nitrogen in infected piglets might result from more severe kidney dysfunction, metabolic acidosis, as well as intravascular haemolysis (Kitagawa *et al.*, 1998; Niwetpathomwat *et al.*, 2007). Ayoade *et al.* (1996) reported that lungworm infection is associated with anaemia, low serum protein and serum sodium value and hence low productivity in domestic pigs. The normal values of the above criterions were taken from the 10% apparently healthy piglets of the respective areas.

CONCLUSION

Swine lungworms were found in the lungs of 80 (40%) of the total 200 piglets examined in different regions of Mizoram, India. A hypoproteaenemia, hyperglycemia with dysfunction in the liver and kidney functions were the main results in pig lungworm caused by *Metastrongylus elongatus* in the present study so it can be deduced that infection of piglet with

lungworm may induce a severe hypoproteinaemia and hyperglycaemia with disturbance in liver and kidney function. It is suggested to rear pigs on sties with concrete floors and avoid moist soil as far as practicable to reduce piglet mortality in association with lungworm and swine fever infection.

REFERENCES

- Ayoade, G.O., R.E. Anita and J. Michale, 1996. Haematological changes associated with lung worm (*Metastrongylus* sp.). *Int. J. Anim. Sci.*, 25: 229-230.
- Campbell, T.W. and E.H. Coles, 1989. *Patologia Clinica de Aves*. In: *Diagnostico y Patologia en Veterinaria*, Coles, E.H. (Ed.), 4th Edn., Interamericana McGraw-Hill, Mexico, pp: 285-308.
- Humbert, J.F., 1991. Helminth parasitism as a factor of mortality among wild ungulates in Europe: *Metastrongylus* sp. Lungworms of the wild boar. *Proceedings of the International Symposium on Ongule/Ungulates*, September 2-6, 1991, Toulouse, France, pp: 535-538.
- Jarvis, T., C. Kapel, E. Moks, H. Talvik and E. Magi, 2007. Helminths of wild boar in the isolated population close to the northern border of its habitat area. *Vet. Parasitol.*, 150: 366-369.
- Kaneko, J.J., J.W. Harvey and M.L. Bruss, 1997. *Clinical Biochemistry of Domestic Animals*. 5th Edn., Academic Press, San Diego, California, ISBN-13: 9780123963055, Pages: 932.
- Kitagawa, H., K. Kitoh, Y. Ohba, Y. Kuwahara, T. Iwasaki and Y. Sasaki, 1998. Comparison of laboratory test results before and after surgical removal of heartworms in dogs with vena caval syndrome. *J. Am. Vet. Med. Assoc.*, 213: 1134-1136.
- Lillie, R.D., 1965. *Histopathologic Technique and Practical Histochemistry*. 3rd Edn., Mc. Graw-Hill, New York, pp: 525-558.
- Mackenzie, A., 1958. Studies on lungworm infection of pigs II. Lesions in experimental infections. *Vet. Record*, 70: 903-906.
- Mackenzie, A., 1959. Studies on lungworm infection of pigs III. The progressive pathology of experimental infections. *Vet. Record*, 71: 209-212.
- Monning, H.O. and G. Lapage, 1956. *Veterinary Helminthology and Entomology*. 4th Edn., Bailliere Tindall, London, Pages: 511.
- Morita, T., K. Haruta, A. Shibata-Haruta, E. Kanda, S. Imai and K. Ike, 2007. Lung worms of wild boars in the western region of Tokyo, Japan. *J. Vet. Med. Sci.*, 69: 417-420.
- Nagalakshmi, D., V.R.B. Sastry, D.K. Agrawal, R.C. Ketiyar and S.V.S. Verman, 1996. Performance of broiler chicks fed on alkali-treated neem (*Azadirachta indica*) kernel cake as a protein supplement. *Pr. Poult. Sci.*, 37: 809-818.
- Niwetpathomwat, A., M. Kaewthamasorn, S. Tiavsirisup, S. Techamgansuvan and S. Suvarnvibhaja, 2007. A retrospective study of the clinical hematology and the serum biochemistry tests made on canine dirofilariasis cases in an animal hospital population in Bangkok, Thailand. *Res. Vet. Sci.*, 82: 364-369.
- Preston, K.S. and W.P. Switzer, 1976. Failure of lungworm larvae infected earthworm to transmit mycoplasmal pneumonia to swine. *Vet. Microbiol.*, 1: 15-18.
- Reddy, V.R., P.V. Rao and C.V. Reddy, 1988a. Chemical composition and nutritive value of variously processed neem cake. *India J. Anim. Sci.*, 58: 870-874.
- Reddy, V.R., P.V. Rao and C.V. Reddy, 1988b. Utilization of chemically neem oil in broiler chicks. *Ind. J. Anim. Sci.*, 58: 830-834.
- Rose, J.H., 1973. Lungworms of the domestic pig and sheep. *Adv. Parasitol.*, 11: 559-599.

- Shope, R.E., 1958. The swine lungworm as a reservoir and intermediate host for pig hog cholera virus. I. The provocation of masked hog cholera virus. *J. Exp. Med.*, 107: 609-622.
- Solaymani-Mohammadia, S., I. Mobedia, M. Rezaiana, J. Massouda and M. Mohebalia *et al.*, 2003. Helminth parasites of the wild boar, *Sus scrofa*, in Luristan Province, western Iran and their public health significance. *J. Helminthol.*, 77: 263-267.
- Soulsby, E.J.L., 1982. *Helminths, Arthropods and Protozoa of Domesticated Animals*. 7th Edn., Bailliere Tindall, London Pages: 809.
- Stockdale, P.H., 1976. Pulmonary pathology associated with metastrongyloid infections. *Br. Vet. J.*, 132: 595-608.
- Subramaniam, T., B.A. D'souza and D.A. Victor, 1967. Broncho-pneumonia in baby pig due *Metastrongylus apri.*. *Indian Vet. J.*, 44: 121-127.
- Yoon, B.I., H.C. Kim and J.T. Kim, 2010. Lung worm (*Metastrongylus elongates*) infection in wild boars (*Sus scrofa*) of the demilitarized zone, Korea. *J. Wildl. Dis.*, 46: 1052-1054.