



# International Journal of Pharmacology

ISSN 1811-7775

**science**  
alert

**ansinet**  
Asian Network for Scientific Information



## Research Article

# Beneficial Effects of Lipoic Acid on Post-burn Hypertrophic Scarring Model

Chunhu Zhao, Lingyun Dai, Jing Wang, Yu Jian, Zujun Mei, Xufeng Pei, Xiaoqing Xiong, Wensheng Yuan and Fengxue Wu

The Second Clinical Medical College, Yangtze University, Jingzhou City, 434020 Hubei, China

1st and 2nd author contributed to this work equally

## Abstract

**Background and Objective:** Hypertrophic scar (HTS) is a fibroproliferative disorder which develops from thermal or traumatic injury. The present experiment was intended to evaluate the beneficial effect (anti-scarring) of alpha-lipoic acid (ALA) against post burn hyperscarring rabbit ear model. **Materials and Methods:** Rabbits were separated into four groups as negative control- HTS group rabbits were induced with full thickness burn wound using a 7 mm red hot plate (100°C). While, the HTS induced rabbits were treated topically with 5, 10 and 20% ALA, respectively from the 8th day until 28 days. Data were analyzed using one-way ANOVA (analysis of variance) with a significance level of 5%. **Results:** The contents of collagen (type I and III), as well as glycosaminoglycans (hydroxyproline and hexosamine), were significantly decreased upon treatment with a different dose of ALA. All the irregular/abnormal histological changes were reverted to normal (regular collagen fibres and lesser fibroblast) on addition with ALA in dose concentration fashion. Topical application of ALA for 21 days considerably lowered the scar elevation index (SEI). Moreover, treatment with ALA could markedly up regulate or down-regulate the protein expressions of matrix metalloproteinase-1 (MMP-1) and transforming growth factor beta-1 (TGF-β1), respectively. **Conclusion:** The topical application of ALA could drastically lower the scarring area after a thermal wound in a dose-dependent manner. Hence, ALA can be recommended for treating various injury scar especially post-burn hypertrophic scar with standard anti-scarring agents.

**Key words:** Lipoic acid, hypertrophic scar, collagen, scar elevation index, thermal wound

**Received:** October 29, 2017

**Accepted:** December 26, 2017

**Published:** June 15, 2018

**Citation:** Chunhu Zhao, Lingyun Dai, Jing Wang, Yu Jian, Zujun Mei, Xufeng Pei, Xiaoqing Xiong, Wensheng Yuan and Fengxue Wu, 2018. Beneficial effects of lipoic acid on post-burn hypertrophic scarring model. *Int. J. Pharmacol.*, 14: 733-739.

**Corresponding Author:** Fengxue Wu, The Second Clinical Medical College, Yangtze University, Jingzhou City, 434020 Hubei, China  
Tel/Fax: 0086-716-8180532

**Copyright:** © 2018 Chunhu Zhao *et al.* This is an open access article distributed under the terms of the creative commons attribution License, which permits unrestricted use, distribution and reproduction in any medium, provided the original author and source are credited.

**Competing Interest:** The authors have declared that no competing interest exists.

**Data Availability:** All relevant data are within the paper and its supporting information files.

## INTRODUCTION

Hypertrophic scar (HTS) may cause due to burn, skin infection/injury, laceration, bites or by surgery owing to uncontrolled synthesis (proliferation) and deposition of fibroblast-derived extracellular matrix protein, especially collagen for a long period with persistent inflammation and fibrosis<sup>1</sup>. However, hypertrophic scar after burn injury is the common type and its prevalence is higher in Chinese population<sup>2</sup>. Currently, no acceptable procedure/protocol for treating post burn HTS, nevertheless few modalities are used to manage HTS including laser surgery, radiotherapy, silicone gel sheeting, corticosteroid injection and natural products or combination therapy<sup>3,4</sup>.

Alpha lipoic acid (ALA) and its reduced form (dihydro-lipoic acid) are known for its antioxidant activity. ALA is synthesized in mitochondria of liver and other tissues and act as a cofactor for various enzymatic reaction<sup>5</sup>. ALA has a free hydroxyl group with two sulfhydryl group (SH group), which might aid in scavenging free radicals by donating electrons and thus act as a potent antioxidant property<sup>6</sup>. In addition, it spares the endogenous antioxidant like vitamin C and E is owing to its free radical scavenging property. Also, its amphipathic property makes it as a universal antioxidant<sup>7</sup>. ALA display various pharmaceutical activities like anti-diabetic, anti-inflammatory, antimicrobial and anticancer<sup>8-10</sup>. Moreover, it exhibits neuroprotective, cardioprotective, renoprotective and hepatoprotective properties<sup>11-13</sup>.

Several studies have reported that lipoic acid possesses anti-wrinkle and anti-aging activities with enhanced wound healing property<sup>14-15</sup>. Moreover, lipoic acids are reported to inhibit excessive deposition of collagen in UV-irradiated human skin fibroblasts cells<sup>16</sup>. Taking those reports into consideration, it was hypothesized that ALA might exert an anti-scarring effect. Hence, this preclinical study was designed to check the beneficial effect of ALA by checking the collagen levels (deposition), glycosaminoglycans, scar elevation index (SEI), protein expression of TGF- $\beta$ 1 and MMP-1 as well as histological changes.

## MATERIALS AND METHODS

**Chemicals and sample preparation (ALA):** Alpha lipoic acid (ALA), hematoxylin and eosin (H and E) stain, lysis buffer, formaldehyde, xylene, toluene, glycerol were purchased from Kangchen Biotech Inc., Ltd., (Shanghai, China). All the

other chemicals utilized in the present study were of analytical grade. All the nano-sized lipoic acid samples (5/10 and 20%-tropical gels), were prepared as described by Kulkamp-Guerreiro *et al.*<sup>14</sup> for maximum absorption and provided by Nanjing Zelang Medical Technological Co. Ltd., (Nanjing, China) as gel-based cream.

**Experimental animals:** Eight healthy male New Zealand white rabbit weighing  $2300 \pm 500$  g, were procured from the animal center of Hubei University (Hubei, China). Animals were housed in a steel cage and maintained at the standard environment with 12 h light/dark cycle at 22-24°C with 60% humidity. All the animals were free to access food and water (*ad libitum*). This animal study was conducted between February, 2016-May, 2016 and had been approved by the Ethical Committee members of Yangtze University, Hubei, China (2016YU132). All the protocol used in this study (animal handling) were performed according to guidelines put forth by NIH (MD, USA).

**Induction of hypertrophic scar (HTS):** HTS induction was performed by the methods of Kryger *et al.*<sup>17</sup> with slight modifications. Briefly, the rabbits were anesthetized with sodium pentobarbital ( $50 \text{ mg kg}^{-1}$ ) and place at a dorsal position under sterile condition. Followed by six full thickness burn wounds were created by placing a 7 mm steel plate (at 100°C) for 10 sec. Each ear received 6 random (7 mm) burn wounds with complete removal of dermis, epidermis and perichondrium. Each burn wound was covered with sterile gauze for a day and returned to their respective cage.

**Grouping:** Animals were divided into four group (2 in each) as control-HTS model rabbits were induced with full thickness burn wound as mentioned above and were untreated. While, the HTS induced rabbits were treated topically with 5, 10 and 20 % ALA, respectively from the 8th day until 28 days (21 days of treatment).

**Sample preparation:** Overnight fasted animals were sacrificed on the 29th day (after 21 days of treatment) by cervical decapitation. The scar tissue in the ear region was separated immediately by avoiding cartilage and were stored at -80°C until use. A portion of scar tissue was fixed in 10% formaldehyde for histopathological analysis. The remaining portion of scar tissue was homogenised (10%) using a tris-phosphate buffer (lysis buffer) and the resultant filtrate

was centrifuged at 3000 rpm for 10 min at 4°C and the resultant supernatant was used for biochemical and molecular analysis. The proteins levels in the scar tissue homogenate were estimated using a PierceBicinchoninic acid assay kit (Thermo Fisher Scientific, Inc., MA, USA).

**Determination of collagens and glycosaminoglycans:** Both collagen I and III contents were measured using commercial ELISA kit provided by R and D Systems (MN, USA) based on manufacturers instruction. Both collagen I and III were expressed as mg g<sup>-1</sup> scar tissue. Hydroxyproline and hexosamine contents in the scar tissue (homogenate) were estimated by the methods of Woessner<sup>18</sup> and Wagner<sup>19</sup>, respectively. Both Hydroxyproline and hexosamine were expressed as mg/100 mg scar tissue.

**Histopathological analysis:** The scar tissue fixed in 10% formaldehyde and were embedded in liquid paraffin wax and sectioned at 4 µm size using microtome and mounted onto a microscope slide and stained with H and E stain for 10 h at 37°C. Finally, the scar tissue mounted on the microscopic slide was viewed under a light microscope (Olympus Co., Tokyo, Japan) to assess any histopathological changes.

**Determination of scar elevation index (SEI):** SEI corresponds the ratio of total scar area to the area of underlying dermis (based on surrounding unwounded dermis) was calculated by capturing image via light microscope (Olympus Co., Tokyo, Japan) and analyzed by ImageJ software (ver 5.1, NIH, MD, USA) and graded by the method of Kloeters *et al.*<sup>20</sup>.

**Immunoblot:** A protein extract of 50 µg (scar tissue homogenate) was resolved onto 12% polyacrylamide gel, separated by SDS-PAGE (apparatus) and electrotransferred onto a polyvinylidene difluoride membrane (Sigma, MO, USA). A mixture of 5% skimmed milk and Tween 20 in tris-phosphate buffer solution (TPBS) was used to block the membrane and followed by probing with the primary antibodies like rabbit polyclonal anti-transforming growth factor beta-1 (TGF-β1) and anti-matrix metalloproteinase-1 (MMP-1) with dilution of 1:800 and 1:1200, respectively

(abcam, Cambridge, UK) and housekeeping gene β-actin (1:800, abcam, Cambridge, UK) for 10 h at 37°C. The secondary antibody conjugated with anti-rabbit HRP (1:10,000, abcam, Cambridge, UK) were incubated for 1 h at 37°C and followed by washing with TPBS (remove unbound antibodies). The protein band of specific proteins (band) were visualized and quantified using enhanced chemiluminescent image analyzer (ChemiDoc-17001401, Bio-Rad Laboratories, Inc., Hercules, CA, USA), coupled with ImageJ software (5.1 ver, NIH, MD, USA).

**Statistical analysis:** Data were expressed as the mean ± standard deviation (SD). The significant differences between HTS vs. ALA (5/10 or 20%) were analyzed using one-way ANOVA (analysis of variance) followed by least significant difference (LSD) *post-hoc* test for multiple comparisons. SPSS software (version 23, IBM Co., NY, USA) was employed for the analysis. The p<0.05 was considered to indicate a statistically significant difference.

## RESULTS

**Effect of ALA on collagen and glycosaminoglycans:** Table 1 represented the efficacy of ALA on dermal collagens and glycosaminoglycans (GAGs) in the experimental animal. Topical application of a different dose of ALA (5, 10 and 20 %) for 21 days could significantly decrease (p<0.001) the contents of collagen type I and III as well as GAGs in a dose-dependent manner (hydroxyproline and hexosamine) as compared to HTS model.

**Effect of ALA on histological changes:** The effect of ALA on the scar tissue section stained with H and E (magnification 100×) in experimental animals are presented in Fig. 1. The HTS induced wound model rabbit section (Fig.1a) showed prominent micro-vessels with elevated neutrophil infiltration as well as showed the irregular arrangement of collagen fibers (arrow mark) with higher numbers of scattered fibroblast (spindle shape). Meanwhile, 5% ALA (Fig.1b) treated scar section showed lesser micro-vessels and neutrophil infiltrations with slightly irregular collagen fibers with high numbers of fibroblast. Whereas, treatment

Table 1: Effect of ALA on dermal collagens and glycosaminoglycans in experimental animal

Groups	Collagen I (µg g <sup>-1</sup> tissue)	Collagen III (µg g <sup>-1</sup> tissue)	Hydroxy-proline (mg/100 mg tissue)	Hexosamine (mg/100 mg tissue)
HST induced	2.24±0.34	3.72±0.50	3.23±0.42	5.89±0.77
HST+ALA 5%	2.01±0.20*	3.25±0.56*	3.00±0.44*	5.76±0.82*
HST+ALA 10%	1.88±0.27**	2.93±0.44**	2.81±0.35**	5.63±0.65*
HST+ALA 20%	1.65±0.19***	2.60±0.36***	2.59±0.33***	5.49±0.57**

Data are expressed as the mean ± standard deviation (SD). \*\*p<0.001, \*p<0.01, #p<0.05 show comparison between HST vs ALA group (5, 10 and 20%)

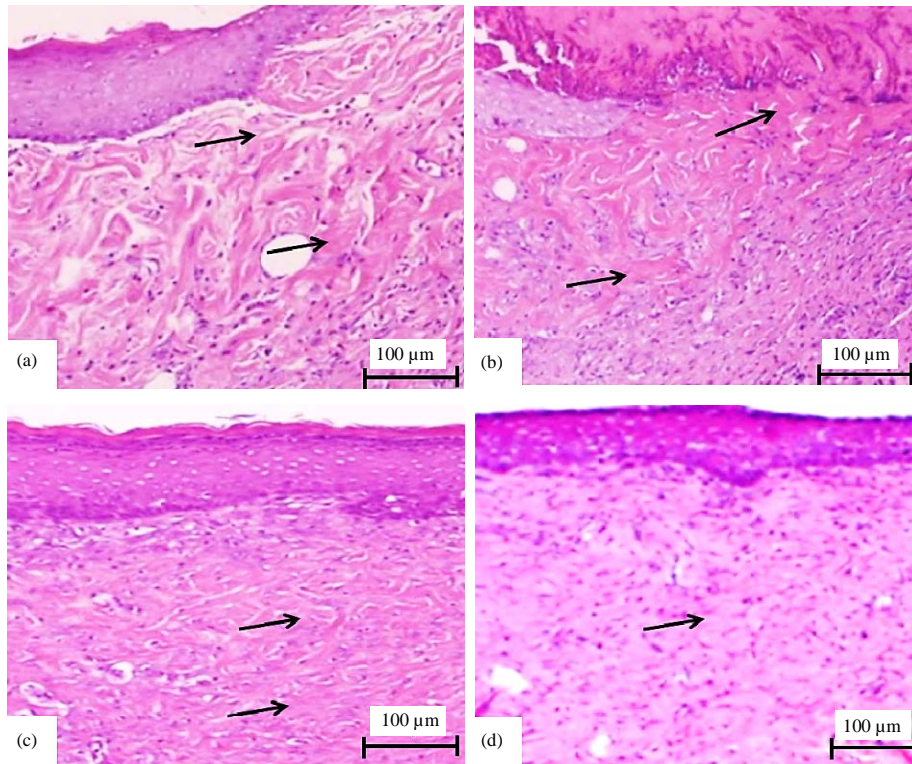


Fig. 1(a-d): Effect of ALA on the scar tissue section stained with H and E (magnification 100×) in experimental animals, (a) The HTS induced wound rabbit section, showed elevated neutrophil infiltration with an irregular arrangement of collagen fibers (arrow mark) and higher numbers of scattered fibroblasts (spindle shape), (b) 5% ALA, treated scar section showed lesser neutrophil infiltrations with slightly irregular collagen fibers and higher numbers of fibroblasts, (c) Treatment with 10% of ALA showed much lesser neutrophil infiltrations with few irregular collagen fibers and moderate regular collagen fibers and moderate numbers of fibroblasts and (d) Topical application of 20% ALA portrait minimal neutrophil infiltrations, with regularly arranged collagen fibers and minimum numbers of fibroblast

with 10% of ALA (Fig.1c) showed much lesser micro-vessels and neutrophil infiltrations with few irregular collagen fibers and moderate regular collagen fibers pattern with moderate numbers of fibroblasts. Topical application of 20% ALA (Fig.1d) portrait minimal micro-vessels and neutrophil infiltrations, with regularly arranged collagen fibers with minimal numbers of fibroblast and thus, illustrating its anti-scarring effect with decreased length of the scar.

**Effect of ALA on scar elevation index:** The effect of ALA on the levels of scar elevation index (SEI) in experimental animals were illustrated in Fig. 2. The levels of SEI in HTS induced rabbit ( $3.10 \pm 0.5$ ) were higher than other experimental groups. Administration of ALA 5% ( $2.60 \pm 0.3$ ,  $p < 0.05$ ), 10% ( $2.20 \pm 0.4$ ,  $p < 0.01$ ) and 20% ( $2.00 \pm 0.3$ ,  $p < 0.001$ ) could substantially decrease the levels of SEI than HTS induced rabbit.

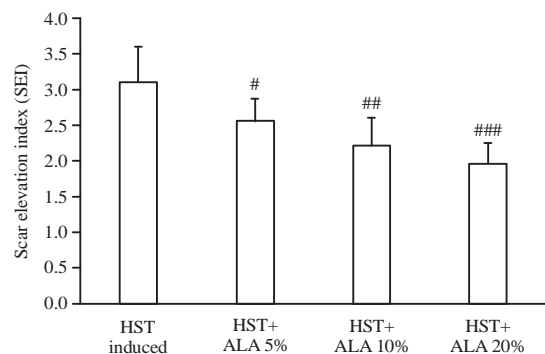


Fig. 2: Effect of ALA on the levels of scar elevation index (SEI) in experimental animals. Data are expressed as the mean  $\pm$  standard deviation (SD). ### $p < 0.001$ , ## $p < 0.01$ , # $p < 0.05$  show comparison between HST vs ALA group (5, 10 and 20%)

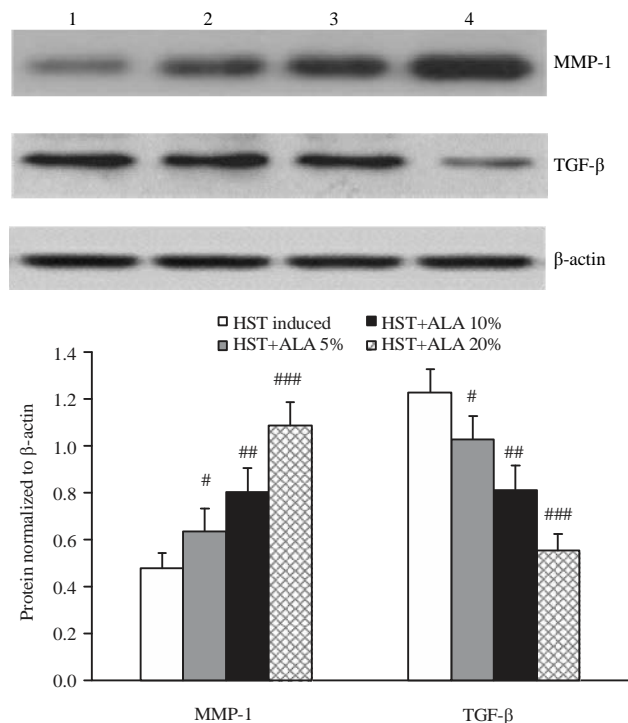


Fig. 3: Effect of ALA on the protein expression of MMP-1 and TGF-β in the scar tissue homogenate of experimental animals. Data are expressed as the mean ± standard deviation (SD). ###p<0.001, ##p<0.01, #p<0.05 show comparison between HST vs ALA group (5, 10 and 20%)

**Effect of ALA on the protein expressions of MMP-1 and**

**TGF-β:** Figure 3 represents the effect of ALA on the protein expression of MMP-1 and TGF-β in the scar tissue homogenate of experimental animals. The protein expressions of MMP-1 and TGF-β were markedly up regulated or down regulated, respectively upon treatment with ALA in a dose-dependent manner in comparison with HTS induced group. Overall, ALA 20% treatment could show better anti-scarring effect by lowering collagen, GAGs contents, SEI and protein expression of TGF-β with increased expression of MMP-1 than other groups of ALA (5 or 10%).

**DISCUSSION**

Hypertrophic scar (HTS) is a fibroproliferative disorder which develops due to burn, skin infection/injury, laceration, bites or by surgery owing to uncontrolled synthesis (proliferation) and deposition of fibroblast-derived extracellular matrix protein, especially collagen and GAGs<sup>1</sup>. HTS is a displeasing as it causes patients with both physical and physiological distress and hence must be treated as quick as possible. Therefore, the present study was undertaken to assess the effect of ALA on hypertrophic scarring rabbit ear model by checking the collagen levels (deposition),

glycosaminoglycans, scar elevation index (SEI), protein expression of TGF-β and MMP-1 as well as histological changes. The outcome of this study showed that 20% ALA treatment could exhibit better anti-scarring effect by lowering collagen, GAGs contents, SEI and protein expression of TGF-β with increased expression of MMP-1 than other groups of ALA doses.

Collagen and glycosaminoglycans (GAGs) are the crucial component of extracellular matrix (ECM), which is secreted by fibroblasts and play a pivotal role in wound healing<sup>21</sup>. However, dysfunction or alteration in the contents of collagen or GAGs for a long period with persistence inflammation may contribute to hypertrophic scarring<sup>1,22</sup>. During, late phase of wound healing the production of collagen type III is more than collagen type I<sup>23</sup>, even researchers study showed similar results that type III was higher than collagen type I in all groups. Topical application of ALA for 21 days significantly reduced the contents of both type of collagens (I and III) as well as GAGs (hydroxyproline and hexosamine) in dose concentration fashion. Thus, indicating that 20% of ALA has a high potential for anti-scarring activity than other doses of ALA.

To assess the scarring pattern, it was checked the histological alterations in rabbit scar tissue of HTS induced and

ALA-treated experimental rabbits using a light microscope. The HTS induced wound model rabbit section showed prominent micro-vessels with elevated neutrophil infiltration as well as showed an irregular arrangement of collagen fibers with higher numbers of scattered fibroblasts and myoblasts. Similar kind of histological changes was shown by Huang *et al.*<sup>24</sup>, who also highlighted that HTS induced rabbit showed irregular collagen fibers with rich micro-vessel and infiltration in hyper scarring rabbit ear model. Meanwhile, 5% ALA-treated scar section showed lesser micro-vessels and neutrophil infiltrations with slightly irregular collagen fibers with high numbers of fibroblast. Whereas, treatment with 10% ALA showed much lesser micro-vessels and neutrophil infiltrations with few irregular collagen fibers and moderate regular collagen fibers pattern with moderate numbers of fibroblasts. Topical application of 20% ALA portrait minimal micro-vessels and neutrophil infiltrations, with regularly arranged collagen fibers with minimal numbers of fibroblast. Thus, illustrating its anti-scarring effect owing to antioxidant and anti-inflammatory properties<sup>10</sup>.

The levels of scar elevation index (SEI) in HTS induced animals were greater than the other experimental animals. Present study results are incongruent with the results of Ju-Lin *et al.*<sup>25</sup>. However, topical application of ALA for 21 days has considerably attenuated the levels of SEI than HTS induced rabbit. Similar, to other parameters, ALA 20% showed least SEI value and thus endorsing its anti-scarring activity.

Matix metalloproteinases (MMPs) are zinc-dependent proteinases, which plays a crucial role in the tissue remodeling process. MMP-1 (collagenase) is one of the major proteolytic enzyme involved in breakdown or degradation of various collagen types especially type I and III in HTS condition<sup>23</sup>. Numerous studies have demonstrated that MMP-1 activity was markedly reduced during HTS condition and hence any pharmaceutical agent with MMP-1 upregulating activity might exert anti-scarring activity<sup>26,27</sup>. Hence, to explore the involvement of MMP-1 protein expressions are evaluated by immunoblot technique. The protein expressions of MMP-1 was notably upregulated upon treatment with ALA (5, 10 or 20%) in a dose-dependent manner. Also, oleanolic acid treatment could markedly upregulate the expression of MMP-1 in hypertrophic scarring rabbit ear model<sup>23</sup>.

Transforming growth factor beta (TGF- $\beta$ ), is a secreted protein which exists in three isoforms as TGF- $\beta$ 1, TGF- $\beta$ 2 and TGF- $\beta$ 3 and plays a different role in different pathological conditions<sup>28</sup>. However, TGF- $\beta$ 1 plays a central role in the initiation of burn-induced HTS via up regulating Smad

signaling pathway<sup>29</sup> and hence for the current study the protein expression of TGF- $\beta$ 1 were quantified to assess the anti-scarring activity of ALA. The protein expressions of TGF- $\beta$ 1 were significantly down regulated after 21 days of topical application of a different dose of ALA. Likewise, Zhang *et al.*<sup>30</sup>, demonstrated that treatment with oleanolic acid could effectively down regulate the protein expression of TGF- $\beta$ 1 and thus showcase its anti-scarring effect. This study has few limitation such as avoidance of apoptotic markers, inflammatory markers and Smad signaling pathway to reveal the in-depth mechanism for the anti-scarring effect.

## CONCLUSION

It is concluded that the topical application of ALA could drastically lower the scarring area after a thermal wound in a dose-dependent manner by suppressing collagen and GAGs contents, SEI and protein expression of TGF- $\beta$ 1 with increased protein expression of MMP-1. Therefore, ALA can be recommended for treating various injury scar especially post-burn hypertrophic scar with standard anti-scarring agents. However, further studies are required to confirm the in-depth mechanism behind the anti-scarring activity.

## SIGNIFICANCE STATEMENT

This animal study reveals the uncovered anti-scarring effect of lipoic acid by abolishing collagen and GAGs contents. Therefore, it contributes to the discovery of novel anti-scarring agent (ALA) with a combination of other standard anti-scarring drug which can improve the quality of life in thermal injured patients by lowering the scar marks.

## ACKNOWLEDGMENT

This study was financially aided by Yangtze University, Hubei, China (YU-2016/17).

## REFERENCES

1. Keorochana, K., P. Chaiyasuk and P. Muangman, 2015. Prospective randomize-controlled comparison between silicone plus herbal extract gel versus Aloe vera gel for burn scar prophylaxis. *Wound Med.*, 9: 1-4.
2. Bombaro, K.M., L.H. Engrav, G.J. Carrougher, S.A. Wiechman and L. Faucher *et al.*, 2003. What is the prevalence of hypertrophic scarring following burns? *Burns*, 29: 299-302.



3. Bloemen, M. C., W.M. van der Veer, M.M. Ulrich, P.P. van Zuijlen, F.B. Niessen and E. Middelkoop, 2009. Prevention and curative management of hypertrophic scar formation. *Burns*, 35: 463-475.
4. Alster, T.S. and E.L. Tanzi, 2003. Hypertrophic scars and keloids. *Am. J. Clin. Dermatol.*, 4: 235-243.
5. Bilska-Wilkosz, A., M. Iciek, D. Kowalczyk-Pachel, M. Gorny, M. Sokolowska-Jezewicz and L. Wlodek, 2017. Lipoic acid as a possible pharmacological source of hydrogen sulfide/sulfane sulfur. *Molecules*, Vol. 22. 10.3390/molecules22030388.
6. Packer, L., E.H. Witt and H.J. Tritschler, 1995. Alpha-lipoic acid as a biological antioxidant. *Free Radic. Biol. Med.*, 19: 227-250.
7. Koufaki, M., 2014. Therapeutic applications of lipoic acid: A patent review (2011-2014). *Expert Opin. Therapeut. Patents*, 24: 993-1005.
8. Shi, C., Y. Sun, X. Zhang, Z. Zheng and M. Yang *et al.*, 2016. Antimicrobial effect of lipoic acid against *Cronobacter sakazakii*. *Food Control*, 59: 352-358.
9. Rochette, L., S. Ghibu, A. Muresan and C. Vergely, 2015. Alpha-lipoic acid: Molecular mechanisms and therapeutic potential in diabetes. *Can. J. Physiol. Pharmacol.*, 93: 1021-1027.
10. Toklu, H.Z., T. Hakan, N. Biber, S. Solakoglu, A.Z.V. Ogunc and G. Sener, 2009. The protective effect of alpha lipoic acid against traumatic brain injury in rats. *Free Radical Res.*, 43: 658-667.
11. Zhao, H., X. Zhao, L. Liu, H. Zhang and M. Xuan *et al.*, 2017. Neurochemical effects of the R form of  $\alpha$ -lipoic acid and its neuroprotective mechanism in cellular models of Parkinson's disease. *Int. J. Biochem. Cell Biol.*, 87: 86-94.
12. Winiarska, K., D. Malinska, K. Szymanski, M. Dudziak and J. Bryla, 2008. Lipoic acid ameliorates oxidative stress and renal injury in alloxan diabetic rabbits. *Biochimie*, 90: 450-459.
13. Deng, C., Z. Sun, G. Tong, W. Yi and L. Ma *et al.*, 2013.  $\alpha$ -Lipoic acid reduces infarct size and preserves cardiac function in rat myocardial ischemia/reperfusion injury through activation of PI3K/Akt/Nrf2 pathway. *Plos One*, Vol. 8. 10.1371/journal.pone.0058371.
14. Kulkamp-Guerreiro, I.C., M.N. Souza, M.D. Bianchin, M. Isoppo and J.S. Freitas *et al.*, 2013. Evaluation of lipoic acid topical application on rats skin wound healing. *Acta Cirurgica Brasil.*, 28: 708-715.
15. El Komy, M., S. Shalaby, R. Hegazy, R. Abdel Hay, S. Sherif and E. Bendas, 2017. Assessment of cubosomal alpha lipoic acid gel efficacy for the aging face: A single blinded, placebo controlled, right left comparative clinical study. *J. Cosmetic Dermatol.*, 16: 358-363.
16. Krismi, A., S.R. Pudjiati and Y.W. Wirohadidjojo, 2011.  $\alpha$ -Lipoic acid inhibit the decrease of collagen deposition in ultraviolet B-irradiated cultured normal human skin fibroblasts cell culture. *J. Med. Sci.*, 43: 94-98.
17. Kryger, Z.B., M. Sisco, N.K. Roy, L. Lu, D. Rosenberg and T.A. Mustoe, 2007. Temporal expression of the transforming growth factor-Beta pathway in the rabbit ear model of wound healing and scarring. *J. Am. College Surgeons*, 205: 78-88.
18. Woessner, Jr., J.F., 1961. The determination of hydroxyproline in tissue and protein samples containing small proportions of this imino acid. *Arch. Biochem. Biophys.*, 93: 440-447.
19. Wagner, W.D., 1979. A more sensitive assay discriminating galactosamine and glucosamine in mixture. *Anal. Biochem.*, 94: 394-396.
20. Kloeters, O., A. Tandara and T.A. Mustoe, 2007. Hypertrophic scar model in the rabbit ear: A reproducible model for studying scar tissue behavior with new observations on silicone gel sheeting for scar reduction. *Wound Repair Regener.*, 15: S40-S45.
21. Olczyk, P., L. Mencner and K. Komosinska-Vassev, 2014. The role of the extracellular matrix components in cutaneous wound healing. *BioMed Res. Int.*, 10.1155/2014/747584.
22. Mehta, M., O.A. Branford and K.J. Rolfe, 2016. The evidence for natural therapeutics as potential anti-scarring agents in burn-related scarring. *Burns Trauma*, Vol. 4. 10.1186/s41038-016-0040-1.
23. Wei, Y.J., X.Q. Yan, L. Ma, J.G. Wu, H. Zhang and L.P. Qin, 2011. Oleanolic acid inhibits hypertrophic scarring in the rabbit ear model. *Clin. Exp. Dermatol.*, 36: 528-533.
24. Huang, L.P., G.Q. Wang, Z.S. J ia, J.W. Chen, G. Wang and X.L. Wang, 2015. Paclitaxel reduces formation of hypertrophic scars in the rabbit ear model. *Therapeut. Clin. Risk Manage.*, 11: 1089-1095.
25. Ju Lin, X., Q. Shao Hai, L. T ian Zeng, H. Bin and T. Jing Ming *et al.*, 2009. Effect of asiaticoside on hypertrophic scar in the rabbit ear model. *J. Cutaneous Pathol.*, 36: 234-239.
26. Eto, H., H. Suga, N. Aoi, H. Kato and K. Doi *et al.*, 2012. Therapeutic potential of fibroblast growth factor-2 for hypertrophic scars: upregulation of MMP-1 and HGF expression. *Lab. Invest.*, 92: 214-223.
27. Xie, J.L., H.N. Bian, S.H. Qi, H.D. Chen and H.D. Li *et al.*, 2008. Basic fibroblast growth factor (bFGF) alleviates the scar of the rabbit ear model in wound healing. *Wound Repair Regener.*, 16: 576-581.
28. Yu, H., S. Zitron, A. Bayat, M.W. Ferguson and U. Mrowietz, 2005. Studies of transforming growth factors beta 1-3 and their receptors I and II in fibroblast of keloids and hypertrophic scars. *Acta Dermato-Venereol.*, 85: 216-220.
29. Zhu, Z., J. Ding, H.A. Shankowsky and E.E. Tredget, 2013. The molecular mechanism of hypertrophic scar. *J. Cell Commun. Signal.*, 7: 239-252.
30. Zhang, H., Y. Zhang, Y.P. Jiang, L.K. Zhang and C. Peng *et al.*, 2012. Curative effects of oleanolic acid on formed hypertrophic scars in the rabbit ear model. *Evidence-Based Complement. Alternat. Med.*, 10.1155/2012/837581.