Journal of Medical Sciences

ISSN 1682-4474

science alert

ANSInet
an open access publisher
http://ansinet.com

Review Article

J. Med. Sci., 15 (3): 110-121
1st April, 2015
DOI: 10.3923/jms.2015.110.121

A Review of Computer-Aided Detection and Diagnosis of Breast Cancer in Digital Mammography

Luqman Mahmood Mina and Nor Ashidi Mat Isa

Mammography is the most valuable existing examination tool for the detection of early signs of breast cancer such as masses, calcifications, bilateral asymmetry and architectural distortion. Mammographic screening has been shown to be effective in reducing breast cancer mortality rates by 30-70%, as confirmed from available screening programs. However, mammograms are difficult to interpret, especially in the screening of physical aberrations. Studies have shown that the sensitivity of screening mammography is influenced by image quality and the radiologist's level of proficiency. Over the years, computers have played a significant role in detecting early signs of cancer because of the limitations of human observation, hence a lot of research is presently being embarked on to develop Computer Aided Detection systems (CAD) of high accuracy. This paper presents a concise review of some of the advanced computer-aided detection and diagnosis methods currently being utilized to improve the intrinsic aspects of CAD, which include: contrast enhancement, detection and analysis of calcifications, masses and tumors, analysis of bilateral asymmetry and detection of architectural distortion.

Key words: Breast cancer, computer-aided diagnosis, mammography, calcifications, architectural distortion, enhancement, segmentation, feature extraction

JMS (ISSN 1682-4474) is an International, peer-reviewed scientific journal that publishes original article in experimental & clinical medicine and related disciplines such as molecular biology, biochemistry, genetics, biophysics, bio-and medical technology. JMS is issued eight times per year on paper and in electronic format.

For further information about this article or if you need reprints, please contact:

Luqman Mahmood Mina
School of Electrical and Electronic Engineering, Engineering Campus, University Sains Malaysia, Nibong Tebal, Penang, 14300, Malaysia

Tel: +6045996051
Fax: +6045941023

ANSInet
Asian Network for Scientific Information

School of Electrical and Electronic Engineering, Engineering Campus, University Sains Malaysia, Nibong Tebal, Penang, 14300, Malaysia

INTRODUCTION

Mammography is presently the best existing tool for detecting symptoms of breast cancer early on. It is also capable of revealing obvious distinctive physical aberrations, such as masses and calcifications, as well as subtle signs such as bilateral asymmetry and architectural distortion (Rangayyan *et al*., 2007). The prompt detection of breast cancer is of paramount significance since early detection of benign cancer leads to a 5 years survival rate of 97.5%, whereas malignant cancer has a 5 years survival rate of only 20.4% (Jemal *et al*., 2004). Mammography is an exceptional type of X-ray imaging that provides detailed visual images of the breast using intrinsic advanced features such as low dose X-ray, high contrast, high-resolution film and an X-ray system designed purposely for imaging the breasts (Helms *et al*., 2008). Bird *et al*. (1992) demonstrated that the sensitivity of screening mammography to breast cancer detection ranges from 85-90%. Breast self-examination insufficient as indicated by several researches that have proved there is no apparent reduction in the mortality rate attributable to regular breast self-examination (Hackshaw and Paul, 2003).

The wrong elucidation of breast cancer signs has been shown to account for 52% of the detection errors, while neglecting early signs and symptoms is responsible for 43% of the undetected abnormalities. Van Dijck *et al*. (1993) discovered minimal signs of abnormalities in screening mammograms obtained previously in several cases of screen detected cancers. Sickles (1986a) reported that generally overlooked signs of malignancy (such as architectural distortion, bilateral asymmetry, single dilated duct and developing densities) accounted for almost 20% of the detected cancers. In a study of cases of screening interval breast cancer, Burrell *et al*. (1996) observed that architectural distortion was the most frequently unnoticed abnormality in false-negative cases.

With the recent development in X-ray mammography using digital mammography, the breast image can now be captured using a special electronic X-ray detector, which transforms the image into a digital picture for evaluation on a computer screen. The digital mammogram is then stored on a computer. The modification of intrinsic features of digital mammography, such as the magnification, orientation, brightness and image contrast after the evaluation is completed allows the radiologist to clearly visualize specific and intricate areas (Helms *et al*., 2008). Digital mammography has the potential to provide a number of benefits compared to the conventional film mammography and they include: quicker image acquisition, shorter duration of examination, improved image storage, simple transmission of images to other physicians and enhanced computer processing of breast images for better precision of breast cancer detection (Helms *et al*., 2008).

COMPUTER-AIDED DETECTION AND DIAGNOSIS (CAD)

Computer-Aided Detection (CAD) is a technique that combines diagnostic imaging with computer science, image processing, pattern recognition and artificial intelligence technologies (Rangayyan *et al*., 2007). It is a diagnostic tool (Giger, 2000) developed in radiology to utilize the output of computerized analysis of medical images as a secondary opinion in the detection of lesions and making diagnostic assessments. In recent times, CAD systems have garnered several interests from both research scientists and radiologists because of the related complex research subjects and prospective clinical applications. The incorporation of computer processing in biomedical image analyses provides a more precise diagnosis since humans are prone to making errors and their analysis is generally biased and qualitative rather than quantitative. Improved biomedical image analysis using CAD leads to a more accurate diagnostic decision by the physician (Rangayyan and Ferrari, 2004).

Freer and Ulissey (2001) studied the potential impact of CAD in screening, where 12,860 screening mammograms were analysed with the aid of a CAD system over a 12 months duration. It was noted that cancer detection generally increased by 19.5% and the rate of early-stage detection of malignant cancer tissue increased from 73-78%. The recall rate increased from 6.5-7.7% and the positive-predictive value of biopsy remained constant at 38%. The study concluded that CAD can enhance the detection of early-stage malignancies devoid of any markedly negative effect on the recall rate or the positive-predictive value of biopsy. Ciatto *et al*. (2003) carried out a comparative analysis between conventional mammogram reading and CAD reading based on a national proficiency test of screening mammography in Italy. The authors deduced that the performance of single reading with CAD is equivalent to double conventional mammogram reading.

Evans *et al*. (2002) examined the ability of a commercial CAD system to detect invasive and persistent lobular carcinoma of the breast. The system was found to be capable of detect accurately 17 of 20 cases of architectural distortion. Also, Burhenne *et al*. (2000) analysed the aptness of a commercial CAD system in the detection of masses and calcifications in screening mammography. The study attained a sensitivity of 75% in the detection of masses and architectural distortion, at the rate of one false positive per image. Furthermore, Birdwell *et al*. (2001) assessed the capability of a commercial CAD system in identifying benign cancer tissues that were unnoticed by radiologists. The results showed that the software was able to detect five out of six cases of architectural distortion and 77% of the formerly unobserved lesions, at the rate of 2.9 false positives per image.

Broeders *et al*. (2003) suggested that modifications in the detection process of architectural distortion can produce an

efficient upgrade in the diagnosis of breast cancer. In contrast, Baker *et al*. (2003) put forward that the sensitivity of two commercial CAD systems was limited in the detection of architectural distortion, effective in less than 50% of the 45 cases of architectural distortion presented (with a lesser image-based sensitivity of 38% or 30 out of 80 images, at a rate of 0.7 false positive per image).

A concise summary of the results obtained in the above mentioned studies is detailed in Table 1. The inconsistency in the results signifies the need for additional studies in this area, as well as the development of algorithms designed explicitly to characterize architectural distortion. Thus, the rest of this paper entails a review of several image analysis components of CAD systems, advancements in CAD development and directions for future research.

TECHNIQUES FOR CAD OF BREAST CANCER

There have been recent advancements in development of CAD for improved breast cancer detection (Peitgen, 2003: Pisano *et al*., 2004), largely in relation to the detection of subtle aberrations in mammograms, particularly in the recognition of masses and calcifications. Nonetheless, certain areas of research in CAD of breast cancer still require attention. Most of the published studies focused on a more general area of abnormalities, such as spiculated lesions, which encompasses some of the possible appearances of architectural distortion. Other areas of research that demand increased interest include the analysis of bilateral asymmetry, curvilinear structures (CLS) and breast density as a predictive indicator of breast cancer. In a larger framework, areas of interest related to CAD of breast cancer include the creation of systems for content-based retrieval of mammograms, indexed atlases and data-mining systems. Full-field digital mammography systems, though still under assessment, could aid the regular application of the aforementioned techniques.

Image enhancement: The enhancement of mammographic images could improve the precision of breast cancer detection early on (Rangayyan, 2004; Morrow *et al*., 1992). Analytical contrasting features in mammograms, masses and calcifications, may be indiscernible and have low disparity with regards to the neighboring breast tissues, which could render the diagnostic features unidentifiable. Therefore, contrast enhancement techniques can improve the ability of a radiologist to recognize subtle diagnostic features, resulting in early and more precise diagnosis of breast cancer. Contrast enhancement can also improve the quality of an unsatisfactory mammogram, as shown in a study by Ram (1982), who suggested that the use of contrast enhancement techniques in a clinical setting may decrease the radiation dose by approximately 50%.

Conventional image enhancement techniques have been used in radiography for more than 30 years. Chan *et al*. (1987) examined the relevance of unsharp masking for digital mammography. Receiver Operating Characteristics (ROC) studies were performed to confirm the positive impact of unsharp masking technique on the detectability of calcifications in digital mammograms. However, the method is limited by elevated noise which causes some artifacts in the images. Traditional image enhancement techniques have been shown to be more effective for global transformations, rather than adapt to localized information content and features in an image. Thus, these classical techniques often perform defectively in improving specific sections of a mammogram, due to the considerable variations in the size and shape of diagnostic features in mammograms. Therefore, it is crucial to develop adaptive contrast enhancement algorithms for mammographic images, where the transformation is modified to be effective for analyzing the local content of a given image. Based on this, Laine *et al*. (1994) developed a method for nonlinear contrast enhancement derived from multi-resolution representation and the use of dyadic wavelets.

Furthermore, Morrow *et al*. (1992) developed a novel technique comprising of a new definition of background regions and is referred to as the Adaptive Neighborhood Contrast Enhancement (ANCE) algorithm. The ANCE works

Table 1: Summary of the results obtained in related studies

Authors	Size of dataset	Summary of results
Freer and Ulissey (2001)	12,860 screening mammograms	Increase in cancer detection by 19.5%, increase in proportion of early-stage malignant cancer detection from 73-78%, recall rate increased from 6.5-7.7%, positive-predictive value of biopsy remained unchanged at 38%
Ciatto *et al*. (2003)	89 negative screening mammograms, plus 31reported as negative and developing interval cancer in the following two-year interval (11 false negatives, 20 showing minimal signs), 19 radiologists	Double conventional mammogram reading: sensitivity of 46.1% and recall rate of 26.1%. CAD reading: sensitivity of 42.1% and recall rate of 23.9%
Evans *et al*. (2002)	90 mammograms (94 invasive lobular carcinoma lesions)	CAD detected 86 out of 94 lesions (sensitivity of 91%), detected 17 of 20 cases of architectural distortion (sensitivity of 85%)
Birdwell *et al*. (2001)	110 cases of screen-detected cancers, where the prior mammograms were available, and where a panel of radiologists recommended a recall, on retrospective analysis	CAD marked 77% of the missed lesions, at 2.9 false positives per image
Baker *et al*. (2003)	43 cases, 45 detected regions of architectural distortion	Fewer than 50% of the 45 cases of architectural distortion were detected, image-based sensitivity of 38%, or 30 out of 80 images, at 0.7 false positive per image

as follows: Each pixel in the digitized mammographic image is taken as the seed pixel in a region growing procedure. The region growing procedure recognizes the set of pixels that are related and linked to the foreground and the background regions. In another study, Dhawan *et al*. (1986) proposed the integration of an amenable contrast function into enhancement algorithms in order to effectively discern features such as microcalcifications in an image, thereby limiting their negative effects on breast cancer diagnosis. Other image enhancement techniques may improve the visibility of diagnostic features but eventually distort the final appearance and shape qualities, probably resulting in wrong diagnosis (Kimme-Smith *et al*., 1989).

Several image enhancement techniques of mammograms may lead to increase in noise or distortion of the breast anatomy in the image. Radiologists would rather choose to have the enhanced image retain the original appearance of the mammogram, which may constrain the extent of enhancement techniques. However, with the introduction of innovative techniques like the direct digital imaging systems which utilizes intrinsic features such as increased contrast, dynamic range and reduced Signal-to-Noise Ratio (SNR), the need to continually enhance an image may no longer be required.

Segmentation of mammograms and analysis of breast density: It has been shown in several studies that enlarged breast density is linked with a higher chance of cancer occurrence (Ursin *et al*., 2005). Many researchers have examined computer methods for estimating the risk of breast cancer development using automated analysis of breast density. Byng *et al*. (1996) computed the skewness of histograms of 24×24 (3.12×3.12 mm) sections of mammograms. A mean skewness was computed for each image by measuring the overall average of the section-based skewness of the image. Mammograms of breasts with increased fibro glandular density were observed to have histograms skewed toward higher density, resulting in negative skewness. Furthermore, the study found that mammograms of fatty breasts were predisposed to have positive skewness. The fractal dimension of the breast image was also computed by interpreting the image as a relief map. The fractal dimension was then computed using the box-counting method. The skewness and the fractal dimension measures were found to be valuable in forecasting the possibility of breast cancer development.

In other studies, Karssemeijer (1998) utilized the Hough transform to delineate the pectoral muscle as a straight-line edge in the mammogram. Ferrari *et al*. (2004a) put forward two methods for identifying the pectoral muscle in mammograms. The first method is an alternate Karssemeijer's method, which applies the Hough transform and filtering to the accumulator cells. However, the theory of using a straight line to depict the pectoral muscle is not always applicable and may impose restrictions on successive stages of image analysis. The disadvantages of the first method are accounted for in the proposed second method (Ferrari *et al*., 2004b), which is based upon directional filtering using Gabor wavelets. Several other studies have theorized techniques for the delineation of the breast boundary (Sun *et al*., 2006). Ferrari *et al*. (2004c) also developed a method for the recognition of the breast boundary using active contour models. This method consists of successive mammogram enhancement processes that include; contrast-enhancement and thresholding to create an initial chain-code representation of the breast boundary until a final boundary is acquired through the application of a specifically modified active contour model algorithm. The method was tested in 84 MLO mammograms obtained from the Mini-MIAS database. An assessment of the breast contours developed with this method was executed based on a comparative analysis between the percentage of false-positive and false-negative pixels of the new model and the contours that were manually produced by a radiologist. The average false-positive and false-negative rates were 0.41 and 0.58%, respectively.

Ferrari *et al*. (2004a) also segmented the fibroglandular disk in mammograms using the Gaussian mixture model. Initially the breast boundary and the pectoral muscle were identified using other methods developed for the study (Ferrari *et al*., 2004b). Afterward, the fibroglandular disk was detected by delineating a breast density model. The parameters of the model were computed using the expectation-maximization algorithm and the minimum description length principle. A qualitative evaluation of the segmentation results was then carried out by an experienced radiologist. The 64.3% of the results were rated as excellent, 16.7% rated as good, 10.7% rated as average, 4.7% rated as poor and only 3.6% of the results as unsuccessful segmentation.

Detection and classification of microcalcifications: Calcifications in mammograms emerge as relatively bright regions compared to surrounding tissue because of the higher X-ray attenuation coefficient (or density) of calcium in contrast to normal breast tissue. Calcifications present within dense masses or overlain by dense tissues in the process of mammograms acquisition could exhibit low gray-level disparity or contrast relative to their local background. Conversely, calcifications present adjacent to a background of fat or low-density tissue would exhibit higher differences and contrast. Malignant calcifications are likely to be many, clustered, minute with irregular sizes and shapes, angular, unevenly shaped and branching in orientation (Feig *et al*., 1987; Sickles, 1986b). In contrast, calcifications related to benign diseases are usually bigger, more rounded, less numerous, more randomly dispersed and more uniform in size and shape.

Shen *et al*. (1994) developed a technique for the detection and classification of mammographic calcifications. The

technique begins with an initial phase of creating a multi-tolerance region for the recognition of possible calcification, followed by the extraction of contours representing the potential region. Other extracted features include shape elements based on central moments, Fourier descriptors and compactness. Finally, a neural network is used for the classification of the feature vectors in order to differentiate between malignant and benign calcifications. Accurate classification rates obtained for the benign and malignant calcifications were 94 and 87%, respectively. Investigation of shape features and a more detailed classification of calcifications for a database containing 143 biopsy-proven calcifications (79 malignant and 64 benign) were carried out by contemporary studies (Strickland and Hahn, 1996). Results showed classification accuracy of 100% for both benign and malignant calcifications.

Strickland and Hahn (1996) created a two-stage method based on wavelet transforms for the detection and segmentation of microcalcifications. In this method, the detection of calcifications is performed in the wavelet domain. The detected sites are enhanced in the wavelet domain, prior to the computation of the inverse wavelet transform. The appearance of microcalcifications is enhanced by this procedure; a threshold procedure suffices to segment the calcifications. The test database consisted of 40 mammograms and a sensitivity of 91% at three false positives per image was obtained. Yu *et al*. (2006) used a wavelet filter for the detection of microcalcifications and a Markov random field model to obtain textural features from the neighborhood of every detected calcification. The Markov-random-field-based textural features, along with three auxiliary textural features (the mean pixel value, the gray-level variance and a measure of edge density), were used to reject false positives. The method was evaluated using 20 mammograms containing 25 areas of clustered microcalcifications. A sensitivity of 92% was obtained, at 0.75 false positive per image. Yu and Guan (2000) developed a technique for the detection of clustered microcalcifications that is comprised of two parts: detection of potential microcalcification pixels and delineation of individual microcalcifications by the elimination of false positives. The first part involves the extraction of features based on wavelet decomposition and gray-level statistics, followed by a neural-network classifier. The detection of individual objects requires a vector of 31 features related to gray-level statistics and shape factors, followed by a second neural-network classifier. A database of 40 mammograms containing 105 clusters of calcifications was used to assess the performance of the proposed algorithm: a sensitivity of 90% was attained with 0.5 false positive per image.

Serrano *et al*. (2001) and Acha *et al.* (2006) developed a novel technique for delineating calcifications, taking into consideration the errors associated with 2D adaptive linear prediction algorithm (46). The validity of the method relies on the fact that a microcalcification can be observed as a point of nonstationarity or inertness in a generally homogeneous region or neighborhood in a mammogram, since such a pixel cannot be well predicted using the linear predictor, thereby reducing inherent errors. The algorithm identifies and confines calcifications and afterwards a multi-tolerance region growing algorithm (Shen *et al*., 1993) is used to define each calcification.

A review of the statistical performance of selected CAD methods for the detection and classification of calcifications is shown in Table 2. Based on the high levels of sensitivity in the detection of calcifications that have been attained at low rates of false positives, this problem could be regarded as satisfactorily solved.

Analysis of bilateral asymmetry: Bilateral asymmetry is a diagnostic tool used by radiologists to detect the presence of breast cancer, where there is disparity between the left and right breasts in overall appearance as observed from mammographic images. Several methods have been utilized and proposed to achieve accurate asymmetry detection. Miller and Astley (1993) proposed a technique that comprised a semi-automated texture-based procedure for the segmentation of the glandular tissue and shape measurements and registration cost between views for detection of the presence of asymmetry. An accuracy of 86.7% was reported for the technique based on a dataset of 30 screening mammogram pairs. Similarly, Miller and Astley (1994) reported a method based on measurements of shape, topology and distribution of brightness in the fibroglandular disk. The method was tested on 104 mammogram pairs and a classification accuracy of 74% was attained. Lau and Bischof (1991) also developed a method that involves computing brightness, roughness and directionality. The assessment of the method using 10 pairs of mammograms showed a sensitivity of 92% along with 4.9 false positives per mammogram.

Ferrari *et al*. (2001) developed a method to analyze the asymmetry in mammograms using directional filtering with Gabor wavelets. In the method, the fibroglandular disk is

Table 2: Summary of selected CAD methods for the detection and classification of calcifications

Authors	Size of dataset	Summary of results
Shen *et al*. (1993)	Four images, 58 benign calcifications, 241 malignant calcifications	Correctly classified 94% of the benign calcifications and 97% of the malignant calcifications
Strickland and Hahn (1996)	40 mammograms	Sensitivity of 91% at three false positives per image
Yu *et al*. (2006)	20 mammograms containing 25 areas of clusters microcalcification	Sensitivity of 92% at 0.75 false positive per image
Yu and Guan (2000)	40 mammograms, 105 clusters of microcalcifications	Detection rate of 90% with 0.5 false positive per image. Note: 20 training samples were also used in the testing step
Serrano *et al*. (2001)	428 microcalcifications	86% detection of microcalcifications, with eight false detections

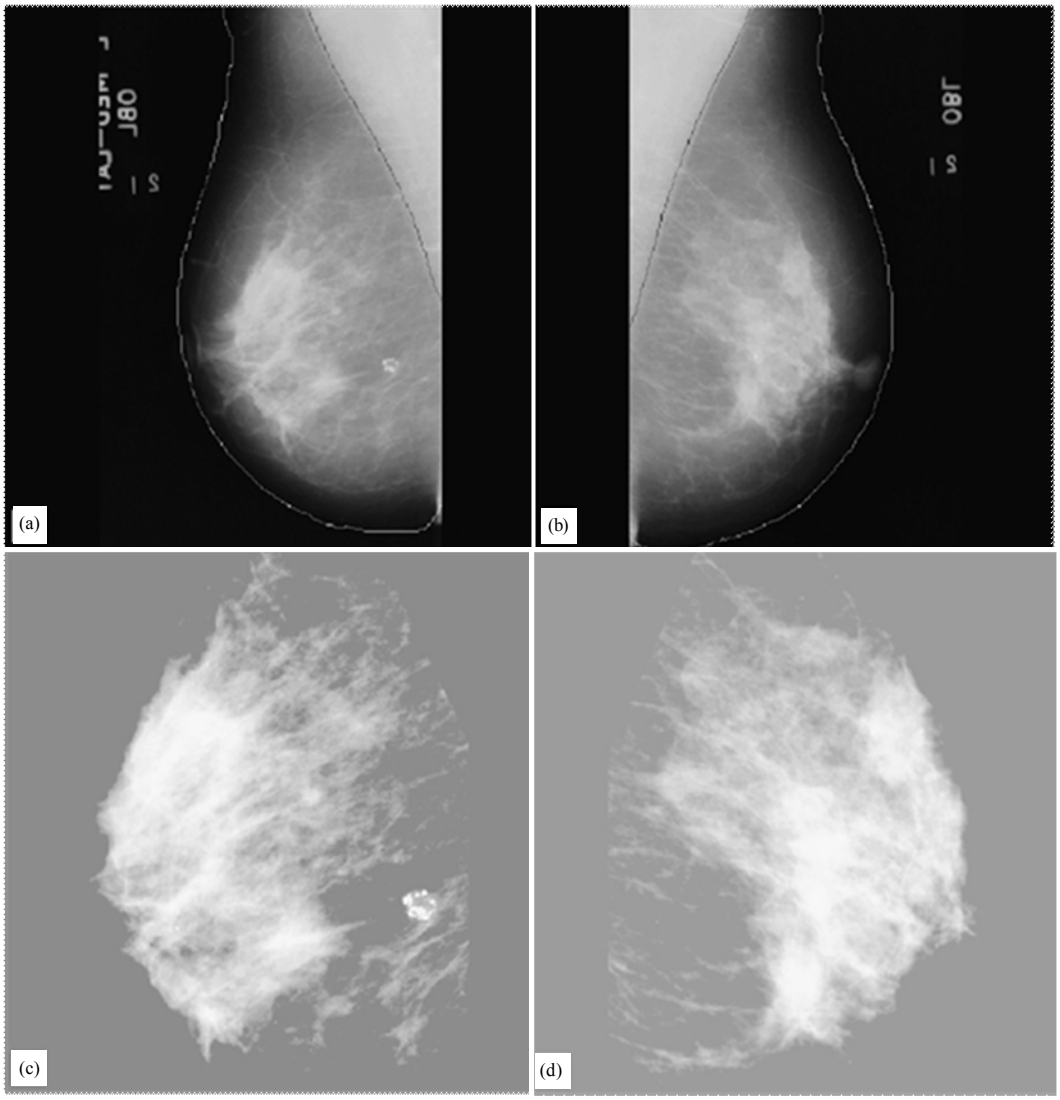

Fig. 1(a-d): (a, b) Original images (1024_1024 pixels at 200 mm/pixel). The breast boundary (white) and pectoral muscle edge (black) detected are shown and (c, d) Fibro glandular disks segmented and enlarged (512_512 pixels). Histogram equalization was applied to enhance the global contrast of each ROI for display purposes only. Reproduced with permission from Ferrari *et al*. (2001) IEEE

segmented as illustrated in Fig. 1 and the resultant image is broken down using a cache of Gabor filters at varied orientations and scales. The Karhunen–Loeve transform is used to choose the major elements of the filter responses. Rose diagrams are calculated from the phase images and afterwards examined to identify incidences of asymmetry as typified by disparity in oriented textural patterns (Fig. 2). Based on the theory, a file of 80 images from the Mini-MIAS database containing 20 normal cases, 14 asymmetric cases and six architectural distortion cases was employed to assess the algorithm. The results showed a classification accuracy rate of up to 74.4%. The Gabor-filter-based method provides quantitative tool for evaluating the variations in the directional distribution of the fibroglandular tissue (pattern asymmetry). Rangayyan *et al*. (1997) carried out further work on the method proposed by Ferrari *et al*. (2001) by incorporating morphological parameters to quantify the variations in fibroglandular-tissue-covered area on both breasts, in terms of size and shape. Also, the directional data was aligned with reference to the edge of the pectoral muscle (in MLO views). A sensitivity of 82.6% and a specificity of 86.4% were attained in the detection of bilateral asymmetry.

Detection of architectural distortion: Architectural distortion is one of the most frequently undetected or overlooked abnormalities during screening mammography. It is defined as

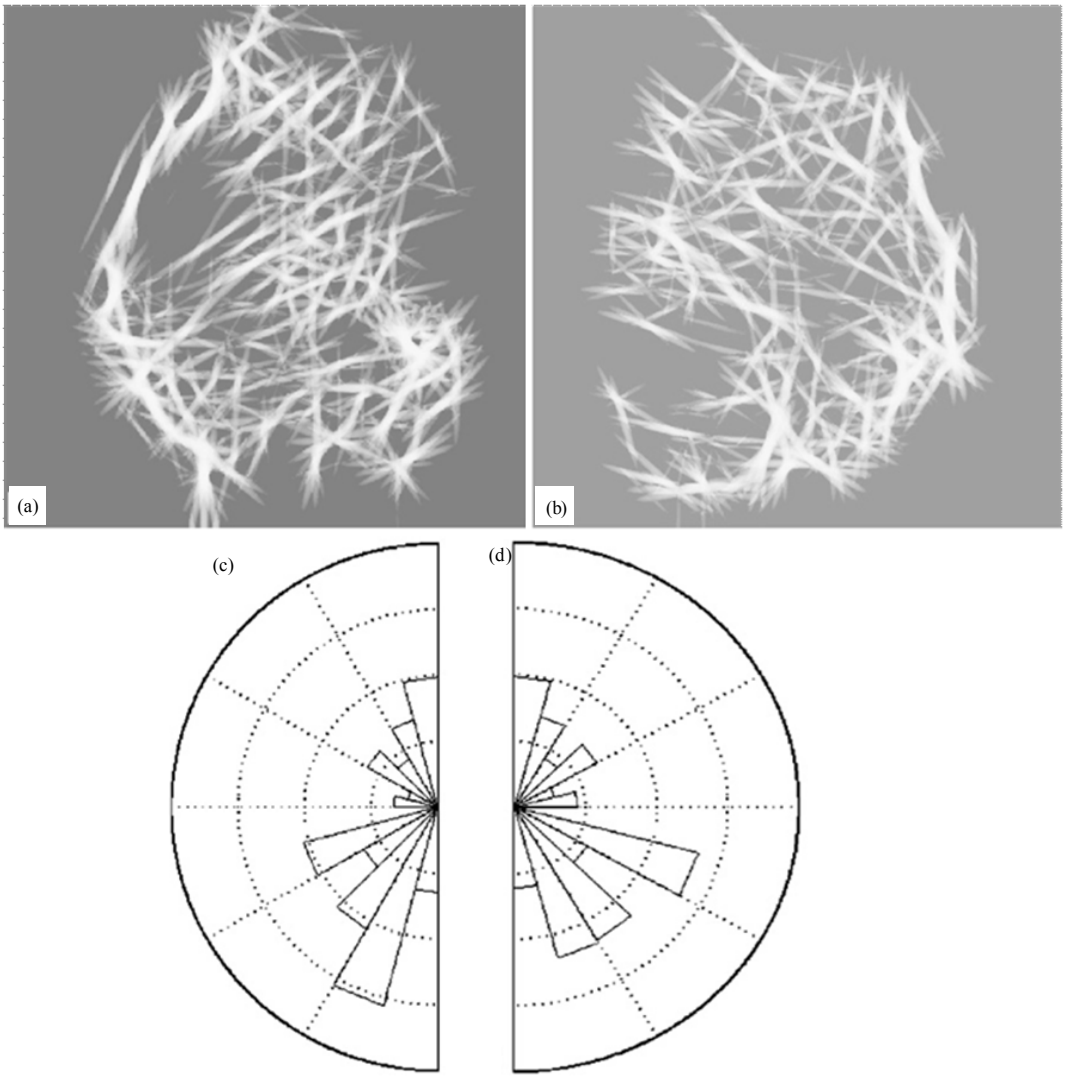

Fig. 2(a-d): Results of analysis of bilateral asymmetry for the case of architectural distortion in Fig. 1, (a, b) Magnitude images and (c, d) Rose diagrams. The magnitude images were histogram-equalized for improved visualization. The rose diagrams have been configured to match the mammograms in orientation. Reproduced with permission from Ferrari *et al*. (2001) IEEE

distortion or alteration of the normal architecture with no distinctive change in mass. It also includes spiculations radiating from a point and focal retraction or distortion at the edge of the parenchyma (American College of Radiology, 1998). The imprecise description of architectural distortion along with its latent features leads to complexities in the development of image processing techniques for its detection.

Nonetheless, several studies have been drawn up to develop effective techniques for improved and concise detection. For instance, fractal dimension have been used recently to characterize the occurrence of architectural distortion in mammographic ROIs. Guo *et al*. (2005) examined the characterization of architectural distortion using the Hausdorff dimension and a support vector machine classifier to differentiate mammographic ROIs displaying architectural distortion from those with regular mammographic patterns. The evaluation involved the use of a collection of 40 ROIs obtained from the MIAS database (19 ROIs with architectural distortion and 21 ROIs with normal tissue patterns). The study reported a classification accuracy of 72.5%.

Tourassi *et al.* (2006) assessed the application of fractal dimension in distinguishing between normal and architectural distortion patterns in mammographic ROIs. The dataset employed in the study consisted of 112 ROIs with architectural distortion patterns and 1388 ROIs exhibiting normal tissue patterns. An area under the ROC curve of Az = 0.89 was obtained. The study also showed that the mean fractal

dimension of ROIs displaying architectural distortion was seen to be comparatively lower than that of ROIs with normal patterns. The observed disparity was deduced to be statistically significant under an independent-sample carried out in a two-tailed t-test.

Ichikawa *et al*. (2004) proposed a viable method for identifying architectural distortion. The method entails certain intricate procedures: the detection of linear structures using the mean curvature of the image, the computational analysis of a concentration index that specifies the presence of stellate structures over half-circles and the detection of architectural distortion based on a set of local parameters such as the concentration index. The study reported a sensitivity of 68% with 3.4 false positives per image.

Review of prior mammograms: Generally, screening mammography has a limited sensitivity and it has been observed that latent indications of abnormality are discernible in a considerable portion of previous screening mammograms of screen-detected or interval cases of breast cancer, regarded as prior mammograms. It is likely that there is the existence of such cases of undetected indications of abnormality present, present as unclear, subtle or difficult-to-detect features pointing to early signs of breast cancer. Sameti *et al*. (1998) investigated the structural distinguishing features between malignant tumor regions on mammograms and surrounding normal areas in images taken in the previous screening instance preceding the detection of tumors. Manually identified circular ROIs were modified into their optical-density equivalents and then grouped into three types of regions based on the level of density: low, medium and high optical density. Based upon the regions, a set of photometric and texture features was extracted. The study was able to identify the disparity between malignant tumor regions and normal tissues in previous screening images for 72% of the 58 breast cancer cases studied.

Petrick *et al*. (2000) studied the efficiency of their mass-detection method in the detection of masses in prior mammograms. The dataset utilized for the study consists of 92 images (54 malignant and 38 benign) from 37 cases (22 malignant and 15 benign). Their detection methods achieved a ''by film'' mass-detection sensitivity of 51% with 2.3 false positives per image, although a slightly better accuracy of 57% was attained in the detection of only malignant tumors. The study carried out attempts to segment salient (subtle) densities using regions developed by image contrast enhancement. However, such an intensity-based segmentation approach was unable to detect the developing densities in prior mammograms as a result of the insufficient contrast of possibly abnormal regions before the masses are actually formed.

Zheng *et al*. (2003) examined the impact of a CAD algorithm on the detection of masses in current and prior mammograms under two settings: algorithm optimization with current mammograms and algorithm optimization with prior mammograms. The CAD algorithm comprises three steps: difference-of-Gaussian filtering and thresholding for the preliminary selection of possible lesion sites; adaptive region growing and topological analysis of the doubtful regions to remove false positives and feature extraction (including shape, histogram and texture features) and classification using an Artificial Neural Network (ANN). A database of 260 pairs of successive mammograms was utilized in this study, where the most recent image showed one or two masses and the prior image had been initially classified as negative or possibly benign. The first two steps of the CAD algorithm were performed on both the current and prior images of the database, producing a set of 1,449 suspicious ROIs, which were classified according to the true mass location in the current mammograms. The ROIs were classified into the normal and mass categories using the third step of the CAD algorithm (feature extraction and ANN classification). The authors reported that training the ANN with the current mammograms resulted in areas under the ROC curves of 0.8±0.01 and 0.65±0.02 when classifying ROIs from the current and prior mammograms, respectively. When the ANN was trained with ROIs from the prior mammograms, areas under the ROC curve of 0.8±0.02 and 0.71±0.02 were obtained in the classification of ROIs from the current and prior mammograms, respectively. The results further emphasizes the significance of developing CAD algorithms capable of incorporating information about specific features of early signs, rather than the use of methods developed for well-developed malignant masses, for the detection of early signs of breast cancer. The synchronized analysis of current and prior mammograms could enhance the ability of radiologists in the detection of breast cancer and possibly also improve the effectiveness of CAD systems.

Full-field digital mammography: Full-field digital mammography, although not precisely a CAD technology, encompasses a number of valuable parameters that can be utilized by a CAD system. It is a digital imaging system that involves a series of steps that include image acquisition, processing, display and storage, which are decoupled to allow their optimization. Several studies have reviewed the available technologies in full-field digital mammography (James, 2004; Pisano, 2000; Yaffe, 1998; Lewin *et al*., 2002) by carrying out comparative analyses between the performances of full-field digital mammography and screen-film mammography for the detection of breast cancer in a screening population. The results showed that there is no statistical significant difference ($p \geq 0.1$) existed in cancer detection and digital mammography exhibited fewer recalls compared to screen-film mammography ($p \leq 0.001$).

Indexed atlases, data mining and content-based retrieval: The introduction of mammographic screening programs in the health sector has produced variety of data, such as patient

reports and mammographic images, which are stored in numerous databases across medical centers and universities worldwide. This vast amount of data could be explored through the application of information management technologies that will eventually be of immense benefit to researchers, clinical practitioners, students, patients and companies involved in research and development projects associated with CAD systems, as well as others concerned with the endeavors of decreasing breast cancer mortality. Data represent a meaningless entity that is transformed into information through the process of analysis and attribution of meaning. It is necessary to develop the proper computational tools in order to obtain useful information from the vast amounts of data present in mammographic and associated databases.

The impact of effectively recovering and evaluating information can be determined by examining the mechanism by which search engines assist in taming the enormous and intricate amount of data accessible on the Internet. Nonetheless, it is essential to modify the information retrieval tools in order to adapt to the nature of information being retrieved. Some researchers have studied the application of Content-Based Image Retrieval (CBIR) and data mining techniques to explore the immense materials present in databases of mammograms and patient information (Wang *et al*., 2004). Honda *et al*. (2002) developed a CBIR system based on textural features and PCA. The study reported a precision rate ranging between 25 and 100%. Nakagawa *et al*. (2002) created a method for CBIR where mammographic ROIs containing masses were represented by autocorrelation measures. Based on an experimental sample, the study demonstrated that the technique was effective for retrieving ROIs that were visually analogous to a given ROI. However, the visual parallels did not validate an agreement between the radiologist's estimation of the query ROI and the retrieved ROIs. Rather, an agreement of only 29% was achieved in the shape of the mass and 34% in the depiction of the mass border.

Furthermore, Alto *et al*. (2003) investigated several issues related to the use of an indexed atlas of digital mammograms for CAD of breast cancer. Specifically, the use of objective measures developed from the application of image processing techniques, to signify diagnostic features in mammograms could result in peripheral features such as semantic indexing, data mining, content-based retrieval and comparative analysis of cases. Indexed atlases can be further extended to aid in the teaching and training of radiologists and integrated with content-based retrieval tools to assist radiologists in the decision-making process for difficult-to-diagnose complex breast cancer cases (Guliato *et al*., 2006).

CONCLUSION

In this study, the general processes involved in computer-aided detection and diagnosis of breast abnormalities were reviewed. The study provides a concise synopsis of methods utilized in the detection of breast lesions and their associated features. Identification of other significant abnormalities that may indicate breast cancers are described (mass, calcifications, architectural distortion and bilateral asymmetry) using advanced techniques were also discussed. Studies have shown that computer-aided detection and diagnosis of breast abnormalities is hindered by a broad range of features and their low visibility within the surrounding tissue. Therefore, the recently developed CAD algorithms were outlined as well as further modifications required to enhance the detection and diagnosis of breast abnormalities using computers. Computer-aided diagnosis technology serves as an affordable substitute to double reading and is effective for error reduction in mammographic screening to a level analogous to that attained with double reading. From the review of the several techniques established for the detection of masses and calcifications, certain modifications are suggested in this study to improve the early detection of latent signs of breast cancer, such as bilateral asymmetry and architectural distortion.

REFERENCES

Acha, B., C. Serrano, R.M. Rangayyan, J.E.L. Desautels, 2006. Detection of Microcalcifications in Mammograms. In: Recent Advances in Breast Imaging, Mammography and Computer-Aided Diagnosis of Breast Cancer, Suri, J.S. and R.M. Rangayyan (Eds.). Chapter 9, SPIE, Bellingham, WA., USA., ISBN-13: 9780819460813, pp: 291-314.

Alto, H., R.M. Rangayyan, R.B. Paranjape, J.E.L. Desautels and H. Bryant, 2003. An indexed atlas of digital mammograms for computer-aided diagnosis of breast cancer. Annales Telecommunications, 58: 820-835.

American College of Radiology, 1998. Illustrated Breast Imaging Reporting and Data System (BI-RADS). 3rd Edn., The American College of Radiology, Reston, VA.

Baker, J.A., E.L. Rosen, J.Y. Lo, E.I. Gimenez, R. Walsh and M.S. Soo, 2003. Computer-Aided Detection (CAD) in screening mammography: Sensitivity of commercial CAD systems for detecting architectural distortion. Am. J. Roentgenol., 181: 1083-1088.

Bird, R.E., T.W. Wallace and B.C. Yankaskas, 1992. Analysis of cancers missed at screening mammography. Radiology, 184: 613-617.

Birdwell, R.L., D.M. Ikeda, K.F. O'Shaughnessy and E.A. Sickles, 2001. Mammographic characteristics of 115 missed cancers later detected with screening mammography and the potential utility of computer-aided detection. Radiology, 219: 192-202.

Broeders, M.J.M., N.C. Onland-Moret, H.J.T.M. Rijken, J.H.C.L. Hendriks, A.L.M. Verbeek and R. Holland, 2003. Use of previous screening mammograms to identify features indicating cases that would have a possible gain in prognosis following earlier detection. Eur. J. Cancer, 39: 1770-1775.

Burhenne, L.J.W., S.A. Wood, C.J. D'Orsi, S.A. Feig and D.B. Kopans *et al*., 2000. Potential contribution of computer-aided detection to the sensitivity of screening mammography. Radiology, 215: 554-562.

Burrell, H.C., D.M. Sibbering, A.R. Wilson, S.E. Pinder and A.J. Evans *et al*., 1996. Screening interval breast cancers: Mammographic features and prognosis factors. Radiology, 199: 811-817.

Byng, J.W., N.F. Boyd, E. Fishell, R.A. Jong and M.J. Yaffe, 1996. Automated analysis of mammographic densities. Phys. Med. Biol., 41: 909-923.

Chan, H.P., C.J. Vyborny, H. MacMahon, C.E. Metz, K. Doi and E.A. Sickles, 1987. Digital Mammography: ROC studies of the effects of pixel size and unsharp-mask filtering on the detection of subtle microcalcifications. Invest. Radiol., 22: 581-589.

Ciatto, S., M.R. Del Turco, G. Risso, S. Catarzi and R. Bonardi *et al*., 2003. Comparison of standard reading and Computer Aided Detection (CAD) on a national proficiency test of screening mammography. Eur. J. Radiol., 45: 135-138.

Dhawan, A.P., G. Buelloni and R. Gordon, 1986. Enhancement of mammographic features by optimal adaptive neighborhood image processing. IEEE Trans. Med. Imaging, 5: 8-15.

Evans, W.P., L.J.W. Burhenne, L. Laurie, K.F. O'Shaughnessy and R.A. Castellino, 2002. Invasive lobular carcinoma of the breast: Mammographic characteristics and computer-aided detection. Radiology, 225: 182-189.

Feig, S.A., B.M. Galkin and H.D. Muir, 1987. Evaluation of Breast Microcalcifications by Means of Optically Magnified Tissue Specimen Radiographs. In: Breast Cancer: Present Perspective of Early Diagnosis, Brunner, S. and B. Langfeldt (Eds.). Springer, Berlin, Germany, ISBN: 978-3-642-82966-6, pp: 111-123.

Ferrari, R.J., R.M. Rangayyan, J.E.L. Desautels and A.F. Frere, 2001. Analysis of asymmetry in mammograms via directional filtering with Gabor wavelets. IEEE Trans. Med. Imaging, 20: 953-964.

Ferrari, R.J., A.F. Frere, R.M. Rangayyan, J.E.L. Desautels and R.A. Borges, 2004a. Identification of the breast boundary in mammograms using active contour models. Med. Biol. Eng. Comput., 42: 201-208.

Ferrari, R.J., R.M. Rangayyan, J.E.L. Desautels, R.A. Borges and A.F. Frere, 2004b. Automatic identification of the pectoral muscle in mammograms. IEEE Trans. Med. Imaging, 23: 232-245.

Ferrari, R.J., R.M. Rangayyan, R.A. Borges and A.F. Frere, 2004c. Segmentation of the fibro-glandular disc in mammogrms using Gaussian mixture modelling. Med. Biol. Eng. Comput., 42: 378-387.

Freer, T.W. and M.J. Ulissey, 2001. Screening mammography with computer-aided detection: Prospective study of 12,860 patients in a community breast center. Radiology, 220: 781-786.

Giger, M.L., 2000. Computer aided diagnosis of breast lesions in medical images. Comput. Sci. Eng., 2: 39-45.

Guliato, D., E.V. de Melo, R.S. Boaventura, R.M. Rangayyan, 2006. AMDI indexed Atlas of Digital Mammograms that Integrates Case Studies, e-Learning and Research Systems via the Web. In: Recent Advances in Breast Imaging, Mammography and Computer-Aided Diagnosis of Breast Cancer, Suri, J.S. and R.M. Rangayyan (Eds.). Chapter 15, SPIE Press, Bellingham, WA., USA., ISBN-13: 9780819460813, pp: 529-555.

Guo, Q., J. Shao and V. Ruiz, 2005. Investigation of support vector machine for the detection of architectural distortion in mammographic images. J. Phys.: Conf. Ser., 15: 88-94.

Hackshaw, A.K. and E.A. Paul, 2003. Breast self-examination and death from breast cancer: A meta-analysis. Br. J. Cancer, 88: 1047-1053.

Helms, R.L., E.L. O'Hea and M. Corso, 2008. Body image issues in women with breast cancer. Psychol. Health Med., 13: 313-325.

Honda, M.O., P.M. de Azevedo Marques and J.A.H. Rodrigues, 2002. Content-based image retrieval in mammography: Using texture features for correlation with BI-RADS categories. Proceedings of the 6th International Workshop on Digital Mammography, June 22-25, 2002, Bremen, Germany, pp: 231-233.

Ichikawa, T., T. Matsubara, T. Hara, H. Fujita, T. Endo and T. Iwase, 2004. Automated detection method for architectural distortion areas on mammograms based on morphological processing and surface analysis. Proceedings of SPIE Medical Imaging 2004: Image Processing, Volume 5370, February 16-19, 2004, San Diego, CA., USA., pp: 920-925.

James, J.J., 2004. The current status of digital mammography. Clin. Radiol., 59: 1-10.

Jemal, A., L.X. Clegg, E. Ward, L.A. Ries and X. Wu *et al*., 2004. Annual report to the nation on the status of cancer, 1975-2001, with a special feature regarding survival. Cancer, 101: 3-27.

Karssemeijer, N., 1998. Automated classification of parenchymal patterns in mammograms. Phys. Med. Biol., 43: 365-378.

Kimme-Smith, C., R.H. Gold, L.W. Bassett, L. Gormley and C. Morioka, 1989. Diagnosis of breast calcifications: Comparison of contact, magnified and television-enhanced images. Am. J. Roentgenol., 153: 963-967.

Laine, A.F., S. Schuler, J. Fan and W. Huda, 1994. Mammographic feature enhancement by multiscale analysis. IEEE Trans. Med. Imag., 13: 725-740.

Lau, T.K. and W.F. Bischof, 1991. Automated detection of breast tumors using the asymmetry approach. Comput. Biomed. Res., 24: 273-295.

Lewin, J.M., C.J. D'Orsi, R.E. Hendrick, L.J. Moss, P.K. Isaacs, A. Karellas and G.R. Cutter, 2002. Clinical comparison of full-field digital mammography and screen-film mammography for detection of breast cancer. Am. J. Roentgenol., 179: 671-677.

Miller, P. and S.M. Astley, 1993. Detection of breast asymmetry using anatomical features. Proceedings of the SPIE Conference on Biomedical Image Processing and Biomedical Visualization, Volume 1905, February 1-4, 1993, San Jose, CA., USA., pp: 433-442.

Miller, P. and S.M. Astley, 1994. Automated Detection of Breast Asymmetry Using Anatomical Features. In: State of the Art in Digital Mammographic Image Analysis, Bowyer, K.W. and S. Astley (Eds.). World Scientific, River Edge, NJ., USA., ISBN-13: 9789810215095, pp: 247-261.

Morrow, W.M., R.B. Paranjape, R.M. Rangayyan and J.E.L. Desautels, 1992. Region-based contrast enhancement of mammograms. IEEE Trans. Med. Imaging, 11: 392-406.

Nakagawa, T. Hara, H. Fujita, T. Iwase, T. Endo, 2002. Image retrieval system of mammographic masses by using local pattern matching technique. Proceedings of the 6th International Workshop on Digital Mammography, June 22-25, 2002, Bremen, Germany, pp: 562-565.

Peitgen, H.O., 2003. Digital Mammography: IWDM 2002-6th International Workshop on Digital Mammography. Springer-Verlag, Berlin, Germany, ISBN-13: 9783642593277, Pages: 596.

Petrick, N., H.P. Chan, B. Sahiner, M.A. Helvie, S. Paquerault, 2000. Evaluation of an automated computer-aided diagnosis system for the detection of masses on prior mammograms. Proceedings of SPIE Medical Imaging 2000 Conference: Image Processing, Volume 3979, February 12-18, 2000, San Diego, CA., USA., pp: 967-973.

Pisano, E.D., 2000. Current status of full-field digital mammography. Radiology, 214: 26-28.

Pisano, E.D., M.J. Yaffe and C.M. Kuzmiak, 2004. Digital Mammography. Lippincott Williams and Wilkins, Philadelphia, PA., USA., ISBN-13: 9780781741422, Pages: 231.

Ram, G., 1982. Optimization of ionizing radiation usage in medical imaging by means of image enhancement techniques. Med. Phys., 9: 733-737.

Rangayyan, R.M., 2004. Biomedical Image Analysis. CRC Press, Boca Raton, FL., USA., ISBN-13: 9780849396953, Pages: 1312.

Rangayyan, R.M. and A.F. Ferrari, 2004. Detection of asymmetry between left and right mammograms. Proceedings of the 7th International Workshop on Digital Mammography, June 18-21, 2004, Chapel Hill, NC., USA., pp: 651-658.

Rangayyan, R.M., F.J. Ayres and J.E. Leo Desautels, 2007. A review of computer-aided diagnosis of breast cancer: Toward the detection of subtle signs. J. Franklin Inst., 344: 312-348.

Rangayyan, R.M., L. Shen, Y. Shen, J.E.L. Desautels and H. Bryant *et al*., 1997. Improvement of sensitivity of breast cancer diagnosis with adaptive neighborhood contrast enhancement of mammograms. IEEE Trans. Inform. Technol. Biomed., 1: 161-170.

Sameti, M., J. Morgan-Parkes, R.K. Ward and B. Palcic, 1998. Classifying image features in the last screening mammograms prior to detection of a malignant mass. Proceedings of the 4th International Workshop on Digital Mammography, June 7-10, 1998, Nijmegen, The Netherlands, pp: 127-134.

Serrano, C., J.D. Trujillo, B. Acha and R.M. Rangayyan, 2001. Use of 2D linear prediction error to detect microcalcifications in mammograms. Proceedings of the 2nd Latin American Congress on Biomedical Engineering, May 23-25, 2001, Havana, Cuba.

Shen, L., R.M. Rangayyan and J.L. Desautels, 1993. Detection and classification of mammographic calcifications. Int. J. Pattern Recognit. Artif. Intell., 7: 1403-1416.

Shen, L., R.M. Rangayyan and J.E.L. Desautels, 1994. Application of shape analysis to mammographic calcification. IEEE Trans. Med. Imag., 13: 263-274.

Sickles, E.A., 1986a. Breast calcifications: Mammographic evaluation. Radiology, 160: 289-293.

Sickles, E.A., 1986b. Mammographic features of 300 consecutive nonpalpable breast cancers. Am. J. Roentgenol., 146: 661-663.

Strickland, R.N. and H.I. Hahn, 1996. Wavelet transforms for detecting micro calcifications in mammograms. IEEE Trans. Med. Imag., 15: 218-229.

Sun, Y., J.S. Suri, J.L. Desautels and R.M. Rangayyan, 2006. A new approach for breast skin-line estimation in mammograms. Pattern Anal. Applic., 9: 34-47.

Tourassi, G.D., D.M. Delong and C.E. Floyd Jr., 2006. A study on the computerized fractal analysis of architectural distortion in screening mammograms. Phys. Med. Biol., 51: 1299-1312.

Ursin, G., L. Hovanessian-Larsen, Y.R. Parisky, M.C. Pike and A.H. Wu, 2005. Greatly increased occurrence of breast cancers in areas of mammographically dense tissue. Breast Cancer Res., 7: R605-R608.

Van Dijck, J.A., A.L. Verbeek, J.H. Hendriks and R. Holland, 1993. The current detectability of breast cancer in a mammographic screening program. A review of the previous mammograms of interval and screen detected cancers. Cancer, 72: 1933-1938.

Wang, X., M.R. Smith and R.M. Rangayyan, 2004. Mammographic information analysis through association-rule mining. Proceedings of the Canadian Conference on Electrical and Computer Engineering, Volume 3, May 2-5, 2004, Niagara Falls, Canada, pp: 1495-1498.

Yaffe, M.J., 1998. Development of Full Field Digital Mammography. In: Digital Mammography, Karssemeijer, N., M. Thijssen J. Hendriks and L. van Erning (Eds.). Kluwer Academic Publishers, Nijmegen, The Netherlands, ISBN: 978-94-010-6234-3, pp: 3-10.

Yu, S. and L. Guan, 2000. A CAD system for the automatic detection of clustered microcalcifications in digitized mammogram films. IEEE Trans. Med. Imaging, 19: 115-126.

Yu, S.N., K.Y. Li and Y.K. Huang, 2006. Detection of microcalcifications in digital mammograms using wavelet filter and Markov random field model. Comput. Med. Imaging Graph., 30: 163-173.

Zheng, B., W.F. Good, D.R. Armfield, C. Cohen, T. Hertzberg, J.H. Sumkin and D. Gur, 2003. Performance change of mammographic CAD schemes optimized with most-recent and prior image databases. Acad. Radiol., 10: 283-288.