

<http://www.pjbs.org>

PJBS

ISSN 1028-8880

**Pakistan
Journal of Biological Sciences**

ANSI*net*

Asian Network for Scientific Information
308 Lasani Town, Sargodha Road, Faisalabad - Pakistan

Mercury Release from Dental Amalgam Restorations after Magnetic Resonance Imaging and Following Mobile Phone Use

^{1,2}S.M.J. Mortazavi, ³E. Daiee, ³A. Yazdi, ⁴K. Khiabani, ⁴A. Kavousi, ⁵R. Vazirinejad, ⁶B. Behnejad, ⁷M. Ghasemi and ⁸M. Balali Mood

¹Department of Medical Physics, School of Paramedical Sciences, Shiraz University of Medical Sciences, Shiraz, Iran

²Department of Medical Physics, School of Dentistry, Rafsanjan University of Medical Sciences, Rafsanjan, Iran

³School of Dentistry, Rafsanjan University of Medical Sciences, Rafsanjan, Iran

⁴Department of Dental Radiology, Dentistry School,

Rafsanjan University of Medical Sciences, Rafsanjan, Iran

⁵Department of Community Medicine, School of Medicine, Rafsanjan University of Medical Sciences, Rafsanjan, Iran

⁶Department of Radiologic Technology, School of Paramedical Sciences, Rafsanjan University of Medical Sciences, Rafsanjan, Iran

⁷Toxicology Laboratory, Imam Reza Hospital, Mashhad University of Medical Science, Mashhad, Iran

⁸Department of Medical Toxicology, Medical Toxicology Research Center, Imam Reza Hospital, Mashhad University of Medical Science, Mashhad, Iran

Abstract: In the 1st phase of this study, thirty patients were investigated. Five milliliter stimulated saliva was collected just before and after MRI. The magnetic flux density was 0.23 T and the duration of exposure of patients to magnetic field was 30 minutes. In the 2nd phase, fourteen female healthy University students who had not used mobile phones before the study and did not have any previous amalgam restorations were investigated. Dental amalgam restoration was performed for all 14 students. Their urine samples were collected before amalgam restoration and at days 1, 2, 3 and 4 after restoration. The mean±SD saliva Hg concentrations of the patients before and after MRI were 8.6 ± 3.0 and 11.3 ± 5.3 $\mu\text{g L}^{-1}$, respectively ($p<0.01$). A statistical significant ($p<0.05$) higher concentration was observed in the students used mobile phone. The mean±SE urinary Hg concentrations of the students who used mobile phones were 2.43 ± 0.25 , 2.71 ± 0.27 , 3.79 ± 0.25 , 4.8 ± 0.27 and 4.5 ± 0.32 $\mu\text{g L}^{-1}$ before the amalgam restoration and at days 1, 2, 3 and 4, respectively. Whereas the respective Hg concentrations in the controls, were 2.07 ± 0.22 , 2.34 ± 0.30 , 2.51 ± 0.25 , 2.66 ± 0.24 and 2.76 ± 0.32 $\mu\text{g L}^{-1}$. It appears that MRI and microwave radiation emitted from mobile phones significantly release mercury from dental amalgam restoration. Further research is needed to clarify whether other common sources of electromagnetic field exposure may cause alterations in dental amalgam and accelerate the release of mercury.

Key words: Mobile phone, MRI, microwave radiation, mercury, dental amalgam

INTRODUCTION

Magnetic Resonance Imaging (MRI), as an efficient medical diagnostic procedure, is increasingly used. During MRI patients are exposed to static and gradient magnetic fields as well as electromagnetic radiation in radiofrequency range (Formica and Silvestri, 2004). Nowadays, MRI systems utilize stronger static magnetic fields, faster and stronger gradient magnetic fields and more powerful radiofrequency (RF)

transmission coils (Shellock and Crues, 2004). Potential hazards associated with MRI systems and procedures have been extremely controversial over the past decade (Formica and Silvestri, 2004). Heating and induction of electrical currents may present risks to patients with implants or external devices (Shellock, 2002; Dempsey and Condon, 2001). The majority of MRI related accidents have been originated from metallic objects, implants and biomedical devices (Sawyer-Glover and Shellock, 2000; Ho, 2001).

Corresponding Author: S.M.J. Mortazavi, The Center for Radiation Research, Department of Radiology, School of Paramedical Sciences, P.O. Box 71345-1755, Shiraz, Iran
Tel: +98-711-2295023, 2294720 Fax: +98-711-2289113

Drastically increased number of mobile phone users has lead to large numbers of base station to provide widespread availability of service to large populations (Valberg *et al.*, 2007). Rapidly increasing use of wireless communication systems has caused a growing public concern about possible health effects of EMFs (Marková *et al.*, 2005), particularly because the mobile phones operate in close proximity to brain. Dental amalgam is believed to be the main source of human total mercury body burden (Mutter *et al.*, 2007a). Amalgam fillings release mercury at a low level ranging 2-5 micrograms/day in an adult (Spencer, 2000). The half-life of mercury deposits in brain and bone tissues ranges from several years to decades and this is the reason that mercury accumulates over time of exposure (Mutter *et al.*, 2007a). New studies suggests that mercury from dental amalgam may lead to nephrotoxicity, neurobehavioural changes, oxidative stress, autism, skin and mucosa alterations or non-specific symptoms and complaints (Mutter *et al.*, 2005). In spite of the widespread use of amalgam, most dentists and doctors are still unaware of its health effects (Pleva, 1994). Studies which indicate that amalgam fillings are safe for human beings seem to have considerable methodological flaws (Mutter *et al.*, 2007b).

It has recently been reported that elevated occupational exposure to magnetic fields is associated with an increased risk of Alzheimer (Davampour *et al.*, 2007). Higher mercury concentrations were found in brain regions and blood of some patients with Alzheimer's Disease (AD). Low levels of inorganic mercury were able to cause AD- typical nerve cell deteriorations *in vitro* and in animal experiments. On the other hand, some recent studies show higher mercury concentrations in brains of patients with Alzheimer's disease. Researchers have indicated that even low levels of mercury are able to cause nerve cell changes, which are typical for Alzheimer's disease (Mutter *et al.*, 2007a). These researchers were possibly unaware of the early experiments on undersea welders which showed that electromagnetic fields might alter the evaporation of mercury from dental amalgam restorations (Ortendahl *et al.*, 1988). We believe that it may be hypothesized that the increase in mercury release due to exposure to magnetic fields is possibly the cause of increased incidence of Alzheimer disease in individuals occupationally exposed to magnetic fields. In this light, we believed that relatively short-term non-occupational exposure to electromagnetic fields may lead to increased release of mercury from dental amalgam restorations. We have previously found no association between the exposure to some major sources of electromagnetic fields and self-reported illness symptoms (Mortazavi *et al.*, 2007). The aim of the present study was to assess the potential alterations in the release of mercury from human

dental amalgam restorations after exposure to electromagnetic fields produced by conventional MR imaging and microwave radiation emitted by using mobile phones.

MATERIALS AND METHODS

Following approval of the University Medical Ethics Committee in Rafsanjan and the informed consents of the subjects, two different studies were undertaken in years 2006 and 2007.

A-MR imaging: In this natural experiment, studied population was consisted of individuals with at least 4 teeth with amalgam restorations. The time passed from the last restoration was not more than one week. The sample size was calculated after conducting a pilot study. The confidence interval, power and effect size were 95, 80 and 0.5%, respectively. Thirty persons (27F, 3M; aged 18 to 48 years), who met all the inclusion criteria for our research and were referred by their own physicians to MRI department of Ali-ebn Abitaleb Teaching Hospital for performing brain scans, were investigated. As inter-individual variations is usually a major confounding factor in these studies, mercury level in each individual's saliva before MRI was compared to that of himself/herself after MRI. Following interview, 5 mL stimulated saliva was collected just before and after MRI for Hg determination. The MRI scanner used in this experiment was an electromagnet type Bruker (Tomikon R 23, Bruker Medizintechnik, Karlsruhe) that is the first MRI facility installed in IR Iran. The magnetic flux density was 0.23 T and the duration of exposure of patients to magnetic field was 30 min.

B-Mobile phone use: Fourteen female healthy University students aged 19-23 years who had not used mobile phones before the study and did not have any previous amalgam restorations but had more than 4 teeth decayed were investigated. Their urine samples were collected before amalgam restoration and one hour after mobile phone use at days 1, 2, 3 and 4 after restoration. Dental amalgam restorations were performed for all 14 students (2 molars on one side, one class I and one class II restorations with identical volume and surface area of the amalgam fillings). They all were asked not to use sea food, canned food and hot tea/coffee from one week before the study to final sampling at day 4 after amalgam restoration. The students were randomly divided into two equal groups. The test group students were exposed to microwave radiation emitted from a Nokia 3310 mobile phone ($SAR = 0.96 \text{ W kg}^{-1}$) that was operated in talk mode for 15 min every day at days 1-4 after restoration.

The other seven female age matched students who served as controls, sham exposed to microwave radiation.

For each subject of the two studies, a questionnaire regarding their possible sources of exposure to electromagnetic fields or microwave radiation, occupation, medical history and life style was filled out.

After freezing, the samples were sent to the Toxicology Laboratory of Imam Reza Hospital (Mashhad, Iran) and mercury concentrations in samples were measured by cold vapor (Mercuric Hydride System) of an atomic absorption (Perkin Elmer, Model 3030) spectrophotometer.

Relevant statistical tests (paired and independent Student-t and ANOVA) were performed using statistical package for social sciences (SPSS, version 13.0) at $p < 0.05$ as the significant level.

RESULTS

MRI: The overall mean age of the studied participants was 30.70 ± 11.80 (mean \pm SD) years. The participants mean age for males and females were 29.23 and 40.66 years, respectively. Age and sex distributions of the studied patients are shown in Table 1. More than 50% of them were in the age range 30-49 year (Table 1). The chief complaints for which participants were referred to MRI department were headache and vertigo (68.96%), hypophys gland problems (13.79%) and other causes including MS, cerebrovascular accidents, driving accidents and vision problems (17.24%). MRI procedure for all participants took 30 minutes and the number of slices was 57.

The oral cavity of participants were carefully examined by a dentist and the number of teeth with amalgam restoration was recorded. The minimum, maximum and mean numbers of teeth with amalgam fillings were 4, 11 and 6.4, respectively. The minimum, maximum and mean numbers of amalgam-filled surfaces were 4, 23 and 10.5, respectively.

Mean \pm SD saliva Hg concentrations of the patients before and after MRI were 8.6 ± 3.0 and $11.3 \pm 5.3 \mu\text{g L}^{-1}$, respectively ($p < 0.01$). Mercury saliva concentrations of the studied participants before and after MRI are shown in Fig. 1. The mercury saliva concentrations before MRI ranged from 5.0 to $15.0 \mu\text{g L}^{-1}$, but after MRI, it ranged from 5.0 to $25.0 \mu\text{g L}^{-1}$.

Mobile phone use: As shown in Table 2, an elevated urinary mercury concentration released from dental amalgam fillings was observed after exposure to microwave radiation emitted from mobile phones. The (mean \pm SD) urinary Hg concentrations in the test group

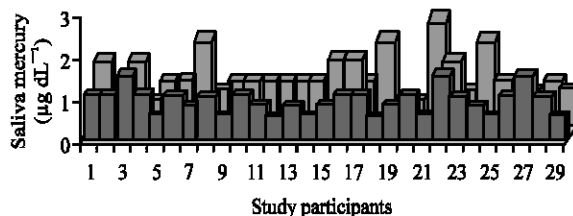


Fig. 1: Mercury saliva concentrations of the studied participants before and after MRI

Table 1: Age distribution of the MRI studied participants

Age (year)	Gender				Total	
	No.	(%)	No.	(%)	No.	(%)
<20	3	11.1	0	0	3	10.0
20-29	14	51.9	0	0	14	46.7
30-39	3	11.1	2	66.7	5	16.7
>40	7	25.9	1	33.3	8	26.7
Total	27	100.0	3	100.0	30	100.0

Table 2: The (mean \pm SE) urinary Hg concentrations of students with (test group) and without using mobile phone (controls) after dental amalgam restoration

Urine Hg ($\mu\text{g L}^{-1}$)	Time					p-value (ANOVA)
	Day 0	Day 1	Day 2	Day 3	Day 4	
Controls	2.07 ± 0.58	2.34 ± 0.80	2.51 ± 0.67	2.66 ± 0.64	2.76 ± 0.84	NS
Test group	2.43 ± 0.66	2.71 ± 0.72	3.79 ± 0.65	4.80 ± 0.71	4.50 ± 0.85	$p < 0.001$
p-value (Student's t-test)	NS	NS	$p < 0.001$	$p < 0.001$	$p < 0.001$	

Mercury level ($\mu\text{g L}^{-1}$), NS: Non Significant

students were 2.43 ± 0.66 , 2.71 ± 0.72 , 3.79 ± 0.65 , 4.8 ± 0.71 and $4.5 \pm 0.85 \mu\text{g L}^{-1}$ before the amalgam restoration and at days 1, 2, 3 and 4, respectively. Whereas the respective figures in the controls were 2.07 ± 0.33 , 2.34 ± 0.64 , 2.51 ± 0.44 , 2.66 ± 0.41 and $2.76 \pm 0.72 \mu\text{g L}^{-1}$.

DISCUSSION

In this study, it was shown that MRI and microwave radiation emitted from mobile phones significantly increased the release of mercury from dental amalgam restoration. Although the amount of released mercury from dental amalgam is not sufficient for causing a toxic effect in humans, potential toxicity due to exposure to mercury vapor (Hg) from dental amalgam fillings is still the subject of current public health debate in many countries (Echeverria *et al.*, 1998). Despite there is no evidence that dental amalgams cause health problems in the majority of the population, the effects of dental amalgam on specific groups, including pregnant women, small children, elderly and people who are especially sensitive to mercury is not clearly known.

MRI: Magnetic fields may interfere with ferromagnetic material and cause serious risks such as projectile effects, twisting, burning, artifacts and malfunction in some special device. However, other health effects of MR imaging have not been clearly known yet. In present study a significant relationship was observed between the mercury level in saliva and exposure to MRI. This finding confirms previous reports regarding the increased release of mercury from dental amalgam restorations in undersea welders. As in MRI the exposure to the magnetic field exceeds by far the exposure from undersea welding/cutting, these findings are expected. However, present findings are in contrast with the results reported in an *in vitro* study (Müller-Miny *et al.*, 1996). As far as we know, our study is the first to investigate the effect of MR imaging *in vivo* on the release of mercury from dental amalgams and the only other study that is previously performed *in vitro*, is the study performed by Müller-Miny *et al.* (1996). These investigators examined the mercury release for typical MRI conditions, separated for both the static and the variable magnetic fields in a 1.5 T MR-unit. They could not demonstrate any significant increase in mercury release due to MRI. Their *in vitro* study showed no evidence of an increased mercury release from a non-gamma-2 amalgam during magnetic field exposure by MRI. The main difference observed between the results of present study and those reported by Müller-Miny *et al.* (1996) can simply explained by the *in vivo* condition used in this study. It should be noted that saliva is a good electrolyte and may increase the release of mercury from dental amalgam due to induction of galvanic currents (Huggins and Levy, 1999). Amalgam fillings produce electrical currents which accelerate the release of mercury vapor. As saliva acts as an electrolyte, negatively charged fillings or crowns push electrons into the oral cavity. These currents are measured in micro amperes, with some measured at over 4 micro amps.

A point worth consideration is that the Bruker MRI device used in this experiment was the first MRI facility installed in IR Iran and the magnetic flux density was only 0.23 T. Needless to say, modern MRI scanners use magnets as strong as 0.5 to 2 T. In this light, it can be suggested that further studies should be performed on this topic by modern MR imaging systems.

Mobile phone use: In recent years, the widespread use of mobile phones has lead to a public debate about possible detrimental effects on human health. As mobile phones are a relatively new technology, scientists do not yet have long-term follow-up on their possible health effects (Frumkin *et al.*, 2001). In this study a significant

relationship was detected between the mercury levels in urine samples and exposure to microwave radiation emitted from mobile phones. This finding is in agreement with previous reports regarding the increased release of mercury from dental amalgam restorations in undersea welders.

CONCLUDING REMARKS

Electromagnetic radiation in radiofrequency (RF) region has long been used for different types of information exchange. Despite it is widely believed that MRI does not present any biological risk for humans, its components (static magnetic field, gradient magnetic fields and RF pulses) may cause some risks for patients. On the other hand, the dramatic increase in the use of cellular phones has generated great concerns about all potential adverse effects. Lack of ionizing radiation and the low energy level emitted from cell phones has led to this public perception that mobile phone use is safe. Results obtained in this study show a significant increase of the mercury release in urine after mobile phone use. These findings confirm early reports that showed an increased release of mercury from dental amalgam restorations in undersea welders. Further research is required to clarify whether other common sources of EMF exposure may cause alterations in dental amalgam and accelerate the release of mercury. However, further studies are needed to make a general conclusion.

REFERENCES

- Davampour, Z., C.C. Tseng, P.J. Lee and E. Sobelm, 2007. A case-control study of occupational magnetic field exposure and Alzheimer's disease: Results from the California Alzheimer's disease diagnosis and treatment centers. *BMC. Neurol.*, 7: 13.
- Dempsey, M.F. and B. Condon, 2001. Thermal injuries associated with MRI. *Clin. Radiol.*, 56 (6): 457-465.
- Echeverria, D., H.V. Aposhian, J.S. Woods, N.J. Heyer, M.M. Aposhian, A.C. Jr. Bittner, R.K. Mahurn and M. Cianciola, 1998. Neurobehavioral effects from exposure to dental amalgam Hg: New distinctions between recent exposure and Hg body burden. *FASEB. J.*, 12 (11): 971-980.
- Formica, D. and S. Silvestri, 2004. Biological effects of exposure to magnetic resonance imaging: An overview. *Biomed. Eng. Online*, 3: 11.
- Frumkin, H., A. Jacobson, T. Gansler and M.J. Thun, 2001. Cellular phones and risk of brain tumors. *CA Can. J. Clin.*, 51 (2): 137-141.
- Ho, H.S., 2001. Safety of metallic implants in magnetic resonance imaging. *J. Magn. Reson. Imaging*, 14 (4): 472-477.

- Huggins, H.A. and T.E. Levy, 1999. Uniformed Consent: the Hidden Dangers in Dental Care. Hampton Roads Publishing Company Inc.
- Marková, E., L. Hillert, L. Malmgren, B.R.R. Persson and I.Y. Belyaev, 2005. Microwaves from GSM mobile telephones affect 53BP1 and γ -H2AX Foci in human lymphocytes from hypersensitive and healthy persons. *Environ. Health Perspect.*, 113 (9): 1172-1177.
- Mortazavi, S.M.J., J. Ahmadi and M. Shariati, 2007. Prevalence of Subjective Poor Health Symptoms Associated with Exposure to Electromagnetic Fields among University Students. *Bioelectromagnetics*, 28 (4): 326-330.
- Muller-Miny, H., D. Erber, H. Moller, B. Muller-Miny and G. Bongartz, 1996. Is there a hazard to health by mercury exposure from amalgam due to MRI? *J. Magn. Reson. Imaging*, 6 (1): 258-260.
- Mutter, J., J. Naumann, H. Walach and F. Daschner, 2005. Amalgam risk assessment with coverage of references up to 2005. *Gesundheitswesen*, 67 (3): 204-216.
- Mutter, J., J. Naumann, R. Schneider and H. Walach, 2007a. Mercury and Alzheimer's disease. *Fortschr. Neurol. Psychiatr.*, 75 (9): 528-538.
- Mutter, J., J. Naumann and C. Guethlin, 2007b. Comments on the article the toxicology of mercury and its chemical compounds by Clarkson and Magos (2006). *Crit. Rev. Toxicol.*, 37 (6): 537-549.
- Ortendahl, T.W., P. Högstedt, H. Odelius and J.G. Norén, 1988. Effects of magnetic fields from underwater electrical cutting on *in vitro* corrosion of dental amalgam. *Undersea Biomed. Res.*, 15 (6): 443-455.
- Pleva, J., 1994. Dental mercury: A public health hazard. *Rev. Environ. Health*, 10 (1): 1-27.
- Sawyer-Glover, A. and F.G. Shellock, 2000. Pre-MRI procedure screening: Recommendations and safety considerations for biomedical implants and devices. *J. Magn. Reson. Imaging*, 12 (1): 92-106.
- Shellock, F.G., 2002. Magnetic resonance safety update. Implants and devices. *J. Magn. Reson. Imaging*, 16 (5): 485-496.
- Shellock, F.G. and J.V. Crues, 2004. MR procedures: Biologic effects, safety and patient care. *Radiology*, 232 (3): 635-652.
- Spencer, A.J., 2000. Dental amalgam and mercury in dentistry. *Aust. Dent. J.*, 45 (4): 224-234.
- Valberg, P.A., T.E. Van Deventer and M.H. Repacholi, 2007. Workgroup report: Base stations and wireless networks-radiofrequency (RF) exposures and health consequences. *Environ. Health Perspect.*, 115 (3): 416-424.