

## Testicular Pathologic Changes in Relation to Serum Concentrations of Testosterone in *Trypanosoma Vivax*-Infected White Fulani Bulls

<sup>1</sup>S. Adamu, <sup>1</sup>M.Y. Fatihu, <sup>1</sup>N.M. Useh, <sup>1</sup>N.D.G. Ibrahim, <sup>2</sup>M. Mamman, <sup>3</sup>V.O. Sekoni and <sup>1</sup>K.A.N. Esievo

<sup>1</sup>Department of Veterinary Pathology and Microbiology, Faculty of Veterinary Medicine,  
 Ahmadu Bello University, Zaria, Nigeria

<sup>2</sup>Department of Physiology and Pharmacology, Faculty of Veterinary Medicine,  
 Ahmadu Bello University, Zaria, Nigeria

<sup>3</sup>Department of Animal Reproduction, National Animal Production Research Institute, Shika, Nigeria

**Abstract:** In order to investigate whether testicular pathologic changes reported in trypanosome-infected animals are related to declining testosterone concentrations or not, four White Fulani bulls (infected group) with similar ages and weights were infected with *Trypanosoma vivax* (*T. vivax*), Kudara stock, by inoculating each, intravenously, with 2 mL of blood from an infected donor calf containing  $2 \times 10^6$  *T. vivax* organisms. Three other White Fulani bulls, with ages and weights similar to those of the infected group, which were uninfected, served as control group. Blood samples were collected from animals in the two groups before and after the infection to determine Packed Cell Volume (PCV) and serum testosterone profile. To carry out histopathological studies on the testes and other organs in the body of these animals, one bull from the infected group was sacrificed on day 14 Post-Infection (PI), while two bulls (one each from the infected and control groups) were sacrificed, each, on days 28, 56 and 84 PI. All animals in the infected group were parasitaemic by day 6 PI. This was followed by a gradual and progressive decrease in the values of Packed Cell Volume (PCV) and serum testosterone concentrations in these animals. PI values of these parameters in the control group remained normal relative to the pre-infection ones. The mean PI testosterone concentrations, measured in  $\text{ng mL}^{-1}$ , in individual bulls of the infected group sacrificed on days 14, 28, 56 and 84 were  $9.6 \pm 4.2$ ,  $7.8 \pm 3.7$ ,  $4.9 \pm 4.1$  and  $5.0 \pm 3.4$ , respectively. Histopathologically, severe testicular degeneration was observed in all animals in the infected group characterized by necrosis and depletion of the spermatogenic and sertoli cells in the seminiferous tubules. Leydig cells in the interstitial tissues of the testes were also severely degenerated. Severity of the lesions was related to serum testosterone concentrations as testicular degeneration was progressive from the bull that was sacrificed on day 14 PI moving through to the bull that was sacrificed on day 56 PI which had the least mean PI testosterone concentration and in which both spermatogenic and sertoli cells had undergone karyolysis and so were completely depleted. In contrast, testes of bulls in the control group were normal as both seminiferous tubules and interstitial tissues of the testes contained full complement of the spermatogenic and Leydig cells, respectively. It is concluded from this study that lowering testosterone concentration may be an aggravating factor to the degenerative changes observed in the testes of trypanosome-infected male animals.

**Key words:** Trypanosomosis, testicular degeneration, white fulani bulls, *Trypanosoma vivax*, testosterone

### INTRODUCTION

Animal trypanosomosis, caused in tropical Africa mainly by *Trypanosoma vivax* (*T. vivax*), *T. congolense* and *T. brucei*, has continued to be the greatest obstacle to livestock production in the region<sup>[1]</sup>. Amongst the different livestock species, cattle are the most exposed to hazard of contracting the disease. This is because their grazing requirement compels them to traverse different vegetation zones, many of which are tsetse-infested. This

reason, coupled with the immense economic importance of the disease, possibly, explains why trypanosomosis research has over the years been focused mainly on the effects of the disease on cattle.

Reproductive disorders are some of the most consistent clinical features of both human and animal trypanosomoses<sup>[2-4]</sup>. However, little effort has been made to investigate the pathophysiology of their development. Testicular degeneration and deterioration of semen characteristics that could lead to infertility or even

sterility, in extreme conditions, have been reported in trypanosome-infected male animals<sup>[5-8]</sup>, while some reports have indicated a reduction in plasma concentrations of Luteinizing Hormone (LH) and testosterone<sup>[9-13]</sup>.

Testosterone is known to play a trophic role in the function of the testis during spermatogenesis<sup>[14-16]</sup>. The observed testicular degeneration and deterioration of semen characteristics in the trypanosome-infected animals may be attributable, at least in part, to the lowering plasma testosterone levels caused by the infection. Conversely, studies conducted on the effects of trypanosomosis on the functional status of the testis were either focused on histopathology or determination of the hormonal profile only. There is the need to conduct a concurrent study on the two in order to elucidate the possible effects of the decline in serum levels of testosterone on the functional status of the testes. The objective of this study, therefore, was to investigate whether the degree of testicular degeneration is related to the declining serum concentration of testosterone in *T. vivax*-infected bulls.

## MATERIALS AND METHODS

**Experimental animals:** Seven healthy bulls of the White Fulani breed exhibiting good libido, as shown by their attempts to mount females in their midst, with ages ranging between 2½ and 3 years were selected and purchased from a local market and used for this study. History revealed that these animals were raised in a local farm situated in Anchau, an apparently tsetse-free area, in Kaduna State of Northern Nigeria. On arrival, they were accommodated in a fly-proof concrete animal house and fed daily on groundnut hay, green pasture, concentrate ration and salt licks. Water was provided *ad libitum*. The bulls were dewormed with albendazole® (Pantex B.V., Holland) at 5 mg kg<sup>-1</sup> body weight and sprayed against external parasites with diazinon (Diazintol®, Alfasan International B.V., Holland). The animals were allowed to acclimatize for six months during which they were exposed to routine examination and collection of blood samples three times a week for parasite screening and haematological studies.

***T. vivax* stock:** The *T. vivax* used in this study was an isolate from a natural infection of a cow in Kudaru, a village in Northern Nigeria. This parasite was identified and confirmed to be *T. vivax* using morphological characteristics<sup>[17]</sup>. Blood from the infected cow was inoculated into a donor calf in which parasitaemia was detected 4 days post-infection.

**Animal grouping and infection with *T. vivax* Kudaru stock:** The bulls were on the day of infection allocated to two groups of 4 infected and 3 control animals. These groups were closely matched on the basis of live mass (infected 198.0±9.4 kg, control 191.5±10.1 kg). Each bull in the infected group was injected intravenously with 2 mL of blood from the donor calf containing 2.0 × 10<sup>6</sup> *T. vivax* organisms. The number of trypanosomes was estimated by the method described by Paris *et al.*<sup>[18]</sup> as modified by Mutayoba *et al.*<sup>[12]</sup>.

**Clinical and routine blood examinations:** Beginning from the day of infection all animals in the infected group were observed for changes in demeanor and general body condition. Starting from 5 days before infection, blood (2 mL) was collected every other day from each of the infected and control animals for the estimation of Packed Cell Volume (PCV) using standard microcapillary method. After the infection, jugular blood samples were collected daily and examined for parasitaemia using buffy coat dark ground method<sup>[19]</sup>. After parasitaemia detection, blood samples were taken every other day for parasitaemia levels and PCV estimations. Trypanosomes were estimated according to the modified scoring method<sup>[12]</sup>.

**Blood sampling for serum testosterone measurement:** Beginning 5 days before infection, blood sample (3 mL) was collected from each of the infected and control animals every other day, including the day of infection, by jugular venepuncture. Samples were collected at a fixed hour on each day of sampling (6.00-7.00 am) as recommended<sup>[20]</sup>. The blood was allowed to clot and serum expressed. This was followed by centrifugation at 1500 g at room temperature for 10 min. Serum was decanted and stored in vials at -20°C until needed for testosterone assay.

Serum testosterone was measured using microwell testosterone enzyme immunoassay (Microwell testosterone EIA) kit (Syntron Bioresearch, Inc., Carlsbad, USA). The sensitivity of the assay was 0.1 ng mL<sup>-1</sup>, while the intra-assay and inter-assay coefficients of variation were 10.2 and 10.4, respectively.

**Histopathological studies:** One bull in the infected group was sacrificed on day 14 Post-Infection (PI) while two bulls, one from the infected and the other from the control groups, were sacrificed each on days 28, 56 and 84 PI. Tissue samples were collected from the testes of these animals and preserved in Bouin's solution. These were processed according to standard histological techniques<sup>[21]</sup> and stained with haematoxylin and eosin.

The presence and conditions of germinal epithelia and sertoli cells of the testis were studied microscopically. Testicular lesions were graded according to the method described by Sekoni *et al.*<sup>[7]</sup>

**Statistical analyses:** Values of individual parameters (serum testosterone and PCV) from both infected and control White Fulani bulls were pooled together as pre- and PI means. The latter values of serum testosterone in the *T vivax*-infected group were represented in a bar chart. Comparison of the mean values for infected with those of control was done using Student's t-test<sup>[22]</sup>.

**RESULTS**

**Parasitaemia:** Trypanosomes were first detected in the blood of infected bulls on day 4 PI. By day 6 PI, all animals had developed parasitaemia. Parasitaemia was intermittent in individual animal of the infected group. The control group remained aparasitaemic throughout the

course of the experiment. A mean parasitaemia of 3+, representing  $5 \times 10^4$  trypanosomes per milliliter of blood was obtained while parasitaemia peak of 6+, representing more than  $5 \times 10^6$  trypanosomes per milliliter of blood, was recorded on day 8 PI. Thereafter, moderate to mild parasitaemia was obtained up to time the experiment was terminated.

**PCV:** The pre-infection mean PCV in the control and infected White Fulani bulls were  $28.1 \pm 1.0\%$  and  $29.0 \pm 0.5\%$ , respectively. Following infection, there was progressive decrease in PCV in the infected group and by day 20 PI, the mean PCV value in this group had dropped to  $16.0 \pm 2.9\%$ . Thereafter, the mean PCV gradually rose and by day 30PI, it had risen to  $18.0 \pm 0.6\%$ . The mean PCV in control group remained normal relative to the pre-infection value throughout the course of the experiment. The pooled mean PI PCV in the infected bulls ( $19.3 \pm 0.5\%$ ) was significantly different ( $p < 0.05$ ) from that of the control bulls ( $27.3 \pm 1.5\%$ ).

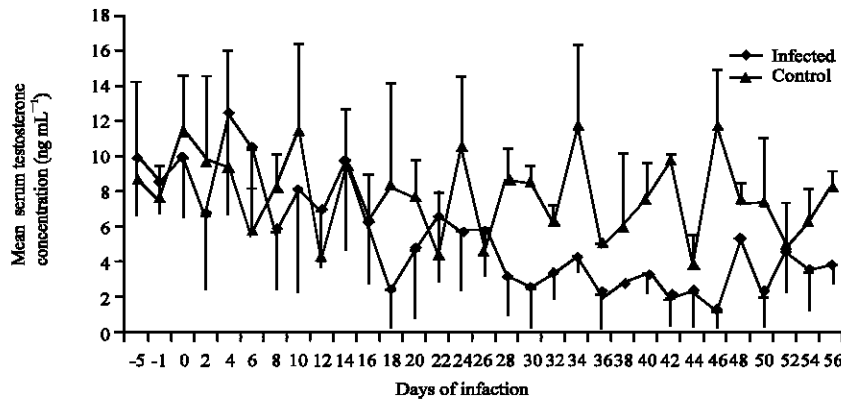


Fig. 1: Mean ( $\pm$ SD) serum testosterone profile in *T. vivax*-infected and control White Fulani bulls

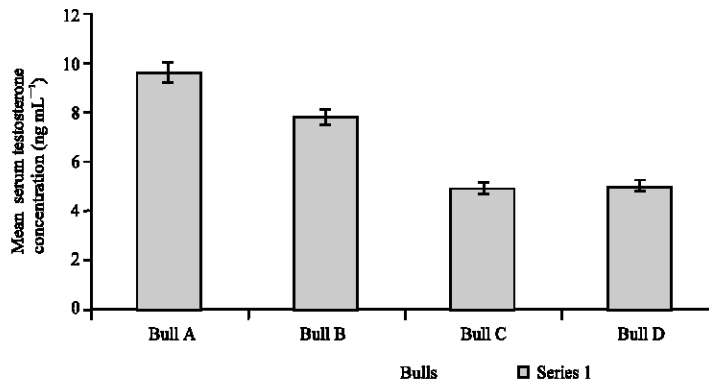


Fig. 2: Mean ( $\pm$ SD) serum testosterone concentration in individual bulls of the infected group Bull A = Bull sacrificed on day 14 post-infection, Bull B = Bull sacrificed on day 28 post-infection, Bull C = Bull sacrificed on day 56 post-infection, Bull D = Bull sacrificed on day 84 post-infection

**Serum testosterone levels:** Testosterone secretion was characteristically episodic in both infected and control bulls Fig. 1. The serum testosterone concentration in the control bulls remained within a range of 0.8 to 18.0 ng mL<sup>-1</sup> (10.8±1.6 ng mL<sup>-1</sup>), with peak values ranging from 15 to 18 ng mL<sup>-1</sup>, throughout the period of experiment. A gradual and progressive decrease in serum testosterone concentration was however observed in the *T. vivax*-infected bulls. The PI mean concentrations of testosterone in individual bulls of the infected group sacrificed on days 14, 28, 56 and 84 are presented in Fig. 2.

**Histopathological findings:** Testes of the control bulls were normal as seminiferous tubules contained full complement of spermatogenic and sertoli cells. Similarly,

Fig. 5: Cross-section of the testis of the *T. vivax*-infected White Fulani bull that was sacrificed 28 days post-infection. Note that spermatogenic cells here were more depleted than in the testis in Fig. 4 (H and E×250)

Fig. 3: Cross-section of the testis of a control White Fulani bull showing seminiferous tubules and interstitial tissue ,respectively containing full complement of the spermatogenic and Leydig cells (H and E...)

Fig. 6: Cross-section of the testis of the *T. vivax*-infected White Fulani bull that was sacrificed 56 days post-infection showing the most severe testicular degeneration with seminiferous Tubules (T) completely depleted of spermatogenic cells. Note the vacuolation (arrow) in the germinal epithelium. (H and E× 250)

Fig. 4: Cross-section of the testis of the *T. vivax*-infected White Fulani bull that was sacrificed 14 days post-infection. Note the hypoplasia as a result of the degeneration and subsequent depletion of spermatogenic cells (H and E×250)

interstitial tissues of the testes contained full complement of Leydig cells Fig. 3. Severe testicular degeneration was however observed in the testes of all the infected bulls, which was characterized by depletion of spermatogenic cells. Severity of the lesions increased with duration of the infection and with decreasing testosterone levels Fig. 4, 5 and 6 except in the bull that was sacrificed on day 84 PI Fig. 7 in which case the degree of the testicular degeneration was similar to that observed in the bull that was sacrificed on day 14 PI. Testicular degeneration was most severe in the bull that was sacrificed on day 56 PI Fig. 6. In this bull, spermatogenic and the sertoli cells in the testis were completely destroyed. Leydig cells in the interstitial tissue of the testis were also destroyed.

Fig. 7: Cross-section of the testis of the *T. vivax*-infected White Fulani bull that was sacrificed 84 days post-infection showing testicular degeneration of comparable degree to that of the testis in Fig. 4 (H and E×250)

### DISCUSSION

It is evident from this study that the severity of degeneration in seminiferous tubules of the testes of infected bulls is related to the decreasing levels of testosterone. The most severe lesions were observed in the bull that had the least PI mean testosterone concentration. This was in contrast to the observation made in the control group which had normal testes and in which testosterone profile remained normal throughout the course of the experiment. The observation made in this study of the progressive decline in testosterone concentrations in the *T. vivax*-infected White Fulani bulls seems to confirm earlier reports that trypanosomosis is associated with impairment of testicular steroidogenesis<sup>[9,11,12]</sup>. As testosterone plays an important trophic role in the function of the testis during spermatogenesis, it is probable that the progressive decrease in testosterone levels caused by the infection contributed to the degenerative changes observed in the seminiferous tubules with subsequent depletion of spermatogenic cells which was most severe in the bull that had the least value PI mean testosterone concentration. Trypanosome infection has been shown to cause rapid degeneration of primary and secondary spermatocytes<sup>[5,7,3]</sup>. The degeneration and the subsequent depletion of spermatogenic cells in the seminiferous tubules of the testes of infected bulls may partly be attributable to the decline in testosterone levels since sufficient secretion of this hormone is essential for normal spermatogenesis<sup>[15,16]</sup>. The pathophysiological mechanisms that result in the development of testicular dysfunction in trypanosomosis are not quite understood. The possibility that pituitary damage during trypanosome infection may result in testicular dysfunction due to reduced Luteinizing (LH) Hormone secretion<sup>[23,24]</sup> has been negated by previous reports<sup>[11,12]</sup> in which it was observed

that pituitary response to exogenous Gonadotrophin Releasing Hormone (GnRH), measured by LH response, was not impaired in trypanosome-infected animals at any stage of the experiment. This would strongly suggest that the observed decline in spontaneous LH secretion after the infection, as contained in their reports, was not due to impaired pituitary function per se but to defect in hypothalamic GnRH secretion or transport. In the same studies, however, testicular responsiveness, as measured by testosterone response to GnRH-induced LH stimulation, was decreased in infected animals.

Although the dynamic changes in GnRH and LH secretions were not investigated in the present study, the simultaneous reductions in plasma LH and testosterone<sup>[11,12]</sup> and the reduction in serum testosterone observed in the present study are more likely to occur when there is a reduction in the secretion or release of hypothalamic GnRH<sup>[25]</sup>.

Anoxia has been incriminated in the development of most tissue degenerative changes observed in trypanosome-infected animals<sup>[26]</sup>. It is, thus, an important factor that plays an important role in the development of testicular dysfunction in trypanosome-infected animals. As testis is an oxygen-dependent organ<sup>[27]</sup>, anaemia that accompanies trypanosomosis is more likely to inflict more injurious effects on testicular tissue than any other factor. The importance of oxygen in the steroidogenic function of the testis is further evidenced by the high vascularization of its interstitial tissue in which Leydig cells, the testosterone-producing cells of the testis, are found<sup>[28]</sup>. Hence, decreased testosterone secretion in trypanosome-infected animals may be the result of anoxia-induced degenerative changes in the Leydig cells. Several other factors might have been involved in the development of testicular dysfunction in trypanosome-infected animals that include capacity of the pathogenic trypanosome to cause extensive tissue and organ damage; release of biologically active and toxic substances; physical swelling and disruption of tissue architecture; pyrexia and increased vascular permeability<sup>[29,3]</sup>.

### CONCLUSION

In conclusion, this study has demonstrated that lowering testosterone concentration may be an aggravating factor to the degenerative changes observed in the testes of trypanosome-infected animals.

### ACKNOWLEDGMENT

The authors are grateful to the Board of research of Ahmadu Bello University, Zaria, Nigeria for partly funding the research. We also appreciate the technical assistance of Mr A. Adaji, Late A. Olonotola and Late G. Akaa, all of

the Department of Veterinary Pathology and Microbiology, Ahmadu Bello University, Zaria, Nigeria and Mr Ngozi Oburo of the Federal Medical Centre, Asaba, Nigeria.

## REFERENCES

1. Irungu, P., S.O. Nyamwaro and D.K. Masiga, 2002. Financial Implications of Rearing Sheep and Goats Under Natural Trypanosomosis Challenge at Galana Ranch, Kenya. *Trop. Anim. Hlth. Prod.*, 34: 503-513.
2. Ikede, B.O., E. Alhassan and S.O. Akpavie, 1988. Reproductive disorders in African animal trypanosomosis: A review. *Acta Trop.*
3. Sekoni, V.O., 1994. Reproductive disorders caused by animal trypanosomosis: A review. *Theriogenol.*, 42: 557-570.
4. Bawa, E.K., V.O. Sekoni, S.A.S. Olorunju, K.A.N. Esievo, D.V. Uza, D. Ogwu and E.O. Oyedipe, 2005. Comparative Clinical Observations on Trypanosoma vivax Infected Pregnant Yankasa and West African Dwarf Ewes. *J. Anim. Vet. Adv.*, 4: 630-636.
5. Kaaya, G. and Oduor-Okelo, 1980. The effects of *T. congolense* infection on the testis and epididymis of the goat. *Bull. Anim. Hlth. Prod. Afr.*, 28: 1-5.
6. Akpavie, S.O., B.O. Ikede and G.N. Egbunike, 1987. Ejaculate characteristics of sheep infected with *T. brucei* and *T. vivax*: changes caused by treatment with diminazene aceturate. *Res. Vet. Sci.*, 42: 1-6.
7. Sekoni, V.O., C.O. Njoku, J. Kumi-diaka and D.I. Saror, 1990. Pathological changes in male genitalia of cattle infected with *T. vivax* and *T. congolense*. *Bri. Vet. J.*, 146: 181-185.
8. Omeke, B.C.O. and G.I. Onuora, 1992 Comparative effects of *T. brucei* and *T. congolense* infections on reproductive capacity of boars in tsetse endemic zone. *Anim. Rep. Sci.*, 27: 225-237.
9. Adeyemo, O., A.O. Oyejide and O. Agbedana, 1990. Plasma testosterone in *T. congolense* and *T. brucei*-infected WAD rams. *Anim. Rep. Sci.*, 22: 21-26.
10. Soudan, B., D. Tetert, P. Degand and A. Boersma, 1992. Decrease in testosterone levels during an experimental African trypanosomiasis: Involvement of testicular LH receptors desensitization. *Acta Endoc.*, 127: 86-92.
11. Boly, H., P. Humblot, Y. Tilliet and M. Thibier, 1994. Effects of *T. congolense* infection on the pituitary gland of Baoule bulls: Immunohistochemistry of LH and FSH secreting cells and response of plasma LH and testosterone to combined dexamethasone and GnRH treatment. *J. Rep. Fer.*, 100: 157-162.
12. Mutayoba, B.M., P.D. Eckersall, I.A. Jeffcoate, H. Cestnik and P.H. Holmes, 1994. Effects of *T. congolense* infection in rams on the pulsatile secretion of LH and testosterone and response to injection of GnRH. *J. Rep. Fer.*, 102: 425-431.
13. Adamu, S., M.Y. Fatihu, N.M. Useh, M. Mamman, V.O. Sekoni and K.A.N. Esievo, 2004. Effect of experimental Trypanosoma vivax infection on serum testosterone levels in White Fulani bulls: A preliminary report. *Sok. J. Vet. Sci.*, 6: 14-17.
14. Karg, H., T. Gimenez, L.M. Hurt, B. Hofmann, E. Schallenberger and D. Shams, 1976. Testosterone, Luteinizing Hormone (LH) and Follicle Stimulating Hormone (FSH) in peripheral plasma of bulls. *Zentr. Veterinarmed.*, 23: 793-803.
15. Setchell, B.P., 1978. Endocrinology of testis In: B.P. Setchell (Ed.), *The mammalian testis*. Paul Elek, London. pp: 234-240.
16. Camerone, D.F., K.E. Muffy and J. Naziam, 1993. Testosterone stimulated spermatid binding to competent sertoli cells in vitro. *Endoc. J.*, 1: 61-65.
17. Soulsby, E.J.L., 1968. Helminths, Arthropods and Protozoa of Domesticated Animals. The Williams and Wilkins Company, Baltimore, USA., pp: 1-809.
18. Parris, J., M. Murray and F. McOdimba, 1982. A comparative evaluation of parasitological techniques currently available for the diagnosis of African trypanosomiasis in cattle. *Acta Trop.*, 39: 307-316.
19. Murray, M., P.K. Murray and W.I.M. McIntyre, 1977. An improved parasitological technique in the diagnosis of African trypanosomiasis. *Trop. Med. Hyg.*, 75: 325-326.
20. Sanwal, P.C., A. Sundby and L.E. Edquist, 1974. Diurnal variation of peripheral plasma levels of testosterone in bulls measured by rapid radioimmunoassay. *Acta Vet. Scand.*, 15: 90-99.
21. Humason, G.L., 1962. In: *Animal Tissue techniques*. Freeman and Company, pp: 11-13.
22. Steel, R.G.D. and J.G. Torrie, 1980. *Principles and Procedures in Statistics*, 2nd Ed., McGraw-Hill, New York, pp: 782-789.
23. Apted, P.I.C., 1970. Clinical manifestations and diagnosis of sleeping sickness In: E.W. Mulligan and W.H. Potts (Eds.), *The African trypanosomiasis*. Allen and Unwin, London, pp: 661-668.
24. Ikede, B.O. and G.J. Losos, 1975. Pathogenesis of *T. brucei* infection in sheep; hypophyseal and other endocrine lesions. *J. Comp. Pathol.*, 85: 37-44.
25. Jeffcoat, I.A., J.M.S. Lucas, and D.B. Crichton, 1982. Effects of active immunization of ram lambs and bull calves against synthetic LH-releasing hormone. *Theriogenol.*, 18: 65-67.

26. Logan-Henfrey, L.L., P.R. Gardiner and M.M. Mahmoud, 1992. In: J.P. Kreier and J.R. Baker (Eds.), *Par. Prot.*, 2: 157-275.
27. Markey, C.M., A.M. Jeqvier, J.T. Meyer and G.B. Martin, 1994. Testicular morphology and androgen profiles following testicular ischaemia in ram. *J. Rep. Fer.*, 102: 643-650.
28. Dellmann, H.D. and M. Wrobel, 1976. Male reproductive system In: H.D. Dellmann and E.M. Brown (Eds.), *A Textbook of Veterinary Histology*. Lea and Fabiger, Philadelphia, pp: 293-300.
29. Sileghem, M.R., S.R. Flynn and D.J.Z. Williams, 1993. Secretion of co-stimulatory cytokines by monocytes and macrophages during infection with *T. congolense* in susceptible and trypanotolerant cattle. *Vet. Immunol. Immunopathol.*, 37: 123-134.