

A Case Report of *Cheyletiella* Infestation on a Terrier Dog in Tabriz, Iran

M.H. Movassagh Ghazani, A.R. Karami, J. Dolgharisharf, M. Khajeh and K. Najafian
Faculty of Veterinary Medicine, Islamic Azad University, Shabestar Branch, Iran

Abstract: This study is a clinical case report of *Cheyletiella* infestation on a white terrier dog born and raised in Tabriz, Iran. The dog was referred to small animal clinic of Islamic Azad University, Tabriz Branch. In clinical examination of a 2 years old female Terrier, multiple white dandruff-like flakes were seen on the hair coat, especially over the neck. The dog was in good physical condition except the coat appeared to be somewhat dry. Microscopic examination of a skin by tape impression method revealed an infestation of *Cheyletiella yasguri*.

Key words: *Cheyletiella yasguri*, dermatitis, dog, Tabriz

INTRODUCTION

The description of mites belonging to the genus *Cheyletiella* dates back to 1875 when Megnin (Ayalew and Vaillancourt, 1976) first found them on the rabbit (*Oryctolagus cuniculus*) in France. These mites were assigned to the species *C. parasitorax* (Ayalew and Vaillancourt, 1976). *Cheyletiella* have since been reported on dogs, cats, foxes and badgers. The pathogenicity of this mite for both the dog and man has already been established by other authors. The infestation of the dog with *Cheyletiella* was first reported by Kuschner (Ayalew and Vaillancourt, 1976) in Austria and similar reports from other parts of the world have been increasing. Gething (1973) presents a review of these infestations. The disease caused by *Cheyletiella* mites is often called walking dandruff. On close observation of an infested dog, cat, or rabbit, it may be possible to see movement of the dandruff on the skin. The movement is caused by the mites motoring around under the scales (Ayalew and Vaillancourt, 1976).

Until recently, though, *Cheyletiella* removed from dogs have been assumed to be long to species *C. yasguri*, *C. parasitivorax* being retained for that found on rabbits. Thus, in most reports of *Cheyletiella* on dogs subsequent to Smiley's research, the mites have been described as *C. yasguri* (Ayalew and Vaillancourt, 1976; Baker, 1969; Dodd, 1970; Ewing *et al.*, 1967). *C. yasguri* is the common species affecting dogs, while *Cheyletiella parasitivorax* is the species found on rabbits. Both species of mites can interchangeably transfer to man, dogs, cats and rabbits. It is not yet clear how long the mites survive on another host. Human infestations vary

in severity, but after direct contact with infested animals, grouped, erythematous macules form on the trunk and buttocks. These rapidly develop a central papule which becomes vesicular and then pustular, finally rupturing to produce a yellow crusted lesion which is frequently excoriated because of the intense pruritus. Although, the lesions are severely inflamed, they are well demarcated from surrounding skin. Older lesions have an area of central necrosis which is highly diagnostic (Gething, 1973).

There has been much dispute as to whether or not *C. yasguri* (*parasitivorax*) behaves as a harmful parasite on dogs. Most of the accumulated evidence shows that *Cheyletiella* does induce skin lesions in dogs; variously described as cutaneous exfoliation, scurf or dandruff accompanied by intense scratching (Ayalew and Vaillancourt, 1976; Brockis, 1971). Furthermore, *Cheyletiella* has been incriminated in skin lesions of human beings in contact with infested dogs (Ayalew and Vaillancourt, 1976; Bakkers and Fain, 1972; Bjarke *et al.*, 1973; Brockis, 1971; Davis and Kyle, 1969; Dodd, 1970; Savik *et al.*, 2004). In Canada the first report was made by Maclulich (Ayalew and Vaillancourt, 1976), who removed *Cheyletiella* from hares in Ontario. Shin (1996) reported the *Cheyletiella* infestation on a Whippet dog in Korea.

Information on *Cheyletiella* infestation of animals in Iran is unknown. The aim of this study was to point out the importance of mites from the *Cheyletidae* family as etiological agents in a case report of the dermatological manifestation in dog. The objective was to orient future research toward a better understanding of the biology and interaction of these mites with dogs.

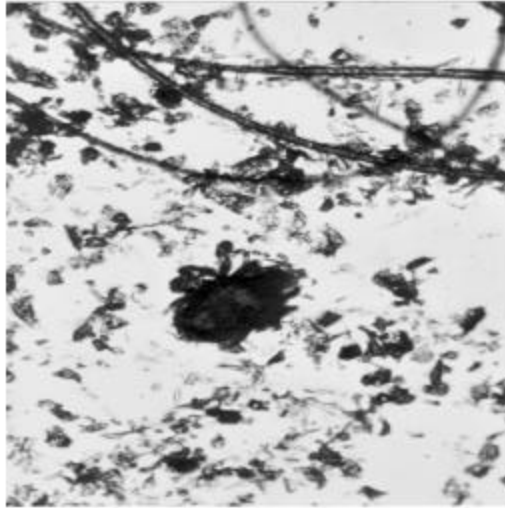


Fig. 1: Adult *Cheyletiella yasguri* ×15

CASE REPORT

This study is a clinical case report of *Cheyletiella* infestation on a white Terrier dog born and raised in Tabriz, Iran. The dog was referred to Small Animal Clinic of Islamic Azad University, Tabriz Branch on June 2003. In clinical examination of a 2 years old female Terrier, multiple white dandruff-like flakes were seen on the hair coat, especially over the neck. The dog was in good physical condition except the coat appeared to be somewhat dry. Microscopic examination of a skin by tape impression method revealed a infestation of *Cheyletiella yasguri*, as identified by the presence of hooks of the palpi and heart-shaped sensory organ on genu I (Fig. 1).

DISCUSSION

In diagnosis of *Cheyletiella* infestation, morphological identification of adult mites from skin scraping is made on the basis of heavy curved palpal claws and a comb like tarsal appendage at the distal end of each leg. The heart shaped sense organ on genu I indicates the species to be *C. Yasguri*. The adult mite is yellow and measures 466-500 microns long by 300-320 microns wide. Mite eggs may be fastened to hairs by loosely woven cocoon-like strands. Some eggs be free among skin debris or even passed in feces if the dog has been licking at the lesions (Ayalew and Vaillancourt, 1976; Ewing *et al.*, 1967). Eggs are nonoperculate, elliptical in shape and approximately 190-260 microns long by 110-140 microns wide. Inside, their contents vary from a developing cytoplasmic mass to a recognizable mite larva with 6 folded legs. Extending through, the blunt pole of

fully developed eggs, a lancet-shaped hornlike process is visible. This unusual structure remains with the eggshell after hatching and possibly aids the larva in breaking through, the shell.

Until recently, *Cheyletiella* sp. removed from dogs in different countries have been assumed to be *C. parasitivorax*. In 1965, however, Smiley (Ayalew and Vaillancourt, 1976) described a new species, which he named *C. Yasguri* from dogs in the U.S.A. Subsequent to Smiley's work, *Cheyletiella* recovered from dogs have been usually described as *C. yasguri* (Ayalew and Vaillancourt, 1976; Bakkers and Fain, 1972; Davis and Kyle, 1969; Dodd, 1970; Ewing *et al.*, 1967) with *C. parasitivorax* by a few (Ayalew and Vaillancourt, 1976; Bjarke *et al.*, 1973; Brockis, 1971). *C. Yasguri* has been recorded mostly from dogs. It is tentatively held that the dog is the natural host for *C. Yasguri*, while *C. parasitivorax* parasitizes rabbits. The behavior of *Cheyletiella* on dogs has been subject to much dispute for many years. *Cheyletiella* infestations are known to be more severe in young dogs (Ayalew and Vaillancourt, 1976; Dodd, 1970) than in adults, which may only be asymptomatic carriers. *Cheyletiella* are killed by most of the common insecticides used against fleas including pyrethrins, permethrins and organophosphates (Ayalew and Vaillancourt, 1976).

CONCLUSION

This case indicates adult carrier dogs without dermatitis as a source of infestation, themselves likely escaping diagnosis. These mites can temporarily infest humans causing a mild skin irritation and some itching. In severe cases, some open lesions may occur.

Human infestation may occur either by direct skin contact between man and animal or through clothing and most common site of infection is arms and torso.

ACKNOWLEDGMENT

We gratefully acknowledge the contribution of Dr. Ali Shabestari and Ali Movassagh Ghazani to this research.

REFERENCES

- Ayalew, L. and M. Vaillancourt, 1976. Observations on an outbreak of infestation of dogs with *Cheyletiella yasguri* and its public health implications. *Can. Vet. J.*, 17 (7): 184-191.
- Baker, K.P., 1969. Infestation of domestic animals with the mite *Cheyletiella parasitivorax*. *Vet. Rec.*, 84: 561.

- Bakkers, E.J.M. and A. Fain, 1972. Dermatitis in man and in a dog caused by the mite *Cheyletiella yasguri* Smiley. *Br. J. Dermatol.*, 87: 245-247.
- Bjarke, T., L. Hellgren and K. Orstadius, 1973. *Cheyletiella parasitivorax* dermatitis in man. *Acta Dermatovener.* Stockholm, 53: 217-224.
- Brockis, D.C., 1971. Scurf in dogs. *Vet. Rec.*, 89: 473.
- Davis, G.B. and M.G. Kyle, 1969. *Cheyletiella yasguri* infestation of a dog. *N.Z. Vet. J.*, 17: 136.
- Dodd, K., 1970. *C. yasguri*: Widespread infestation in a breeding kennel. *Vet. Rec.*, 86: 346-347.
- Ewing, S.A., J.E. Mosier and T.S. Foxx, 1967. Occurance of *Cheyletiella* sp. on dogs with skin lesions. *J. Am. Vet. Med. Ass.*, 151: 64-67.
- Gething, M.A., 1973. *Cheyletiella* infestation in small animals. *Vet. Bull.*, 43: 63-69.
- Savik, B.K., W. Bredal, T.L. Ulgteim, 2004. *Cheyletiella* infestation in the dog: Observations on diagnostic methods and clinical signs. *J. Small Anim. Prac.*, 45 (10): 495-500.
- Shin, S.S., 1996. A case report of *Cheyletiella* infestation on a Whippet dog in Korea. *Korean J. Parasitol.*, 34 (4): 267-271.