

## Ultrasonographic Findings in 25 Zebu Calves with Liver Fascioliasis

<sup>1</sup>S.M.A. Khogali, <sup>2</sup>R.M. Abdelghafar, <sup>1</sup>F.A. Omer and <sup>3</sup>M.S. Fadel

<sup>1</sup>Central Veterinary Research Laboratories Center,

<sup>2</sup>College of Veterinary Medicine and Animal Production,

Sudan University of Science and Technology,

P.O. Box 204, Hilat Kuku Khartoum North, Khartoum, Sudan

<sup>3</sup>Animal Reproduction Research Institute, Giza, Egypt

**Abstract:** Fasciola eggs were detected in fecal samples of 16 out of 25 local zebu calves. All animals had low hematocrit concentration (18%) and decreased hemoglobin (Hb) concentration ( $6.0 \text{ g dL}^{-1}$ ), while serum Bilirubin concentration within the normal range ( $0.2 \pm 0.1$ ). Ultrasonography of the liver was performed using 3.5 MHz convex probe (Proxima-Germany) and 6-8 MHz linear array transducer (Pie medical Holland) on the right side of the animals while they were in the standing position and well restrained. Area of scanning was clipped and shaved carefully and the animals were fasted for 14 h prior to the scanning. Ultrasonography revealed Normal liver size and texture in 5 calves (negative for Fasciola eggs) and different pathological changes in the other 20 calves. Four calves which were negative to Fasciola eggs showed hepatomegally with coarse texture, dilated gall bladder and intrahepatic bile ducts calcification. Ultrasound was found to be more reliable, rapid and accurate method for detecting hepatic pathology in bovine calves.

**Key words:** Ultrasound, bovine, liver fascioliasis, zebu calves

### INTRODUCTION

Fascioliasis is an economically important disease of domestic livestock, in particular, cattle and sheep and occasionally man. Fasciola gigantica is found on most continents primarily in tropical regions (Andrews, 1999). It is an economically important disease of ruminants' world-wide and especially in Europe, Asia and Africa where it causes significant morbidity and grave economic loss (Okewole *et al.*, 2000).

Fascioliasis in cattle, unlike in sheep is principally a chronic debilitating disease related to the anemia created by the blood sucking activities of the adult liver fluke in the bile duct (Armour and Bagon, 1982). It is the common and one of the major anemia causing helminth infections in the tropic (Mathewos *et al.*, 2001).

Ultrasonography is a non-invasive method for imaging of internal organs and is particularly useful for detecting hepatic pathology (Jian-xin and Carol, 1995). It has markedly enhanced the diagnosis of hepatic disease in cattle (Braun *et al.*, 1996). There are many indications for using ultrasonography of the liver, because the existing diagnostic methods for detecting liver diseases, such as the determination of hepato-specific enzymes, are

insufficient in many cases (Braun, 1990). In Sudan the White Nile state is known to be endemic with bovine Fascioliasis and to our knowledge no ultrasonographic methods were performed to detect and confirm liver Fascioliasis in the country.

The aim of the present study is to establish the ultrasonographic method of scanning the liver and to obtain sonographic features of naturally occurring hepatic Fascioliasis in bovine calves.

### MATERIALS AND METHODS

**Animals:** Local zebu calves ( $n = 25$ ) were involved in the study. Their ages were between 1-2 years and their weights were between 135-160 kg, they were delivered from the White Nile state and kept in the central laboratory research, they were severely emaciated and clinically not healthy. They were fed Abusabeen ad lib with free access to water.

#### Experimental technique

**Parasitological examination:** Fecal examination was done using the floatation method according to (Anon, 1977) for confirmation of Fasciola eggs.

**Corresponding author:** Rihab Mohamed Abdelghafar Osman, College of Veterinary Medicine and Animal Production, Sudan University of Science and Technology, P.O. Box 204, Hilat Kuku Khartoum North, Khartoum, Sudan

**Hematological examination:** Packed Cell Volume (PCV) and Hemoglobin (Hb) concentration were measured using the conventional methods described by Schalm (2000). Serum Bilirubin was measured using the method described by Malloy *et al.* (1973).

**Ultrasound:** Ultrasound was done using Real-time ultrasound machine (Proxima equipped with 3.5 MHz transabdominal convex probe) and (Pie medical machine equipped with 6.8 MHz linear probe) on the right side of the animal while the animal was standing and well restrained.

Animals were fasted for 14 h prior to the scanning area of scanning which extends from the 3rd last intercostal space and a hand breadth behind the last rib, was clipped and shaved carefully and liberal amount of ultrasonic gel was applied to the area. Each intercostal space was examined dorsally to ventrally with transducer held parallel to the ribs. The texture, visceral and diaphragmatic surface of the liver was scanned, portal, hepatic veins and biliary system were also examined.

**RESULTS**

The general condition of the animals was severely disturbed, with anemia and loss of condition. Fecal flotation test revealed *Fasciola* eggs in 16 out of 25 (64%) calves. Hematological examination revealed decreased hematocrit concentration (18%) and decreased (Hb) concentration ( $6.0 \text{ g dL}^{-1}$ ) in all animals.

Table 1: Showed calcification, dilatation of the gall bladder, liver size and texture in 25 calves

Anim ID	Calc.	Gb dil.	Cyst	Texture	Size
1	+	+	-	Coarse	Enlarged
2	+	+	-	Coarse	Enlarged
3	+	+	-	Coarse	Enlarged
4	-	-	-	Normal	Normal
5	+	+	-	Coarse	Enlarged
6	-	-	-	Normal	Normal
7	-	+	+	Coarse	Enlarged
8	-	+	-	Coarse	Enlarged
9	-	-	-	Normal	Normal
10	+	+	-	Coarse	Enlarged
11	-	+	-	Coarse	Enlarged
12	-	+	-	Coarse	Enlarged
13	+	+	-	Coarse	Enlarged
14	-	+	-	Coarse	Enlarged
15	-	-	-	Normal	Normal
16	-	+	-	Coarse	Enlarged
17	+	+	-	Coarse	Enlarged
18	-	+	+	Coarse	Enlarged
19	+	+	-	Coarse	Enlarged
20	+	+	+	Coarse	Enlarged
21	-	+	+	Coarse	Enlarged
22	-	+	-	Coarse	Enlarged
23	-	+	-	Coarse	Enlarged
24	-	+	+	Coarse	Enlarged
25	-	-	-	Normal	Normal

Key: - Negative, + Positive, Calc: Calcification, GB dil: Gall bladder dilatation, ID: Identity Number

Serum Bilirubin concentration was  $(0.2 \pm 0.1 \text{ nmol L}^{-1})$ . Ultrasonography of the liver revealed normal liver texture and size in 5 calves and different pathological changes in 20 calves as shown in Table 1. The diseased calves had enlarged liver with coarse texture and dilated hepatic veins (Fig 1), dilated gall bladder, 9 of them had calcified foci (Fig 2). Liver cyst was detected in 5 calves as shown in Fig. 3 and 4.

At necropsy, the liver was greatly enlarged with rounded edges, liver was solid in texture with a dark color and the gall bladder was greatly enlarged with thickened walls.

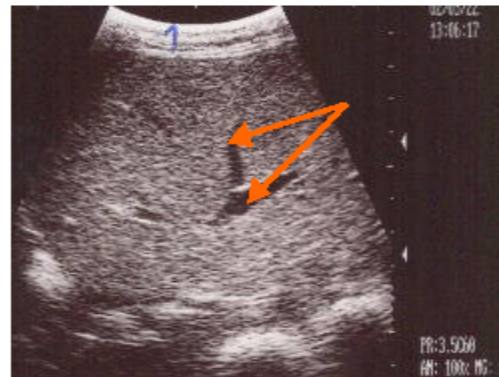


Fig 1: Enlarged liver with coarse texture and Dilated hepatic veins (Arrows)

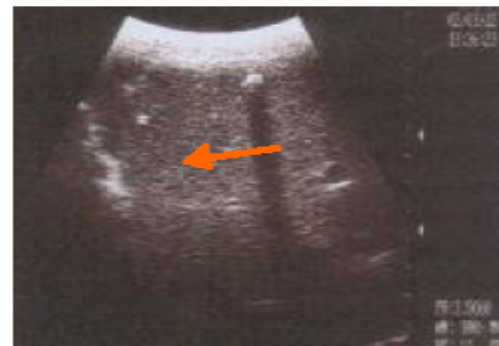

Fig 2: Intrahepatic bile duct calcification (Arrow) with distal acoustic shadowing

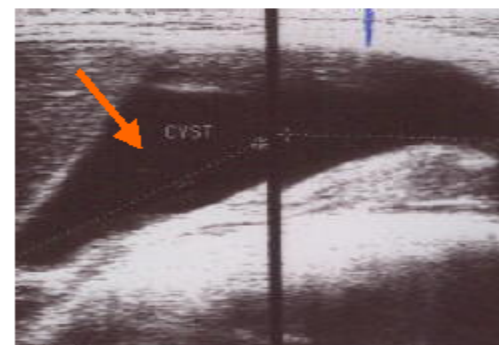


Fig. 3: Liver cyst (arrow) with distal enhancement

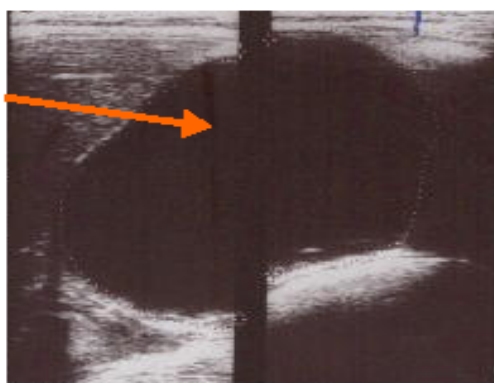


Fig. 4: Liver cyst (Arrow)

### DISCUSSION

Calves were obtained from the White Nile state which is known to be endemic with bovine liver Fascioliasis.

Faecal examination could detect fluke eggs in 16 out of 25 calves. In Fascioliasis in cattle few flukes reach the bile ducts and few eggs are passed, most flukes are lost by 30-50 weeks after infection Behm and Sangster (1999), so low number of eggs may be passed in faeces which may not be detected in faecal examination. Serum Bilirubin was insignificant in all animals, this is in agree with Behm and Sangster (1999) who reported that the occurrence of bilirubinaemia has been reported only occasionally e.g. in rats during the paranchymal stage and in sheep during both the paranchymal and biliary stages. Most studies in rats or sheep have reported no significant changes in serum Bilirubin concentration.

Hematological study revealed decreased (Hb) concentration and PCV this is in agree with Haroun *et al.* (1986), who reported decreased Hb concentration and PCV in infected cattle with *Fasciola gigantica* in an endemic area in the Sudan.

Ultrasonography revealed hepatomegally, dilated gall bladder with thickened walls and hepatic veins dilatation which could not be detected by other conventional methods, liver cyst was also found in 5 calves during the examination. Behm and Sangster (1999) reported that calcium deposition start to form in the duct walls after 19-20 weeks of infection, ultrasonographically intrahepatic bile ducts calcification which is seemed to be the most common feature in chronic bovine Fascioliasis was seen as highly echogenic circles with distal acoustic shadowing.

### CONCLUSION

In conclusion Ultrasonography was found to be most efficient, non- invasive and non-time consuming method for detection of liver Fascioliasis in bovine calves.

### ACKNOWLEDGEMENT

The authors would like to thank Dr Amel Omer Bakheit, department of pathology, parasitology and microbiology, Sudan University of Science and Technology (SUST) and Prof. Ahmed Abdelrahim Gameel, head department of pathology, University of Khartoum (U of K) for revising the manuscript.

### REFERENCES

- Andrews, S.J., 1999. The life cycle of *Fasciola hepatica* in Dalton, J.P. Fascioliasis. Cab International Wallingford Oxon OX10 8DE.
- Anon, 1977. Trends in mortality from cirrhosis and alcoholism. United States, MMWR, 35: 703-705.
- Amour, J. and J. Bagon, 1982. Diagnostic and therapeutic check list, anthelmintics for ruminants. Br. Vet. J., 138: 371-381.
- Behm, C.A. and N.C. Sangster, 1999. Pathology, pathophysiology and clinical aspects in Dalton, J.P. Fascioliasis. Cab International, Wallingford, Oxon OX10.
- Braun, U., 1990. Ultrasonographic examination of the liver in cows. Am. J. Vet. Res., Vol 51.
- Braun, U., N. Pusterla and K. Wild, 1996. Ultrasonographic examination of the liver and gall bladder in cows: Abnormal findings. Compendium, 13: 1255-1269.
- Haroun, E.M., H. Abdelgadir and A.A. Gameel, 1986. Studies on naturally- occurring bovine Fascioliasis in the Sudan. J. Helminthol, 60: 47-53.
- Jian-Xin, W.U. and H.C. Carol, 1995. Ultrasonographic examination of the canine liver based on recognition of hepatic and portal veins. Vet. Radiol. Ultrasound, 36: 234-239.
- Mathewos, Z., A. Getachew and J. Yilma, 2001. Observations on the effect of concurrent natural bovine trypanosome and *Fasciola* infections in kone area, western Ethiopia. Revue, Med. Vet., 152: 12,851-858.
- Okewole, E.A., G.A.T. Oqundipe, J.O. Adejinni and A.O. Okunyan, 2000. Clinical evaluation of three chemo prophylactic regimes against ovine helminthosis in a Fasciol- endemic farm in Ibadan, Nigeria. Israel J. Vet. Med., pp: 56.
- Schalm, O.W., N.C. Jain and E.J. Carroll, 1975. Veterinary Hematology 3rd Edn. Philadelphia, Lea and Febiger, USA.
- Varley, H., A.H. Gowerlock and M. Bell, 1984. Practical clinical biochemistry 5th Edn. Vol. 1. William Heinemann Medical Books, LTD, London.