

Growth Evaluation of Selected Digestive Organs from Day One to Four Months Post-Hatch in Two Breeds of Chicken Known to Differ Greatly in Growth Rate

¹Khalid K. Kadhim, ¹A.B.Z. Zuki, ²M.M. Noordin, ²S.A. Babjee and ³W. Khamas

¹Department of Veterinary Preclinical Sciences,

²Department of Veterinary Pathology and Microbiology, Faculty of Veterinary Medicine,
University Putra Malaysia, 43400 UPM, Serdang, Selangor, Malaysia

³Department of Anatomy and Histology, College of Veterinary Medicine, Western
University of Health Sciences, Pomona, CA 91766, USA

Abstract: The digestive organs of Malaysian Village Fowl (MVF) and Broiler Breed (BB) differ in body weight were studied grossly and histologically. Weight of digestive organs and length of small intestine were obtained from fifty male from each breed euthanased from first day after hatch to 4 months. At day 20 body weight of BB was five times greater than those of MVF. The differences between breeds for the weight of vitelline residue, proventriculus, gizzard, liver, pancreas, weight and length of small intestine segments for the absolute and relative to body weight at day one were also obtained. The liver, pancreas and intestinal segments of the two breeds showed increased in relative weight at the 10 days post-hatch and after that the relationship were reversed. At days 20-4 months post-hatch, all organs relative weight of MVF increased except jejunum in 56-120 days and ileum in 56 days. The same patterns observed for intestinal length in both breeds. Day one post-hatch relative lengths of all intestinal segments in MVF were higher than BB. The latter was dominantly showed larger proventricular glands, gizzard glands and gizzard lining membrane. In BB, the villi heights of intestinal mucosa were higher than that of MVF, except in ileum at days 20 and 56 post-hatch. The villus surface areas were constantly greater in BB, the crypt depths were greater in BB, except in 56 and 120 days. There were no different in thickness of muscularis externa in each intestinal segment at the day one and after the 20 days old.

Key words: Breed, chicken, digestive organ, growth rate, body weight

INTRODUCTION

Growth in bird has been investigated by Lilja (1983). The previous studies have examined patterns of growth in chickens (Siegel and Dunnington, 1987) and for various breeds of poultry (Dror *et al.*, 1977; Nitsan *et al.*, 1991; Uni *et al.*, 1998). The others have compared organ sizes, especially gut sizes of domestic chickens (Cherry *et al.*, 1987; Shires *et al.*, 1987; Nir *et al.*, 1993). Intestine dimensions and function were also studied in mice (Lidia *et al.*, 1998) and in broiler chicken (Iji *et al.*, 2000).

Most of these studies have emphasized comparison at a set point of age. The timing is standard for comparison which is commonly accepted method to examine differences in growth (Chambers, 1990). The vitelline residue complements nutrient intake for the first

few days post-hatch (Nitsan *et al.*, 1991). The weight of small intestine reported in domestic ducks at 5 weeks post-hatch were declined in spite of continuous rise of other digestive organs (Watkins *et al.*, 2004). The relative weight of the duodenum, jejunum and pancreas but not ileum was found to be higher in light breed than in heavy breeds (Dror *et al.*, 1977). The contributions of distinct physiological compartments of intestinal segments may be regarded as consisting of two major tissues. Firstly, the mucosa that is responsible for digestion, absorption and secretion (Karasova and Diamond, 1983). Secondly, a muscle layer that comprised of both circular and longitudinal muscles (Mitchell and Smith, 1991). Differences in growth rates correlated with changes in villus surface area however, the crypt size did not vary significantly between the high and low growth

rate (Smith *et al.*, 1990). Increased food intake through the small intestine is the most potent factor which, results in modification of the villus surface area (James *et al.*, 1988). The MVF is descendant from the south-east Asia jungle fowl (*Gallus bankiva*) through natural mating, its still keep in widespread under backyard production (Ramlah, 1996).

This breeds characterized by small body weight and slow growth rate vary in the external phenotype. To the knowledge, the growth of digestive organs in MVF has never been documented elsewhere. Thus, the study was carried out to evaluate the growth of digestive system on day one-four months post-hatch in two breeds of chicken known to differ greatly in growth rate. In addition, the villus architecture of the mucosal surface of small intestine was also examined histologically in each breed.

MATERIALS AND METHODS

Animals: Fifty-male Malaysian Village Fowl (MVF) and fifty male Broiler Breed (BB) were used for this study. The birds reared separately in cages with commercial feed and tap water provided *ad libitum*. Using the same feed and same rearing condition. The MVF eggs obtained from Jenderam Hulu, Sepang, Selangor, Malaysia were incubated and hatched within the UPM (University Putra Malaysia) farm. The broiler breed chick, commercial line selected for high body weight (Ross) were supplied by *CP (M) Private Limited hatchery (*Chareon Phophan (M) Private Limited, Kajang, Selangor, Malaysia).

Collection of tissue samples: Ten birds from each breed at days 1, 10, 20, 56 and 4 months were weighed and euthanased by intravenous (cutaneous ulnar vein) administration of sodium pentobarbitone (80 mg kg⁻¹) (Mitchell and Smith, 1991). Amid-line incision was made to expose the digestive organs. Collected specimens were vitelline residue, proventriculus, gizzard, small intestine, pancreas and liver.

These organs were washed with saline solution to remove blood and any other adhering debris. The small intestine was then divided into duodenum, jejunum and ileum, following the demarcation set by Mitchell and Smith (1990). The contents of each segments gently emptied by pressure. The weight of each separated organs recorded and the length of intestine was recorded.

Histology light microscope: Samples from each segment were taken for histological study. Specimens were fixed in 10% Bufferd Neutral Formalin (BNF) for 24 h and

processed using standard histological procedures. Tubular organs were embedded vertically in paraffin wax (Baddeley *et al.*, 1986). Sections of 3 µm thick were cut and stained with Hematoxyline and Eosin and Masson's trichrome (Bancroft and Gamble, 2002). Tissues were viewed on an Olympus image analysis (BX 51 TF, with attached CC 12 camera) for the measurement of proventricular glands, gizzard lining epithelium, gizzard glands, villus dimensions (villus height and villus surface area). The depth of individual crypts and the muscularis externa were also recorded.

Measurement of villi surface area: The dimension of intestinal villi determined until 10 days post hatch following the procedure suggested by Iji *et al.* (2001), for the remainder specimens.

Ten intact villi were selected from the mid point of each small intestinal segment under a dissecting microscope using fine hypodermic needles and mounted on microscopic slides with one drop of saline to prevent dehydration and conformation of villi. These villi were then flattened by gentle force with cover-slip and the edges of the cover-slip sealed with Tipp-Ex (Smith *et al.*, 1990).

The villi surface area were finally doubled, it being assumed that each villus consisted of two flat sheets bent to meet each other only in the region of the villus perimeter.

The height, width and surface area of these villi was determined by transferring image analysis. T test was used to compare the two groups at each age and for each observational unit. All data represented as a mean+SD, statistical significance was at $p < 0.05$.

RESULTS AND DISCUSSION

Macroscopic evaluation: The pattern of total body weight in BB (Fig. 1) showed a gradual increase from day 1-20 post-hatch, however at day 20 and day 56 post-hatch there were marked increased ($p < 0.05$) approximately four and five times, respectively than that of MFV. In MVF, the body weight increased slowly and not at the same rate as in BB. At one day old, the weights of vitelline residue both absolute and relative to body weight were greater in MVF than BB.

The absolute organs weights in all age groups were consistently greater ($p < 0.05$) in the BB as compared to MVF. In MVF the organs weights increased slowly to persist in the same rate during the period of the study (Fig. 1-3).

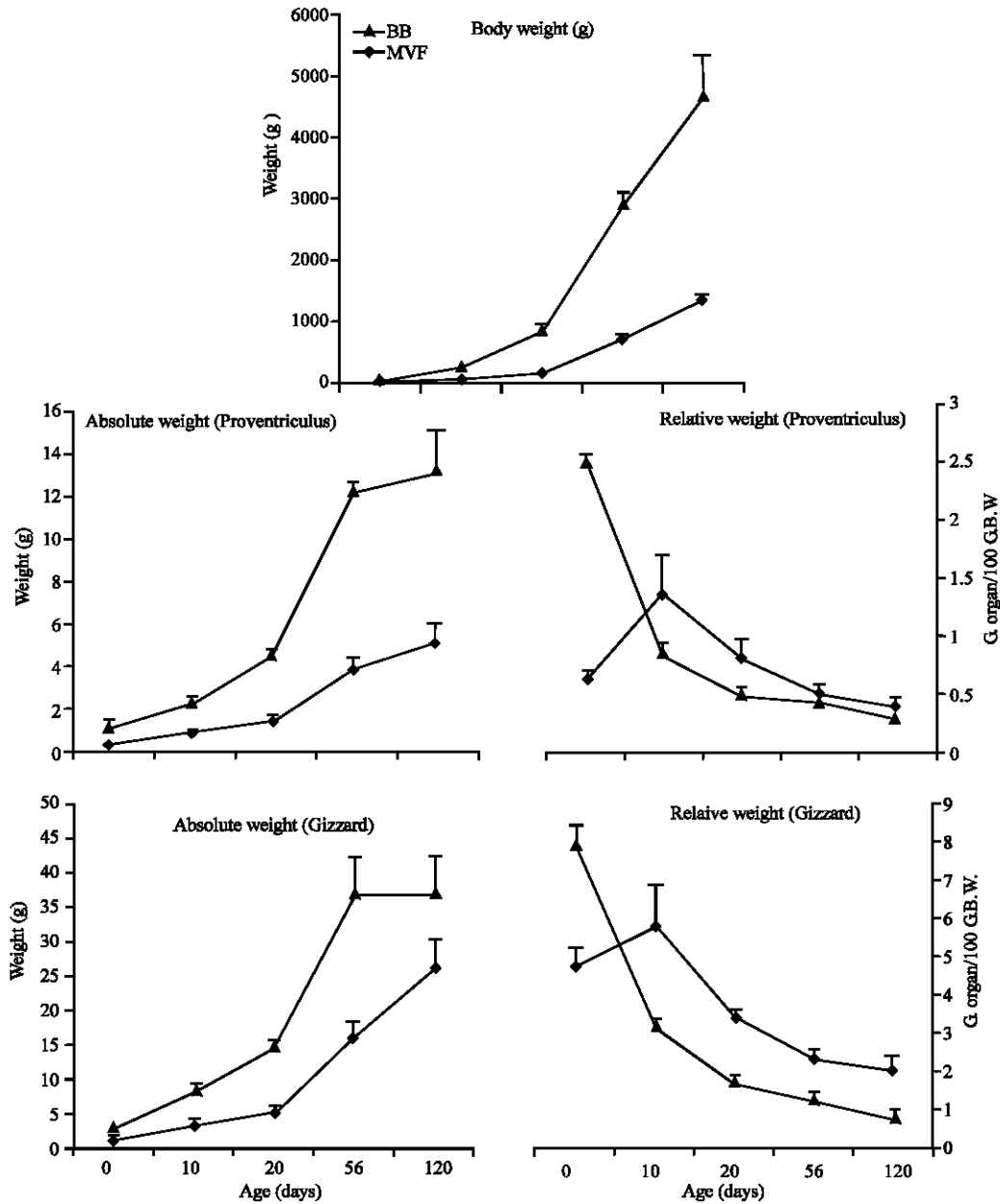


Fig. 1: Total body weight, weight of proventriculus and gizzard (absolute-left and relative-right) of BB and MVF from day 1-120 post-hatch, the relative organs weight represented by gram weight/100 g body weight (N = 50). Vertical bars represent the SD, when not shown the SD is smaller than the symbol. (*) not significantly different (p>0.05)

At one day old, the weights of the digestive organs, both absolute and relative to body weight were significantly higher (p<0.05) in BB than in the MVF (Fig. 1-3).

The pattern of organs weight relative to body weight for all organs of both breeds reach the optimum value at day 10 post-hatch and after that declined sharply

except for the proventriculus and gizzard of BB, which declined sharply after day one post-hatch and then gradually decreased from day 20-120 post-hatch.

The absolute lengths of the intestinal segments of MVF were shorter by approximately one fold than those of BB (Fig. 4). At 10 days post-hatch, the relative weight

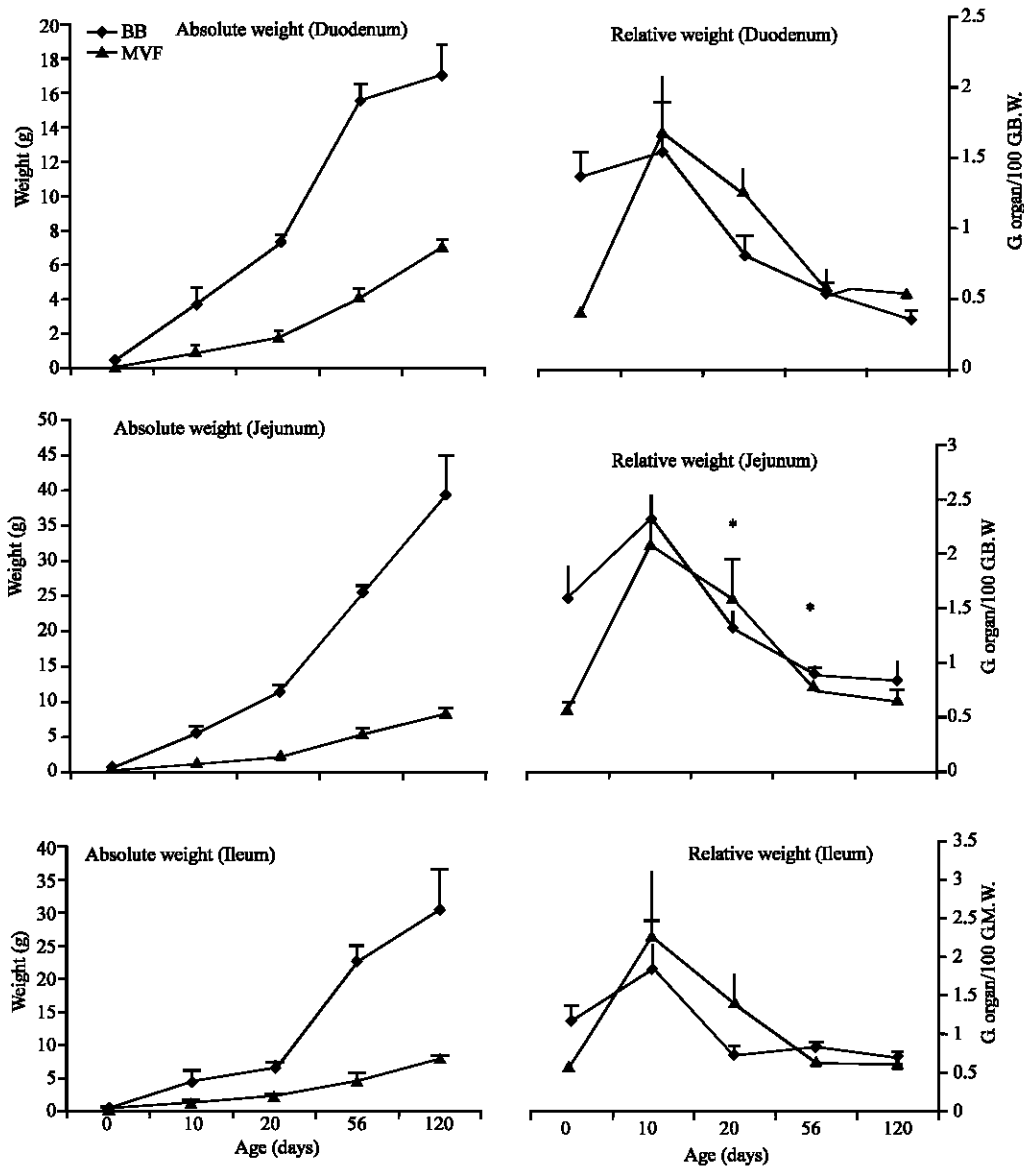


Fig. 2: Weight of duodenum, jejunum and ileum (absolute-left and relative-right) of BB and MVF, from day 1-120 post-hatch, the relative organs weight represented by gram organ weight/100 g body weight (N = 50). Vertical bars represent the SD, when not shown the SD is smaller than the symbol. (*) not significantly different ($p > 0.05$)

and length of the digestive organs of MVF were significantly higher ($p < 0.05$) than the BB, except for the liver, pancreas and duodenum weight which were not significantly different ($p > 0.05$). However, the relative weight of the jejunum in BB was significantly higher ($p < 0.05$) than the MVF.

At day 20 post-hatch, the relative weight and length of intestinal organs of MVF were significantly

higher than the BB except in jejunum weight, which was not significantly differs. Similar results were obtained at 56 days post-hatch but the liver, pancreas, duodenum, jejunum and ileum relative weight showed no difference between both the breeds. After 56 days post-hatch, the organs absolute weights increased in the same degree for the jejunum and ileum, slightly increased in duodenum, liver and proventriculus, while it was

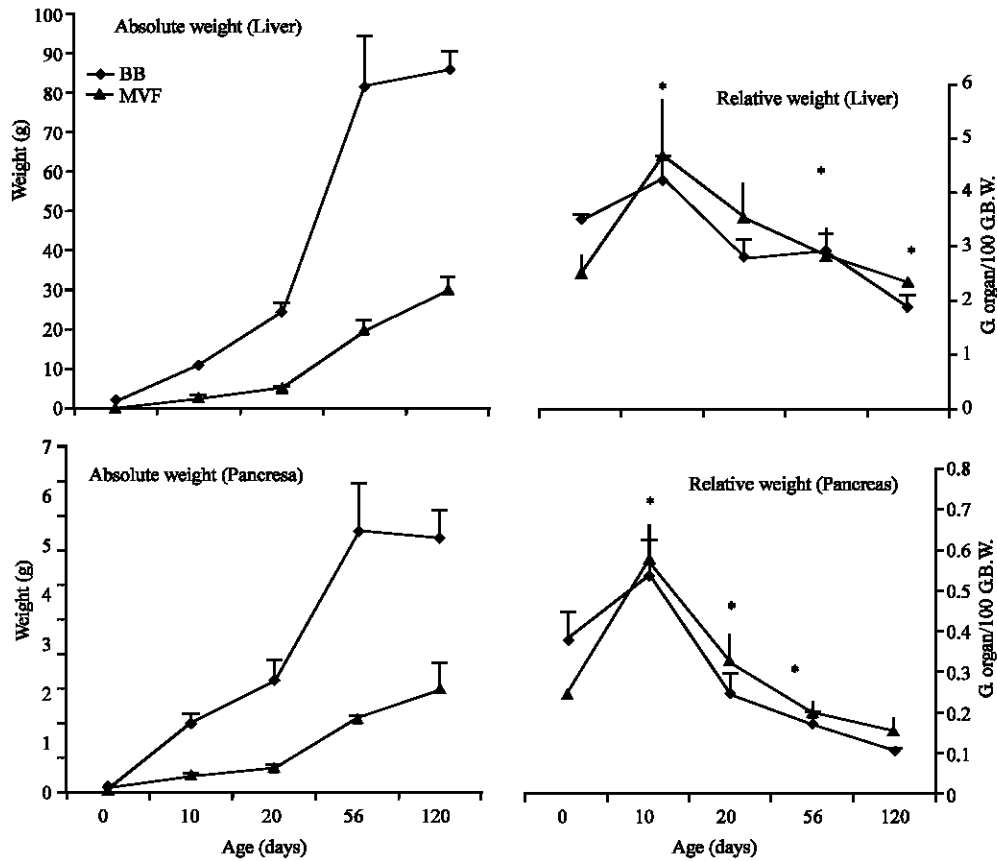


Fig. 3: Weight of the liver and pancreas (absolute-left and relative-right) of BB and MVF, from first day 1-120 post-hatch. The relative organs weight represented by gram organ weight/100 g body weight (N = 50). Vertical bars represent the SD, when not shown, the SD is smaller than the symbol. (*) not significantly different ($p > 0.05$)

constant for the pancreas and gizzard. From 20-56 days post-hatch there were sharp increased of all organs absolute weight in BB.

At day 120 post-hatch, the relative weight and length were higher in MVF, while the jejunum relative weight were significantly higher in BB and no differences for liver and ileum relative weight. The absolute length of intestinal segments (duodenum, jejunum and ileum) increased greatly during the first 10 days in BB and in the same rate between 20-56 days after that the length became steady (Fig. 4).

Similarly, the lengths of intestinal segments were increased in the MVF but the increment was gradual and more steadily.

There were marked declined in the length of intestinal segments in the BB relative to body weight especially during the first 20 days post-hatch and gradually decreased after that.

In contrast, the length of intestinal segments in the MVF relative to body weight was increased during the first 10 days post-hatch and then decreased rapidly till the 56 days post-hatch, which then decreased more gradually until day 120 post-hatch.

Microscopic findings: Histological examination of the proventriculus showed that the thickness of submucosa layer which consists of the proventricular glands, the glandular alveolus and glandular lobules were significantly thicker ($p < 0.05$) in the BB than in the MVF.

The height and surface area of the villi of duodenum in BB were significantly higher ($p < 0.05$) than those in the MVF at all age of post-hatch examined. The depth of the crypt of duodenum in BB was significantly higher ($p < 0.05$) than those in the MVF at days 1, 10 and 20 post-hatch. However, the depth of the

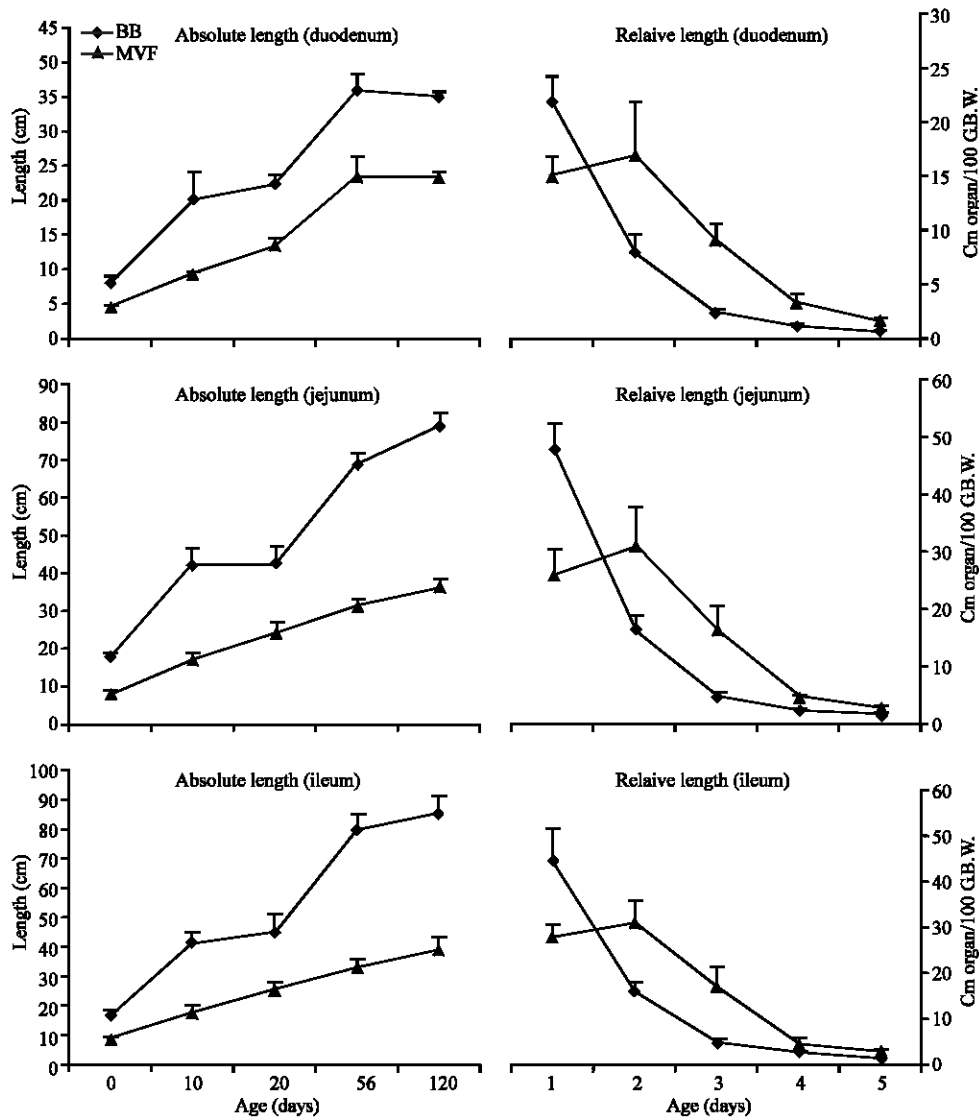


Fig. 4: Length of intestinal segments (absolute-left and relative-right) of BB and MVF, from 1-120 days post-hatch. The relative organs length represented by cm organ length/100 g body weight (N = 50). Vertical bars represent the SD, when not shown the SD is smaller than the symbol. (*) not significantly different ($p > 0.05$)

crypt of duodenum between the two breeds was not significantly different ($p > 0.05$) at days 56 and 120 post-hatch. The thickness of muscularis externa in the duodenum was significantly higher ($p < 0.05$) in BB at days 10 and 120 post-hatch.

However, at days 1, 20 and 56 post-hatch, the thickness of muscularis externa in the duodenum was not significantly different ($p > 0.05$) between the two breeds (Table 1).

The height and surface area of the villi of jejunum in BB were significantly higher ($p < 0.05$) than those in the MVF during the period of the experiment. Similarly, the depth of the crypt of jejunum in BB was significantly

higher ($p < 0.05$) than those in the MVF at all age of post-hatch examined. The muscularis externa in the jejunum was significantly thicker ($p < 0.05$) in BB at days 10, 20 and 120 post-hatch.

However, at days 1 and 56 post-hatch, the thickness of muscularis externa in the jejunum was not significantly different ($p > 0.05$) between the two breeds (Table 2).

The height of the villi of ileum were significantly higher ($p < 0.05$) in the BB than those in the MVF except at days 20 and 56 post-hatch. The surface area of the villi were also significantly greater ($p < 0.05$) in the BB except at day 120 post-hatch.

Table 1: Micromorphometric measurement of duodenum wall in first, 10, 20, 56 and 120 days post-hatch of BB and MVF

Age (day)	Villus height μm		Villus surface area cm^2		Crypt dep. μm		Musc. externa μm	
	BB	MVF	BB	MVF	BB	MVF	BB	MVF
1	778±27	454±37	0.24±.04	0.08±.01	160±11	36±13	69±5*	68±10*
10	1403±112	964±61	0.46±.07	0.23±.05	172±14	79±14	68±14	39±6
20	1963±113	1152±149	1.46±.17	0.69±.08	140±14	114±13	128±8*	122±8*
56	2016±80	1305±110	1.98±.24	1.29±.46	147±8*	140±8*	192±12*	185±10*
120	1955±133	1422±39	3.05±.23	1.86±.25	214±36*	192±10*	430±40	134±12

Height of ten intact villi from jejunum, expressed in μm ; Villus surface area of ten intact villi from jejunum expressed in mm^2 ; Crypt depth and Total thickness of muscularis externa for jejunum, expressed in μm ; N= 10, for each age. Measurements were obtained by image analysis; Values are presented as means±SD; comparison between the breeds within ages; (*) not significantly different ($p>0.05$) between breeds in the same age

Table 2: Micromorphometric measurement of jejunum wall in first, 10, 20, 56 and 120 days post-hatch of BB and MVF

Age (day)	Villus height μm		Villus surface area cm^2		Crypt dep. μm		Musc. externa μm	
	BB	MVF	BB	MVF	BB	MVF	BB	MVF
1	488±25	252±35	0.15±.02	0.02±.005	121±19	43±10	69±6*	67±2*
10	704±27	380±21	0.24±.04	0.13±.02	124±6	72±11	110±9	33±4
20	1092±107	743±155	0.85±.07	0.34±.03	105±22	86±12	124±13	93±16
56	1755±226	1068±97	2.19±.6	0.87±.27	155±45	145±11	216±29*	204±16*
120	18401±125	1139±86	2.4±.4	0.66±.12	169±32	90±6	214±19	149±14

Height of ten intact villi from jejunum, expressed in μm ; Villus surface area of ten intact villi from jejunum expressed in mm^2 ; Crypt depth and Total thickness of muscularis externa for jejunum, expressed in μm ; N= 10, for each age. Measurements were obtained by image analysis; Values are presented as means±SD; comparison between the breeds within ages; (*) not significantly different ($p>0.05$) between breeds in the same age

Table 3: Micromorphometric measurement of ileum wall in first, 10, 20, 56, and 120 days post-hatch of BB and MVF

Age (day)	Villus height μm		Villus surface area cm^2		Crypt dep. μm		Musc. externa μm	
	BB	MVF	BB	MVF	BB	MVF	BB	MVF
1	390±14	181±13	0.13±.02	0.02±.004	90±8	25±10	58±10*	56±6*
10	733±30	341±25	0.25±.03	0.11±.01	128±18	62±10	20±8	35±3
20	574±52*	518±75*	0.50±.14	0.21±.03	90±12	72±13	118±14	91±10
56	847±84*	776±129*	0.88±.28	0.33±.08	103±10	94±7	220±37*	216±9*
120	884±84	646±61	0.55±.12*	0.43±.15*	128±13	91±7	325±58	176±9

Height of ten intact villi from ileum, expressed in μm ; Villus surface area of ten intact villi from ileum expressed in mm^2 ; Crypt depth and Total thickness of muscularis externa for ileum expressed in μm ; N= 10, for each age. Measurements were obtained by image analysis; Values are presented as means±SD; comparison between the breeds within ages; (*) not significantly different ($p>0.05$) between breeds in the same age

The depth of the crypt of ileum in BB was significantly higher ($p<0.05$) than those in the MVF at all age of post-hatch examined. The muscularis externa in the ileum was significantly thicker ($p<0.05$) in BB at days 10, 20 and 120 post-hatch.

However, at days 1 and 56 post-hatch, the thickness of muscularis externa in the ileum was not significantly different ($p>0.05$) between the two breeds (Table 3).

The different breeds used in the study exhibited clearly the different in body weights. This is due to the selection process of the BB for better growth rate, while for the MVF there is no selection process been reported elsewhere.

The data obtained in study used male only due to the differences in body weight between the genders especially in the MVF.

The greater residual yolk relative weights (vitelline residue) in MVF as compared to the BB observed in this study are consistent with the report by Nitsan *et al.* (1991)

who showed that the relative weight of vitelline residue in fastest growing line was lowest due to complexity for the need and use of this material during the embryonic and transitional periods.

It was suggested that this nutrient materials was used to develop the GIT during the embryonic life in preparation for the extreme changes required for consuming and assimilating considerable amounts of food after hatch (Uni *et al.*, 1998).

In general, the weight and length of digestive tract for MVF were lighter and shorter than the BB, respectively. The breeds used in study differ considerably not only in patterns for body weight growth but also in feed intake behavior.

This was due to the selection process which done in BB for feed efficiency that affects the total size of gastrointestinal tract. Even at day 1 post-hatch, the digestive organs weight of both absolute and relative to body weight were larger in the BB than in the MVF. This suggested that the BB has greater capacity available for

feed intake. Lilja (1983) has shown that fast-growing birds are characterized by early development of the supplying organs.

Dror *et al.* (1977) proposed that adaptation to exogenous feed was associated with increases in weights of the GIT.

Several researchers observed that broiler breed ate at gut capacity whereas slower growing egg-type bird did not (Nir *et al.*, 1978; Cherry and Siegel, 1978; Barbato *et al.*, 1984). The results presented in this study are in agreement with Lilja *et al.* (1985).

Results of the study showed that the growth pattern of most organs of BB increased rapidly especially during the first ten days post-hatch.

However, the marked increase between day 20-56 post-hatch may be related to the longer duration between these two points. The absolute weights of digestive organs were markedly increased up to day 56 post-hatch and gradually increased or constant there after except for the jejunum and ileum.

In BB, the intestinal weight increased greater than the length due to the increase of the two main morphological components, mucosa and muscles. In the MVF, the organs growth pattern were somewhat different the growth increased progressively and showed persistence at the same rate during the experiment.

The higher relative weight of the digestive organs in BB than MVF during the first 10 days because this period of early post-hatch continues to be proportionally larger in the life of BB. Although, the light breed tended to have larger GIT than the heavy breed at 25 and 61 days of age (Cherry *et al.*, 1987).

The relative intestine length sharply declined after first days. Therefore, the increase in weight of small intestine of BB was much more than the increase in its length. The relative organs weight of MVF were found somewhat similar pattern except the proventriculus in the first 10 days.

In addition to the difference in the relative length of small intestine were observed during this period compared with BB.

Part of these data agrees with the finding of Dror *et al.* (1977), in respect to the relative weight of pancreas and duodenum of light breed, but not with jejunum or ileum.

However, Shires *et al.* (1987) and Nir *et al.* (1993) suggested that the light breed have relatively lighter and shorter intestines than the broilers.

After 10 days age and because of the villi shape became longer, folded and overlap with each others, so

this made it difficult to measure with routine procedure. Therefore, procedure was used which was developed by Smith *et al.* (1990).

The study revealed significant differences in villus height and villus surface area of all intestinal segments between the two breeds investigated (BB>MVF). The differences were proportionate to differences in metabolic body weight supporting the hypothesis that absorptive surfaces of the small intestine are related directly to metabolic requirements (Mayhew and Middleton, 1985).

James *et al.* (1988) and Smith *et al.* (1990) proved that the presentation of nutrients within small intestine constitutes one of the most potent ways to modify villus structures for different groups of chickens selected for high growth rate, thus the differences noted in the villus height and villus surface area.

The duodenum had the highest villi followed by lower in jejunum and the lowest in ileum in both breed, which is in agreement with the findings of Yamauchi (2002) and Lidia *et al.* (1998).

According to the findings of Smith *et al.* (1990), there were differences in the crypt sizes of the small intestine between unselected and selected breeds for high growth rate which were reported in this experiment. However, there were no difference in the duodenal crypts at 56 and 120 days post-hatch. These results indicate that the duodenum showed a marked growth rate in early life stage and reach the maximum point earlier followed by jejunum and ileum (Yamauchi *et al.*, 1995).

In the study, except on the days 1 and 56 post-hatch, there were differences in the thickness of the muscular layer in the wall of small intestine for both breeds (BB>MVF).

This fact explained by Karasova and Diamond (1983) that the broiler increases their nutrient transporter capacities by increasing the mass of the entire small intestine. These differences were also found between the domestic and wild duck as a kind of adaptations to the large volume of food eaten by commercial ducks (Watkins *et al.*, 2004).

CONCLUSION

In this study, these all the parameters relative to body weight in the BB which consciously selected for high body weight and rapid growth rate were failed to tracking the rapid growth of the body with the exception of the first day after hatch. This is contrary to the unselected

breed (MVF), which their traits followed the slow body growth. The differences in growth rate between both breeds accompanied by differential growth of digestive organs and this reinforce the interpretation that the morphological and digestive differences that we noted between the both breeds are related to selection for high body weight, in addition to reflect of the genetic effects.

REFERENCES

- Baddeley, A.J., H.J.G. Gundersen and L.M.C. Orice, 1986. Estimation of surface area from vertical sections. *J. Microscopy*, 142: 259-276.
- Bancroft, J.D. and M. Gamble, 2002. *Theory and Practice of Histological Techniques*. 5th Edn., Churchill Livingstone, London, New York and Philadelphia.
- Barbato, G.F., P.B. Siegle, J.A. Cherry and I. Nir, 1984. Selection for body weight at eight weeks of age. 17 Overfeeding. *Poult. Sci.*, 63: 11-18.
- Chambers, J.P., 1990. Genetics of Growth and Meat Production in Chickens. In: *Poultry Breeding and Genetics*, Crawford, R.D. (Ed.). Elsevier Scientific Publishers, New York, pp: 1123.
- Cherry, J.A. and P.B. Siegel, 1978. Selection for body weight at eight weeks of age. 15 feed passage and intestinal size of normal and dwarf chicks. *Poult. Sci.*, 57: 336-340.
- Cherry, J.A., I. Nir, D.E. Jones and E.A. Dunnington, 1987. Growth-associated traits in parental and F₂ population of chickens under different feeding programs. 1. *Ad libitum* feeding. *Poult. Sci.*, 66: 1-9.
- Dror, Y., I. Nir and Z. Nitsan, 1977. The relative growth of internal organs in light and heavy breeds. *Br. Poult. Sci.*, 18: 493-496.
- Iji, P.A., A. Saki and D.R. Tivey, 2001. Body and intestinal growth of broiler chicks on a commercial starter diet. 1. Intestinal weight and mucosal development. *Br. Poult. Sci.*, 42: 505-513.
- Iji, P.A., R.J. Hughes, M. Choct and D.R. Tivey, 2000. Intestinal structure and function of broiler chickens on wheat-based diets supplemented with a microbial enzyme. *Asian Aust. J. Anim. Sci.*, 14: 54-60.
- James, P.S., M.W. Smith and D.R. Tivey, 1988. Single villus analysis of disaccharidase expression by different regions of the mouse intestine. *J. Physiol.*, 401: 533-545.
- Karasova, W.H. and J.M. Diamond, 1983. Adaptive regulation of sugar and amino acid transport by vertebrate intestine. *Am. J. Physiol.*, 245: 6443-6462.
- Lidia, O., W. Rudiger, R. Oswald, H. Walter and W. Eckhard, 1998. Intestinal dimensions of mice divergently selected for body weight. *Anat. Rec.*, 250: 292-299.
- Lilja, C., 1983. A comparative study of postnatal growth and organ development in some species of birds. *Growth*, 47: 317-339.
- Lilja, C., I. Sperber and H.L. Marks, 1985. Postnatal growth and organ development in Japanese quail selected for high growth rate. *Growth*, 49: 51-69.
- Mayhew, T.M. and C. Middleton, 1985. Crypts, villi and microvilli in the small intestine of the rat. A stereological study of their variability within and between animals. *J. Anat.*, 141: 1-17.
- Mitchell, M.A. and M.W. Smith, 1991. The effects of genetic selection for increased growth on mucosal and muscle weights in the different regions of the small intestine of the domestic fowl (*Gallus domesticus*). *Comp. Biochem. Physiol.*, 99: 251-258.
- Mitchell, M.A. and M.W. Smith, 1990. Jejunal alanine uptake and structural adaptation in response to genetic selection for growth rate in the domestic fowl (*Gallus domesticus*). *J. Physiol.*, 424: 7-15.
- Nir, I., Z. Nitsan and M. Mahagna, 1993. Comparative growth and development of the digestive tract and of some enzymes in broiler and egg type chicks after hatching. *Br. Poult. Sci.*, 34: 523-532.
- Nir, I., Z. Nitsan, Y. Dror and N. Shapira, 1978. Influence of overfeeding on growth, obesity and intestinal tract in young chicks of light and heavy breeds. *Br. J. Nutr.*, 39: 27-35.
- Nitsan, Z.G., B. Avraham, Z. Zoref and I. Nir, 1991. Organ growth and digestive enzymes levels to fifteen days of age in lines of chickens differing in body weight. *Poult. Sci.*, 70: 2040-2048.
- Ramlah, A.H., 1996. Performance of village fowl in Malaysia. *World Poult. Sci. J.*, 527: 75-79.
- Shires, A.J., J.R. Thompson, B.V. Turner, P.M. Kennedy and Y.K. Goh, 1987. Rate of passage of corn-canola meal and corn-soybean meal diets through the gastrointestinal tract of broiler and white leghorn chickens. *Poult. Sci.*, 66: 289-298.
- Siegel, P.B. and E.A. Dunnington, 1987. Selection for growth in chickens. *World Poult. Sci.*, 1: 1-24.
- Smith, M.W., M.A. Mitchell and M.A. Peacock, 1990. Effects of genetic selection on growth rate and intestinal structure in the domestic fowl (*Gallus domesticus*). *Comp. Biochem. Physiol. A*, 97: 57-63.

- Uni, Z., S. Ganot and D. Sklan, 1998. Posthatch development of mucosal function in the broiler small intestine. *Poult. Sci.*, 77: 75-82.
- Watkins, E.J., P.J. Butler and B.P. Kenyon, 2004. Posthatch growth of the digestive system in wild and domesticated ducks. *Br. Poult. Sci.*, 45: 331-341.
- Yamauchi, K., 2002. Review on chicken intestinal villi histological alterations related with intestinal function. *Poult. Sci.*, 39: 229-242.
- Yamauchi, K., K. Yamamoto and Y. Isshiki, 1995. Morphological alterations of the intestinal villi and absorptive epithelial cells in each intestinal part in fasted chickens. *Jap. Poult. Sci.*, 32: 241-251.