

## Radiological Evaluation of Orbit Tumors

<sup>1</sup>Mehran Midia, <sup>2</sup>Zinat Miabi, <sup>3</sup>Ramin Midia and <sup>4</sup>Omid Mashrabi

<sup>1</sup>Department of Radiology, McMaster Medical Center Hamilton Health Science, Iran

<sup>2</sup>Department of Radiology, Tabriz Medical University, Imam Khomeini Hospital, Iran

<sup>3</sup>Department of Radiology Iowa City VA Medical, Iran

<sup>4</sup>Ajabashir Health Center, Iran

**Abstract:** Our purpose was to examine the accuracy and efficacy of preoperative imaging by Computing Tomography (CT) scan and/or Magnetic Resonance Imaging (MRI) in assessing tumor invasion of the orbit. Ninety eight preoperative CT and 40 preoperative MR images from patients with orbital masses were reviewed. Results were corroborated by pathologic and intraoperative assessment. 60.9% of patients were male and 39.1% of them were female. Sensitivity of CT scan in diagnosis of orbit masses was 89.9% and MRI sensitivity was 95%. Both CT and MRI have high potency in diagnosis of orbit lesions and from the viewpoint of statistics, no significant difference was found between diagnostic accuracy of orbit lesions by CT scan and MRI ( $p>0.05$ ). MRI was more sensitive in detecting neoplastic invasion of orbit tumor than CT scan.

**Key words:** Orbital masses, CT, MRI, accuracy, radiological evaluation, orbit tumors

### INTRODUCTION

Since pathology of orbits has great importance as for an important limb such as eye (Belden and Zinreich, 1997; Sutton, 1998), nowadays evaluation of these lesions has been facilitated by computed imaging (Belden and Zinreich, 1997). Some authors more recommended Magnetic Resonance Imaging (MRI) in evaluation of eye (Duvoisin *et al.*, 1998), but MRI was an expensive method (Belden and Zinreich, 1997; Sutton, 1998) while the other authors, as the first step in these patients proposed Computing Tomography (CT) scan (Mauriello *et al.*, 1999). The aim of this study, was evaluation of the efficacy and economical of two CT and MRI methods in evaluation of orbits masses.

### MATERIALS AND METHODS

In this study, efficacy of CT and MRI in diagnosis of orbits masses has been evaluated. In this evaluation, from 1999-2005, patients with orbit lesions, referring to Hafez MRI center and evaluated by CT or MRI, were selected. All imaging of CT and MRI were performed by X1, X2, respectively. All images were evaluated and reported by author and receipt results were compared with post operative pathology of patients and determined

sensitivity of CT and MRI in diagnosis of orbit masses. One hundred and thirty eight patients enrolled to study; 98 patients were evaluated by CT scan and 40 patients were evaluated by MRI. Using SPSS 11.5 for Windows and T-test and Chi-square test for analysis of data, the level of meaningfulness was considered as  $p<0.05$ .

### RESULTS AND DISCUSSION

Eighty four (60.9%) patients were male and 54(39.1%) them were female. Mean age of patients at CT group was  $33\pm 23.5$  year and mean age of patients in MRI group was  $41\pm 17$  year ( $p>0.05$ ). Age distribution of patients at the base of diagnostic methods is shown in Fig. 1. MRI and CT scan findings are shown in Fig. 2. Agreement rate of CT scan with post operative pathology was 89.8% and MRI was 95%. No significant difference was found comparing the agreement rate of CT scan and MRI with post operative pathology ( $p>0.05$ ).

In our study, CT in 89.9% and MRI in 95% of patients were able to diagnose the orbit masses and in statistics evaluation, no significant difference was found between diagnostic potency of CT scan and MRI in diagnosis of orbital masses although several studies has considered MRI to take priority over CT scan.

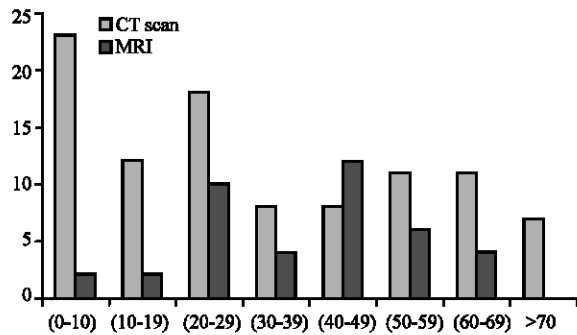


Fig. 1: Age distribution of patients in both CT and MRI groups

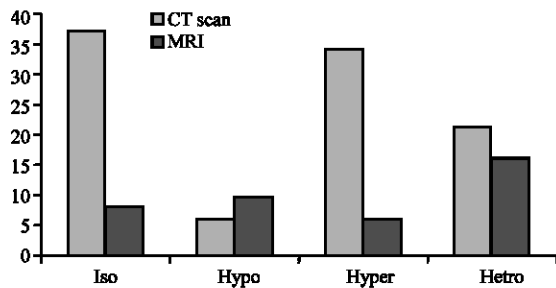


Fig. 2: CT scan and MRI findings from patients with orbit masses

He *et al.* (2002) reported the histopathologic classification and distribution of orbital diseases in 3,476 patients. They reported that the 10 leading diseases were cavernous hemangioma, leiomyoma, inflammatory pseudo tumor, dermoid, schwannoma, meningioma, benign mixed tumor of the lacrimal gland, mucocele, varix and lacrimal gland epithelial tumor.

The usefulness of MRI of orbital mass lesions is well known (Bilaniuk, 1999; Mihara *et al.*, 1991; Abe *et al.*, 2000).

MR plays an important role in evaluating pathologic conditions that affect the orbit. MR appears to be superior to ultrasound and computed tomography in evaluation of intraocular tumors and fluid collections (Dorfman and Spickler, 1990).

The additional advantages of spiral CT have further cemented CT's role as the screening examination of choice for the orbit. The shorter scan times permit ideal enhancement yet reduce the contrast load, providing the optimal post contrast studies that routine imaging of the orbit requires (Maya *et al.*, 1998).

MRI was more conspicuous for detecting orbital invasion than CT. The mass beyond the thickened periorbita on T2-weighted images was considered to be a positive finding of orbital invasion (Kim *et al.*, 2006).

CT-arteriography, with a minimal dose of contrast medium, can offer significant advantages over intravenously injected dynamic neuroimaging and provides additional valuable preoperative information about the orbital tumor under investigation (Hasegawa *et al.*, 2005).

Modern stereotaxy utilizes preoperative Computed Tomography (CT) and Magnetic Resonance Imaging (MRI) to provide accurate localization information which can be very helpful in orbital surgery (Karcioglu and Moscote, 2006).

## CONCLUSION

Both CT and MRI have high potency in diagnosis of orbit lesions and from the viewpoint of statistics, no significant difference was found between diagnostic accuracy of orbit lesions by CT scan and MRI and because of the high price of MRI, use of CT scan is recommended as the first diagnostic step in evaluation of orbit lesions and if in the case of inefficacy, use MRI for diagnosis is recommended.

## REFERENCES

- Abe, T., N. Kawamura, H. Homma, K. Sasaki, H. Izumiyama and K. Matsumoto, 2000. MRI of orbital schwannomas. *Neuroradiology*, 42: 466-468.
- Belden, C.J. and S.J. Zinreich, 1997. Orbital imaging techniques. *Semin Ultrasound CT MR.*, 18: 413-422.
- Bilaniuk, L., 1999. Orbital vascular lesions: Role of imaging. *Radiol. Clin. North Am.*, 37: 169-183.
- Dorfman, R.E. and E.M. Spickler, 1990. Current status of magnetic resonance imaging of the orbit. *Top. Magn. Reson Imaging*, 2: 17-26.
- Duvoisin, B., F.E. Zanella and K.W. Sievers, 1998. Imaging of the normal and pathological orbit. *Eur. Radiol.*, 8: 175-88.
- Hasegawa, M., H. Fujisawa, Y. Hayashi, J. Yamashita, M. Suzuki and O. Matsui, 2005. CT arteriography for orbital tumors: Diagnostic and surgical value. *J. Clin. Neurosci.*, 12: 548-552.
- He, Y., G. Song and Y. Ding, 2002. Histopathologic classification of 3476 orbital disease. *Zhonghua Yan Ke Za Zhi*, 38: 396-398.
- Karcioglu, Z.A. and C.R. Mascote, 2006. Computer-assisted image-guided orbit surgery. *Eur. J. Ophthalmol.*, 16: 446-452.
- Kim, H.J., T.H. Lee, H.S. Lee, K.S. Cho and H.J. Roh, 2006. Periorbita: Computed tomography and magnetic resonance imaging findings. *Am. J. Rhinol.*, 20: 371-374.

- Mauriello, J.A., H.J. Lee and L. Nguyen, 1999. CT of soft tissue injury and orbital fractures. *Radiol. Clin. North Am.*, 37: 241-252.
- Mihara, F., K.L. Gupta, S. Murayama, N. Lee and B.G. Haik, 1991. MR imaging of orbital mass lesions with contrast agent: A preliminary report. *Comput. Med. Imaging Graph*, 15: 445-449.
- Maya, M.M., L.A. Heier and C.T. Orbital, 1998. Current use in the MR era. *Neur. Clin. N Am.*, 8: 651-83.
- Sutton, D., 1998. Text book of radiology and imaging, 6th Edn. Mc-Graw-hill Company, Philadelphia, pp: 544-456.