

## Attenuation of Cisplatin-Induced Hepatotoxicity in Rats Using Zerumbone

<sup>1</sup>Mohamed Yousif Ibrahim, <sup>1,2</sup>Ahmad Bustamam Abdul, <sup>1</sup>Siddig Ibrahim Abdel Wahab,  
<sup>1</sup>Manal Mohammed Elhassan, <sup>1,3</sup>Adel Sharaf Alzubairi and <sup>1</sup>M.M. Syam  
<sup>1</sup>UPM-MAKNA Cancer Research Laboratory, Institute of Bioscience,  
<sup>2</sup>Department of BioMedical Sciences, Faculty of Medical and Health Sciences,  
University of Putra Malaysia, Serdang, 43400, Selangor, Malaysia  
<sup>3</sup>Faculty of Medicine, Sana'a University, Sana'a, Yemen

**Abstract:** Zerumbone is a natural compound isolated from the fresh rhizomes of *Zingiber zerumbet*. This bioactive compound has shown a chemo-preventive, anti-inflammatory and free radical scavenging activities. This study examines, the effect of zerumbone on the extent of tissue damage in Cisplatin-induced hepatotoxicity in rats. The rats received a single dose injection of 45 mg kg<sup>-1</sup> Cisplatin. Other groups of rats received zerumbone (100 and 200 mg kg<sup>-1</sup>), corn oil or the vehicle (DMSO) intraperitoneally for 4 days prior to Cisplatin injections. All animals were decapitated 16 h after Cisplatin injection. Trunk blood was collected and analyzed for alanine aminotransferase, aspartate aminotransferase, lactate dehydrogenase, alkaline phosphatase and gama-glutamyl transferase. Liver tissue was kept for the quantification of malondialdehyde and glutathione levels. Histopathological investigations were carried out and severity of lesions was scored to obtain quantitative data. This study revealed that zerumbone reduced the extent of liver damage and preserved liver functions as proved by microscopic observations and lesion scoring. Increase in liver MDA levels with a simultaneous reduction in GSH in the Cisplatin 45 mg kg<sup>-1</sup> group was attenuated by zerumbone treatment (p<0.05). Zerumbone is beneficial in Cisplatin-induced liver dysfunction and organ damage in rats via prevention of lipid peroxidation and preservation of antioxidant glutathione.

**Key words:** Zeumbone, cisplatin, liver injury, oxidative stress, antioxidant glutathione, lipid peroxidation

### INTRODUCTION

Cisplatin (cis-diamine-dichloroplatinum) is a prominent member of the effective broad-spectrum antitumour drugs. However, its clinical usage is restricted due to some adverse side effects, such as nephrotoxicity and ototoxicity (Ekborn *et al.*, 2003; Iraz *et al.*, 2005; Yao *et al.*, 2007). The Cisplatin-induced-nephrotoxicity and ototoxicity have been very well studied in both clinical and animal researches however, liver toxicity has been rarely paid attention to. Recent studies in our laboratory and others reported that liver toxicity is also a major dose-limiting side effect in Cisplatin-based chemotherapy (Liao *et al.*, 2004; Hong *et al.*, 2005; Lu and Cederbawm, 2006; Pratibha *et al.*, 2006; Iseri *et al.*, 2007).

Continued aggressive high-dose Cisplatin chemotherapy necessitates investigating newer measures of preventing dose-limiting side effects that inhibit the administration of Cisplatin at tumouricidal doses. Up until now, a large number of studies have been focused on measures of preventing Cisplatin's side effects via the

simultaneous supplementation of preventive agents (Ali *et al.*, 2006a). The findings of the studies suggested the side effects of Cisplatin could be protected using drugs and micronutrients with different chemical nature (Blakley *et al.*, 2001; Leitao and Blakley, 2003; Fetoni *et al.*, 2004; Kalkanis *et al.*, 2004; Weijl *et al.*, 2004; Kim *et al.*, 2005). Though, the mechanism underlying Cisplatin's side effects are not clearly understood, it was considered to be attributed by multiple factors (Hong *et al.*, 2005; Ramesh and Reeves, 2002; Nowak, 2002; Townsend and Hanigan, 2002; Xiao *et al.*, 2003), amongst them included the generation of Reactive Oxygen Species (ROS), which could interfere with the antioxidant defense system, resulting in oxidative damage in different tissues (Pratibha *et al.*, 2006; Koc *et al.*, 2005; Mansour *et al.*, 2006; Iraz *et al.*, 2006) and the reaction with thiols in protein and glutathione, which could cause cell dysfunction. On the other hand, it has been proposed that the antitumour activity of Cisplatin is due to its ability to form adducts with DNA, which could cause cross-linking of DNA strands (Kasparkova *et al.*, 2004). As the antitumor activity and side effects in Cisplatin-based

chemotherapy are mediated in part by different mechanisms, the actions on selective inhibition of certain side effects could be achieved whilst retaining the antitumor activity (Leonetti *et al.*, 2003). Furthermore, as the side effects in Cisplatin-based chemotherapy were thought to be induced by multi-ways, it could be speculated that a potential protective action on these side effects could be achieved via the combined use of preventive agents with different chemical nature; however, until now, very little is known regarding the combined actions of these agents. In this present study, we attempted to explore the use of these agents in preventing Cisplatin liver toxicity. In regards to this, a natural compound belonging to a ginger plant family, Zingiberaceae was used. Several dietary ingredients of this ginger family have been known and their biological activities elucidated (Aggarwal and Shishodia, 2006; Surh, 1999). The natural compound zerumbone used in this study was isolated and purified from *Zingiber zerumbet* of the ginger family. This compound is used initially as an anti-inflammatory adjuvant for sprain and in treating human ailments such as stomach ache and fever. In addition, its rhizome has been used frequently as a spice in traditional cooking (Chien *et al.*, 2008). Several reports on the bioactivities of zerumbone have been reported, which included anticarcinogenesis (Takada *et al.*, 2005), anti-inflammation (Murakami *et al.*, 2003) and most recently from our own laboratory, zerumbone's anticancer effect on cervical tissues (Abdul *et al.*, 2008). In this present study, we investigated the preventive effect of zerumbone on Cisplatin-induced liver toxicity using microscopy examination of rat liver tissues after H and E staining and further evaluating blood liver functions enzymes and levels of Malondialdehyde (MDA), the end product of lipid peroxidation in liver tissues, as biomarkers.

## MATERIALS AND METHODS

**Reagents and laboratory wares:** All reagents used in this study are analytical grade. All glasses and plastic wares were washed with detergent and acid and rinsed with distilled water. Cisplatin and the others chemicals were obtained from Sigma Chemical Co., St. Louis, MO, USA. ZER was provided as a generous gift from the project leader Dr. Ahmad Bustamam Abdul. The chemical structure and purity of ZER were tested using NMR and HPLC, respectively.

**Animals:** Thirty five female rats (Sprague-Dawley) of 150-200 g weight, procured from the Animal House Unit, Faculty of Veterinary Medicine, University of Putra

Malaysia (UPM) were used. The animal room at Institute Bioscience, UPM was maintained at a temperature of  $25\pm 2^{\circ}\text{C}$  with a 12 h light/dark cycle and a relative humidity of 50-60%. Free access to food and water was allowed at all times. Rats were housed five per cage in sterilized plastic cages using homogenized wood shavings as bedding. All experimental protocols held on animals were done according to regulations set by the Institutional Animal Care and Use Committee, Faculty of Medicine and Allied Sciences, UPM.

**Experimental design:** The rats were divided into groups (n = 5): Rats in group 1 were intraperitoneally pretreated for 4 days with ZER (100 mg/kg/day, in corn oil). Rats in group 2 were intraperitoneally pretreated for 4 days with ZER (200 mg/kg/day, in corn oil). Three hours after ZER pretreatment, a dose of  $45\text{ mg kg}^{-1}$  of Cisplatin was injected in rats group 1 and 2. Rats in group 3 were intraperitoneally treated by Cisplatin  $10\text{ mg kg}^{-1}$  as positive control. Group 4 were intraperitoneally treated with corn oil. Rats in group 5 were intraperitoneally treated with ZER ( $100\text{ mg kg}^{-1}$ ) as a control for group 1. Rats in group 6 were intraperitoneally treated with ZER ( $200\text{ mg kg}^{-1}$ ) as a control for group 2. Rats in group 7 were intraperitoneally treated with DMSO in distilled water, as a control for Cisplatin. All animals were injected in similar volume injections. Since, higher doses of Cisplatin showed evidence of tissue damage between 8-15 h after injection (Liu *et al.*, 1998), the rats were killed under ether anesthesia, 16h after injection and blood, liver and kidney tissues were then collected. Trunk blood was collected and analyzed for ALT, AST, ALP and GGT. After bleeding, liver samples were removed and either fixed in 10% formaldehyde for histopathological examinations or stored at  $-80^{\circ}\text{C}$  for subsequent measurement of Malondialdehyde (MDA) and Glutathione (GSH) levels.

**Determination of liver functions:** Serum ALT, AST, GGT and LDH levels were measured to assess the liver function. All biochemical assays were done spectrophotometrically using Hitachi-912 Autoanalyser (Mannheim, Germany) with kits were supplied by Roche Diagnostics (Mannheim, Germany). To obtain data with good sensitivity and validity, serum samples were analyzed in triplicates and blindly analyzed.

**Histopathological examinations:** The liver samples were embedded in paraffin and tissue sections of  $5\text{ }\mu\text{m}$  were obtained using microtome (Lieca, Switzerland) and stained with hematoxylin and eosin following laboratory standard procedure. Stained hepatic tissues slide were mounted

with DPX and covered with cover slips. All sections were examined using a photomicroscope (Olympus BH-2, Japan). At least five microscopic areas were examined to score a specimen. The criteria for liver injury included vacuolization of hepatocytes and pyknotic hepatocyte nuclei, activation of Kupffer cells and enlargement of sinusoids. Each specimen was scored using a scale ranging from 0-3 (0: none, 1: mild, 2: moderate and 3: severe), whereby a total score of 9 was adapted for liver specimens. Histological examination and scoring were examined and performed by an independent histopathologist, non-related to this research team and uninformed of all treatment groups.

**Measurement of tissue MDA:** The measurement of MDA has been used as an indicator of lipid peroxidation. Levels of MDA were assayed following the method of Satoh. Briefly, 10% (w v<sup>-1</sup>) homogenate of liver made by 0.1 mol L<sup>-1</sup> phosphate buffer was centrifuged at 4°C; 3500 rpm for 10 min. Two milliliters supernatant were mixed with 0.67% 2-Thiobarbituric Acid (TBA) and 20% trichloroacetic acid solution and heated in water bath (95°C) for 30 min. Later, tubes were centrifuged and supernatants collected. The pink-colored chromogen formed by the reaction between TBA with MDA was measured at 532 nm. The results were expressed as MDA nmol mg<sup>-1</sup> protein. Contents of protein in the supernatant were measured using Lowry's method with few modifications (Yingjun *et al.*, 2008).

**Measurement of tissue GSH levels:** The tissue samples were homogenized in 10 volumes of ice-cold 10% trichloroacetic acid and centrifuged at 1000 rpm for 15 min at 4°C. Supernatant was removed and recentrifuged at 35,000 rpm at 4°C for 8 min. GSH was determined using a spectrophotometric method, which is a modification of Ellman procedure (Aykac *et al.*, 1985).

**Statistical analysis:** All data are expressed as mean±SD. Histological data (Lesion Scoring) were compared using Kruskal-Wallis non-parametric test whilst other parameters were compared by one-way ANOVA followed by post hoc Tukey HSD multiple comparison tests. The type 1 error level was set at p<0.05 for all tests. All statistical analyses were performed using SPSS software (Chicago, IL, USA) version 16.0 for Microsoft Windows®.

## RESULTS AND DISCUSSION

**The effect of zerumbone on Cisplatin-induced liver dysfunction:** The results of this study showed that Cisplatin 45 mg kg<sup>-1</sup> caused a significant reduction in hepatic function, as characterized by remarkable increased

in serum ALT, ALP, AST and GGT (Table 1). These findings indicate strongly that the single intra-peritoneal injection of 45 mg kg<sup>-1</sup> Cisplatin harms liver function.

Pretreatment with zerumbone for 4 days significantly overturned Cisplatin-induced elevation in serum ALT, ALP, AST and GGT. Moreover, treatment with DMSO and corn oil did not induce any abnormal changes in the serum level of liver function enzymes. In addition, serum levels of these enzymes are not affected by the treatment with zerumbone (Table 1).

**The effect of zerumbone on qualitative and quantitative histopathology and clinical observation:** No death was observed among all groups during the period of the study. Liver samples were obtained and observed under microscopy. Liver tissues in Cisplatin-administered animals have shown cellular damage. This hepatic damage was recognized by severe activation of Kupffer cells, degeneration and moderate enlargement of sinusoids. In zerumbone pre-treated animals, the morphology of hepatic tissue is nearly appears normal with preserved liver parenchyma. The morphological feature of liver from zerumbone injected animals is similarly near to the control morphology with normal hepatocytes, Kupffer cells and sinusoids (Fig. 1-7). In accordance with the morphological appearance of livers from Cisplatin injected animals, their quantitative lesions scoring mean is statistically higher than that of normal control group (p<0.05). Zerumbone administration reduced the microscopic lesion scoring effectively (p<0.05) (Table 2).

Total mean scoring, sinusoidal dilatation, activation of Kupffer cells and vacuolization was used as indices to evaluate the lesions quantitatively as mentioned earlier. In respect to these indices, the highest mean was observed in Cisplatin treated group.

- A : 45 mg kg<sup>-1</sup> Cisplatin 10 mg kg<sup>-1</sup> Platin
- B : 200 mg kg<sup>-1</sup> ZER + 45 mg kg<sup>-1</sup> Cisplatin
- C : 100 mg kg<sup>-1</sup> ZER + 45 mg kg<sup>-1</sup> Cisplatin
- D : 100 mg kg<sup>-1</sup> ZER negative control
- E : 200 mg kg<sup>-1</sup> ZER Negative Control
- F : Negative control (DMSO)
- G : Negative control (corn oil)

**The effect of zerumbone on MDA and GSH levels:** Lipid peroxidation in liver tissues was measured according to MDA level. In Cisplatin injected animals, MDA level is markedly higher compared to normal control. Pretreatment with zerumbone decreases the levels of MDA, which are significantly different from the mean of MDA in Cisplatin treated animals (Table 3). The indigenous level of GSH was strongly depleted by single intraperitoneal injection

Table 1: Liver function enzymes of control and Cisplatin treated rats and the effect of zerumbone pre-treatment

Groups	ALT (U L <sup>-1</sup> )	AST (U L <sup>-1</sup> )	ALP (U L <sup>-1</sup> )	GGT (U L <sup>-1</sup> )
ZER 100 mg kg <sup>-1</sup> + Cisplatin 45 mg kg <sup>-1</sup>	69.2000±19.61	199.92±72.427	21.66±4.32	2.50±1.10
ZER 200 + Cisplatin 45 mg kg <sup>-1</sup>	69.3500±24.27	244.23±83.737	22.44±6.60	2.66±1.21
Cisplatin 45 mg kg <sup>-1</sup>	210.220±51.67*	441.40±93.935*	49.39±10.47*	5.66±1.15*
Com oil negative control	45.9000±17.33	152.70±38.282	12.69±3.81	3.00±0.81
DMS O control	53.6000±12.22	260.92±66.288	13.67±1.70	2.25±1.70
ZER 200 mg kg <sup>-1</sup> control	48.8000±12.72	201.44±82.661	18.21±4.83	1.80±0.83
ZER 100 mg kg <sup>-1</sup> control	43.2000±3.60	159.90±61.700	13.09±3.57	1.66±0.57

ALT: Alanine aminotransferase, AST: Aspartate aminotransferase, ALP: Alkaline Phosphatase, GGT: Gamma-Glutamyl Transpeptidase, Data are expressed as mean±SD of five rats for each group. \*Denotes significant difference at 0.05

Table 2: Lesions scoring of the controls, Cisplatin or Cisplatin + ZER

Groups	Vacuolization	Activation of Kupffer cells	Sinusoidal dilatation
ZER 100 mg kg <sup>-1</sup> + cisplatin 45 mg g <sup>-1</sup>	1.67±1.1	1.33±0.38	1.10±0.0
ZER 200 mg kg <sup>-1</sup> + cisplatin 45 mg kg <sup>-1</sup>	1.00±0.7	1.00±0.00	1.60±0.5
Cisplatin 45 mg kg <sup>-1</sup>	3.00±0.0*	3.00±0.00*	3.00±0.0*
Com oil negative control	0.00±0.0	0.00±0.00	0.00±0.0
DMS O control	0.00±0.0	0.00±0.00	0.00±0.0
ZER 200 mg kg <sup>-1</sup> control	1.25±0.5	1.20±0.00	1.20±0.0
ZER 100 mg kg <sup>-1</sup> control	0.00±0.0	1.01±0.50	1.50±1.0

Data are expressed as mean±SD of five rats for each group. \*Denotes significant difference at 0.05

Table 3: The tissue Malondialdehyde (MDA) level, Glutathione (GSH) content of the control, Cisplatin-injected and zerumbone pretreated groups

Treatments	MDA (nmol g <sup>-1</sup> )	GSH (nmol g <sup>-1</sup> )
ZER 100 + CISPLATIN 45 mg kg <sup>-1</sup>	3.52±1.36	1.66±0.45
ZER 200 + CISPLATIN 45 mg kg <sup>-1</sup>	3.23±1.44	1.90±0.67
CIS PLATIN 45 mg kg <sup>-1</sup>	8.92±3.10*	0.51±0.12*
Negative control (cornoil)	1.18±0.66	0.91±0.31
DMS O Control	2.92±1.34	1.02±0.23
ZER 200 mg kg <sup>-1</sup>	3.11±0.93	1.2±0.36
ZER 100 mg kg <sup>-1</sup>	2.81±0.96	1.2±0.27

Data are expressed as mean±SD of five rats for each group. \*Significant difference at 0.05

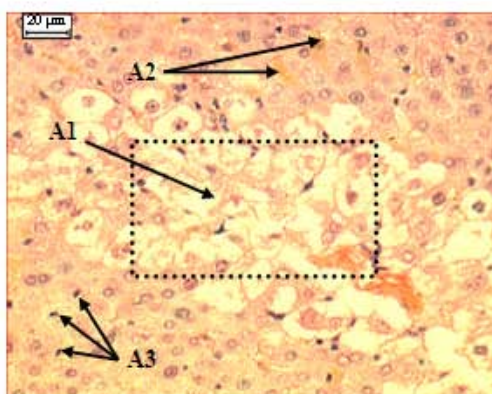


Fig. 1: A-Cisplatin 45 mg kg<sup>-1</sup>. A1: Sever degenerated hepatocytes, A2: Sever hemorrhage inside hepatocytes, A3: Increased number of activated Kupffer cells

of 45 mg kg<sup>-1</sup> Cisplatin. However, this depletion has been reversed by prior treatment of zerumbone at 100 mg kg<sup>-1</sup> and 200 mg kg<sup>-1</sup> injections (Table 3).

Findings of this current study revealed that daily zerumbone pre-treatment of rats markedly improves

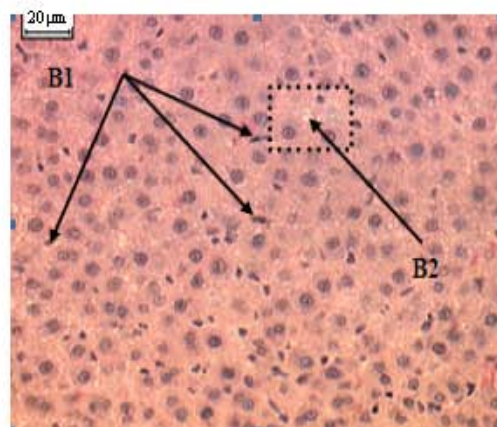


Fig. 2: B-ZII 200 mg kg<sup>-1</sup> Cisplatin 45 mg kg<sup>-1</sup>. B1: Increased number of activated Kupffer cells, B2: Mild degenerated hepatocytes

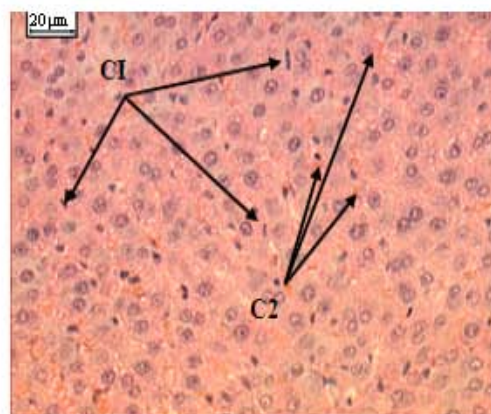


Fig. 3: C 100 mg kg<sup>-1</sup> ZII + 45 mg kg<sup>-1</sup> Cisplatin. C1: Increased number of activated Kupffer cells, C2: Sever haemorrhage inside hepatocytes



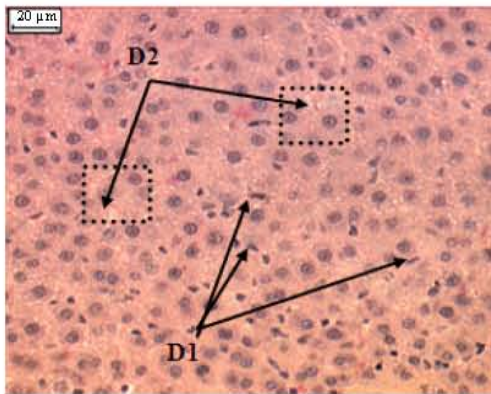


Fig. 4: D-ZII 100 mg kg<sup>-1</sup> negative control. D1: Increased number of activated Kupffer cells, D2: Mild degenerated hepatocytes (vacuolization) semi normal appearance of liver

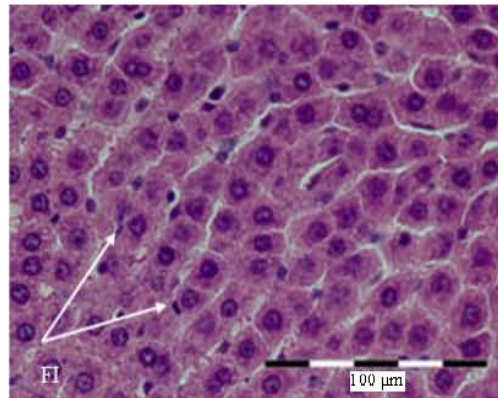


Fig. 6: F-DMSO negative control. F1: Normal number of Kupffer cells. Normal histological appearance of liver

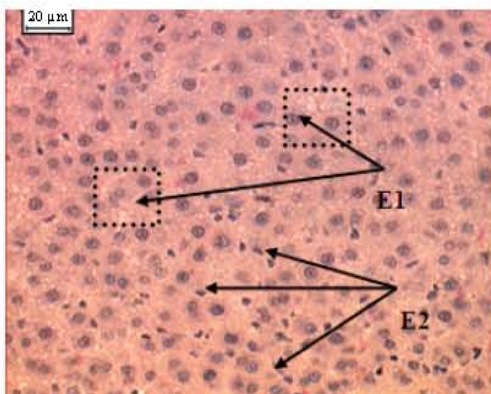


Fig. 5: E-ZII 200 mg kg<sup>-1</sup> negative control. E1: Increased number of activated Kupffer cells, E2: Mild degenerated hepatocytes (vacuolization) semi normal histological appearance of liver

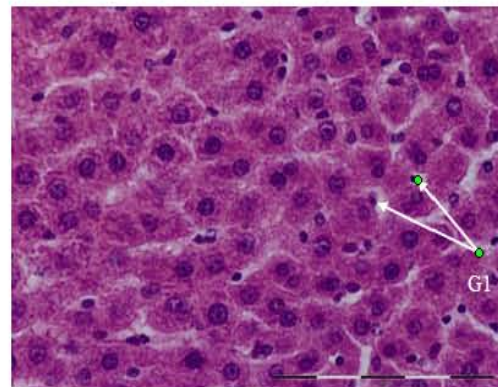


Fig. 7: G-corn oil negative control. G1: Normal number of Kupffer cells. Normal histological appearance of liver

Cisplatin-induced hepatic dysfunction and organ damage as established using histopathological examinations and biochemical assays and further evaluating hepatic oxidative damage determined by levels of GSH and MDA in rat liver tissues. Recent studies have reported the potential usage of zerumbone as an anti-cancer drug candidate (Sakinah *et al.*, 2007; Abdul *et al.*, 2008). However, little is reported regarding the actions of this compound against Cisplatin hepatotoxicity. To the knowledge, the present study is the first to investigate and to explore the use of zerumbone for preventing Cisplatin hepatotoxicity.

Platinating agents are an important class of chemotherapeutic agents for cancer, with Cisplatin and carboplatin used comprehensively in treating testicular, gynecologic, head and neck and lung carcinomas whilst another analogue, oxaliplatin, is becoming a mainstay of

colorectal cancer treatment (Rabik and Dolan, 2007). The clinical contraindications of Cisplatin are well documented as the most important dose limiting factor in cancer chemotherapy, but at high doses of Cisplatin, hepatotoxicity as well as nephrotoxicity does transpire (Weijl *et al.*, 2004). To overcome such contraindications, natural products of plant origin has been examined in their ability to do so (Hong *et al.*, 2005). Zingiberaceae is a botanical family that possesses potential hepatoprotective compounds such as curcumin from *Curcuma longa* and xanthorrhizol from *Curcuma xanthorrhiza* (Kim *et al.*, 2005). Zerumbone, a phytochemical isolated from *Zingiber zerumbet* of the Zingiberaceae family, has shown to possess chemopreventive, anti-inflammatory, free radical scavenging activities and activating properties towards phase II drug metabolizing enzymes (Murakami *et al.*, 2003; Abdul *et al.*, 2008). In addition, the cytotoxic

property of zerumbone was known to be cytoselective towards cancer cells compared to normal cells (Sakinah *et al.*, 2007).

The earlier study had shown that zerumbone acts synergistically with Cisplatin to inhibit cervical intraepithelial neoplasia induced *in utero* experimentally in female Balb/c mice. This synergism later leads to the lowering of the curative dose of Cisplatin and subsequently to its clinical complications (Abdul *et al.*, 2008).

Experimental studies in animals have shown that a minimum dose of Cisplatin (5 mg kg<sup>-1</sup> body weight) was adequate to persuade toxicity in rats (Ravi *et al.*, 1995). A higher dose of (12 mg kg<sup>-1</sup> weight) corresponds to the equivalent human dose presently being used. In this present study, a dose of Cisplatin (45 mg kg<sup>-1</sup> body weight, i.p.) was used that demonstrated significant increase in liver function enzymes, MDA and GSH as well as in causing histopathological lesions in liver; compared to normal control groups.

Biochemical evidence of hepatic injury has been demonstrated by elevated levels of ALP, AST, ALT and GGT and. In the present study, intraperitoneally administrated Cisplatin (45 mg kg<sup>-1</sup>) into Sprague Dawley rats lead to notably elevated levels of these biochemical markers. In contrary, intraperitoneal pretreatment with zerumbone (100 and 200 mg kg<sup>-1</sup>) significantly abrogated these elevations. These biochemical findings were further confirmed by evidences of microscopic examinations.

Platinating agents become aquated in cellular cytoplasm, which enables them to react with thiol-containing molecules, including Glutathione (GSH). Increased concentrations of these compounds are known to induce resistance against Cisplatin (Ali *et al.*, 2007). Glutathione itself acts as an antioxidant to the cell; it helps to maintain the redox environment while, maintaining the reduced sulfhydryl groups. Cisplatin is thought to be detoxified by the glutathione through an adduct formation (Ali *et al.*, 2006b; Hoffman *et al.*, 2002).

The present study revealed noticeable elevations in hepatic glutathione levels in rats treated with zerumbone as compared to the control, DMSO and corn oil groups. Glutathione uptake is one of the principal mechanisms of cells to sustain intracellular thiol redox status (Visarus *et al.*, 1996). Thus, it is possible to speculate that a positive regulation in the biosynthesis of glutathione may contribute to an increase in its intracellular contents. In this context, we postulated that zerumbone indirectly induces the biosynthesis of glutathione and thereby providing a protective intracellular mechanism, presumably as free radical scavenger for toxic agents.

Hoffman *et al.* (2000) had proposed a redox model of cell proliferation, which suggested an appropriate dose of zerumbone will enhance intracellular redox potential E in cancer cells. In this aspect, zerumbone is thought to

deplete intracellular reduced glutathione, thereby raising E, which in turn stops the proliferation of the cancer cells. On the other hand, normal cells increased partially the redox potential E. In relation to this, the present study indicates enhanced levels of antioxidant glutathione (reduced form) in non-cancerous rat liver tissues after pretreatment with zerumbone. We find these results interesting since pretreatment using appropriate dose of zerumbone is able to reduce Cisplatin hepatotoxicity in non-cancerous rats and with zerumbone reported to be a potential anti-cancer agent (Abdul *et al.*, 2008; Sakinah *et al.*, 2007). This could possibly mean that zerumbone is specific towards cancer cells but causing less adversity towards normal surrounding tissues, concurrently to previous findings from our laboratory (Abdul *et al.*, 2008).

Earlier data have mentioned that Cisplatin causes oxidative stress and lipid peroxidation, whereby Cisplatin induced hepatotoxicity is narrowly related to an increase in lipid peroxidation in liver tissues (Abdurrauf *et al.*, 2007). The present study using laboratory rats, liver injury develops after intraperitoneally injecting high dose of Cisplatin (45 mg kg<sup>-1</sup>). Liver toxicity becomes obvious as early as 8 h after injection, as indicated by marked elevations in the liver biomarker enzymes and MDA levels in rats liver tissues.

High numbers of natural products and dietary components have been recently evaluated as potential chemopreventive agents (Hong *et al.*, 2005). The effects of pretreatment of a natural antioxidant on Cisplatin-induced hepatic damages have been investigated and evaluated in this present study, as with other natural products and dietary components as chemopreventive agents reportedly evaluated elsewhere (Hong *et al.*, 2005; Ali *et al.*, 2007). The findings of this study however, have demonstrated.

*In vivo* that pretreatment with a natural compound zerumbone has prevented hepatic cells from further tissue damages as evidenced by the significant difference between Cisplatin alone and zerumbone pretreatment groups.

## CONCLUSION

It can be concluded that Cisplatin, when administrated at a dose of 45 mg kg<sup>-1</sup>, induced liver damages as evidenced by the qualitative and quantitative histopathology and biochemical analysis. DMSO and corn oil did not induce any crossing effect, which clearly shows the validity of the experimental design of this study. On the other hand, zerumbone pretreatment has beneficial in Cisplatin-induced liver dysfunction and organ damage in rats, presumably via the prevention of lipid peroxidation and preservation of antioxidant glutathione. We concluded that these beneficials are

responsible for providing hepatoprotective properties and hence, anti-cancer chemopreventive potential. It is therefore, strongly recommended to consider this natural compound to be a useful co-treatment for Cisplatin, particularly during treatment of cancers.

#### ACKNOWLEDGEMENTS

The researchers are grateful and would like to express their deepest appreciations to Dr. Huda Yahia Hamid, a Clinical Veterinarian Histopathologist, in evaluating the histopathology slides. The researchers would also like to express their appreciation to The National Cancer Counsel of Malaysia (MAKNA) and Research University Grant Scheme (RUGS) for providing financial supports in this study.

#### REFERENCES

- Abdul, A.B., S.A. Adel, D.T. Nirmala, I.A. Siddig, N.Z. Zetty and R. Sharin *et al.*, 2008. Anticancer Activity of Natural Compound (Zerumbone) Extracted from *Zingiber zerumbet* in Human HeLa Cervical Cancer Cells. *Int. J. Pharmacol.*, 4 (3): 160-168. DOI: 10.3923/ijp.2008.160.168.
- Abdurrauf, Y., Ahmet, Atessahin, O.C. Ali and A. Mesut, 2007. Ellagic acid prevents Cisplatin 10 mg kg<sup>-1</sup> platin-Induced oxidative stress in liver and heart tissue of rats. *Basic Clin. Pharmacol. Toxicol.*, 101: 345-349. PMID: 17910619.
- Aggarwal, B.B. and S. Shishodia, 2006. Molecular targets of dietary agents for prevention and therapy of cancer. *Biochem. Pharmacol.*, 71: 1397-1421. PMID: 16563357.
- Ali, B.H., M. Al-Moundhri, M. Tageldin, I.S. Al-Husseini, M.A. Mansour and A. Nemmar *et al.*, 2006a. Ontogenic aspects of cisplatin-induced nephrotoxicity in rats. *Food Chem. Toxicol.*, 46: 3355-3359. PMID: 18790000.
- Ali, B.H., M. Al-Moundhri, M. Tageldin, I.S. Al-Husseini, M.A. Mansour, A. Nemmar and M.O. Tanira, 2006b. Ontogenic aspects of Cisplatin 10 mg kg<sup>-1</sup> platin-induced nephrotoxicity in rats. *Food Chem. Toxicol.*, 46: 3355-3359. DOI: 10.1016/j.fct.2008.07.030.
- Ali, B.H., M.S. Al-Moundhri, M. Tag-Eldin, A. Nemmar and M.O. Tanira, 2007. The ameliorative effect of cysteine prodrug L-2-oxothiazolidine-4-carboxylic acid on Cisplatin 10 mg/kg platin-induced nephrotoxicity in rats. *Fundam Clin. Pharmacol.*, 21: 547-553. PMID: 17868208.
- Aykac, G., M. Uysal, A.S. Yalcin, N. Kocak-Toker, A. Sivas and H. Öz, 1985. The effect of chronic ethanol ingestion on hepatic lipid peroxide, glutathione peroxidase and glutathione transferase in rats. *Toxicology*, 36: 71-76. PMID: 4040665.
- Blakley, B.W., J.I. Cohen, N.D. Doolittle, L.L. Muldoon, K.C. Campbell and D.T. Dickey, 2001. Strategies for prevention of toxicity caused by platinum-based chemotherapy. *Laryngoscope*, 112: 1997-2001. PMID: 12439169.
- Chien, T.Y., L.G. Chen, C.J. Lee, F.Y. Lee and C.C. Wang, 2008. Anti-inflammatory constituents of *Zingiber zerumbet*. *Food Chem.*, 110: 584-589. DOI: 10.1016/j.foodchem.2008.02.038.
- Ekbom, A., A. Lindberg, G. Laurell, I. Wallin, S. Eksborg and H. Ehrsson, 2003. Ototoxicity, nephrotoxicity and pharmacokinetics of Cisplatin 10 mg kg<sup>-1</sup> platin and its monohydrated complex in the guinea pig. *Cancer Chemother Pharmacol.*, 51: 36-42. PMID: 12497204.
- Fetoni, A.R., B. Sergi, A. Ferraresi, G. Paludetti and D. Troiani, 2004. Protective effects of  $\alpha$ -tocopherol and tiopronin against Cisplatin 10 mg kg<sup>-1</sup> platin-induced ototoxicity. *Acta Otolaryngol.*, 124: 421-426. PMID: 15224867.
- Hoffman, A., L.M. Spetner and M. Burke, 2002. Redox-regulated mechanism may account for zerumbone's ability to suppress cancer-cell proliferation. *Carcinogenesis*, 23: 1961. PMID: 12419847.
- Hong, K.O., J.K. Hwang, K.K. Park and S.H. Kim, 2005. Phosphorylation of c-Jun N-terminal Kinases (JNKs) is involved in the preventive effect of xanthorrhizol on Cisplatin 10 mg kg<sup>-1</sup> platin-induced hepatotoxicity. *Arch. Toxicol.*, 79: 231-236. PMID: 15536542.
- Iraz, M., M.T. Kalcioğlu, A. Kizilay and E. Karatas, 2005. Amino guanidine prevents ototoxicity induced by Cisplatin 10 mg kg<sup>-1</sup> platin in rats. *Ann. Clin. Lab. Sci.*, 35: 329-335. PMID: 16081592.
- Iraz, M., E. Ozerol, M. Gulec, S. Tasdemir, N. Idiz and E. Fadillioglu, 2006. Protective effect of Caffeic Acid Phenethyl Ester (CAPE) administration on Cisplatin 10 mg kg<sup>-1</sup> platin-induced oxidative damage to liver in rat. *Cell. Biochem. Funct.*, 24: 357-361. PMID: 16437419.
- Iseri, S., F. Ercan, N. Gedik, M. Yuksel and I. Alican, 2007. Simvastatin attenuates Cisplatin 10 mg kg<sup>-1</sup> platin-induced kidney and liver damage in rats. *Toxicology*, 230: 256-264. PMID: 18406033.
- Kalkanis, J.G., C. Whitworth and L.P. Rybak, 2004. Vitamin E reduces Cisplatin 10 mg kg<sup>-1</sup> platin ototoxicity. *Laryngoscope*, 114: 538-542.
- Kasparkova, J., O. Delalande, M. Stros, M.A. Elizondo-Riojas, M. Vojtiskova, J. Kozelka and V. Brabec, 2004. Recognition of DNA interstrand cross-link of antitumor Cisplatin 10 mg kg<sup>-1</sup> platin by HMGB1 protein. *Biochemistry*, 42: 1234-1244. PMID: 15091231.
- Kim, S.H., K.O. Hong, J.K. Hwang and K.K. Park, 2005. Xanthorrhizol has a potential to attenuate the high dose Cisplatin 10 mg kg<sup>-1</sup> platin-induced nephrotoxicity in mice. *Food Chem. Toxicol.*, 43: 117-22. DOI: 10.1016/j.fct.2004.08.018.

- Koc, A., M. Duru, H. Ciralik, R. Akcan and S. Sogut, 2005. Protective agent, erdosteine, against Cisplatin 10 mg kg<sup>-1</sup> platin-induced hepatic oxidant injury in rats. *Mol. Cell. Biochem.*, 278: 79-84. PMID: 16180092.
- Leitao, D.J. and B.W. Blakley, 2003. Quantification of sodium thiosulphate protection on Cisplatin 10 mg kg<sup>-1</sup> platin-induced toxicities. *J. Otolaryngol.*, 32: 146-150. PMID: 12921131.
- Leonetti, C., A. Biroccio, C. Gabellini, M. Scarsella, V. Maresca and E. Flori, 2003. Alpha-tocopherol protects against Cisplatin 10 mg kg<sup>-1</sup> platin-induced toxicity without interfering with antitumor efficacy. *Int. J. Cancer*, 104: 243-250. PMID: 12569582.
- Liao, Y.J., H. Tang and Y.P. Jin, 2004. Study of toxic effects on hearing, kidney and liver of mice induced by anticancer agent of Cisplatin 10 mg kg<sup>-1</sup> platin and their mechanisms. *Chin. Pharmacol. Bull.*, 20: 82-85. DOI: 10.1016/j.phrs.2008.01.001.
- Liu, J., Y. Liu, S.S. Habeebu and C.D. Klaassen, 1998. Metallothionein (MT)-null mice are sensitive to cisplatin-induced hepatotoxicity. *Toxicol. Appl. Pharmacol.*, 149: 24-31. PMID: 9512723.
- Lu, Y. and A.I. Cederbaum, 2006. Cisplatin 10 mg kg<sup>-1</sup> platin-induced hepatotoxicity is enhanced by elevated expression of cytochrome P450 2E1. *Toxicol. Sci.*, 89: 515-523. PMID: 16251482.
- Mansour, H.H., H.F. Hafez and N.M. Fahmy, 2006. Silymarin modulates Cisplatin 10 mg kg<sup>-1</sup> platin-induced oxidative stress and hepatotoxicity in rats. *J. Biochem. Mol. Biol.*, 39: 656-661. PMID: 17129399.
- Murakami, A., R. Hayashi, T. Takana, K.H. Kwon, H. Ohigashi and R. Safitri, 2003. Suppression of dextran sodium sulfate-induced colitis in mice by zerumbone, a subtropical ginger sesquiterpene and nimesulide: Separately and in combination. *Biochem. Pharmacol.*, 66: 1253-1261. PMID: 14505804.
- Nowak, G., 2002. Protein kinase C- $\alpha$  and ERK1/2 mediate mitochondrial dysfunction, decreases in active Na<sup>+</sup> transport and Cisplatin 10 mg kg<sup>-1</sup> platin-induced apoptosis in renal cells. *J. Biol. Chem.*, 277: 43377-43388. PMID: 12218054.
- Pratibha, R., R. Sameer, P.V. Rataboli, D.A. Bhiwgade and C.Y. Dhume, 2006. Enzymatic studies of Cisplatin 10 mg kg<sup>-1</sup> platin induced oxidative stress in hepatic tissue of rats. *Eur. J. Pharmacol.*, 532: 290-293. PMID: 16458885.
- Rabik and Dolan, 2007. Molecular mechanisms of resistance and toxicity associated with platinating agents. *Cancer Treat Rev.*, 33: 9-23. PMID: 17084534.
- Ramesh, G. and W.B. Reeves, 2002. TNF- $\alpha$  mediates chemokine and cytokine expression and renal injury in Cisplatin 10 mg kg<sup>-1</sup> platin nephrotoxicity. *J. Clin. Invest.*, 110: 835-842. PMID: 12235115.
- Ravi, R.S., S.M. Somini and L.P. Rybak, 1995. Mechanism of cisplatin ototoxicity. Antioxidant system. *Pharmacol. Toxicol.*, 76: 386-394. PMID: 7479581.
- Sakinah, S.A., S.T. Handayani and L.P. Hawariah, 2007. Zerumbone induced apoptosis in liver cancer cells via modulation of Bax/Bcl-2 ratio. *Cancer Cell. Int.*, 7: 4. PMID: 17407577.
- Surh, Y.J., 1999. Molecular mechanisms of chemopreventive effects of selected dietary and medicinal phenolic substances. *Mutation Res. Fundamental Mol. Mechanisms of Mutagenesis*, 428: 305-327. PMID: 10518003.
- Takada, Y., A. Murakami and B.B. Aggarwal, 2005. Zerumbone abolishes NF- $\kappa$ B and I $\kappa$ B kinase activation leading to suppression of antiapoptotic and metastatic gene expression, upregulation of apoptosis and downregulation of invasion. *Oncogene*, 24: 6957-6969. DOI: 10.1038/sj.onc.1208845.
- Townsend, D.M. and M.H. Hanigan, 2002. Inhibition of gamma-glutamyl transpeptidase or cysteine S-conjugate beta-lyase activity blocks the nephrotoxicity of Cisplatin 10 mg kg<sup>-1</sup> platin in mice. *J. Pharmacol. E. Ther.*, 300: 142-148.
- Visarus, T.M., D.A. Putt, J.M. Schare, D.M. Pegouske and L.H. Lash, 1996. Pathways of glutathione metabolism and transport in isolated proximal tubular cells from rat kidney. *Biochem. Pharmacol.*, 52: 259-272. PMID: 8694851.
- Weijl, N.I., T.J. Elsendoom, E.G. Lentjes, G.D. Hopman, A. Wipkink-Bakker and A.H. Zwinderman, 2004. Supplementation with antioxidant micronutrients and chemotherapy-induced toxicity in cancer patients treated with Cisplatin 10 mg kg<sup>-1</sup> platin-based chemotherapy: A randomised, double-blind, placebo-controlled study. *Eur. J. Cancer*, 40: 1713-1723. PMID: 15251161.
- Xiao, T., S. Choudhary, W. Zhang, N.H. Ansari and A. Salahudeen, 2003. Possible involvement of oxidative stress in Cisplatin 10 mg kg<sup>-1</sup> platin-induced apoptosis in LLC-PK1 cells. *J. Toxicol. Environ. Health A.*, 66: 469-479. PMID: 12712633.
- Yao, X., K. Panichpisal, N. Kurtzman and K. Nugent, 2007. Cisplatin 10 mg kg<sup>-1</sup> platin nephrotoxicity: A review. *Am. J. Med. Sci.*, 334: 115-124. PMID: 17700201.
- Yingjun, L., L. Xiuqiang, L. Chunwei, L. Gexin, J. Yaping and Hao Tang, 2008. Selection of agents for prevention of cisplatin-induced hepatotoxicity. *Pharmacol. Res.*, 57: 125-131. PMID: 18282716.