

Cellular Expression of Zonula Occludens-1 Protein in Benign Neurofibroma and Normal Peripheral Nerves

¹M.H. Sulaiman, ²C.A. Kudi, ¹J.O. Hambolu, ¹S.A. Ojo, ³I.M. Hussaini, ⁴M.M. Roebuck, ⁵A.R. Dodson, ⁵T.R. Helliwell, ⁴Q. Yin and ⁴S.P. Frostick

¹Department of Veterinary Anatomy,

²Department of Veterinary Surgery and Medicine, Faculty of Veterinary Medicine,

³Department of Pharmacology and Pharmaceutical Chemistry,

Faculty of Pharmaceutical Science, Ahmadu Bello University, Zaria, Nigeria

⁴Division of Surgery and Oncology, ⁵Department of Pathology, School of Cancer Studies, University of Liverpool, UK

Abstract: Cell-cell attachment in the epithelial and endothelial cell sheets are held in place by tight junctions, adherens junctions and desmosomes. Tight junctions are made up of three integral membrane proteins, namely; claudins, occludin and junctional adhesion molecules. There is a wealth of evidence in the literature suggesting that tight junctions are primarily involved in the sealing of cellular sheets thereby regulating paracellular ion movements between sheets of epithelial cells. Thus, tight junction proteins constitute an essential part of this barrier in perineurial and endothelial cells particularly in peripheral nerves. Schwann cells in the peripheral nerves are isolated from the adjacent tissues by the perineurium which creates a diffusion barrier responsible for the maintenance of endoneurial stability. Some researchers have suggested that oncogenic Ras down regulates tight junction barrier functions thereby leading to the disruption of these barriers. Therefore, the loss of tight junction barriers function may enable growth factors to penetrate from the surrounding tissues to quiescent Schwann cells of the peripheral nerves that are capable of proliferation thus, ensuing neurofibroma formation. Here the researchers demonstrate the cellular expression of Zonula Occludens-1 (ZO-1) to the perineurial fibroblasts of the normal peripheral nerve and benign neurofibroma.

Key words: Peripheral nerves, benign neurofibroma, ZO-1, perineurial fibroblast, autosomal, Nigeria

INTRODUCTION

Neurofibromatosis type 1 (NF1) is one of the common autosomal disorders in human with an estimated birth incidence of 1/3500 people worldwide (Korf, 1999). NF1 affects virtually all body tissues and organs.

Neurofibromas are heterogeneous and complex benign tumours consisting mostly of Schwann cells and fibroblasts and other cell types such as axons, perineurial cells, mast cells, pericytes, endothelial cells, smooth muscle cells, collagen and cells with intermediate features (Peltonen *et al.*, 1988; Korf, 1999). Schwann cells are reported to constitute the major cell type (40-80%) in neurofibromas because they exhibited biallelic mutation of the *NF1* gene (Serra *et al.*, 2002) and by positively staining with the S-100 β protein (Peltonen *et al.*, 1988).

A benign neurofibroma is regarded as familial where there is family history and multiple clinical signs of neurofibroma such as cafe au lait spots, Lisch nodules of

the iris, axillary and inguinal freckling and hyperpigmentation of the skin. The *NF1* gene is mapped to chromosome 17, (17p21). Its protein product, neurofibromin negatively regulate Ras (Serra *et al.*, 2002). Therefore, in Schwann cells loss of function of neurofibromin may promote cell proliferation. In peripheral nerves, Schwann cell-axon relationship is thought to be isolated from the adjacent tissues by the perineurium which creates a diffusion barrier formed by the tight junction.

Tight junctions are specialized cell-cell point of adhesion at the apical region of epithelial and endothelial cells. The tight junction creates a barrier to regulate paracellular transport of solutes (barrier function) between cells and also restrict lateral diffusion (fence function) of molecules so as to maintain cell polarity (Kristensson and Olsson, 1971). Tight junction proteins have been suggested to constitute an essential part of this barrier in perineurial and endothelial cells (Todd *et al.*, 2000;

Hirose *et al.*, 2003). Previous studies using cell markers such as Epithelial Membrane Antigen (EMA) have demonstrated perineurial cells in neurofibroma (Folpe *et al.*, 2002; Ide *et al.*, 2004).

The Ras proteins regulate many cellular signalling pathways associated with cell growth, proliferations, cell adhesion, survival and differentiation (Serra *et al.*, 2002). The pathways associated with Ras activation are of immense physiological and medical importance for their roles in the regulation of proliferation of both normal and transformed cells. Three major isoforms of Ras has been described in the literature. Ras has been demonstrated by various workers to mediate growth factor and extracellular matrix signaling but it also influences cell-cell adhesion (Serra *et al.*, 2002). Many signaling pathways including the Raf pathway are activated by Ras and are thought to regulate cell-cycle entry (Marshall, 1999).

Furthermore, it has been postulated that Ras down regulates tight junction barrier functions through the phosphorylation of tight junction proteins such as ZO-1 and Occludin which would lead to the disruption of tight junction barriers formed by these proteins (Roh and Margolis, 2003). Additionally, the Ras protein has been shown to disrupt cell-cell contacts in mouse fibroblast and decreases the amount of both Afadin-6 (AF-6) and ZO-1 at the cell surface (Boettner *et al.*, 2000). Therefore, it has been suggested that Ras induced disruption of cell-cell interactions may be an initial step in tumourigenesis and may be mediated in part through the AF-6/ZO-1 complex (Gottfried *et al.*, 2006).

It is therefore, important that in order to understand how tumour development and progression correlates to cellular changes in tight junction expression and localisation, the knowledge into how and why the tight junction assembly is altered is important. Therefore, this study was carried out to demonstrate the cellular localisation of tight junction proteins, Zonula Occludens-1 protein in benign neurofibroma and peripheral nerves.

MATERIALS AND METHODS

Nerve sheath tumours samples were obtained from patients who attended and were clinically diagnosed with peripheral nerve sheath tumours in the Royal Liverpool and Broadgreen University Hospitals Trust from July 1993 to March 2007. The nerve sheath tumours comprises of 12 females and 10 males with the mean age of 53 years. Normal peripheral nerves (6) were harvested from amputation stumps from patients with no history of any neuropathy or neurogenic tumour. The normal peripheral nerves were utilised as comparative tissue while the

colon, tonsils and the brain serve as positive control tissues. Prior informed patient consent was obtained and the study has an ethical approval.

Tissue collection and fixation: Immediately following standard surgical resections, tissues were collected from Broadgreen hospital and transported on ice to the Royal Liverpool Hospital UK (takes about 60-90 min). Once in the pathology department, a specialist pathologist conduct the macro examination of the resected tissue and the tissue is carefully placed in a pot containing 10% buffered formalin. However, tissues collected prior to January 2000 were immersed in formalin after resection in the theatre.

About 24-48 h following the fixation, specimens are embedded in paraffin wax and 4 µm sections taken. Routine histological procedures such as staining with Haematoxylin and Eosin (H and E) were carried out. Tissue sections were later stain with cell lineage markers such as S-100, EMA and CD31.

Protocol:

- Formalin-fixed, paraffin-embedded, 3-4 µm sections mounted on superfrost slides were deparaffinised rehydrated in graded alcohol to distilled water
- Endogenous peroxidase activity was blocked using 3% hydrogen peroxide in methanol for 12 min
- Sections were then washed in deionised water for 5 min
- Antigen retrieval was carried out using pressure cooker filled 10 mM EDTA (pH7.0) and treated at full pressure for 3 min
- Following heating, the slides were allowed to cool down at room temperature for 15-20 min
- The slides were then rinsed in PBS (3X) before the commencement of the immunostaining
- Immunohistochemical staining was carried out using an automated staining system (Autostainer; DakoCytomation, Ely, Cambridgeshire, UK)
- Slides were then incubated for 40 min with primary antibodies
- The slides were washed in PBS; the sections were then sequentially incubated with the DakoCytomation ChemMate En Vision Detection Kit, (DakoCytomation, Ely, UK)
- The chromogen, 3, 3, Diaminobenzidine (DAB) was applied for 20 min at room temperature
- Between each step, sections were washed in Tris-buffered saline
- The washed sections were counterstain with haematoxylin and dehydrated in graded alcohol and xylene, coverslips mounted with D.P.X mountant (BDH)

- The normal peripheral nerves were utilised as a comparative tissue while the colon, tonsils and the brain tissues variously serve as positive control
- Negative controls were incubated without the primary antibodies
- The immunostained slides were examined with light microscope (Nikon Eclipse E600 Japan)

Method of evaluation (Scoring): The immunohistological sections were scored based on the intensity of staining are the percentage of cellular distribution of the staining. For the purpose of this study, the quick score method of assessment (Barnes *et al.*, 1996) was utilised to assess the immunostaining in all the tissues used in this study.

RESULTS AND DISCUSSION

Haematoxylin-Eosin stain (H and E): The H and E of the normal nerve demonstrated an outer zone of Epineurium (E), a middle Perineurial zone (P) and an inner Endoneurium (En) (Fig. 1). The H and E demonstrated the normal architectural arrangement of the normal nerve with distinct anatomical zones of the nerve.

The perineurial fibroblasts of the normal peripheral nerve were demonstrated to be Epithelial Membrane Antigen (EMA) (Cat#08-4236 Zymed) positive immunohistochemically as has been shown by other workers. The immunopositivity was restricted to the perineurial fibroblasts of the normal peripheral nerve only Fig. 2.

The normal peripheral nerves were immunostained with rabbit polyclonal anti-ZO-1 (Cat# 61-7300 Zymed). The immunoreactivity of the ZO-1 was observed to be expressed by endothelial cells (moderate immunostaining) together with an intense perineurial fibroblasts staining (Fig. 3). The benign neurofibroma showed an immunolabelling pattern similar but less intense as

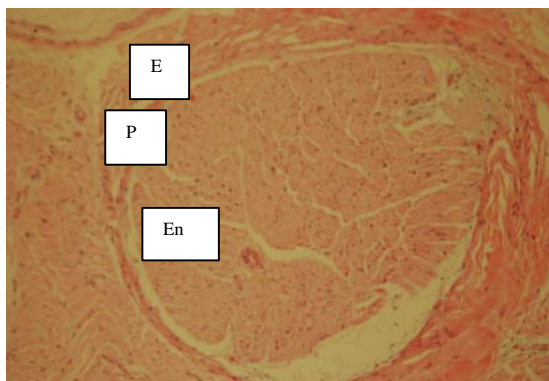


Fig. 1: H and E of normal peripheral nerve showing the Epineurium (E), Perineurium (P) and Endoneurium (En) x40

compared with those observed in the normal nerve when immunostained with rabbit polyclonal anti ZO-1. The immunoreactivity of anti-ZO-1 was noticed with the endothelial cells and the perineurial fibroblasts (moderate) immunostaining (Fig. 4 and 5).

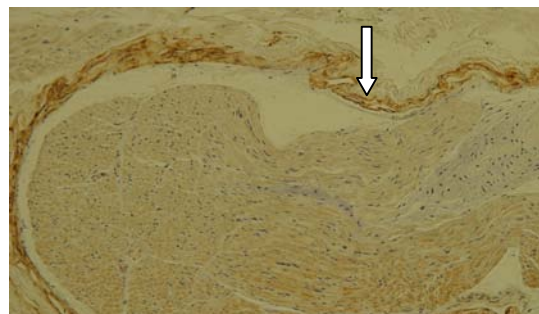


Fig. 2: Epithelial Antigen Membrane (EMA) on the perineurial fibroblasts of the normal peripheral nerve (arrow) x100

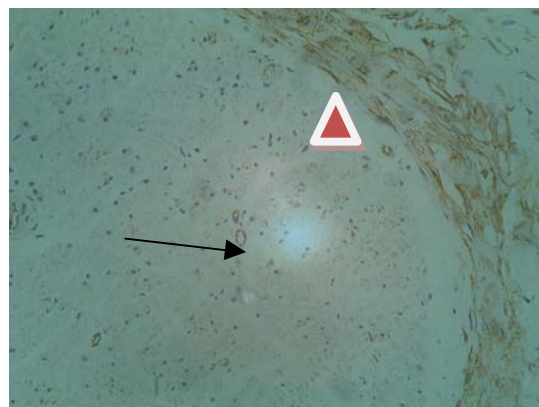


Fig. 3: ZO-1 immunoreactivity on the perineurial fibroblast (arrow head) and the endothelial cells (arrow) of the normal peripheral nerve (x400)

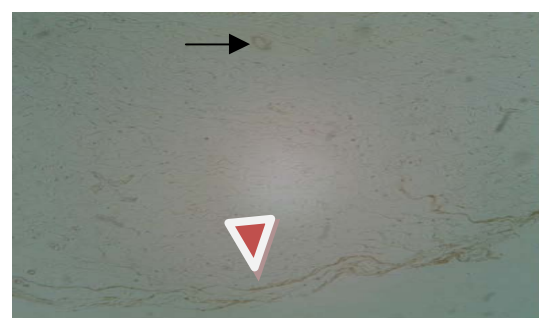


Fig. 4: ZO-1 immunolocalisation on the perineurial fibroblast (arrow head) and the endothelial cells (arrow) (x200)

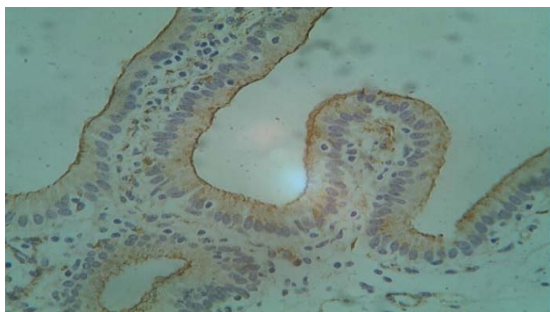


Fig. 5: Positive control, Gall bladder x200

Zonula occludens-1 (ZO-1) a 210-225 kDa is a member of membrane associated guanylate kinase homologues believed to be associated with signal transduction at the sites of cell-cell contact (Gottardi *et al.*, 1996). ZO-1 is a phosphoprotein that is peripherally associated with the cytoplasmic surface of tight junctions in epithelial and endothelial cells. In this study, the perineurial localisation of ZO-1 was observed to be selectively loss in some of the benign neurofibroma specimens. Thus, it seems likely that in NF1, the cellular expression of ZO-1 at the cell-cell membrane is altered. Instead, nuclei localisation of ZO-1 was observed in Schwann cell-like cells within these pathologies. Due to the change in the cellular localisation of the ZO-1 from membrane to nucleus in these pathologies, the scaffolding function of ZO-1 may therefore be affected. This may invariably affect the barrier function of the tight junctions in the benign neurofibromas. Though the functional significance of the nuclear localisation of ZO-1 in benign neurofibromas is poorly understood, the researchers suggest that this distinct nuclei localisation of ZO-1 in benign neurofibromas might not be unconnected with the loss of functional integrity of the cell-cell contact in these lesions. Furthermore, the cell type exhibiting this nuclei staining is the Schwann cell-like cells in all the tissue samples thus, representing the likely proliferating cell population within the neurofibroma studied. Indeed, Gottardi *et al.* (1996) have demonstrated ZO-1 nuclear staining in subconfluent but not confluent cell cultures. Additionally, these researchers (Gottardi *et al.*, 1996) have further suggested that the nuclear accumulation of ZO-1 can indeed be stimulated at the sites of wounding in epithelial cell cultures. Hence, suggesting a potential phenomenon of nuclei translocation of ZO-1 in cells that are actively dividing.

In contrast, the immuno labelling pattern of anti-ZO-1 in the peripheral nerves was restricted to the perineurium (intense staining) and the endothelial cells (strong staining) of the vascular tissues. This is consistent with the reports of (Kanda *et al.*, 2004) which reported that the

anti-ZO-1 immunoreactivity in chronic inflammatory demyelinating polyneuropathy to be localised to the perineurial cell layer and the endothelial cells lining the blood vessels of the epineurial and endoneurial layers of the peripheral nerve. Furthermore, these workers reported lack of significant decreased in ZO-1 immunoreactivity on the endothelial cells (Kanda *et al.*, 2004). On the contrary, (Smalley *et al.*, 2005) demonstrated an increased expression of ZO-1 in melanoma specimen and further alluded to the fact that the inhibition of ZO-1 expression by siRNA could result in the loss of metastatic potential in the melanoma cells. Thus, suggesting that ZO-1 is involved in regulation of metastasis in melanoma cell. In a rather different study (Bullen *et al.*, 2006) reported the localisation of ZO-1 to be restricted to the apical pole of the immediate neighbouring cells of the cell that are apoptotic (Shedding cells).

CONCLUSION

The researchers observed that the expression of ZO-1 in peripheral nerves was localised intensely to the perineurial fibroblasts and the endothelial cells of the peripheral nerves while in the benign neurofibroma, the intensity of the immunolocalisation of ZO-1 was weak on the perineurial fibroblast and the endothelial cells. Further studies will focus on cellular localisation of other tight junction proteins in benign neurofibromas and other neurogenic tumours.

ACKNOWLEDGEMENTS

The researchers wish to acknowledge the assistance rendered by the staff members of the tissue bank of the Department of Pathology, School of Cancer Studies, University of Liverpool. The researchers are also grateful to Niger state Government of Nigeria for funding of this study.

REFERENCES

- Barnes, D.M., W.H. Harris, P. Smith, R.R. Millis and R.D. Rubens, 1996. Immunohistochemical determination of oestrogen receptor: Comparison of different methods of assessment of staining and correlation with clinical outcome of breast cancer patients. *Br. J Cancer*, 74: 1445-1451.
- Boettner, B., E. Govek, J. Cross, L.V. Aelst, 2000. The junctional multidomain protein AF-6 is a binding partner of Rap1A GTPase and associates with the actin cytoskeletal regulator profilin. *Proc. Natl. Acad. Sci. USA.*, 97: 9064-9069.

- Bullen, T.F., S. Forrest, F. Campbell, A.R. Dodson and M.J. Hershman *et al.*, 2006. Characterization of epithelial cell shedding from human small intestine. *Lab. Invest.*, 86: 1052-1063.
- Folpe, A.L., S.D. Billings, J.K. McKenney, S.V. Walsh, A. Nusrat and S.W. Weiss, 2002. Expression of claudin-1, a recently described tight junction-associated protein, distinguishes soft tissue perineurioma from potential mimics. *Am. J. Surg. Pathol.*, 26: 1620-1626.
- Gottardi, C.J., M. Arpin, A.S. Fanning and D. Louvard, 1996. The junction-associated protein, zonula occludens-1, localizes to the nucleus before the maturation and during the remodeling of cell-cell contacts. *Proc. Natl. Acad. Sci. USA.*, 93: 10779-10784.
- Gottfried, O.N., D.H. Viskochil, D.W. Fulst and W.T. Couldwell, 2006. Molecular, genetic and cellular pathogenesis of neurofibromas and surgical implications. *Neurosurgery*, 58: 1-16.
- Hirose, T., T. Tani, T. Shimada, K. Ishizawa, S. Shimada and T. Sano, 2003. Immunohistochemical demonstration of EMA/Glut1-positive perineurial cells and CD34-positive fibroblastic cells in peripheral nerve sheath tumours. *Mod. Pathol.*, 16: 293-298.
- Ide, F., T. Shimoyama, N. Horie and K. Kusama, 2004. Comparative ultrastructural and immunohistochemical study of perineurioma and neurofibroma of the oral mucosa. *Oral Oncol.*, 40: 948-953.
- Kanda, T., Y. Numata and H. Mizusawa, 2004. Chronic inflammatory demyelinating polyneuropathy decreased claudin-5 and relocate ZO-1. *J. Neurol. Neurosurg Psychiatry*, 75: 765-769.
- Korf, B.R., 1999. Neurofibromas and Malignant Tumours of the Peripheral Nerve Sheath. In: *Neurofibromatosis: Phenotype, Natural History and Pathogenesis*, Friedman, J.M., D.H. Gutmann, M. MacCollin and V.M. Riccardi (Eds.). John Hopkins University Press, Baltimore, pp: 142-161.
- Kristensson, K. and Y. Olsson, 1971. The perineurium as a diffusion barrier to protein tracers. Differences between mature and immature animals. *Acta Neuropathol.*, 17: 127-138.
- Marshall, C., 1999. How do small GTPase signal transduction pathways regulate cell cycle entry? *Curr. Opin. Cell Biol.*, 11: 732-736.
- Peltonen, J., S. Jaakkola and M. Lebowohl, 1988. Cellular differentiation and expression of matrix genes in type 1 Neurofibromatosis. *Lab. Invest.*, 59: 760-771.
- Roh, M.H. and B. Margolis, 2003. Composition and function of PDZ protein complexes during cell polarization. *Am. J. Physiol. Renal. Physiol.*, 285: F377-F387.
- Serra, E., T. Rosenbaum and U. Wimmer, 2002. Schwann cells harbour the somatic NF1 mutation in neurofibromas: Evidence of two different Schwann cell populations. *Hum Mol. Genet.*, 20: 3055-3064.
- Smalley, K.S., P. Brafford, N.K. Haass, J.M. Brandner, E. Brown and M. Herlyn, 2005. Up-regulated expression of zonula occludens protein-1 in human melanoma associates with N-cadherin and contributes to invasion and adhesion. *Am. J. Pathol.*, 166: 1541-1554.
- Todd, B.A., C. Inman, E.M. Sedgwick and N.J. Abbott, 2000. Ionic permeability of the sciatic nerve perineurium, examined using electrophysiological and electron microscopic techniques. *Brain Res.*, 867: 223-231.