

Complications Following Lower Third Molar Surgery in a Specific Age Group: A Prospective Study

¹P. Kafas, ²W. Jerjes, ²C. Hopper and ³S. Dalabiras

¹Department of Oral Surgery and Radiology, School of Dentistry, Aristotle University, Thessalonica, Greece

²Department of Oral and Maxillofacial Surgery, Eastman Dental Institute and Hospital for Oral Health Care and Science, London, UK

³Department of Oral and Maxillofacial Surgery, School of Dentistry, Aristotle University, Thessalonica, Greece

Abstract: This prospective study reports the postoperative complications rate in third molar surgery in patients aged 30-36 years. Patients recruited from two dental hospitals in England and Greece. Standardized data collection included the patient's name, age, gender, radiographic position of extracted tooth, grade of surgeon, closeness to inferior dental nerve, postoperative complications, smoking status and the intake of oral contraceptives by females. The results of this study showed that infection and abscess, trismus, swelling, bleeding, sore throat, dry socket, problematic healing were not significantly different to younger groups from other studies. The lip sensation using chi-squared found to correlated significantly in patients 30-36 years old ($p < 0.05$) but the results are not considered precise due to differences in homogeneity between this and other studies. Complications in this specific age group were not higher than other age groups when patients are younger; this study does not support the prophylactic removal of third molars.

Key words: Wisdom teeth, complications, age, third molar, smoking, status

INTRODUCTION

The dental arches usually undergo antero-posterior growth trying to accommodate for all the permanent molars especially the third molars that are known to be the last to erupt. Many problems are associated with their eruption like tenderness, swelling or infection and a considerable number of them become buried in the jawbone that requires surgical intervention for its removal.

Removal of third molars is one of the most common surgical procedures in the specialty of oral and maxillofacial surgery (Singh *et al.*, 1996). Postoperative complications like pain, bleeding, swelling, infection, nerve paraesthesia or dysfunction need the immediate attention of the clinical team (Benediktsdottir *et al.*, 2004). The factors that usually contribute to such problems are numerous and include the patient, tooth-related and the surgeon's operative experience.

Retrospective cohort studies of patients undergoing surgical removal of third molars showed that complication rate could vary between 4.6-8.2% (Tay, 2000; Christiaens and Reyhler, 2002; Bui *et al.*, 2003). The most common complaints were found to be pain, trismus, swelling, bleeding, sore throat, dry socket, poor or delayed healing, abscess formation, infection and sensory nerve alteration.

A study by Yoshii *et al.* (2001) indicated that removing impacted third molars in patients under the age of 30 can reduce the incidence of infection. In another study, Black (1997) concluded that removing them by the age of 20 can reduce the risk of sensory impairment. A number of studies have recommended the removal of mandibular third molars in younger ages to avoid the need to remove them in older ages when they became symptomatic which can lead to undesirable complications (Stanley *et al.*, 1988; Christiaens and Reyhler, 2002; Bui *et al.*, 2003).

Purpose of this prospective study was to evaluate the significance of the age as a principal factor in complications following the surgical removal of mandibular third molars.

MATERIALS AND METHODS

The records of 210 patients (131 females, 79 males), age 30-36 years old undergoing surgical removal of third molar teeth were prospectively collected. This included patients from the Eastman Dental Hospital (London) and at the Dental School, Aristotle University (Thessalonica). The cases were analysed to examine incidence of any postoperative complications.

For each patient, the following data was collected:

- Age
- Gender
- Radiographic position (fully erupted, partially impacted or fully impacted)
- Treating surgeon (senior or junior)
- Surgical technique (described below)
- Closeness to inferior dental nerve (tooth \leq 2 mm is considered to be close)
- Duration of surgery
- Postoperative complications (measured 1 week postoperatively)

Inflammation: Local reddening and swelling of the area following the surgical insult.

Infection: Opening a flap and exposing the underlying tissue to various microbes can lead to infection; patients were recorded as having an infection if they presented with severe pain, swelling and inflammation after the initial swelling subsided.

Abscess: Abscess can be felt clinically by bi-manual palpation; associated signs and symptoms include pain, pyrexia, swelling, inflammation, trismus and pus discharge.

Trismus: Our protocol defines trismus as a mouth opening (interincisal distance) of <25 mm postoperatively.

Swelling: Very difficult to assess especially in a clinical field; in our study we considered soft tissue swelling as an obvious facial asymmetry.

Bleeding: No patient presented with any haemorrhage, any patient who presented with continuous blood loss from the socket is recorded as have postoperative bleeding.

Sore throat: Was recorded as a complication in patients who presented with pharyngeal pain and dysphagia and reddening of the area on clinical examination.

Alveolar osteitis [dry socket]: Was recorded as a complication in patients who presented with dull aching pain in an inflamed tooth socket.

Delayed healing: A patient was recorded as having delayed clinical healing when further surgical treatment was required on a postoperative visit (e.g., re-suturing).

Temporary and permanent nerve dysfunction: Nerve paraesthesia data were either related to the inferior alveolar nerve or the lingual nerve. All patients with paraesthesia were followed up for the first four weeks following surgery, six months and up to two years, with any patient beyond this time being considered to have permanent nerve dysfunction.

Pain: The most common postoperative complication following third molar surgery; this complication was not investigated in our study.

All surgical procedures were performed in similar clinics, equipped with similar surgical instruments, rotary and irrigation devices and materials (sutures and haemostatic agents). Prior to surgery, each patient was informed of possible complications including the possible risk of nerve damage during the procedure and provided fully informed consent.

Local anaesthesia was applied (2% Lidocaine with 1:100,000 epinephrine) by local tissue infiltration and inferior alveolar nerve block injection and no more than five cartridges were given to any single patient.

Surgical approach was implemented in all cases. An envelope mucoperiosteal flap was reflected and bone was removed with a round bur in a straight handpiece. Sectioning of the teeth was carried out using a fissure bur. Bone removal and sectioning of the tooth was performed under continuous irrigation with sterile saline solution at room temperature. The wound was carefully irrigated and any bony spicules removed. The flap was then repositioned and sutured with 4-0 Vicryl. No lingual flap was employed in any of the cases.

Immediately postoperatively all patients were given written instructions about wound care and possible complications in the post-operative period. For all patients, metronidazole (400 mg three times daily for five days) was prescribed as an antimicrobial agent. Ibuprofen (400 mg three times daily for five days) was prescribed as an analgesic. All patients in this study were reviewed seven days postoperatively.

The cases were distributed among seniors and juniors randomly regardless of patient's age, gender or even complexity of surgery. Patients were required to undergo removal of at least one mandibular third molar tooth for inclusion in this study.

No surgical exploration was implemented for any of the patients presented with paraesthesia for less than two years. Patients who continued to have this symptom over two years (permanent) were reviewed to assess their condition and were advised to undergo surgery to explore the area that could include undertaking microneurosurgical repair for the appropriate cases.

RESULTS

The average time of operation was 18 minutes per extraction. The mean age of the patients was 31.9 (range 30-36). All the patients were followed 1 week postoperatively; patients who experienced complications lasting more than 1 week were reviewed regularly up to 2 years.

The 210 patients participated in this study were classified into three groups depending on the third molar impaction; fully erupted third molars group (30 patients), partially impacted third molars group (156 patients) and fully impacted third molars group (24 patients).

The proximity of the inferior alveolar nerve canal to the root(s) assessed on orthopantomogram. One hundred forty eight patients (70.5%) have been identified as having third molars in close proximity to the canal.

More than one third of the female patients (36.8%) were under oral contraception at the time of surgery. One hundred and twenty nine patients were non-smokers. The significance of the previous facts was not assessed in this study.

The post-surgical complications were as follows (Fig. 1):

Infection and abscess: Signs and symptoms of infection were observed clinically in 12 patients including the six cases diagnosed with abscess formation. Diagnosed patients with dental abscesses related to the area of extraction were treated with surgical drainage and intake of amoxicillin 500 mg three times daily for four days, per os.

Trismus: Twenty-five patients suffered limited mouth opening. The experience of the surgeon was not found to be a significant factor ($p > 0.05$).

Swelling: Twenty-three patients suffered a second swelling episode after the initial swelling phase subsided. This symptom was slightly more common in the group of patients treated by the junior doctors, however not statistically significant ($p > 0.05$).

Bleeding: Bleeding but not hemorrhage was identified in 9 patients. This was more common in the hands of senior surgeons, but not statistically significant ($p > 0.05$).

Sore throat: This complication was not identified in any of the patients in this study.

Dry socket: Alveolar osteitis was diagnosed in 25 patients and treated topically with iodoform gauze after irrigating the extraction socket with saline solution to remove debris.

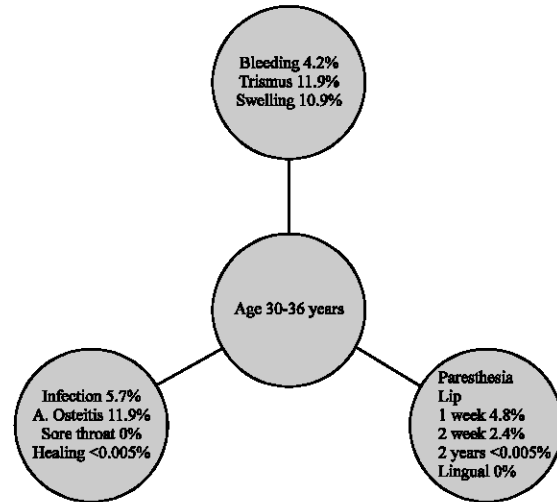


Fig. 1: Descriptive statistics of complications presented in our two center study

Healing: Only one patient presented with poor healing.

Lip sensation: During the first postoperative review, 10 patients suffered paraesthesia in the distribution of the inferior alveolar nerve. The Pearson Chi-Squared revealed a significant correlation ($p < 0.05$) with age (> 30). During the second postoperative review (1 week later) half of those patients were asymptomatic. The others had persistent signs of paraesthesia for 6 months and only one patient continued to have this complication for more than two years postoperatively.

Tongue numbness: No lingual numbness observed. This is possible explained due to avoidance of performing lingual surgical techniques (lingual flap, lingual bone split etc).

DISCUSSION

The removed teeth showed all kind of impactions, so that the procedures varied from simple extraction to difficult surgery. This study represents the whole spectrum of third molar surgery of a dental surgery clinic and the determined incidence of sensory impairment might be considered as reflecting the average risk of sustaining such incidence following third molar surgery.

Complications can arise following third molars surgery that could range from mild pain, tenderness, dry socket and nerve paraesthesia or even life-threatening haemorrhage (Chiapasco *et al.*, 1993) these complications are well documented. Although attention to the main basic principles of surgery, including proper preparation

of the patient, proper management of hard and soft tissue, asepsis and haemostasis might definitely lead to reducing the number and severity of complications, certain unavoidable complications may still occur.

There is lack of evidence in the literature regarding the correlation of age to the appearance of the commonest post-extraction complications, such as dry socket, trismus, delayed healing, infection, pain, inferior alveolar nerve injury, lingual nerve injury and swelling.

There is also a confusion regarding the necessity for prophylactic removal of third molars in patients less than 30 years of age. In general increased age may be one of the factors associated with the presentation of postoperative complications (Christiaens and Reyckler, 2002; Bui *et al.*, 2003), but this finding is not proved in the field of evidence-based dentistry.

Surgical extraction of lower third molars under local anesthesia was reported to have a complication rate of 7.1-12.6% (Tay, 2000; Christiaens and Reyckler, 2002).

Yoshii *et al.* (2001) reported that deep fascial space infection is uncommon after surgical removal of mandibular third molars with an incidence of 0.8% in the total population. Present findings showed that 5.7% of the total group presented with signs of infection; the age factor might be a contributing factor. Therefore the removal of third molars, if indicated, would be better performed at younger (Yoshi *et al.*, 2001).

The condition of trismus was relatively common (11.9%) in our patients; the possible role of exogenous factors such as type of incision, intake of oral contraceptives and smoking were not evaluated. Jerjes *et al.* (2006) suggested that the condition of trismus as a postoperative complication might be the consequence of the masseter muscle trauma due to prolonged surgery as a direct effect. Other possible explanation of trismus might be the excessive periosteal injury, having as a consequence a status of diffused swelling causing limited mouth opening as an indirect effect.

The complication of bleeding may be seen more in bleeding disorders (Filho *et al.*, 2006). Surgical removal of third molars in otherwise healthy individuals may be associated with oozing, which may be controlled with routine haemostatic techniques. Therefore, the most important preventing factor is the pre-surgical assessment.

Surgery associated sore throat, as a common complication of general anaesthesia (Biro *et al.*, 2005) was not observed in our study group. The use of local anaesthesia was not associated with cases of sore throat.

In general alveolar osteitis or dry socket as a condition of problematic healing was seen in about 8.2% of cases where healing complications observed in 11% of

the total group (Adeyemo *et al.*, 2006). In present study group, 11.9% presented post-surgically with alveolar osteitis, slightly different without significant value if compared with the previous study.

The surgical extractions of lower wisdom teeth endanger both the lingual and inferior alveolar nerve (Loescher *et al.*, 2003). Black (1997) reported that inferior alveolar nerve impairment is increased significantly in patients aged more than 30 with a range of 3.1-3.9% compared to the range of 0.2-1.3% at the patients aged less than 30 years old. Our findings are slightly higher; the incidence of inferior alveolar nerve paraesthesia was 4.8%. The role of increased age might be correlated to IAN injury possibly due to biochemical changes of mandibular microstructure and more precisely due to gradual bone toughening, which is clearly established in relation to increased age caused by collagen changes (Burr, 2002).

Although standard radiographs give only a two-dimensional view, it is possible to predict any risk through assessing the location and morphological characteristics of the canal in relation to the mandibular third molar (Kipp *et al.*, 1980; Wofford and Miller, 1987; Rood and Shehab, 1990). These radiographs are not classically defining the pathway of the lingual nerve but this was not our interest due to avoidance of lingual surgical approach. Therefore, the surgical approach followed in present study was negatively associated with lingual nerve irritation.

The findings of this study did not support the prophylactic removal of mandibular third molars in young ages. Although, the results showed tendency for increasing the rate of complications as an overall term, there is no sound evidence to support this theory. More, precisely the surgical removal in patients more than 40 years might be in higher risk if we considered that this age group more likely associated with medical compromised conditions if compared with younger groups (Kaminishi and Kaminishi, 2004).

CONCLUSION

Concluding, in the light of the existing evidence the mandibular third molars should not be removed in the field of prophylactic routine practice in the age group of 30-36 years if the patients were asymptomatic (Haug *et al.*, 2005).

REFERENCES

- Adeyemo, W.L., A.L. Ladeinde and M.O. Oqunlewe, 2006. Clinical evaluation of post-extraction site wound healing. *J. Contemp. Dent. Pract.*, 7: 40-49.

- Benediktsdottir, I.S., A. Wenzel, J.K. Petersen and H. Hintze, 2004. Mandibular third molar removal: Risk indicators for extended operation time, postoperative pain and complications. *Oral. Surg. Oral. Med. Oral. Pathol. Oral. Radiol. Endod.*, 97: 438-446.
- Biro, P., B. Seifert and T. Pasch, 2005. Complaints of sore throat after tracheal intubation: A prospective evaluation. *Eur. J. Anaesthesiol.*, 22: 307-311.
- Black, C.G., 1997. Sensory impairment following lower third molar surgery: A prospective study in New Zealand. *N.Z. Dent. J.*, 93: 68-71.
- Bui, C.H., E.B. Seldin and T.B. Dodson, 2003. Types, frequencies and risk factors for complications after third molar extraction. *J. Oral. Maxillofac. Surg.*, 61: 1379-1389.
- Burr, D.B., 2002. The contribution of the organic matrix to bone's material properties. *Bone*, 31: 8-11.
- Chiapasco, M., L. De Cicco and G. Marrone, 1993. Side effects and complications associated with third molar surgery. *Oral. Surg. Oral. Med. Oral. Pathol.*, 76: 412-420.
- Christiaens, I. and H. Reyckler, 2002. Complications after third molar extractions: Retrospective analysis of 1,213 teeth. *Rev. Stomatol. Chir. Maxillofac.*, 103: 269-274.
- Filho Ade, M., R.S. dos Santos, J.R. Costa, A.A. Puppim, R.A. De Rezende and G.C. Beltrao, 2006. Oral surgery with fibrin sealants in patients with bleeding disorders: A case report. *J. Contemp. Dent. Pract.*, 7: 106-112.
- Haug, R.H., D.H. Perrott, M.L. Gonzalez and R.M. Talwar, 2005. The American Association of Oral and Maxillofacial Surgeons Age-Related Third Molar Study. *J. Oral. Maxillofac. Surg.*, 63: 1106-1114.
- Jerjes, W., M. El-Maaytah, B. Swinson, B. Banu, T. Upile, S. D'Sa *et al.*, 2006. Experience versus complication rate in third molar surgery. *Head Face Med.*, 25: 14.
- Kaminishi, R.M. and K.S. Kaminishi, 2004. New considerations in the treatment of compromised third molars. *J. Calif. Dent. Assoc.*, 32: 823-825.
- Kipp, D.P., B.H. Goldstein and W.W. Weiss Jr., 1980. Dysesthesia after mandibular third molar surgery: A retrospective study and analysis of 1,377 surgical procedures. *J. Am. Dent. Assoc.*, 100: 185-192.
- Loescher, A.R., K.G. Smith and P.P. Robinson, 2003. Nerve damage and third molar removal. *Dent. Update*, 30: 375-80, 382.
- Rood, J.P. and B.A. Shehab, 1990. The radiological prediction of inferior alveolar nerve injury during third molar surgery. *Br. J. Oral. Maxillofac. Surg.*, 28: 20-25.
- Singh, H., K. Lee and A.F. Ayoub, 1996. Management of asymptomatic impacted wisdom teeth: A multicentre comparison. *Br. J. Oral. Maxillofac. Surg.*, 34: 389-393.
- Stanley, H.R., M. Alattar, W.K. Collett, H.R. Stringfellow Jr and E.H. Spiegel, 1988. Pathological sequelae of neglected impacted third molars. *J. Oral. Pathol.*, 17: 113-117.
- Tay, S., 2000. Third molar surgery under local anaesthesia--a clinical audit. *Singapore. Dent. J.*, 23: 11-13.
- Wofford, D.T. and R.I. Miller, 1987. Prospective study of dysesthesia following odontectomy of impacted mandibular third molars. *J. Oral. Maxillofac. Surg.*, 45: 15-19.
- Yoshii, T., Y. Hamamoto, S. Muraoka, A. Kohjitani, O. Teranobu, S. Furudo *et al.*, 2001. Incidence of deep fascial space infection after surgical removal of the mandibular third molars. *J. Infect. Chemother.*, 7: 55-57.