

## Description of a Single-ESIN Osteosynthesis for Metacarpal Fractures In Children and Adolescents

<sup>1</sup>Martin M. Kaiser, <sup>2</sup>B. Lange, <sup>3</sup>Arndt P. Schulz, <sup>3</sup>Andreas Paech and <sup>1</sup>Lucas M. Wessel

<sup>1</sup>Department of Pediatric Surgery,

<sup>2</sup>Department of Plastic and Hand Surgery,

<sup>3</sup>Department of Trauma and Orthopaedic, University Hospital Lübeck,  
Ratzeburger Allee 160, D-23538 Lübeck, Germany

**Abstract:** The aim of this study is to describe the technique and first results of treatment of metacarpal fractures of children and adolescents with a new method. Fractures of the second to fifth metacarpal bone were treated with only one Elastic Stable Intramedullary Nail (ESIN) and followed prospectively. These patients were reviewed at a mean follow-up time of 9 months. Patient's satisfaction was very high, especially because of almost no postoperative pain and lack of immobilization. This method offers an effective and safe alternative in the treatment of closed displaced fractures of the 2nd to 5th metacarpus without significant complications.

**Key words:** Metacarpal fracture, elastic stable intramedullary nailing, children, adolescents

### INTRODUCTION

Different treatment options exist for closed fractures of the Metacarpals but none of them has proven to be superior (Poolman *et al.*, 2005). The often used conservative approaches include cast, tape and splinting techniques (Harding *et al.*, 2001; Kuntscher *et al.*, 2002; Bain and Guy, 2003; Tavassoli *et al.*, 2005; Cornwall, 2006). Immediate mobilisation is reported to be possible as well (Stadius Muller *et al.*, 2003).

Percutaneous K-wire fixation had been the operative procedure of choice in our department which required cast immobilization; treatment with reduction through an Iselin-Cast was often tolerated not very well in these patients. As a new alternative we developed a treatment scheme with a single ESIN under general anaesthesia for fractures of the metacarpals with a volar angulation > 30°, a sagittal angulation > 10°, a longitudinal shortening > 2 mm and any rotational misalignment according to the indications found in literature (Prokop *et al.*, 1999; Kuntscher *et al.*, 2002).

### MATERIALS AND METHODS

From 01/2002 to 09/2006, all patients with closed fractures of metacarpalia 2-5 admitted to our department

with an volar angulation more than 30°, sagittal angulation of more than 10°, longitudinal shortening of more than 2 mm or any rotation of the fractured bone with scissoring (Fig. 1) were offered three different treatment options: Reduction and retention through an Iselin-cast, reduction and retention through a percutaneous K-wire and cast or single-ESIN without immobilization.

The age of the 24 patients treated with single ESIN ranged from 7-15 years (mean 12.8 years), there were 21 boys and 3 girls. Twenty fractures were located at the distal part of the Metacarpus, 2 were located proximal and 2 in the diaphysis. The right hand was injured 17 times, the left 7 times. There were no neurovascular problems. All patients were treated as outpatients.

All patients were operated by an experienced paediatric surgeon within 4 days after injury as an outpatient procedure except for 4 patients with late admission after having developed rotational angulation. All operations were performed under general anaesthesia. No antibiotics were given perioperatively, no Tourniquet was applied. The application of the ESIN is done according to a standard protocol. The fracture is at first reduced using the closed method described by Jahss. Depending on the location of the fracture a small 5 mm longitudinal incision is made above the dorso-ulnar part of the Metacarpal head or base (Fig. 2). A 2 mm ESIN

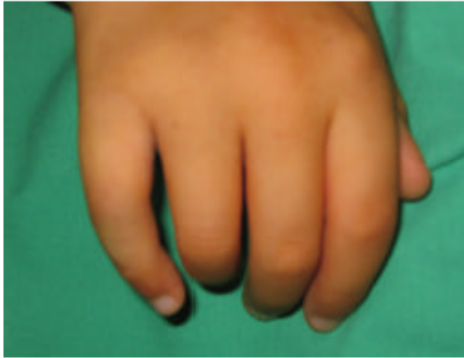

Fig. 1: Typical rotational deformity

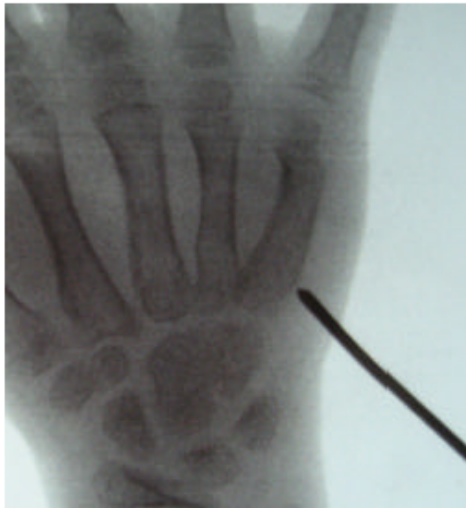

Fig. 2: A small window at the cortex is opened

usually fits very well for metacarpal bones and provides enough stability to maintain reduction. Only in younger patients a 1.5 mm ESIN can be useful.

A window of the cortex is opened by an awl and under fluoroscopic guidance the ESIN is pushed beyond the fracture line with the bending tip towards the palm. In cases of Salter-Harris I or II fractures the physis has to be crossed. After almost complete insertion the ESIN is turned 180° achieving excellent reduction by pushing the Metacarpal head upwards (joystick-manoeuve as used for proximal fractures of the radius, Fig. 3a and b). After this manoeuvre the ESIN is moved forward for another 1 or 2 mm in to the subchondral bone gaining full stabilization. The other end of the ESIN is buried under the skin. To reduce any risk of compromising the soft-tissue the end should not exceed 5 mm. At the end of the procedure complete reduction and functional stability is checked in all planes under fluoroscopy and rotational angulations are ruled out by flexion of all fingers.

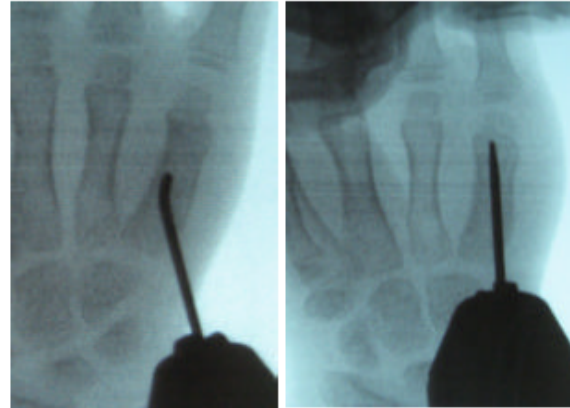


Fig. 3a and b: After almost complete insertion the ESIN is turned 180° achieving excellent reduction by pushing the metacarpal head upwards

Postoperatively neither immobilization nor any kind of physiotherapy was part of the treatment protocol. If x-ray after 4 weeks showed complete union of the fracture without pain upon palpation and forced movements complete exertion was allowed. All ESIN were removed after 3 months under general anaesthesia as an outpatient procedure. Local anaesthesia for removal was offered but not wished by our patients and their parents.

The follow-up of patients was done 5-20 months after removing the ESIN. It included clinical examination and evaluation of the last radiographs.

## RESULTS

All fractures were treated with one ESIN size 2 mm besides 2 fractures with ESIN size 1, 5 mm. Operation time for acute fractures was 14-29 min, all with closed reduction. Four fractures with misalignment after conservative treatment required open reduction and operation time here was 26-41 min.

We saw no infection or second operative procedure (Fig. 4). There was no ESIN migration but one skin irritation, which required removal after 5 weeks without loss of reduction. One hypaesthesia was temporary.

X-Ray examination before removing the ESIN and Ultrasound examination in three angles showed no deformation of axis or rotational deviation. At follow-up all patients reached a complete free range of motion, respectively all reached more than 220° total active flexion from MCPJ to DIPJ digits 2-5, which means an excellent result according to the American Society for Surgery of the Hand.

All fractures	
n =	24
X-ray: deviation of axis	none
Infection	none
Early removal of material	1
Hypaesthesia temporary	1

Fig. 4: Results at follow-up

## DISCUSSION

This study shows a broad spectrum of treatment for metacarpal fractures, each of them having its own potential complications. However, motion should follow fracture-treatment as early as possible to restore complete function (Lewis *et al.*, 1987; Kuntscher *et al.*, 2002). Conservative treatment requires a long immobilization and risks skin lesions. Casts and orthopaedic fabrications require re-evaluations of rotational malalignment and skin care checks (Eglseder *et al.*, 1997). A comparison of functional treatment with immobilization for fractures of the 5th metacarpus does not offer a consistent picture as well (Poolman *et al.*, 2005). Plate fixation allows a higher grade of stability, at least 5 K-wires are needed to achieve a similar stability as plate fixation (Firoozbakhsh *et al.*, 1996). On the other hand, plate fixation is time consuming and requires a greater amount of tissue dissection (Page and Stern, 1998). Kirschner-wires in MC5-position (Wong *et al.*, 2006) (percutaneous transverse or intramedullary) gained excellent functional and radiological results possibly because of avoiding open reduction and extensive soft tissue dissection. Burying K-wires beneath the skin reduces the risk of infection but these intramedullary K-wires are likely to migrate or perforate the head of the metacarpal (Rafique *et al.*, 2006; Wong *et al.*, 2006).

Our results show, that single-ESIN is a safe procedure for Metacarpal fractures in our collective. It combines the minimal-invasive approach of intramedullary devices (no need for soft tissue dissection besides a little skin incision at the dorsolateral aspect of the metacarpus) with the opportunity of immediate movement of all joints compared to a plate fixation. In contrary to multiple intramedullary smaller ESIN or K-wires one ESIN is easier and faster to apply. We had only 2 minor problems which did not have any effect on the result. We had no pull-out or infections. All patients regained full range of motion and participated again in former activities.

X-ray and ultrasound verified optimal fracture healing. Due to the stability of the fixation we performed only one X-ray control after 4 weeks to check on consolidation and a second one before removing the

ESIN; with experience in Ultrasound the amount of X-ray was decreasing. The study shows, that X-ray follow-up examinations produce a large amount of non-relevant information and much radiation. After analyzing 408 lateral x-rays in 160 patients. Braakman (1998) demands only oblique views. Ultrasound reduced radiation and provided views in different angles.

As pediatric trauma surgeons we have the advantage that we treat young children with healthy tissue and extraordinary healing potentials, which definitely contribute to our excellent results. Further on, we had no comminuted fractures or any additional injuries to the hand, which may have influenced the outcome. But one ESIN was also a very useful tool for stabilization after secondary treatment following misalignment.

## REFERENCES

- Bain, G.I. and S.D. Guy, 2003. Derotation taping for metacarpal and phalangeal fractures. *Tech. Hand Up Extrem. Surg.*, 7: 130-132.
- Braakman, M., 1998. Are lateral X-rays useful in the treatment of fractures of the 4th and 5th metacarpals. *Injury*, 29: 1-3.
- Cornwall, R., 2006. Finger metacarpal fractures and dislocations in children. *Hand Clin.*, 22: 1-10.
- Eglseder, W.A. and P.J. Juliano *et al.*, 1997. Fractures of the 4th metacarpal. *J. Orthop. Trauma.*, 11: 441-445.
- Firoozbakhsh, K.K. and M.S. Moneim *et al.*, 1996. Internal fixation of oblique metacarpal fractures. A biomechanical evaluation by impact loading. *Clin. Orthop. Relat. Res.*, pp: 296-301.
- Harding, I.J. and D. Parry *et al.*, 2001. The use of a moulded metacarpal brace versus neighbour strapping for fractures of the little finger metacarpal neck. *J. Hand Surg.*, 26: 261-263.
- Kuntscher, M. and J. Blazek *et al.*, 2002. (Functional bracing after operative treatment of metacarpal fractures). *Unfallchirurg*, 105: 1109-14.
- Lewis, R.C. and M. Nordyke *et al.*, 1987. Expandable intramedullary device for treatment of fractures in the hand. *Clin. Orthop. Relat. Res.*, 214: 85-92.
- Page, S.M. and P.J. Stern, 1998. Complications and range of motion following plate fixation of metacarpal and phalangeal fractures. *J. Hand Surg.*, 23: 827-832.
- Poolman, R.W. and J.C. Goslings *et al.*, 2005. Conservative treatment for closed 5th (small finger) metacarpal neck fractures. *Cochrane Database Sys. Rev.*, (3): CD003210.
- Prokop, A. and S. Kulus *et al.*, 1999. (Are there guidelines for treatment of metacarpal fractures? Personal results and literature analysis of the last 12 years). *Unfallchirurg*, 102: 50-58.

- Rafique, A. and S. Ghani *et al.*, 2006. Kirschner wire pin tract infection rates between percutaneous and buried wires in treating metacarpal and phalangeal fractures. *J. Coll. Physicians Surg. Pak.*, 16: 518-520.
- Stadius Muller, M.G. and R.W. Poolman *et al.*, 2003. Immediate mobilization gives good results in boxer's fractures with volar angulation up to 70 degrees: A prospective randomized trial comparing immediate mobilization with cast immobilization. *Arch. Orthop. Trauma. Surg.*, 123: 534-537.
- Tavassoli, J. and R.T. Ruland *et al.*, 2005. Three cast techniques for the treatment of extra-articular metacarpal fractures. Comparison of short-term outcomes and final fracture alignments. *J. Bone Joint Surg. Am.*, 87: 2196-2201.
- Wong, T.C. and F.K. Ip *et al.*, 2006. Comparison between percutaneous transverse fixation and intramedullary K-wires in treating closed fractures of the metacarpal neck of the little finger. *J. Hand Surg.*, 31: 61-65.