

The Protective Effect of Yinzhihuang on Acute Liver Injury Induced by Carbon Tetrachloride in Rabbits

Ma Liqin, Xue Ruicheng, Chu Yaocheng and Li Kai
Department of Veterinary Medicine, College of Animal Science, Hebei North University,
075000 Hebei Province, P.R. China

Abstract: The hepatobiliary disease is frequently seen in companion animal practice. The present study was performed to investigate the protective effect of Yinzhihuang on liver injury in rabbits induced by CCl₄. The results showed that compared with the liver injury model group, the dead rate obviously decreased, the serum ALT, AST and ALP activities were significantly decreased ($p < 0.01$), the serum Total Bilirubin (TBIL) and Direct Bilirubin (DBIL) levels were significantly lower ($p < 0.05$) and the degree of liver injury reduced significantly in Yinzhihuang protection groups. The data suggest that Yinzhihuang has obviously protective effect against liver injury induced by CCl₄.

Key words: Yinzhihuang, liver injury, carbon tetrachloride, protective effect, rabbits

INTRODUCTION

Patients with hepatobiliary disease are frequently seen in companion animal practice. The liver is an extremely important organ in the body. It is responsible for protein, fat and carbohydrate metabolism; Vitamin and mineral storage; digestion of food and detoxification of wastes. Liver disease can be found at any age stage but most prone to senior animal (Kil *et al.*, 2010; Schmucker, 2005). It can develop as a result of many different causes and can manifest itself as a number of different specific liver diseases. In recent decades with an increasing number of pet-keeping, especially in large cities, the number of pets has stepped into the aging stage. Therefore, the age-related diseases, especially the liver disease have become one of the major problems.

Clinically, the liver disease animal always suffers from lethargy, emaciation, jaundice, vomiting, anorexia and seizures. Other signs of illness associated with liver disease can include ascites, pale gums and associated bleeding tendencies. If do not take timely treatment, patients would result in the death. Because the liver can continue to function while up to 70-80% of it is damaged, the liver disease is often not detected until it is very advanced. That makes treatment difficult or impossible. The occurrence of the primary liver disease is due to metabolic disorders, cancer, infections and poisoning and so on. The hepatic lipidosis is a common condition in pets, especially old animal in which the liver accumulates a large amount of fat and the liver cannot function normally. It is a very serious disease and unless treated aggressively can be fatal (Laflamme, 2005; Cornelius *et al.*, 2000; Twedt, 1994).

Yinzhihuang injection, an injectable herbal medicine commonly used for the treatment of liver diseases in China was recorded in the Vol. 14 of patent the Traditional Chinese Medicine (TCM) issued by State Administration of Health. The ingredients of Yinzhihuang injection are capillaris, gardenia, baicalin and honeysuckle. It can clear away heat and toxic material, remove dampness and eliminate jaundice. Research has shown that gardenia and capillaries have a protective effect to the chemical carbon tetrachloride-induced liver injury. In this study, the carbon tetrachloride-induced liver injury in rabbits was adopted (Bernacchi *et al.*, 1983). Then the protective effects of the traditional Chinese medicine Yinzhihuang to this animal model were observed which may provide reference to prevent and cure the live disease.

MATERIALS AND METHODS

Experimental animal: A total of 60 New Zealand white rabbits (16 weeks, 2.6-3.1 kg) were used for the experiments after an acclimation period of about a week. Rabbits were housed in single cages at the Laboratory Animal Research Center of Hebei North University and maintained on a 12/12 h light/dark cycle, standard laboratory diet and water, $23 \pm 2^\circ\text{C}$ temperature, $55 \pm 10\%$ humidity, 12 times h^{-1} ventilation. The experimental protocol was approved by the Institutional Animal Care and Use Committee (IACUC), the Laboratory Animal Research Center of Hebei North University.

Drugs and reagents: Yinzhihuang injection were purchased from ShenWei Pharmaceutical Limited

Company; 10% glucose injection were purchased from Shandong Pharmaceutical Limited Company; carbon tetrachloride and liquid paraffin were purchased from Tianjin Kermel Chemical Reagent Co., Ltd. (before use, the 50% of the sterilization solution was confected with carbon tetrachloride and liquid paraffin according to 1:1 ratio).

Clinical use of Yinzhihuang injection: About 4 mL of Yinzhihuang injection diluted with 10% glucose injection 50~100 mL was intravenously infused through the marginal ear vein of each rabbit.

Grouping and treatment of animals: The experimental rabbits were randomly divided into 3 groups: Control group, liver injury model group and Yinzhihuang protection groups, 20 in each group. The feed was supplied under the same conditions. The rabbits of liver injury model and Yinzhihuang protection groups were injected with 50% of the carbon tetrachloride and paraffin solution subcutaneously (0.4 mL kg^{-1}). At the same time, the rabbits of Yinzhihuang protection group were infused with Yinzhihuang injection via the marginal ear vein. The rabbits of control group were infused with 0.9% saline at the same dose. All these things were done once a day for continuous 15 days. Clinical signs and symptoms were observed and recorded every day. Autopsies were performed and pathological changes in the liver were recorded to dead rabbits in time. The blood was collected from the marginal ear vein of representatives in 3 groups at 16 days after an overnight fast and the serum was separated by centrifugation at 1800 g for 15 min. An automatic blood chemistry analyzer was used for determining the serum concentrations of Aspartate aminotransferase (AST), Alanine Aminotransferase (ALT), Gamma Glutamyl Transpeptidase (GGT) and Alkaline Phosphatase (ALP). The concentration of serum Total Bilirubin (TBIL) and Direct Bilirubin (DBil) were measured using the diazo reagent. The survival rabbits were slaughtered by cervical dislocation at 16 days. The liver samples were fixed with 4% paraformaldehyde buffer, paraffin-embedded and sectioned ($5 \mu\text{m}$).

Statistical analysis: All the data were analysed by SPSS11.5 software by ANOVA analysis and all means were showed with Standard Deviation (SD).

RESULTS

Clinical observation of Yinzhihuang injection in treating liver injury in rabbits induced by carbon tetrachloride:

The rabbits in control group maintain health, good spirits and normal behavior. The rabbit's coat is shiny, soft and healthy. The colour of conjunctiva in the rabbit's eyes is

normal. The body weight increased and no death was found during experimental period. The rabbits of liver injury model group show depressed, lethargy, reduced appetite and drinking, brown urine, the response decreased to the outside stimulation, uncombed hair, crowded together, generalized weakness and weight loss. The conjunctiva was apparently stained yellow. Total of 9 died in the experiment period. The dead rate is 45%. The rabbits of Yinzhihuang protection groups showed good spirit, a slight decline in appetite, normal drinking, the sensitive response to the outside stimulation, shiny hair and light yellow urine. The conjunctiva of the eyelids is not readily visible and has a pale, salmon pink color. Only 2 lethal rabbits were found on 8 days. The dead rate is 10%.

The pathological anatomy changes of Yinzhihuang injection in treating liver injury in rabbits induced by carbon tetrachloride:

The anatomy shows rabbit liver of control group was reddish-brown, surface smooth and shiny, relatively soft and flexible texture. The liver of liver injury model group is enlarged obviously with obtunded edges, tense capsule and light yellow. The cut surface was yellow also. The rabbit liver of Yinzhihuang protection groups is slightly enlarged, surface smooth and has a dark red appearance, sometimes, slightly yellow. The liver edge is lightly obtunded edges.

The liver histological changes of Yinzhihuang injection in treating liver injury in rabbits induced by carbon tetrachloride:

The live tissue samples were obtained from experimental rabbit on 16 days and fixed in 4% paraformaldehyde buffer. Samples were then embedded in paraffin, cut into $5 \mu\text{m}$ -thick sections and stained with H&E.

The normal liver shows regular cellular architecture of a hepatic lobule. Hepatocytes are highly ordered in the hepatic lobule, around the sinusoids and the portal triad. The interstitial space is rather limited. The hepatic lobule were obvious the portal triad is visible in the center and hepatic plates were arranged in cord which is radial around central vein. There are no hepatocyte degeneration and necrosis (Fig. 1).

The damage of the hepatic lobule structure and necrotic hepatic tissues are obvious in liver injury (CCl_4 -induced hepatotoxicity) model group. The degeneration and fragmentation of hepatic cord cells and mild hyperplasia of fibrous tissue was observed. The lipid vacuoles of different sizes appeared in the cytoplasm of the hepatic cells. Severe fatty degeneration of the liver occurs (Fig. 2).

In Yinzhihuang protection groups, the structure of hepatic lobules is clear, light fatty degeneration of the liver can be found and there are no obvious pathological

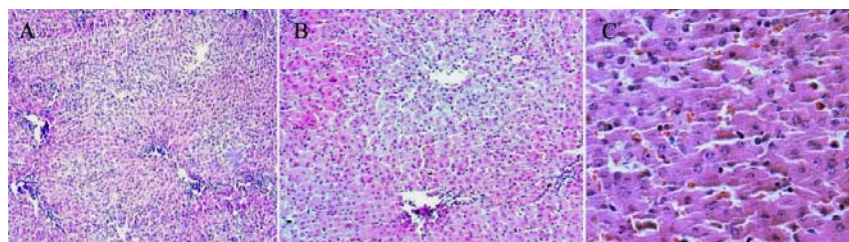


Fig. 1: The structure of liver tissue is complete, no necrosis and degeneration are shown in rabbits liver of the control group on 16 day; A: x100; B: x200; C: x400

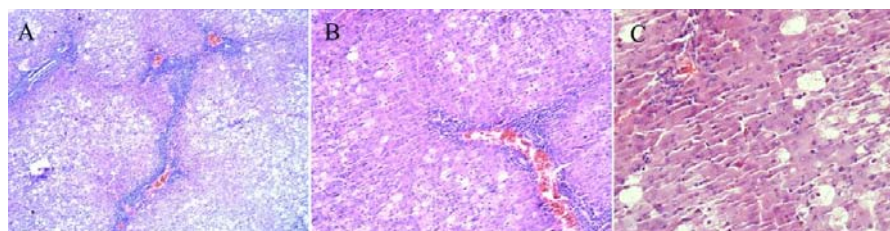


Fig. 2: The structure of liver leaflet is destroyed-obvious liver cells steatosis and mild fibrous tissue proliferation are shown-necrosis cell nucleus are enrichment and broken in rabbits liver of CCl₄ model group on 16 day; A: x100; B: x200; C: x400

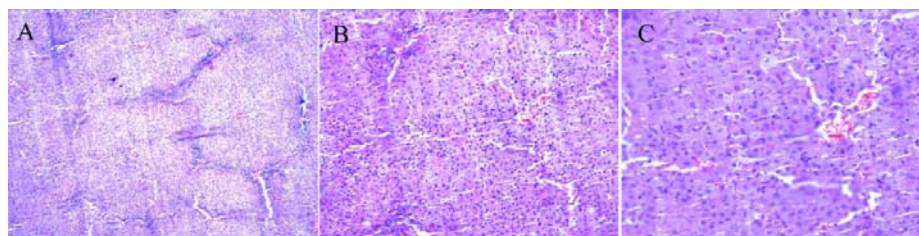


Fig. 3: Compared with CCl₄ model group; the liver tissue injury obviously alleviate. The degeneration and necrosis of liver tissue are less in rabbits liver of Yinzhihuang protection group on 16 day; A: x100; B: x200; C: x400

Table 1: Changes in the activities of serum ALT, AST, ALP and bilirubin in control group, liver injury model group and Yinzhihuang protection groups

Groups	ALT (IU L ⁻¹)	AST (IU L ⁻¹)	ALP (IU L ⁻¹)	TBIL (μmol L ⁻¹)	DBIL (μmol L ⁻¹)
Control	44.50±14.17	20.17±7.360	134.33±20.94	9.93±1.82	3.89±0.54
The liver injury model	97.83±19.60**	52.67±10.61**	287.50±47.12**	20.43±2.33**	9.05±1.14**
Yinzhihuang protection	52.67±9.710 ^{###}	24.67±11.99 ^{###}	185.33±18.40 ^{###}	13.87±1.24 ^{###}	5.68±0.99 ^{###}

Data are presented as mean±SD; ALT = Alanine aminotransferase; AST = Aspartate aminotransferase; ALP = Alkaline Phosphatase; TBIL = Total Bilirubin; DBIL = Direct Bilirubin; **p<0.01 compared with the control group; ^{###}p<0.01 compared with the liver injury model group

changes in the liver. Carbon tetrachloride induced liver necrosis was also found to be significantly reduced (Fig. 3).

Changes in the live function tests of Yinzhihuang injection in treating liver injury in rabbits induced by carbon tetrachloride: As can be seen from Table 1, the serum ALT, AST and ALP activities in liver injury model group are significantly increased compared with the control group (p<0.01). The serum ALT, AST and ALP activities in Yinzhihuang protection group are significantly decreased compared with the liver injury

model group (p<0.01). The serum Total Bilirubin (TBIL) and Direct Bilirubin (DBIL) levels in liver injury model group are significantly higher than the control group (p<0.05). The serum Total Bilirubin (TBIL) and Direct Bilirubin (DBIL) levels in Yinzhihuang protection groups are significantly lower than the liver injury model group (p<0.05).

DISCUSSION

Hepatic injury is a serious and life-threatening clinical syndrome which is characterized by hepatic function

damage due to the necrosis of a large amount of hepatocytes. Administration of carbon tetrachloride (CCl_4) is an established experimental model of severe toxic liver injury, lipid peroxidation and is frequently used for the screening of antihepatotoxic and/or hepatoprotective activities of drugs (Tunon *et al.*, 2009; Hemalatha, 2008). Yinzhihuang injection, as a traditional medicine is an effective drug to cope with liver disease, especially severe hepatitis, acute and chronic hepatitis (Jian, 2002) and jaundice (Lin *et al.*, 2010; Li *et al.*, 2009). It containing artemisia capillaris extract, gardenia extract, baicalin, honeysuckle extract, there is heat-clearing, detoxifying, removing dampness by diuresis and eliminating jaundice role. Stems and leaves of artemisia capillaris contains 6, 7-dimethoxy coumarin, chlorogenic acid and caffeic acid which can promote bile secretion and bile acid and bilirubin excretion. In addition, hydroxyacetophenone in it is also advantageous to choleresis. Gardenia has also been used in Japan and China as herbal drugs for their antiphlogistic, diuretic, antipyretic, haemostatic and cholagogic effects and can be used to treat contusions. Crocin and crocetin in the fruits of gardenia have been reported to have diverse pharmacological functions such as anti-hyperlipidemic, anti-atherosclerotic and anti-cancer effects (Nam *et al.*, 2010). Specifically, choleric action and can inhibit bilirubin elevated in the blood. Baicalin is a flavonoid compound purified from *Scutellaria baicalensis* Georgi (Huangqin). Huangqin has been used for centuries in traditional Chinese herbal medicine in the treatment of discomfort in the chest, nausea, acute dysentery, jaundice, carbuncles and threatened miscarriage (The Pharmacopoeia Commission of PRC, 1992). The various pharmacologic effects of baicalin include anti-bacterial, anti-virus, anti-tumor, antipyretic and analgesic, anti-oxidation and scavenging oxygen free radicals and treatment of the role of cardiovascular disease (Yang and Junpeng, 2004). Honeysuckle contains cyclohexanhexol, flavonoids, inositol, saponin, tannin, etc. It has been used in Chinese medicine for treating inflammation, fever and infection.

Carbon tetrachloride (CCl_4) is metabolized by cytochrome P450 2E1 to the trichloromethyl radical (CCl_3) which is assumed to initiate free radical-mediated lipid peroxidation leading to the accumulation of lipid-derived oxidation products that cause liver injury (Von Minden *et al.*, 2000). In this trial, the protective effect of the Yinzhihuang injection on hepatic function was studied. A total of 9 rabbits died in liver injury model group, however only 2 rabbits died in Yinzhihuang protection group during the experiment. The rabbits of liver injury model group showed depression, anorexia, the decreased response to the outside stimulation and apparently conjunctival jaundice. The livers were

enlarged obviously with obtunded edges, tense capsule, and light yellow. The rabbits of Yinzhihuang protection groups showed good spirit, a slight decline in appetite and the sensitive response to the outside stimulation. The conjunctival color of the eyelids is normal as well as those of control group. The livers are slightly enlarged, surface smooth and have a dark red appearance and the liver edge is lightly blunt. These illustrate that Yinzhihuang injection has a significant protective effect to the liver. The rise in serum levels of Aspartate Transaminase (AST), Alanine Transaminase (ALT) and Alkaline Phosphatase (ALP) has been attributed to the damaged structural integrity of the liver because they are cytoplasmic in location and released into circulation after cellular damages (Sallie *et al.*, 1991; Hemalatha, 2008). The rise in the levels of serum bilirubin is the most sensitive and confirms the intensity of jaundice. The CCl_4 is converted into reactive metabolite, halogenated free radical by hepatic cytochrome P450s which in turn covalently binds to cell membrane and organelles to elicit lipid peroxidation with subsequent tissue injury. High lipid peroxidation values indicate excessive free radical induced peroxidation (Packer *et al.*, 1978; Van de Straat *et al.*, 1987; Brattin *et al.*, 1985; Prabakan *et al.*, 2000). It is reported that Yinzhihuang injection prepared by different techniques can significantly reduced the biochemical parameters of the acute injured liver of mice made by carbon tetrachloride in soybean oil (Wang and Yue, 2010). In this study, as compared to those of the liver injury model group, the results demonstrated that serum AST, ALT and ALP activities in the Yinzhihuang protection group were significantly decreased ($p < 0.01$), respectively. In addition, the serum Total Bilirubin (TBIL) and Direct Bilirubin (DBIL) levels in Yinzhihuang protection groups are significantly lower than the liver injury model group ($p < 0.05$). It was considered that these changes were caused by the recovery of the hepatic tissues by Yinzhihuang injection.

On the histopathological features of the hepatic tissues in CCl_4 intoxication, Lee *et al.* (2004) and Sung *et al.* (1998) reported that the coagulative necrosis of the hepatic cells, the hemorrhage of the centrilobular and the midzonal region were observed after liver injury. The current study's results showed that massive changes characterized by the necrosis of lobules and contiguous lobules were found on the 16th day in the liver injury model group while mild hepatocytic degenerations of the liver were observed in the Yinzhihuang protection group. It was therefore assumed that the histopathological alleviated finding for the injured hepatic tissue backed up the therapeutic effect of Yinzhihuang injection.

CONCLUSION

From the results, researchers investigated the therapeutic effect of Yinzhihuang injection on acute liver injury induced by carbon tetrachloride in rabbits. It was demonstrated that Yinzhihuang injection was effective in the recovery of damaged liver tissues. But because of the medicine injection preparations, differences in production technology and the manufacturers, the adverse reactions should draw attention and need further study.

ACKNOWLEDGEMENT

This research was supported by the Science and Technology Bureau of Zhangjiakou (Grant No. 1012004C-4) and sponsored by Hebei North University.

REFERENCES

- Bernacchi, A.S., C.R. de Castro, E.C. de Ferreyra, M.C. Villarruel, G. Fernandez, O.M. de Fenos and J.A. Castro, 1983. Carbon tetrachloride-induced liver injury in the rabbit. *Br. J. Exp. Pathol.*, 64: 261-267.
- Brattin, W.J., E.A. Glende Jr. and R.O. Recknagel, 1985. Pathological mechanisms in carbon tetrachloride hepatotoxicity. *J. Free Radicals Biol. Med.*, 1: 27-38.
- Cornelius, L.M., J.W. Bartges and C.C. Miller, 2000. CVT Update: Therapy for Hepatic Lipidosis. In: *Current Veterinary Therapy XIII*, Bonagura, J.D. (Ed.). W.B. Saunders Co., Philadelphia, pp: 686-690.
- Hemalatha, R., 2008. Anti-hepatotoxic and anti-oxidant defense potential of *Tridax procumbens*. *Int. J. Green Pharm.*, 2: 164-169.
- Jian, Z., 2002. Observation of curative effect of Yinzhihuang injection on 57 cases with neonatal hyperbilirubinemia. *J. Pediat. Pharmacy*, 3: 59-60.
- Kil, D.Y., B.M. Vester Boler, C.J. Apanavicius, L.B. Schook and K.S. Swanson, 2010. Age and diet affect gene expression profiles in canine liver tissue. *PLoS One*, Vol. 5. 10.1371/journal.pone.0013319
- Laflamme, D.P., 2005. Nutrition for aging cats and dogs and the importance of body condition. *Vet. Clin. North Am. Small Anim. Pract.*, 3: 713-742.
- Lee, S.E., K.H. Song, J. Liu, H.J. Kwon and S.B. Youn, 2004. The effectiveness of auriculoacupoint treatment for artificially induced acute hepatic injury in dogs. *Am. J. Chin. Med.*, 32: 445-451.
- Li, C.M., J.M. Mou and J. Wang, 2009. Clinical observation on 64 cases with neonatal jaundice by yinzhihuang injection oral treatment. *Med. Recapitulate*, 13: 2051-2052.
- Lin, Y., X. Hongyan, T.J. Hui, Y. Kehu, Y. Guangyu and S. Wenbin, 2010. Treating neonatal jaundice with yinzhihuang injection: A systematic review. *Chinese J. Inform. Tradit. Chin. Med.*, 12: 17-20.
- Nam, K.N., Y.M. Park, H.J. Jung, J.Y. Lee and B.D. Min *et al.*, 2010. Anti-inflammatory effects of crocin and crocetin in rat brain microglial cells. *Europ. J. Pharmacol.*, 648: 110-116.
- Packer, J.E., T.F. Slater and R.L. Wilson, 1978. Reactions of the carbon tetrachloride related peroxy free radical (CC 130.2) with amino acids: Pulse radiolysis evidence. *Life Sci.*, 23: 2617-2620.
- Prabakan, M., R. Anandan and T. Devaki, 2000. Protective effect of *Hemidesmus indicus* against rifampicin and isoniazid-induced hepatotoxicity in rats. *Fitoterapia*, 71: 55-59.
- Sallie, R., J.M. Tredger and R. Williams, 1991. Drugs and the liver Part 1: Testing liver function. *Biopharm. Drug Dispos.*, 12: 251-259.
- Schmucker, D.L., 2005. Age-related changes in liver structure and function: Implications for disease? *Exp. Gerontol.*, 40: 650-659.
- Sung, J.K., H.C. Lee, J.H. Yoon, Y.W. Lee, Y.J. An and H.J. Choi, 1998. Ultrasonographic and radiographic evaluation for the quantitative diagnosis of diffuse hepatic disease in dogs. *Kor. J. Vet. Res.*, 38: 918-928.
- The Pharmacopoeia Commission of PRC, 1992. *Pharmacopoeia of the People's Republic of China*. 2nd Edn., Guangdong Science and Technology Press, Guangzhou, China, pp: 182-183.
- Tunon, M.J., M. Alvarez, J.M. Culebras and J. Gonzalez-Gallego, 2009. An overview of animal models for investigating the pathogenesis and therapeutic strategies in acute hepatic failure. *World J. Gastroenterol.*, 15: 3086-3098.
- Twedt, D.C., 1994. Feline liver disease. *Vet. Int.*, 3: 33-43.
- Van de Straat, R., J. de Vries, A.J.J. Debets and N.P.E. Vermeulen, 1987. The mechanism of prevention of paracetamol-induced hepatotoxicity by 3, 5-dialkyl substitution. The roles of glutathione depletion and oxidative stress. *Biochem. Pharmacol.*, 36: 2065-2070.
- Von Minden, H.M., K. Brandenburg, U. Seydel, M.H.J. Koch, V. Garamus, R. Willumeit and V. Vill, 2000. Thermotropic and lyotropic properties of long chain alkyl glycopyranosides. Part II. Disaccharide headgroups. *Chem. Phys. Lipids*, 106: 157-179.
- Wang, J.M. and G. Yue, 2010. Effects of yinzhihuang injection prepared by different techniques on the protective effect of acute liver injury in mice. *Chin. J. Med. Guide*, 5: 72-75.
- Yang, J. and F. Junpeng, 2004. Skullcap active ingredients and efficacy recent research. *Pract. Med. Pharmacy*, 3: 271-273.