

Corpus Callosum Classification Using Case Based Reasoning and Genetic Classifier for the Prediction of Epilepsy from 2D Medical Images

¹P. Tamijeselvy, ²V. Palanisamy and ¹S. Elakkiya

¹Department of CSE, Sri Krishna College of Technology, Coimbatore, India

²Info Institute of Engineering, Coimbatore, India

Abstract: Corpus callosum is a highly visible structure in brain imaging whose function is to connect the left and right hemisphere of the brain. Epilepsy is the sudden alterations in human behavior caused by an electrical discharge from the brain. Such electrical activity that starts from one side of the brain spread to the other side through the corpus callosum. Epilepsy occurs in 2% of the general population and it is the oldest known brain disorder. The traditional classification methods have less average prediction accuracy of 84.15% in diagnosing epilepsy. The proposed technique includes the improved classification approach for the diagnosis of epilepsy. The technique includes the following phases: pre-processing the 2D MR Brain Image using Threshold Interval Method and Min.-Max. Normalization Segmentation of brain image using multiscale segmentation method to obtain the segments of corpus callosum. Multiscale segmentation proves to be better in curvature segmentation with less execution time and 91% of accuracy based on entropy shape features such as corpus callosum bending angle, Genu thickness and Intelligent Quotient (IQ) are extracted from the segmented corpus callosum diagnosis of epilepsy using Case Based Reasoning (CBR) and genetic classification. The performance of the proposed optimized CBR classification reduces the false positive rate. The CBR classification model results in 96.7% of prediction accuracy and the optimized classification approach results in 97.3% of prediction accuracy.

Key words: Corpus callosum, epilepsy, multiscale segmentation, genetic classification, shape features, case based reasoning

INTRODUCTION

Medical imaging is the technique or process used to create images of the human body for clinical or medical science. Medical imaging is a routine and essential part of medicine. Medical imaging techniques can also be used when planning or even while performing surgery (Ganguly *et al.*, 2010). Epilepsy is a common and diverse set of chronic neurological disorders characterized by seizures. Epileptic seizures result from abnormal, excessive or hyper synchronous neuronal activity in the brain. Epilepsy is usually controlled but not cured with medication. The application domain that is focused in this study is the classification of Magnetic Resonance (MR) image data according to the nature of the corpus callosum using CBR and genetic classification. The corpus callosum is a highly visible structure in MR images whose function is to connect the left and right cerebral hemispheres and facilitates interhemispheric communication. It is the largest white matter structure in the brain, consisting of 200-250 million contralateral axonal projections. The specific application used to illustrate the described classification process is the categorization of MR images into one of two classes: epileptic and non-epileptic.

Classification and prediction are two forms of data analysis that can be used to extract models describing important data classes or to predict future data trends. Such analysis provides us with a better understanding of the data at large.

The proposed system applies pre-processing on input images using threshold interval method and Min.-Max. normalization, segmentation of corpus callosum using multiscale segmentation, shape feature extraction, CBR and genetic classification which also includes, Support Vector Machine (SVM), decision tree, bayes and neural network with the application to supervised classification of epilepsy. Figure 1 depicts the corpus callosum in the MRI medial view of the brain.

Image pre-processing techniques are applied to the input brain image. The aim of image enhancement is to improve the interpretability or perception of information in images to provide better input for next automated image processing techniques. Multiscale segmentation is used to segment the corpus callosum. To reduce the number of features to a more manageable number, a shape feature selection mechanism is applied. Finally, classification methods are applied for the diagnosis of epilepsy.

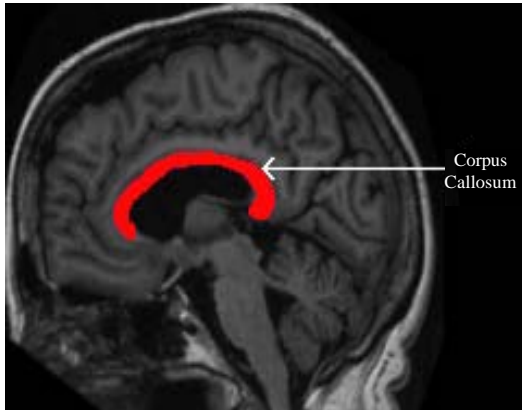


Fig. 1: View of corpus callosum

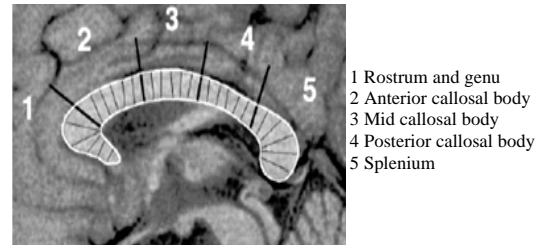


Fig. 2: Five-subregions of carpus callosum

Corpus callosum: The corpus callosum is a large bundle of white fibers that connects the left and right halves (hemispheres) of the brain. Figure 2 shows the partition in corpus callosum. The posterior portion of the corpus callosum is called the splenium; the anterior is called the genu (or knee) between the two is the truncus (or body) of the corpus callosum. The body part of corpus calloum is having anterior callosal body, mid callosal body and posterior callosal body. The part between the body and the splenium is often thinly marked and thus referred to as the isthmus. The rostrum is the part of the corpus callosum that projects posteriorly and inferiorly from the anteriormost genu as can be seen on the sagittal image of the brain displayed on the right. The rostrum is so named for its resemblance to a bird's beak the Region of Interest (ROI) is the corpus callosum which is segmented for the epilepsy prediction.

Epilepsy: Epilepsy is a brain disorder in which a person has repeated seizures (convulsions) over time. Seizures are episodes of disturbed brain activity that cause changes in attention or behavior (Akselrod-Ballin *et al.*, 2009). In many cases, a cause cannot be identified however, factors that are associated include brain trauma, strokes, brain cancer, drug and alcohol misuse among others. Epilepsy occurs when permanent changes in brain tissue cause the brain to be too excitable or jumpy. The brain sends out abnormal signals. This results in repeated, unpredictable seizures. Symptoms vary from person to person. Some people may have simple staring spells while others have violent shaking and loss of alertness (Hills, 2007). The seizure depends on the part of the brain affected and cause of epilepsy.

Literature review: Da La Court *et al.* (2006) presented a multiscale spectral image segmentation algorithm. In

contrast to most multiscale image processing, the algorithm discussed on multiple scales of the image in parallel without iteration to capture both coarse and fine level details. The normalized cut graph partitioning framework is used for the image segmentation. A graph encoding pairwise pixel affinity is constructed and the graph is partitioned for image segmentation. Large image graphs can be compressed into multiple scales capturing image structure at increasingly large neighbourhood was demonstrated. The decomposition of the image segmentation graph into different scales can be determined by ecological statistics on the image grouping cues was discussed. Segmentation algorithm works simultaneously across the graph scales with an inter-scale constraint to ensure communication and consistency between the segmentations at each scale. Three orthogonal issues in multiscale image segmentation are argued: Multiscale signal processing to enhance faint contours, image region similarity cues at multiple scales provides texture/shape cues for larger regions and propagation of local grouping cues across multiple ranges of spatial connections allows us to detect coherent regions with faint boundary.

Bloom and Hynd (2005) studied the nature of corpus callosum. The corpus callosum is the major neural pathway that connects homologous cortical areas of the two cerebral hemispheres. Several studies take the position that the corpus callosum provides the pathway through which a hemisphere or cortical area can inhibit the other hemisphere or homologous cortical area in order to facilitate optimal functional capacity. The corpus callosum integrates information across cerebral hemispheres and thus serves an excitatory function in interhemispheric communication. Studies of callosotomies, callosal agenesis and language disorders theories of lateralization and hemispheric asymmetry and comparative research are critically considered. The available research no matter how limited, primarily supports the notion that the corpus callosum serves a predominantly excitatory function. There is evidence however, to support both theories and the possibility

remains that the corpus callosum can serve both an inhibitory and excitatory influence on the contralateral hemisphere.

Woodruff *et al.* (1995) researched that the corpus callosum area was significantly reduced by checking all levels in the human brain. The measures of corpus callosum in midsagittal area, length and corpus callosal area were discussed. The genu and the splenium of the corpus callosum have been the focus of investigation for many DTI studies examining white matter integrity in schizophrenia given its importance to neurobiological models of the disorder and ease of identification. Across voxelwise, region-of-interest and tractography based analyses of DTI data, evidence has accumulated indicating that this region is abnormal in schizophrenia. Grabczewski and Jankowski (2005) discussed two feature selection algorithms which take advantage of a decision tree criterion. Effective and versatile classification cannot be achieved by single classification algorithms. The methods are applied to a number of publicly available datasets and the results are compared to those obtained with some most commonly used feature selection techniques.

MATERIALS AND METHODS

The overall process of the proposed system is depicted in Fig. 3. MRI brain image is pre-processed using Threshold Interval Method and Min.-Max. normalization. Then, the pre-processed image is segmented using multiscale image segmentation and the shape features are extracted from the segmented image. Based on the features, the images are classified using CBR classification model and genetic classifier.

Image enhancement (pre-processing)

Threshold Interval Method: In the proposed system, the corpus callosum which is located at the centre of the brain comprises white matter tissue (i.e., the pixel represented corpus callosum has high intensity values). Portions of the corpus callosum boundary are indistinct which make it difficult to apply segmentation algorithm based on edge information alone. Thus, a pixel intensity value histogram of the corpus callosum derived from MR brain images where the corpus callosum is very well defined and easy to segment. A variation of Cour and Shi's algorithm is therefore developed that applied a threshold interval to extract objects with the same intensity values (such as corpus callosum) during the application of segmentation (Elsayed *et al.*, 2010). The corpus callosum have high pixel intensity value. Later, the result of the threshold interval is applied with pixel normalization.

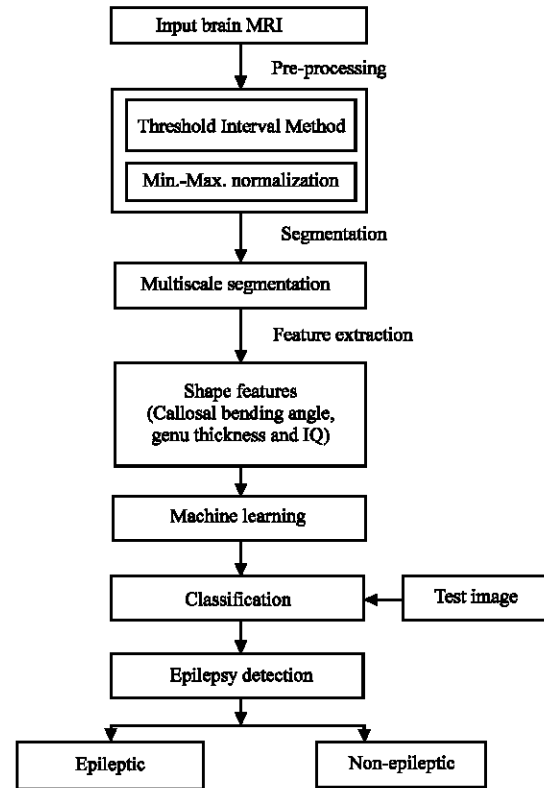


Fig. 3: Overall process of the proposed system

Min.-Max. normalization: This method is applied to images with poor contrast due to glare (Anitha *et al.*, 2012). The image is normalized before applying segmentation algorithm. The method improves the brightness of the image. The pixel normalization performs two steps:

- The minimum and maximum brightness of the image is computed
- The normalization is applied to every pixel. The linear normalization of a grayscale image is performed according to the Eq. 1:

$$I_N = (I - \text{Min.}) \frac{\text{newMax.} - \text{newMin.}}{\text{Max.} - \text{Min.}} + \text{newMin.} \quad (1)$$

where, I_N is the new image, the range of intensity values are represented using Min., Max., newMin. and newMax. The output image is stored in the database for the segmentation process.

Multiscale image segmentation: Corpus callosum is a commissural fiber bundle with a specific diffusion pattern which can be coded as prior knowledge in the segmentation framework. Using this information,

researchers prevent the hyper-surface from propagating into adjacent white matter structures such as cingulum, tapetum, minor and major forceps and tracts of the corona radiata (Gazzah and Ben Amara, 2008). Using the fact that the diffusivity in corpus callosum is perpendicular to the mid-sagittal plane of the brain, researchers consider a threshold (PDD_x Threshold) for the x-component (left-right component) of the PDD ($PDD_x(r)$) for propagating the front only inside the corpus callosum.

The x-component of the PDD is large throughout the structure body. However, corpus callosum fibers project to the cortical area at its genu and splenium where the x-component of PDD is not large anymore (Kuzniecky and Jackson, 2011). Fortunately, these fibers are considered as different fiber tracts of minor and major forceps and most of the studies investigating the different diffusion indices within the corpus callosum, exclude the minor and major forceps from that. The proposed segmentation steps are as follows:

- The initial seeds in corpus callosum of midsagittal plane have been selected
- The hyper-surface as the congregation of small spheres around the seed points is initiated
- Signed distance map from mask was created
- The interior and exterior mean was found
- Until convergence the following is continued; For each point r on the hyper-surface at step t :
 - The normal direction to the surface have been calculated
 - The 26 neighborhood points are calculated and the neighbours nr for r which are collinear with the normal with respect to the r
- Curve is evolved and the corpus callosum is segmented

Shape feature extraction

Callosal bending angle: The shape features are used to detect masses. The shape features are also called geometric features or morphological features. These types of features are based on the shape of ROI. The feature does not consider the intensity of the pixels in the region. It will take the shape of segmented region. The corpus callosum is automatically segmented from the brain MRI. The line segment was defined by dividing the upper and lower surfaces of the callosum into 40 equidistant portions by 39 nodes. The midpoints between corresponding nodes on the upper and lower surfaces were identified.

The line segment was created by joining endpoints and successive midpoints. Once the optimum endpoints and corresponding midpoints are identified, a smooth curve joining them was obtained with cubic spline

interpolation and the anteroposterior length of this curve was measured (callosal length). This curve is divided into 40 segments of equal lengths by 39 nodes.

At each node, the line orthogonal to the curve is calculated. The distance between its intersection with the dorsal and ventral surfaces of the callosum represented regional callosal thickness at these 39 points and the mean of these 39 regional thicknesses represented mean callosal thickness. Finally, a simple measure of curvature, the callosal bending angle is obtained by measuring the angle between two vectors each joining the midpoint, along the mid-spline of the callosum.

Genu thickness: Mean thickness in the anterior genu is significant predictor of transition to epilepsy. The variation in the thickness of the genu of corpus callosum in the selected subjects having epilepsy was compared to normal subjects. The chief measure types are visually illustrated in Fig. 4. Parcellation of the Corpus Callosum (CC) in the midsagittal cross-section of the brain is of utmost importance for diffusion properties. The method uses the watershed transform from markers and the choice of markers is based only on the diffusion properties inside the corpus callosum of each subject.

Traditional Classification Models: Classification is one of the most frequently encountered decision making tasks of human activity. A classification problem occurs when an object needs to be assigned into a predefined group or class based on a number of observed attributes related to that object. The individual observations are analyzed into a set of quantifiable properties known as various explanatory variables, features, etc. Classification can be thought of as two separate problems-binary classification and multiclass classification. In binary classification, a better understood task, only two classes are involved whereas in multiclass classification involves several classes. Implemented classification models include CBR, Support Vector Machine (SVM), decision tree, bayes and neural network.

Support Vector Machine (SVM): Support Vector Machine (SVM) which is related to supervised learning methods that analyze data and recognize patterns used for classification and regression analysis. Given a set of training images each image marked as belonging to one of two categories, SVM training algorithm builds a model that assigns new images into one category or the other.

Decision tree: A decision tree is a decision support tool that uses a tree-like graph or model of decisions and their possible consequences, including chance event outcomes

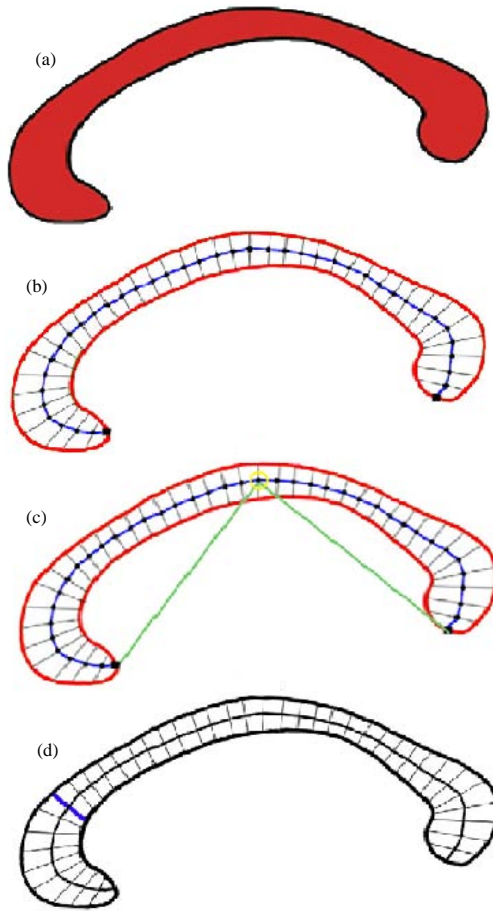


Fig. 4: a) Segmenting corpus callosum from mid-sagittal view; b) obtaining mid points and end points by traversing mid-spline in corpus callosum; c) bending angle of corpus callosum; d) measuring thickness of genu

resource costs and utility. Decision trees are commonly used in operations research, specifically in decision analysis to help identify a strategy most likely to reach a goal.

Neural networks: A neural network is used to refer a network or circuit of biological neurons. It consists of an interconnected group of artificial neurons and it processes information using a connectionist approach to computation. It has emerged as an important tool for classification.

Naive bayes classifier: A naive bayes classifier is a simple probabilistic classifier based on applying bayes theorem with strong (naive) independence assumptions. A more descriptive term for the underlying probability model would be independent feature model.

Proposed Classification Models

CBR classification: Case-based reasoning is used for classification. Case based reasoning can be defined as the methodology for solving problems by utilizing earlier experiences CBR uses a similar philosophy to that which humans sometimes use. It tries to solve new cases of a problem by using old previously solved cases. In case-based reasoning, the training cases are stored and accessed to solve a new problem.

Key concept in the whole system is to retrieve the similar cases. Similarity between two cases is computed using k-Nearest Neighbour (NN) algorithm. The main components of CBR are database of earlier cases, solution retrieval of previous cases and obtaining the solution. This model is called as R4 Model of CBR. Because this model can be represented by schematic cycle which contains four Rs:

- Retrieve the most similar cases
- Reuse the cases to attempt to solve the problem
- Revise the proposed solution
- Retain the new solution as a part of a new case

A new problem is solved by retrieving one or more earlier experienced cases in the case base, reusing the case in one way or another, revising the solution based in reusing a previous case and retaining the new experience by incorporating it into the existing case base. Each process involves a number of more specific steps for example, retrieve involves, identify, search, match and select.

Genetic classification: A Genetic Algorithm (GA) is a heuristic search that mimics the process of natural evolution. This heuristic is routinely used to generate useful solutions to optimization and search problems. In a genetic algorithm, a population of strings (called chromosomes) which encode candidate solutions (called individuals) to an optimization problem, evolves toward better solutions. The evolution usually starts from a population of randomly generated individuals and happens in generations. The GA steps is given:

- Generate initial population of individuals
- Do until 20 generations

Evaluate each population on the training set using fitness function as shown in Eq. 3:

$$\text{Fitness} = \gamma \frac{\text{Tol_Pats} - \text{Correct_Pats}}{\text{Tol_Pats}} + \delta \frac{\text{nmin}}{\text{Tol_Pats}} \tag{3}$$

Where:

- Tol_Pats = The number of total data patterns to be examined
- Correct_Pats = The number of patterns correctly classified in the transformed space with a feature subset of reduced dimensionality
- nmin = The cardinality of the near-neighbor minority set

The constants g and d are used to tune the processing of the algorithm, currently 2 and 0.2, respectively. Select the best in the population P_i to P_j :

- Crossover P_i individuals with P_j individuals
- Mutation P_i
- Replace least fit population with new individuals

RESULTS AND DISCUSSION

The performance of the proposed system is demonstrated using a MATLAB 2010b platform. A dataset of 250 images are taken from the oasis dataset (Brain 3). The cerebrum is divided into the left and right hemispheres, each consists of four lobes: frontal, parietal, occipital and temporal. The corpus callosum is the one that connects the left and right hemisphere. The pre-processing of the MRI brain image is performed by using threshold grayscale interval method. The corpus callosum can barely be recognized with a threshold interval of (0-80). With a threshold interval of (0-91), the corpus callosum is clearly defined which is shown in the Fig. 5 and 6, depicts the histogram of the pixel greyscale values of the input image. The corpus callosum starts to blur into the surrounding tissues using a threshold interval >91 . The significance here is that the high intensity of the corpus callosum can be exploited to yield a segmentation algorithm that is both effective and efficient across the input image set.

Multiscale segmentation is applied on the pre-processed image. Figure 7 describes the segmenting process of the corpus callosum. Then, at next stage the extracted corpus callosum is obtained which is depicted in the Fig. 8. Figure 9 shows the midpoint extraction and the angle extraction from the segmented corpus callosum. The shape features are extracted. The shape features obtained in the corpus callosum are genu thickness, the mid-sagittal angle and the Intelligent Quotient (IQ). Unitary callosal measures such as callosal length and callosal bending angle were compared between groups. The statistical measure of the corpus callosal bending angle is within the angle 91.34-109. The genu overall

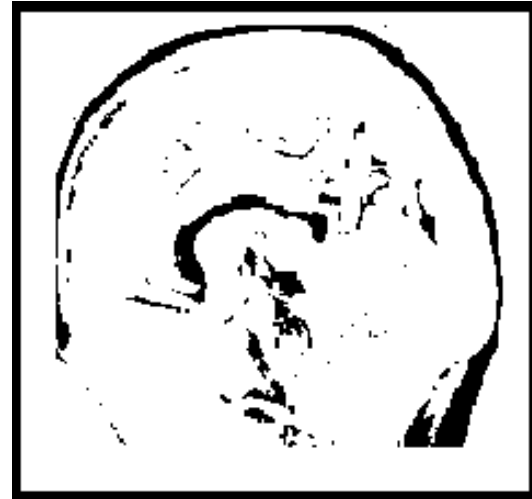

Fig. 5: Thershold interval between (0-91)

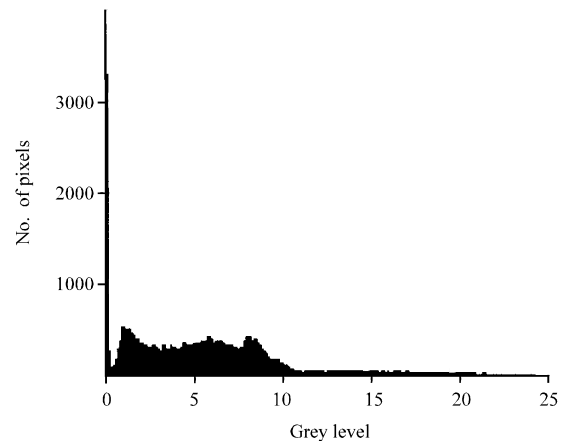


Fig. 6: Histogram of the pixel greyscale values

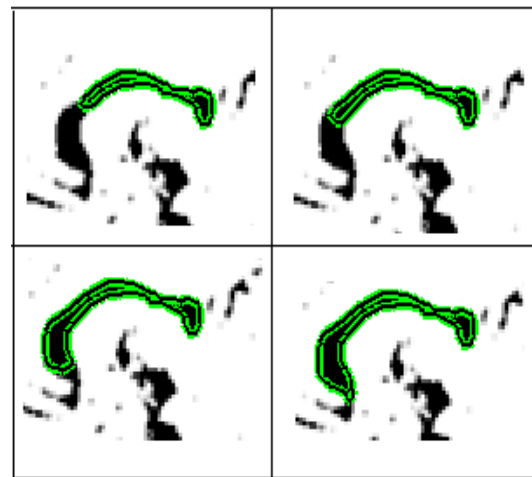


Fig. 7: The segmenting process of corpus callosum




Fig. 8: Segmented corpus callosum




Fig. 9: a) Midpoint extraction; b) angle extraction from segmented corpus callosum

thickness is 1.0-3.5 mm. Mean thickness in the anterior genu is a significant predictor of transition to epilepsy. The genu thickness is calculated with the help of parcellation.

Once the segmentation of the corpus callosum is performed in the midsagittal slice of the brain, the parcellation can be done. Parcellation is carried out by watershed transform which is depicted in Fig. 10. The accuracy of segmentation methods are compared based on entropy (Prasanth *et al.*, 2008). The entropy of an




Fig. 10: Parcellation of corpus callosum

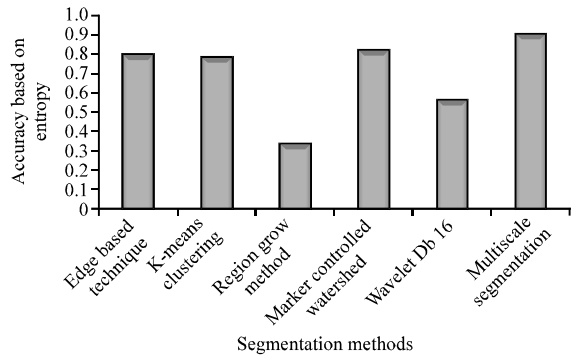


Fig. 11: Comparison of segmentation accuracy

image can be defined as a measure of the uncertainty associated with a random variable and it quantifies in the sense of an expected value, the information contained in a message. Entropy of an image E returns a scalar value representing the entropy of grayscale image I . The Entropy is a statistical measure of randomness that can be used to characterize the texture of the input image. Entropy is defined using Eq. 4 where p_i is the probability of event i :

$$\text{Entropy} = \sum_i -p_i \log_2 p_i \quad (4)$$

The accuracy comparison based on entropy of various segmentation algorithms are depicted in the Table 1 and Fig. 11. The comparison of segmentation methods based on execution time is tabulated in Table 2 which shows multiscale segmentation has less execution time compared to other traditional methods.

In the next stage of the comparison, MR images were segmented and the correct boundary of the corpus callosum was identified. Then, for detailed analysis the amount of false negatives and the amount of false positives of all resultant images were calculated (Gajanayake *et al.*, 2009). Completeness can be defined as the percentage of the complete region extracted by the segmentation algorithm and can be calculated using the Eq. 5:

Table 1: Accuracy of segmentation algorithms

Segmentation methods	Accuracy based on entropy
Edge based technique	0.7923
k-means clustering	0.7768
Region Grow Method	0.3325
Marker controlled watershed	0.8176
Wavelet Db16	0.5546
Multiscale segmentation	0.9151

Table 2: Execution time comparison of segmentation methods

Segmentation methods	Execution time (sec)
Edge based technique	1.32
k-Means Clustering	1.02
Region Grow Method	1.67
Marker controlled watershed	1.56
Wavelet Db16	1.05
Multiscale segmentation	0.86

$$\text{Completeness (\%)} = \frac{TP}{TP+FN} \times 100 \quad (5)$$

Where:

- TP = True Positive
- FN = False Negative
- TN = True Negative
- FP = False Positive

Correctness can be defined as the percentage of correctly extracted region by the segmentation algorithm and can be calculated using the Eq. 6:

$$\text{Correctness (\%)} = \frac{TP}{TP+FP} \times 100 \quad (6)$$

Table 3 depicts the calculated values of correctness and completeness of the segmentation methods. From the result, the correctness and the completeness measure of the multiscale segmentation >95%. So, this can be considered as the suitable method for the segmentation of 2D magnetic resonance images. In this study, classification algorithms are evaluated in terms of Sensitivity (Se), Specificity (Sp) and Accuracy (Acc). The values are tabulated in Table 4. The metrics are defined as:

$$\text{Sensitivity (\%)} = \frac{TP}{TP+FN} \times 100 \quad (7)$$

$$\text{Specificity (\%)} = \frac{TN}{TN+FP} \times 100 \quad (8)$$

$$\text{Accuracy (\%)} = \frac{TP+TN}{TP+FN+TN+FP} \times 100 \quad (9)$$

Where:

- TP = True Positive
- FN = False Negative
- TN = True Negative
- FP = False Positive

Table 3: Completeness and correctness of Segmentation methods

Segmentation methods	Completeness (%)	Correctness (%)
Edge based technique	84.0	71.0
K-means clustering	98.0	83.0
Region Grow Method	96.0	90.0
Marker controlled watershed	83.0	81.0
Wavelet Db16	91.0	92.0
Multiscale segmentation	99.2	96.5

Table 4: Performance results of classification model

Classification model	Sensitivity (%)	Specificity (%)	Accuracy (%)
Case based reasoning	97	89	96.7
Decision tree	87	73	81.0
SVM	93	89	95.6
Neural networks	86	70	78.0
Bayes	90	69	82.0
Genetic classification	98	89	97.2

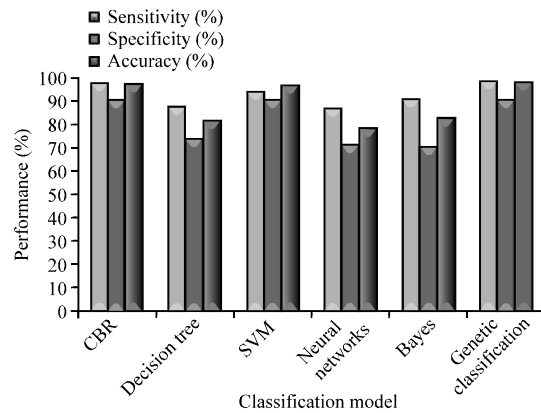


Fig. 12: Comparing Se, Sp and Acc of classification model

The performance result shows that CBR provides an overall Accuracy (Acc) of 96.7% and genetic classification provide 97.2% when compared to SVM, decision tree, bayes and neural network. Figure 12 shows the comparison results of classification models in terms of Se, Sp and Acc.

CONCLUSION

In this study, the corpus callosum is segmented and the shape features are extracted from the corpus callosum. The classification of epileptic and non-epileptic patients using case based reasoning classification model and genetic classification has been implemented. This study compares traditional classification models with CBR and genetic algorithm. Threshold Interval Method, Min.-Max. normalization, multiscale segmentation and optimized CBR Classification Model provides more prediction accuracy than traditional methods. Future research will include the application of the process for the detection of neurodegenerative diseases. Further alternative methods for pre-processing and post processing methods are to be introduced.

REFERENCES

- Akselrod-Ballin, A., M. Galun, J.M. Gomori, M. Filippi, P. Valsasina, R. Basri and A. Brandt, 2009. Automatic segmentation and classification of multiple sclerosis in multichannel MRI. *IEEE Trans. Biomed. Eng.*, 56: 2461-2469.
- Anitha, M., P. Tamije Selvy and V. Palanisamy, 2012. WML detection of brain images using fuzzy and possibilistic approach in feature space. *WSEAS Trans. Comput.*, 11: 180-189.
- Bloom, J.S. and G.W. Hynd, 2005. The role of corpus callosum in interhemisphere transfer of information: Excitation or inhibition? *Neuropsychol. Rev.*, 15: 59-71.
- Da La Court, A., M.M. Breteler, H. Meinardi, W.A. Hauser and A. Hofman, 2006. Prevalence of epilepsy in the elderly: The rotterdam study. *Epilepsia*, 37: 141-147.
- Elsayed, A., F. Coenen, C. Jiang, M. Garcia-Finana and V. Sluming, 2010. Corpus callosum MR image classification. *Knowledge-Based Syst.*, 23: 330-336.
- Gajanayake, R., R.D. Yapa and B. Hewavithana, 2009. Comparison of standard image segmentation methods for segmentation of brain tumors from 2D MR images. *Proceedings of the 4th International Conference on Industrial and Information Systems*, December 2009, Peradeniya, Sri Lanka, pp: 301-305.
- Ganguly, D., S. Chakraborty and T.H. Kim, 2010. A cognitive study on medical imaging. *Int. J. Bio-Sci. Bio-Technol.*, 2: 1-18.
- Gazzah, S. and N. Ben Amara, 2008. Neural networks and support vector machines classifiers for writer identification using Arabic script. *Int. Arab J. Inf. Technol.*, 5: 92-101.
- Grabczewski, K. and N. Jankowski, 2005. Feature selection with decision tree criterion. *Proceedings of the 5th International Conference on Hybrid Intelligent Systems*, November 6-9, 2005, Torun, Poland.
- Hills, M.D., 2007. The psychological and social impact of epilepsy. *Neurol. Asia*, 12: 10-12.
- Kuzniecky, R.I. and G.D. Jackson, 2011. *Magnetic Resonance in Epilepsy*. 2nd Edn., Neuro Imaging Techniques, USA.
- Prasanth, H.S., H.L. Shashidhara, K.N.B. Murthy and G. Madhavi Lata, 2008. Medical image segmentation. *Int. J. Comput. Sci. Eng.*, 2: 1209-1218.
- Woodruff, P.W., I.C. McManus and A.S. David, 1995. Meta-analysis of corpus callosum size in schizophrenia. *J. Neurol. Neurosurg Psychiatry*, 58: 457-461.