

## Histopathological Examination of the Liver and Gills of *Clarias gariepinus* Treated With Glyphosate

O.I. Ayanda and E.A. Egbamuno  
Department of Biological Sciences, Covenant University,  
P.M.B. 1023 Ota, Ogun State, Nigeria

**Abstract:** Healthy live fishes *Clarias gariepinus* (average weight and length; 40-50 g and 12-22 cm) were procured from a farm and acclimatized at  $28 \pm 1.2^\circ\text{C}$  for a minimum of 2 weeks prior to treatment. The water was changed once every 48 h to maintain the test medium. About 10 fishes each in Groups A-D with two replicates were exposed to 0.02, 0.04, 0.08 and 0.00% v/v of glyphosate in that order for a period of 15 days. Fishes were killed after the 5th, 10th and 15th days their gills and liver removed and prepared for histopathological observation. They were fixed in bouin's fluid for 24 h, washed with 70% ethanol and dehydrated through a graded series of ethanol. They were embedded in paraffin, sectioned at 4-5  $\mu\text{m}$  thickness stained with haematoxylin and eosin and examined using light microscope and photomicrography. The gills of both the control and treated fishes from histopathological examination showed no damage. However, the liver of treated fishes showed different degrees of damaged ranging from mild portal to congestion of central veins.

**Key words:** Glyphosate, histopathology, *Clarias gariepinus*, liver and gills, veins, damage

---

### INTRODUCTION

Fish is a highly nutritious source of protein which is tasty and easily digested. It is much sought after by a broad cross-section of the world's population, particularly in developing countries. It is estimated that around 60% of people in many developing countries depend on fish for >30% of their animal protein supplies while almost 80% in most developed countries obtain <20% of their animal protein from fish (FAO, 2005). Fish products are comparable to meat and dairy products in nutritional quality, depending on the methods used in preservation and preparation. The protein content of most fish averages 15-20%.

Fish also contains significant amounts of all essential amino acids, particularly lysine in which cereals are relatively poor. Fish protein can be used therefore to complement the amino acid pattern and improve the overall protein quality of a mixed diet (FAO, 2005). Moreover, the sensory properties of an otherwise bland diet can be enhanced through fish products thus facilitating and contributing to greater consumption. Whereas cereal grains are usually low in lysine and/or the sulphur-containing amino acids (methionine and cysteine), fish is an excellent source of these acids. A fish supplement can significantly raise the biological value of a cereal-based diet.

*Clarias gariepinus*, an omnivore freshwater fish is a popular delicacy relished throughout tropical Africa. It is a prominent culture species because of its hardiness and fast growth rate. *Clarias gariepinus* (Teugels, 1986) family Clariidae is generally considered to be one of the most important tropical catfish species for aquaculture in West Africa (Clay, 1979). It is highly priced in Nigeria either as smoked, dried or fresh. *Clarias* sp. inhabit calm freshwaters ranging from lakes, streams, rivers and swamps to flood plains, many of which are subject to seasonal drying. The most common habitats of the catfish are flood plains, swamps and pools. The catfish can survive during the dry seasons due to the possession of accessory air breathing organ (Bruton, 1979; Clay, 1979).

Pesticides and herbicides at high concentration are known to reduce the survival, growth and reproduction of fish and produce many visible effects on fish (Rahman *et al.*, 2002). Toxicity testing of chemicals on animals has been used for a long time to detect the potential hazards posed by chemicals to man. Bioassay technique has been the cornerstone of programmes on environmental health and chemical safety (Ward and Parrish, 1982). Aquatic bioassays are necessary in water pollution control to determine whether a potential toxicant is dangerous to aquatic life and if so, to find the relationship between the toxicant concentration and its effect on aquatic animals (Olaifa *et al.*, 2003). The

application of environmental toxicology studies on non-mammalian vertebrates is rapidly expanding and for the evaluation of the effects of noxious compounds (Ayoola, 2008).

Herbicides are widely used for the control of water plants which may impede the flow of water during the summer when sudden heavy rain can cause flooding (Annune *et al.*, 1994). While the direct effect of herbicides addition is the loss of macrophytes, non-target organisms such as fish may also be affected through loss of habitat and food supply (Ervest, 2004). Glyphosate, the active ingredient which is the 48% acid equivalent, of the isopropylamine salt of glyphosate (N-phosphonomethyl glycine) is used as a non-selective herbicide and for control of a great variety of annual, biennial and perennial grasses, sedges, broad-leaved weeds and woody shrubs.

They are also used in fruits orchards, vineyards, conifer plantations and many plantation crops. It is perhaps the most important herbicide ever developed (WHO, 1994).

Because of its low persistence, repeated applications of this herbicide are practiced for the control of weeds in agricultural fields and thereby, large quantities find their ways into the water bodies. However, only a few reports have described its effects on fresh water fish (Mitchell *et al.*, 1987; Servizi *et al.*, 1987; Ayoola, 2008).

The indiscriminate use of herbicide, careless handling, accidental spillage or discharges of treated effluents into natural waterways have harmful effects on the fish population and other forms of aquatic life and may contribute long term effects in the environment (Akhtar, 1986). Xenobiotic compounds usually concentrate in the tissues of aquatic biotas and are known to produce cumulative deleterious effects (Abbas, 1998; Abbas and Mahmood, 2004). These pollutants build up in the food chain and are responsible for the adverse effects and death in aquatic organisms (Farkas *et al.*, 2002). Fishes are widely used to evaluate the health of aquatic ecosystem and physiological changes serves as biomarkers of environmental pollution (Kock *et al.*, 1996).

Environmental contamination with herbicides is a problem of worldwide importance. Data on their bioaccumulation and excretion by fish are therefore valuable both for the assessment of the safety of herbicides for man and the extent of contamination of the environment. Few studies exist on the effects of herbicides on Nigerian fishes (Oti, 2003), therefore studies need to be carried out to determine the effect of different herbicides on Nigerian fishes. It is in this light this study

was carried out to determine the effect of glyphosate, a well-used herbicide, on a common Nigerian fish *Clarias gariepinus*.

## MATERIALS AND METHODS

Specimens of juvenile *C. gariepinus* of average weight and length; 40-50 g and 12-22 cm were used for the experiment. This is due to the increased sensitivity in juveniles when compared to adults (Odiette, 1999; Solbe, 1995). They were purchased from the EDS village in Cnaanland, Ota. The fish were acclimatized for 2 weeks in 30 L aquaria, temperature  $28^{\circ}\text{C}\pm 1.2$ , dissolved oxygen  $7.2\pm 0.1$  and pH 7.0 during which they were fed with commercial floating pellet feed at 5% of their body weight once per day and feeding was discontinued 24 h to the commencement of treatment. Unconsumed feed was removed and the water was changed every 48 h. A commercial formulation of glyphosate (Roundup<sup>®</sup>) containing isopropylammonium salt of glyphosate at  $480\text{ g L}^{-1}$  as the active ingredient (equivalent to 360 g glyphosate per liter) and inert components such as POEA surfactant and water was used.

Ten fish per tank were exposed to three sub-lethal concentrations of glyphosate (0.02% v/v; 0.04% v/v and 0.08% v/v) and a control, i.e., 0% v/v (non-chlorinated water and glyphosate). Each experimental condition was replicated twice >15 days period. These concentrations were selected based on earlier range finding test results of acute toxicity. The test water was renewed once at 2 days. Fish also were fed once per day. Two fishes from each of the treatment groups and the control were killed by cervical dislocation at the end of 5th, 10th and 15th day.

The liver and gills were removed and prepared for histopathological observation. They were fixed in bouin's fluid for 24 h, washed with 70% ethanol and dehydrated through a graded series of ethanol (Schalm *et al.*, 1975; Kelly, 1979). They were embedded in paraffin, sectioned at 4-5  $\mu\text{m}$  thickness stained with haematoxylin and eosin and examined using light microscope and photomicrography (Keneko, 1989).

## RESULTS AND DISCUSSION

**Liver:** The liver of the control fishes showed no sign of any histopathological damage throughout the period of study. However, there were varying degrees of damage to the liver in all the treatment groups. Fishes in Group A showed extensive vacuolation of the hepatocytes after 5 days (Fig. 1). They showed extensive vacuolation of the hepatocytes, mildportal and central venous congestion after the 10th and 15th day (Fig. 2 and 3). All the fishes in Group B showed only extensive

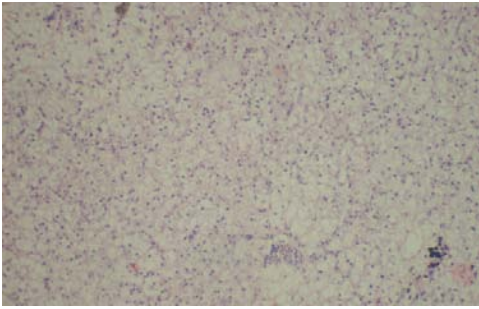


Fig. 1: Liver of Group A fishes after 5 days show extensive vacuolation of the hepatocytes

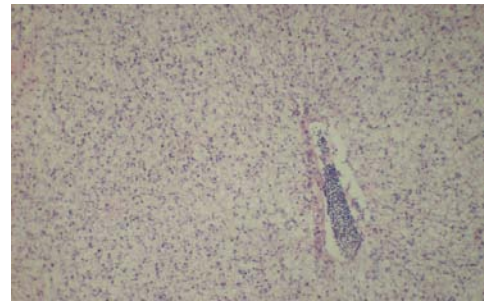


Fig. 4: Liver of Group B fishes after 5 days showing extensive vacuolation of the hepatocytes

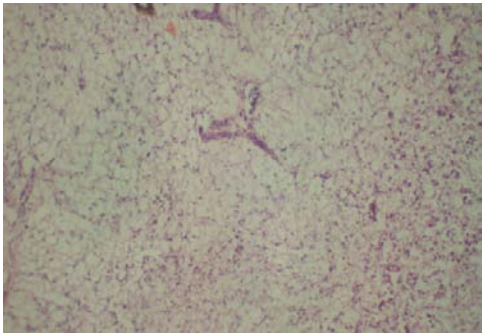


Fig. 2: Liver of Group A fishes after 10 days extensive vacuolation of the hepatocytes mildportal and central venous congestion

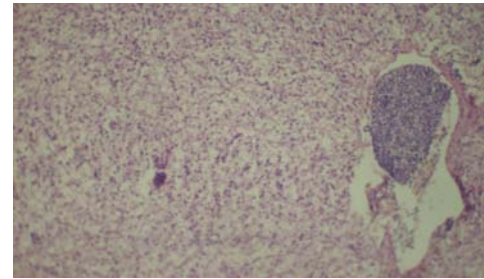


Fig. 5: Liver of Group B fishes after 10 days showing extensive vacuolation of the hepatocytes

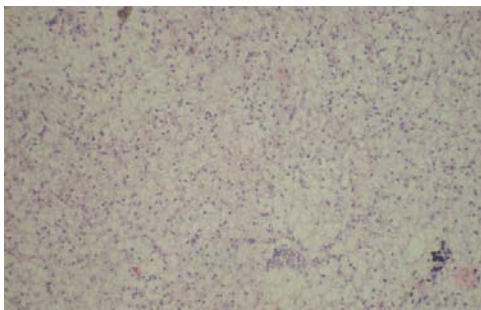


Fig. 3: Liver of Group A fishes after 15 days showing extensive vacuolation of the hepatocytes, mildportal and central venous congestion

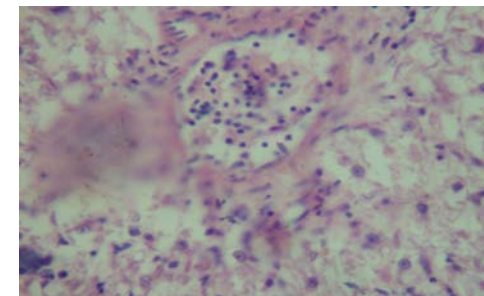


Fig. 6: Liver of Group B fishes after 15 days showing extensive vacuolation of the hepatocyte

vacuolation of the hepatocytes during the whole period of treatment (Fig. 4- 6). Fishes in Group C also all showed diffuse vacuolation of the hepatocytes throughout the treatment period.

**Gills:** Fishes in all of the groups after the 5th, 10th and 15th day showed no sign of any form of damage whatsoever (Fig. 7-10).

There were no visible lesions among the gills of control fishes or treatment groups despite increasing concentrations of the toxicant over the 15 days period. This is in contrast to earlier report like Ayoola (2008) who recorded varying degrees of histopathological damages in the gills of fish treated with glyphosate. Other reports Doherty *et al.* (2011), etc. on the effects of toxicants in gills also reported different damages to it. From previous reports on the effects of toxicants on gills, one of the areas of damages is in the lamella. The walls of the lamellae are covered by mucus. The thickness of the layer is known to vary but the exact thickness is not known.

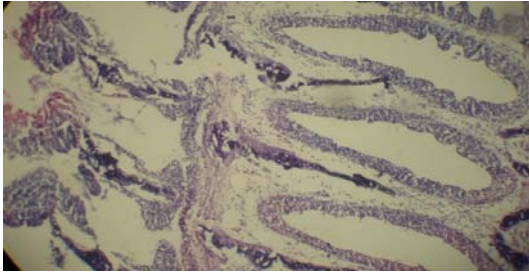


Fig. 7: Gills of Group A fishes after 15 days show no visible lesions

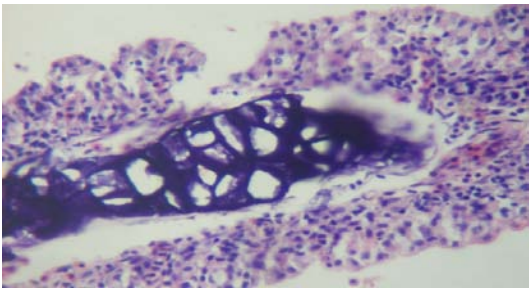


Fig. 8: Gills of Group B fishes after 15 days show no visible lesions

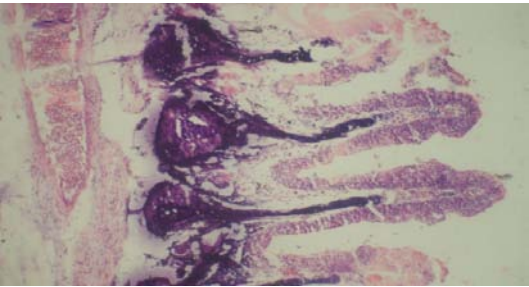


Fig. 9: Gills of Group C fishes after 15 days showing no visible lesion

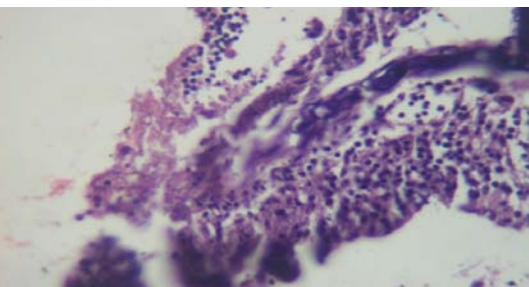


Fig. 10: Gills of control group after 15 days show no visible lesion

The mucus layer is at least thick enough to cover the ridges observed on the surface of the gill epithelium

(Randall and Wright, 1989). Mucus is washed away continuously by the water stream and replaced by the secretions of mucous cells.

The rate of mucus secretion increases in fish exposed to a number of toxic chemicals and to acidotic conditions (Packer and Dunson, 1970, 1972; Wood and McDonald, 1982). Mucus is 95% water, containing glycoproteins with high sialic acid content, constituting a polyionic layer on the surface of the gills. It is a possibility that the above protective mechanism in the gills played out in this research. Also according to McKim and Erickson (1991), aquatic toxicologists have observed definite effects on the toxicity and bio-concentration of chemicals in aquatic animals exposed to the same chemicals under varying environmental conditions of O<sub>2</sub>, temperature, pH, salinity and dissolved and particulate organics. These environmental variables can increase or decrease the flux of a chemical across the respiratory surface of a fish, depending on the specific properties of the chemical and organism. Probably, interplay between these environmental conditions might have skewed in favour of a decrease in the flux the toxicant across the fish gill. This is understandable since the higher the frequency of contact of the fish gill with the contaminated water the higher the tendency for it to damage the gills.

Another reason why the gills show no histopathological damage may not be far-fetched. Knowledge of the general physiology of the fish gill shows that the route that a waterborne chemical takes as it moves from the water into a fish can be described as follows: movement of water with the dissolved chemical through the gill lamellar sieve by the branchial pump; diffusion of the chemical across the water flow channel and the gill epithelium and into the blood and removal of the chemical from the gill by the blood (McKim and Erickson, 1991). If the above processes did take place in the order stated and taking into consideration the fact that fishes used in this study are relatively larger than those reportedly used in other studies which by extension will also mean that they have developed stronger defence systems and are more suited to tolerate or get rid of foreign materials in the water medium. Consequently, they do not exhibit the same degree of sensitivity.

Liver of fishes in Group A showed extensive vacuolation of the hepatocytes on the 5th day and progressive damage was observed as mild portal and central venous congestion were observed on the 15th (Fig. 1-3). The hepatic tissue of the treatment Group B also showed a similar pattern with the damage increasing as the treatment time prolonged. The hepatic tissues of Group C (Fig. 11-13) shows diffuse vacuolation of hepatocytes. The control group showed no lesions, no



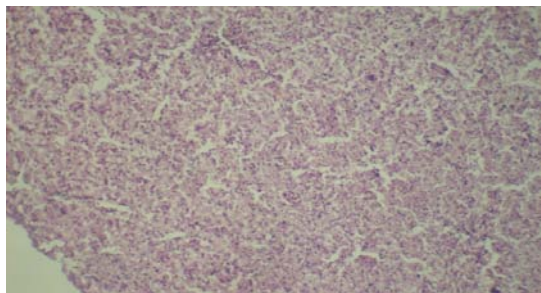


Fig. 11: Liver of Group C fishes after 5 days shows mild, diffuse vacuolation of hepatocytes

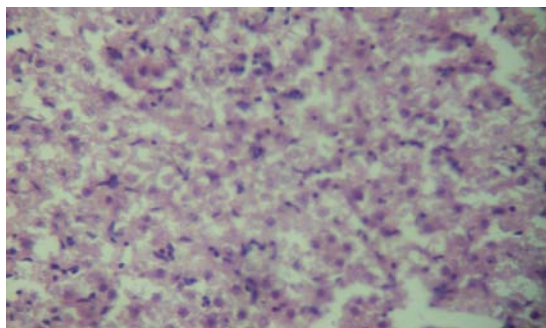


Fig. 12: Liver of Group C fishes after 10 days show diffuse vacuolation of hepatocytes

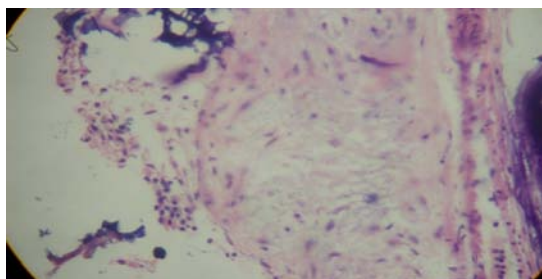


Fig. 13: Liver of Group C fishes after 15 days, diffuse vacuolation of hepatocytes

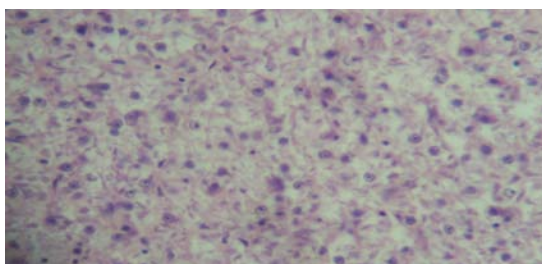


Fig. 14: Liver of the control group after 15 days showing no lesions

vacuolation and no necrosis throughout the treatment period (Fig. 14). This result is in agreement with those of

other similar researchers Omitoyin *et al.* (2006), Ayoola (2008) and Doherty *et al.* (2011) who all reported various degrees of damage to liver after treatment with different toxicants. According to Belicheva and Sharova (2011), high incidence of histological alterations in the gill, liver and kidney is an evidence of the poor environmental quality. Histopathological lesions respond to both direct toxicant effects of contaminated water and sediments and secondary stress effects caused by factors such as parasitism. Most of the histopathological alterations observed in the present study (e.g., cellular infiltration, extensive vacuolation of the hepatocytes, mild portal and central venous congestion, etc.) could be interpreted as a nonspecific response to stress and are described in fish exposed to a wide spectrum of pollutants.

Liver of fish is responsible for the digestion, filtration and storage of glucose. It is found in the anterior part of the body cavity as a brownish red mass. The liver also, produces many enzymes that stored in the gall bladder. These enzymes assist in the breakdown of food. The liver functions to store food energy (Tayel *et al.*, 2008). The organ most associated with the detoxification and biotransformation process is also the liver and due to its function, position and blood supply, it is also one of the organs most affected by contaminants in the water (Camargo and Martinez, 2007).

The histological alterations identified within the hepatocytes in this study may have been the results of various biochemical lesions. The alterations such as portal and central veinous congestions, cellular vacuolation and infiltration may be attributed to the accumulation of lipids and glycogen due to liver dysfunction as a result of exposure to the toxicants. Pacheco and Santos (2002) also described increased level of vacuolation of the hepatocytes as a signal to the degenerating process that suggest metabolic damage, possibly related to exposure to contaminated water.

It is well known that the liver of certain animals are capable of rapid restoration if part of it is damaged. The hepatic cells in the unharmed part undergo extensive mitosis. Similar situations are reported in fish livers (Hibiya, 1982). Dividing cells are usually not seen in normal liver. The liver can regenerate new liver parenchyma after destruction due to toxic substances (Ross *et al.*, 1989). The absence of any form of necrosis in the present study most likely means the damaged cells are quickly regenerating.

## CONCLUSION

This study shows histological changes were observed in the liver of the *C. gariepinus* in the

study. This is indicative of the fact that the fish were responding to the effects of the contaminant, glyphosate together with associated stress responses. The degree of congestion, cellular infiltration and vacuolation of the hepatocytes was noted to be concentration dependent.

#### ACKNOWLEDGEMENT

Researchers will like to acknowledge the assistance of Dr. Amos Abolaji in getting the histopathology done.

#### REFERENCES

- Abbas, H.H.H. and H.M. Mahmood, 2004. Haematological and biochemical changes in *Oreochromis aureus* and *Clarias gariepinus* exposed to mixtures of copper and lead salts. *Egypt. J. Basic Applied Physiol.*, 3: 89-106.
- Abbas, H.H.H., 1998. Toxicological effect of copper and lead on some physiological aspects in two fish species, blue tilapia, *Oreochromis niloticus* and African catfish, *Clarias gariepinus*. Ph.D. Thesis, Faculty of Science, Cairo University, Egypt.
- Akhtar, M.H., 1986. The disposition of <sup>14</sup>C agrochemical residues in plant and animal tissues when consumed by animals. Proceedings of the 6th International Congress of Pesticide Chemistry Ottawa, August, 1986, Canada, pp: 10-15.
- Annune, P.A., S.O.N. Hbele and A.A. Oladimeji, 1994. Acute toxicity of cadmium to juveniles of *Clarias gariepinus* (Tuegls) and *Oreochromis niloticus* (Trewavas). *J. Environ. Sci. Health*, 29: 1357-1365.
- Ayoola, S.O., 2008. Histopathological effects of glyphosate on juvenile African catfish (*Clarias gariepinus*). *Am. Eur. J. Agric. Environ. Sci.*, 4: 362-367.
- Belicheva, L.A. and J.N. Sharova, 2011. Assessment of fish health status under long-term water pollution: Vygozero reservoir, North-West Russia. *Environ. Technol. Resour.*, 2: 368-373.
- Bruton, M.N., 1979. The breeding biology and early development of *Clarias gariepinus* (Pisces: Clariidae) in Lake Sibaya, South Africa, with a review of breeding in species of the subgenus *Clarias* (*Clarias*). *Trans. Zool. Soc. London*, 35: 1-45.
- Camargo, M.M.P. and C.B.R. Martinez, 2007. Histopathology of gills, kidney and liver of a Neotropical fish caged in an urban stream. *Neotrop. Ichthyol.*, 5: 327-336.
- Clay, D., 1979. Population biology, growth and feeding of the African catfish (*Clarias gariepinus*) with special reference to juveniles and their importance in fish culture. *Arch. Hydrobiol.*, 87: 453-482.
- Doherty, V.F., M.K. Ladipo and S.A. Oyebadejo, 2011. Acute toxicity, behavioural changes and histopathological effect of paraquat dichloride on tissues of catfish (*Clarias Gariepinus*). *Int. J. Biol.*, 3: 67-74.
- Ervnest, H., 2004. A Textbook of Modern Toxicology. 3rd Edn., John Wiley and Sons Hoboken, New Jersey, USA., Pages: 557.
- FAO, 2005. Nutritional elements of fish. Food and Agriculture Organization of the United Nations, Fisheries and Aquaculture Department <http://www.fao.org/fishery/topic/12319/en>
- Farkas, A., J. Salanki and A. Specziar, 2002. Relation between growth and the heavy metal concentration in organs of bream, *Abramis brama* L. populating lake Balaton. *Arch. Environ. Contam. Toxicol.*, 43: 236-243.
- Hibiya, T., 1982. An Atlas of Fish Histology: Normal and Pathological features. Kadansha Ltd., Tokyo, Japan, pp: 82-90.
- Kelly, W.R., 1979. Veterinary Clinical Diagnosis. 2nd Edn., Balliere Tindall, London, pp: 266-279.
- Keneko, J.J., 1989. Clinical Biochemistry of Domestic Animals. 4th Edn., Academic press Inc., California, Pages: 132.
- Kock, G., M. Triendi and R. Hofer, 1996. Seasonal pattern of metal accumulation in Arctic char (*Salvelinus alpinus*) from an oligotrophic Alpine lake related to temperature. *Can. J. Fish. Aquat. Sci.*, 53: 780-786.
- McKim, J.M. and R.J. Erickson, 1991. Environmental impacts on the physiological mechanisms controlling xenobiotic transfer across fish gills. *Physiol. Zool.*, 64: 39-67.
- Mitchell, D.G., P.M. Chapman and T.J. Long, 1987. Acute toxicity of round up and Redeo herbicides to rainbow trout, Chinook and Coho salmon. *Bull. Environ. Contam. Toxicol.*, 39: 1028-1035.
- Odiette, W.O., 1999. Environmental Physiology of Animal and Pollution. 1st Edn., Diversified Resources Ltd., Lagos, Nigeria, ISBN: 978-028-957-7, pp: 360.
- Olaifa, F.E., A.K. Olaifa and O.O. Lewis, 2003. Toxic stress of lead on *Clarias gariepinus* (African catfish) fingerlings. *Afr. J. Biomed. Res.*, 6: 101-104.
- Omitoyin, B.O., E.K. Ajani, B.T. Adeshina and C.N.F. Okuagu, 2006. Toxicity of Lindane (ΓHexachloro-CycloHexane) to *Clarias gariepinus* (Burchell 1822). *World J. Zool.*, 1: 57-63.
- Oti, E.E., 2003. Acute toxicity of gammalin 20 to *Chrysichthys nigrodigitatus* (leacepede). *Sci. forum J. Pure Applied Sci.*, 6: 219-225.

- Pacheco, M. and M.A. Santos, 2002. Biotransformation, genotoxic and histopathological effect of environmental contaminants in European eel (*Anguilla anguilla*). *Ecotoxicol. Environ. Saf.*, 53: 331-347.
- Packer, R.K. and W.A. Dunson, 1970. Effects of low environmental pH on blood pH and sodium balance of brook trout. *J. Exp. Zool.*, 174: 65-71.
- Packer, R.K. and W.A. Dunson, 1972. Anoxia and sodium loss associated with the death of brook trout at low pH. *Comp. Biochem. Physiol. A Comp. Physiol.*, 41: 17-26.
- Rahman, M.Z., Z.M. Hossain, M.F.R. Ellah and G.U. Ahmed, 2002. Effect of Diazinon 60EC on *Anabustudineus*, *Chama punctatus* and *barbadesgomonous*, Naga. *Int. Center Living Aquat. Resour. Manage. Q.*, 25: 8-11.
- Randall, D.J. and P.A. Wright, 1989. The interaction between carbon dioxide and ammonia excretion and water pH in fish. *Can. J. Zool.*, 67: 2936-2942.
- Ross, M.H., E.J. Reith and L.J. Romrell, 1989. *Histology: A Text and Atlas*. 2nd Edn., Williams and Wilkins, Baltimore, USA., ISBN-13: 9780683073683, Pages: 783.
- Schalm, O.W., N.C. Jain and E.J. Carroll, 1975. *Veterinary Haematology*. Lea and Febiger, Philadelphia, USA., pp: 15-81.
- Servizi, J.A., R.W. Gordon and D.W. Martens, 1987. Acute toxicity of Garlon 4 and Roundup herbicides to salmon, *Daphnia* and trout. *Bull. Environ. Contam. Toxicol.*, 39: 15-22.
- Solbe, J.F., 1995. Fresh Water. In: *Handbook of Ecotoxicology*, Collins, P. (Ed.). Black Well Science Ltd., Osney Mead, Pages: 683.
- Tayel, S.I., A.M. Yacoub and S.A. Mahmoud, 2008. Histopathological and haematological responses to freshwater pollution in the Nile catfish *Clarias gariepinus*. *J. Egypt. Acad. Soc. Environ. Dev.*, 9: 43-60.
- Teugels, G.G., 1986. A Systematic Revision of the African Species of the Genus *Claries* (Pisces: Clariidae). *Museum Resource Africa Centre*, Belgium, pp: 63-72.
- WHO, 1994. *Glyphosate. Environmental Health Criteria*, Geneva, Switzerland.
- Ward, G.S. and P.R. Parrish, 1982. *Manual of Methods in Aquatic environmental research*. Part 6. Toxicity Tests. *FAO Fisheries Technical Paper*, No 185 FIRI/T185.
- Wood, C.M. and D.G. McDonald, 1982. Physiological Mechanisms of Acid Toxicity to Fish. In: *Acid Rain Fisheries*, Johnson, R.E. (Ed.). American Fisheries Society, Bethesda, USA., pp: 197-226.