

## Wound Healing Activity of *Carica papaya* L. Aqueous Leaf Extract in Rats

Mahmood, A.A., K. Sidik and I. Salmah  
Department of Molecular Medicine, Faculty of Medicine,  
University of Malaya, 50603 Kuala Lumpur, Malaysia

**Abstract:** The aqueous extract of *Carica papaya* leaves were investigated for evaluation of wound healing potential in rats. Four groups of male *Sprague Dawley* rats each consist of 6 animals. All animals were experimentally wounded in the posterior neck area. Blank Vaseline was applied topically to wounds of Group 1 animals. Group 2 and Group 3 rats were treated topically with 5 and 10% Vaseline, respectively. Solcoseryl jelly was applied topically to wounds of Group 4 animals as a reference. The effects of vehicles on the rate of wound healing were assessed. Wounds treated with 5 and 10% Vaseline and wounds treated with solcoseryl jelly significantly accelerate wound healing potential compared to wounds treated with Blank Vaseline. These results strongly document the beneficial effects of plant extract for the acceleration of wound healing process in rats.

**Key words:** *Carica papaya*, solcoseryl jelly, vaseline, wound healing, rats

### INTRODUCTION

*Carica papaya* is used as food or as medication in folk medicine, papain is the active principle in *Carica papaya* that exerts the ulcer-protective effect<sup>[1]</sup> reduces gastric acid secretion induced by histamine in rats<sup>[2]</sup> *Carica papaya* fruit extract possess antibacterial<sup>[3]</sup> antioxidant<sup>[4]</sup> anti-inflammatory activity<sup>[5]</sup> antifertility<sup>[6]</sup> antihypertensive agent<sup>[7]</sup> chronic skin ulcer therapy<sup>[8]</sup> and diuretic effects<sup>[9]</sup>.

Papain from papaya was one of the earliest substances used for debrdement Both papaya as fruit and papain as a commercially available powder are used in wound care<sup>[10]</sup>. Green papaya is rich in two enzymes that have very strong digestive properties: Papain and chymopapain. Papain, the enzyme used in commercial meat tenderizers, has the ability to dissolve dead tissue without damaging living cells. The stems, leaves and fruits contain copious amount of latex. Accuzyme, a debriding ointment that contains papain and urea, is available to debride necrotic tissue and liquefy slough in a variety of acute and chronic lesions<sup>[11]</sup>. Chymopapain was also used in the healing and recovery of surgical wounds. As the fruit ripens, papain and chymopapain dissipate; neither is present in the ripe fruit<sup>[12]</sup>. Arvigo and Balick<sup>[13]</sup> reported that sliced fruit or crushed papaya seeds applied to wounds, curs and infections assisted with healing. Carpaine, an alkaloid compound, is also found in green papaya and has been shown to have antibacterial properties In laboratory tests, extracts from the epicarp (skin) endocarp (flesh) and seeds of both ripe and unripe papaya showed *in vitro* antibacterial activity against several microorganisms<sup>[3]</sup>.

Papaya also has fibrinolytic properties, which help to remove slough from wounds. There may also be a proteolytic effect on bacteria, resulting from the production of a coagulum that immobilize microorganisms and protects the host against bacterial infection<sup>[14]</sup>. The present study was undertaken to determine the wound healing activity of the leaf extract of *Carica papaya* in experimental wounds in rats.

### MATERIAL AND METHODS

**Vaseline (100% pure petroleum jelly):** Vaseline is a brand of petroleum jelly originally produced by Chesebrough-Pond's, USA and currently by Unilever. Vaseline is obtained from the local pharmacy.

**Solcoseryl-jelly:** Solcoseryl Jelly manufactured by Solco Basle Ltd. (CH-4127) Birsfelden, Switzerland is obtained from the local pharmacy.

**Collection of *Carica papaya*:** *Carica papaya* leaves were collected and identified by comparison with specimens available at the Herbarium of the Forest Research Institute, Kepong, Malaysia. Voucher specimens of the plant material are deposited at Department of Pharmacy, University of Malaya, Malaysia.

**Preparation of plant extracts:** *Carica papaya* fresh leaves of this plant were cut, labelled, wash with distilled water and dried in oven 50°C for 5- 7 days until fully dried. The Leaves were ground to a fine texture form using a grinder, and then 50 g of blended plant were weighted and placed into 1000 mL flask.

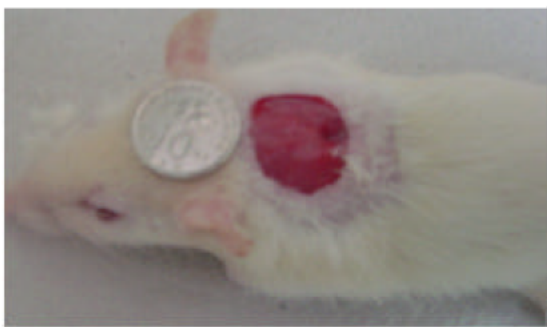


Fig. 1: 2 cm diameter excision skin wound on day 0 before application of vehicle

The water was added in ratio 1:20. After that, it was heated and stirred on hotplate for 3 h. Next, after being left cool using filter paper and filter funnel filtered it. The step was followed by rotor vaporised to remove the water. Aqueous extract was then submitted to lyophilization by a freeze-dryer, to produce powdered forms of the extract. The freeze-dried products were mixed with Vaseline in a concentration of 5% (50 mg extract/g Vaseline, w/w) and 10% (100 mg extract/g Vaseline, w/w) Vaseline, respectively.

**Experimental animals:** *Sprague Dawley* adult male rats were obtained from the animal house, Faculty of Medicine, University of Malaya. The rats were divided randomly into 4 groups of 6 rats each. Each rat that weighted between 180-200 gm was housed separately (one rat per cage). The animals were left for 48 h to acclimatize to the animal room conditions and were maintained on standard pellet diet and tap water.

**Experimentally induced wounds:** An area of uniform wound 2 cm in diameter was excised from the nape of the neck of all rats with the aid of round seal as described by Morton and Melone<sup>[5]</sup> (Fig. 1) in previously shaved, disinfected with 70% alcohol and injected with 1 mL of Lignocaine HCl (2%, 100 mg 5 mL<sup>-1</sup>), to the depth of the muscle, avoiding incision of the muscle layer itself and tension of skin was kept constant during the procedure.

**Topical application of vehicles:** Group 1 rat each was treated with a thin layer of blank Vaseline (100% pure petroleum jelly) as control twice daily. Group 3 and Group 4 animals were treated with a thin layer of 5 and 10% Vaseline twice daily; respectively. A thin layer of commercial solcoseryl jelly was topically applied twice daily to wounds of Group 4 rat as reference.

**Statistical analysis of data:** Results were expressed as Mean±S.M.E. The statistical difference between the groups in the term of the mean of wound healing was calculated by using Student's *t*-test.

## RESULTS AND DISCUSSION

The present study showed that aqueous extract of *Carica papaya* leaves accelerates the progression of wound healing activity (Table 1). Wounds treated with 5 and 10% Vaseline and Solcoseryl jelly showed considerable signs of dermal healing and significantly ( $p<0.05$ ) healed earlier compare to control (Table 1; Fig. 2 and 3). No significant differences exist among animals treated with 5%, 10 Vaseline and solcoseryl jelly in the term of rat of wound healing activity (Table 1)

The fresh leaves and extract of the plant *Carica papaya* are a traditional herbal treatment in developing countries for burns, soft tissue wounds and skin infection. Topical application of the unripe fruit papaya promoted desloughing, granulation and healing and reduced odor in chronic skin ulcers<sup>[6]</sup>. Topical treatment of mush pulp of *Carica papaya*, which contains papain and chymopapaine for pediatric infected burns appeared to be effective for desloughing necrotic tissue, preventing infection and providing a granulating wound. Possible mechanisms of action include the activity of proteolytic enzymes chymopapain and papaine, as well as an antimicrobial activity.

Extract from the leaves of *Carica papaya* have been shown to be beneficial for treatment of wounds. The fact that the extract produced antibacterial activities suggests that there may be a scientific basis for their utility in traditional medicine for the treatment of skin infections<sup>[3]</sup>. *C. papaya* has antibacterial effects that could be useful in treating chronic skin ulcers to promote healing<sup>[7]</sup>.

Table 1: Time required for wounds healing by *Carica papaya* leave extract rats

Animal groups	No of animals	Type of dressings	Healing time (days) (Mean ± S.E.M)
Group 1 (control)	6	Blank Vaseline	17.33 ± 0.67
Group 2	6	5% Vaseline	12.33 ± 0.31'
Group 3	6	10% Vaseline	12.33 ± 0.42'
Group 4	6	Solcoseryl-jelly	12.67 ± 0.49'

\* $p<0.05$  significant from control (Group 1)

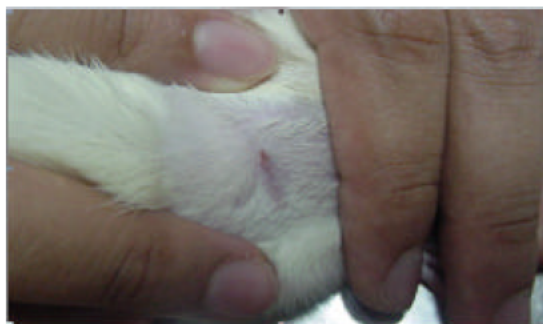

Fig. 2: Complete wound healing in 10% Vaseline treatment on day 12 after topical application

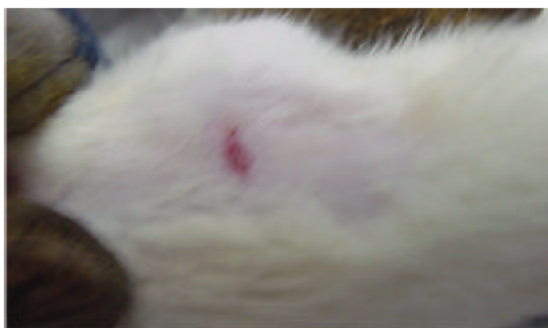

Fig. 3: Healing of wound treated with blank Vaseline on day 17 after topical application

The antioxidant properties of fermented papaya preparation are related to both hydroxyl scavenging as well as iron chelating properties. These antioxidant properties may be one of potential mechanism contributing to enhance wound healing<sup>[4]</sup>. Antioxidant activity of the *Carica papaya* decreases the risk of oxidative damage to tissues. Protection of cells against destruction by inflammatory mediators may be one of the ways in which the extracts from the plant, *Carica papaya* contribute to wound healing<sup>[8]</sup>. Osato *et al.*,<sup>[9]</sup> reported antibacterial and oxidant activities of unripe papaya and they correlate the bacteriostatic activity of papaya with its scavenging action on superoxide and hydroxyl radicals, which could be part of the cellular metabolism of such enteropathogens. This is indicative of the pathophysiological role of these reactive oxygen species in gastrointestinal diseases and papaya's ability to counteract the oxidative stress. In conclusion, aqueous extract of *Carica papaya* significantly accelerate wound healing compare to control and appeared to have several important properties that make it useful ideal as a dressing agent for wounds. Further studies are, however, required compare papaya to other accepted method of burn wound treatment and to define the précis role of papaya in burn wound management.

#### REFERENCE

1. Chen, C.F., S.M. Chen, S.Y. Chow and P.W. Han, 1981. Protective effects of *Carica papaya* Linn on the exogenous gastric ulcer in rats. *Amer. J. Chinese Medicine*. 9: 205-212.
2. Cho, C.H. and P.W. Han, 1984. Papain reduces gastric acid secretion induced by histamine and other secretagogues in anesthetized rats. *Proceedings of the National Science Council, Republic of China-Part B, Life Sciences*. 8:177-1781. 1984.
3. Emeruwa, A., 1982. Antibacterial substance from *Carica papaya* fruit extract. *J. Natural. Prod.*, 45:132-137.
4. Rimbach, G., Q. Guo, T. Akiyama, S. Matsugo, H. Moini, F. Virgili and L. Packer, 2000. Ferric nitrilotriacetate induced DNA and protein damage: Inhibitory effect of a fermented papaya preparation. *Anticancer Res.*, 20: 2907-2914.
5. Gupta, O.P., S. Sing, S. Bani, N. Sharma, S. Malhotra, B.D. Gupta, S.K. Banerjee and S.S. Handa, 2000. Anti-inflammatory and anti-arthritic activities of silymarin acting through inhibition of 5-lipoxygenase. *Phytomedicine*. 7: 21-24.
6. Udoh, P. and A. Kehinde, 1999. Studies on antifertility effect of pawpaw seeds (*Carica papaya*) on the gonads of male albino rats. *Phytotherapy Research*. 13: 226-228.
7. Eno, A.E., O.I. Owo, E.H. Itam and R.S. Konya, 2000. Blood pressure depression by the fruit juice of *Carica papaya* in renal and DOCA-induced hypertension in the rat. *Phytotherapy Res.*, 14: 235-239.
8. Hewitt, H., S. Whittle, S. Lopez, E. Bailey and S. Weaver, 2000. Topical use of papaya in chronic skin ulcer therapy in Jamaica. *West Indian Med. J.*, 49: 32-33.
9. Sripanidkulchai, B., V. Wonpanich, P. Laupattarakasem, J. Suwansakri and D. Jirakulsomchok, 2001. Diuretic effects of selected Thai indigenous medicinal plants in rats. *J. Ethnopharmacol.*, 75:185-190.
10. Klasen, H.J., 2000. A review on the nonoperative removal of necrotic tissue from burn wounds. *Burns*. 26:207-222.
11. Singhal, A. *et al.*, 2001. Options for nonsurgical debridement of necrotic wounds. *Adv. Skin. Wound Care.*, 14: 96-100.
12. Heinerman, J., 1988. Heinerman's encyclopedia of fruits, vegetables and herbs. Upper Saddle River (NJ): Prentice Hall.
13. Arvigo, R. and M.J. Balick, 1993. *Rainforest Remedies: One Hundred Healing Herbs of Belize*. Twin lakes (W1): Lotus Press.
14. Wimalawansa, S.J., 1982. Papaya in the treatment of chronic infected ulcers. *Ceylon Med. J.* 26: 129-132.
15. Morton, J.J.P. and M.H. Melone, Evaluation of vulnerary activity by an open wound procedure in rats. *Arch Inter Pharmacodyn*. 176: 117-126.
16. Starley, I.F., P. Mohammed, G. Schneider, and S.W. Bickler, 1999. The treatment of paediatric burns using topical papaya. *Burns*. 25: 636-639.

17. Dawkins, G., H. Hewitt, Y. Wint, P.C. Obiefuna and B. Wint, 2003. Antibacterial effects of carica papaya fruit on common wound organisms. *West Indian Med. J.*, 52: 290-292.
18. Mikhailchik, E.V., A.V. Ivanova, M.V. Anurov, S.M. Titkova, L. Penkov, Z.F. Yu. Khaevaeva and L.G. Korkina, 2004. Wound-healing effects of papaya-based preparation in experimental thermal trauma. *Bulletin of Experimental Biology and Medicine*. 137:560-562.
19. Osato, J.A., L.A. Santiago, G.M. Remo, M.S. Cuadra, and A. Mori, 1993. Antimicrobial and antioxidant activities of unripe papaya. *Life Sciences*, 53: 1383-1389.