

Gastroprotective Activity of *P. major* in Rats

Phipps, M.E. and A.A. Mahmood
Department of Molecular Medicine, Faculty of Medicine,
University of Malaya, 50603 Kuala Lumpur, Malaysia

Abstract: *P. major* is used in many parts of the world for the treatment of diseases and to promote the healing of wounds. In the present study, the aqueous leaf extracts was evaluation for their cytoprotective activity against ethanol-induced gastric ulcers in rats. Grossly, oral administration of absolute ethanol to rats pretreated with distilled water significantly produced extensive damage of gastric mucosa, whereas animals pretreated with aqueous plant extracts significantly reduced the formation of gastric lesions compared to control group. Histologically, pretreated rats with aqueous extract showed significantly marked inhibition of gastric mucosal damage, marked reduction of submucosal oedema compared to control group. These results strongly document the beneficial cytoprotective effects of plant extract against ethanol-induced gastric ulcer in rats.

Key words: Gastroprotection, ulcer, *P. major*, cimetidine

INTRODUCTION

P. major (Plantaginaceae) is an old medicinal plant that has been known for centuries. The traditional use of *P. major* in wound healing is quite old^[1]. Either whole or crushed leaves are used directly on burns, wasp, stings and wounds of all kinds to stop bleeding, keep the wound clean and to enhance the healing process^[2]. The leaves were prescribed for treatment of dog bites^[3]. The juice from the leaves was applied on the superficial wound to heal^[4]. A decoction of the leaves and roots of *P. major* is drunk to treat coughs, diabetes and to clean the blood^[5].

A range of biological activities has been found from plant extracts including wound healing activity^[6], promote maturation of abscess^[7], burns healing^[8], antiulcerogenic activity^[6], anti-inflammatory^[9], anti-cancer effect^[10], antioxidant activity^[11], antimicrobial activity^[12], antiviral activity^[13], immunosuppressant^[14], analgesic activity^[6], antihypertensive effect diuretic effect; anticomplementary activity^[15] hypoglycaemic effect^[16] and antiseptic properties^[17]. The fresh leaves of *P. major* were reported to contain β -carotene and ascorbic acid^[18]. The aim of the present study was to determine the gastro protective effects of *P. major* leave extract against ethanol-induced gastric ulcer in rats.

MATERIALS AND METHODS

Collection of plant materials: The plant was collected from Machang, Kelantan, Malaysia, and identified by

comparison with specimens available at the Herbarium of the Forest Research Institute, Kepong, Malaysia. Voucher specimens of the plant material are deposited at Department of Pharmacy, University of Malaya, Malaysia. The plant leaves were cut, wash with distilled water and dried in oven 50°C for 5-7 days until fully dried. The leaves were ground to a fine texture using a grinder and stored at 4°C.

Preparation of Plants Extracts: Weighing 50 g of plant powder and mixing it with 1000 mL of sterile distilled water in a conical flask using a ratio of 1:20. It was then heated and stirred on a hotplate for 3 h. After being left to cool, the residue was removed by filtration using a mesh and filter funnel. Rotatory evaporator then extracted the filtered material. Aqueous extract was then submitted to lyophilization by a freeze-dryer, to produce powdered forms of the extract. Plant extract were dissolved in distilled water in the concentration of 100 mg mL⁻¹ and 200 mg mL⁻¹, respectively.

Cimetidine: The reference antiulcer drug, cimetidine, was obtained from University Malaya Medical Centre (UMMC). Each tablet was 200 mg; the tablet was dissolved in distilled water in a concentration of 50 mg mL⁻¹ (250 mg kg⁻¹).

Experimental animals: *Sprague Dawley* adult male rats were obtained from the animal house, Faculty of Medicine, University of Malaya. The rats were divided

Corresponding Author: Phipps Department of Molecular Medicine, Faculty of Medicine, University of Malaya, 50603 Kuala Lumpur, Malaysia

randomly into 4 groups of 6 rats each. Each rat that weighted between 180-220 gm was housed separately (one rat per cage) in cages (Bollman cages) with wide-mesh wire bottoms to prevent coprophagy. The animals were left for 48 h to acclimatize to the animal room conditions, and were maintained on standard pellet diet and tap water.

Animal treatment: All rats were fasted for 48 h before the experiment but excess water were allowed, and just two hours before starting the experiment the water also were removed. Control animals (Group 1) each was administered 5 mL kg⁻¹ distilled water by orogastric intubations; whereas treated animals Group 2 and Group 3 each was administered 500 mg kg⁻¹ and 1000 mg kg⁻¹ aqueous extract of *P. Major* leaves (5 mL kg⁻¹) by same rout, respectively. Group 4 animals each was administered 250 mg kg⁻¹ cimetidine (5 mL kg⁻¹). Thirty minutes after their pretreatment, all animals were gavaged with absolute ethanol (5 mL kg⁻¹). They were sacrificed 30 min later by diethyl ether and their stomach rapidly removed and fixed in 10% buffered formalin.

Gross gastric lesions examination : Each stomach was opened along the greater curvature, rinsed in ice-cold PBS and fixed with 10% formalin and examined macroscopically for gastric damage. The length (mm) and the width (mm) of the ulcer on the gastric mucosa were measured by planimeter square (10 X 10 mm) under a dissecting microscope (20x). The ulcer area (UA) was calculated as described by Kauffman and Grossman^[19]. The total ulcer area (mm²) of each stomach was recorded and the % protection was calculated as follow:

% Protective = $\frac{UA_{control} - (UA_{treatment})}{UA_{control}} \times 100$

Histological examination : Stomach biopsies were processed and assessed for damage by taking a 5µm section, stained with Hematoxylin and Eosin and analyzed under light microscopy.

Statistical analysis of data: Results were expressed as mean±S.E.M The statistical difference between the groups in the term of the mean rate of wound healing was calculated by using Student's t-test

RESULTS AND DISCUSSION

Grossly, the results of the present study showed that pretreated rats with *P. major* leaf extracts or cimetidine significantly reduced the formation of gastric ulcer induced by absolute ethanol compared

to animals pre-treated with distilled water and administered absolute ethanol (Table 1, Fig. 1 and 2). Also animals pretreated with aqueous plant extract significantly reduced the gastric lesion compared to rats pretreated with cimetidine (Table 1). Histologically, rats pretreated with *P. major* leaf extracts or cimetidine significantly inhibited the gastric lesions formation, submucosal edema and leucocytes infiltration compared to control animals. Rats pre-treated with aqueous extract significantly protect gastric mucosa compared to animals pretreated with cimetidine (Table 1). There were no significant differences between the both concentrations of aqueous plant extract. The results of the present study clearly indicate that the oral administration of aqueous extract of *P. major* L. leaves had significant cytoprotective effects in rats.

Absolute ethanol method of inducing gastric lesions is rapid and convenient way of screening plant extracts for anti-ulcer potency and cytoprotection in macroscopically and microscopically visible lesions. Ethanol-induced gastric ulcer has been widely used for the experimental evaluation of anti-ulcer activity. Disturbances in gastric secretion, damage to gastric mucosa, alterations in permeability, gastric mucus depletion and free-radical production are reported to be the pathogenic effects of ethanol^[20]. Ethanol-induced gastric lesion formation may be due to stasis in gastric blood flow, which contributes to the development of the hemorrhagic and necrotic aspect of tissue injury^[21].

Several polysaccharides from *P. major* have effects on the human immune system. Biologically active polysaccharides might at least partly explain the cytoprotective effect of *P. major* L.^[2]. Aqueous extract of *P. major* was reported to posse's significant antioxidant activity^[22].

Plantamajoside is the main caffeic acid derivative in *P. major* L. Plantamajoside was reported to posse's significant antioxidant activity^[22]. Several flavonoids, luteolin 7- glucoside, baicalein and plantagin, have been isolated from *P. major*. Skari *et al.*,^[23] are antioxidants^[24] and also known to have free radical scavenging activity and inhibit lipid peroxidation^[25]. It is likely that the antioxidant property of the *P. major* could be linked to its gastroprotective effect^[26]. It could be conceived that *P. major* aqueous leaf extract exert their anti-ulcer activity through the flavonoids since flavonoids are reported to protect the mucosa by preventing the formation of lesions by various necrotic agents^[25]. Numerous flavonoids have been shown antiulcer properties in different experimental models^[27]. These results suggest that *P. major* leaf extract could be beneficial component of preventing ulcer formation induced by ethanol. In conclusion, the anti-ulcer effects of aqueous extract of *P. major* appeared

Table 1: Effects of *P. major* L. leaf extracts on ethanol-induced gastric lesions in rats

| Groups | Pre-treatment | Oral dosage mL kg ⁻¹ | Ulcer area (mm ²) (Mean + S.E. M) | Protection % |
|--------|--|------------------------------------|--|-----------------|
| 1 | Distilled water (control) | 5 mL kg ⁻¹ | 1025.00+25.38 | - |
| 2 | <i>P. major</i> 500 mg kg ⁻¹ | 5 mL kg ⁻¹ | 231.33+8.13* | 77.46% |
| 3 | <i>P. major</i> 1000 mg kg ⁻¹ | 5 mL kg ⁻¹ | 186.00+8.28* | 81.85% |
| 4 | Cimetidine 250 mg kg ⁻¹ | 5 mL kg ⁻¹ | 395.00+9.62** | 61.46% |

*P<0.05 significantly from control (Group 1), **P<0.05 significantly from control (Group 1), Group 2 and Group 3

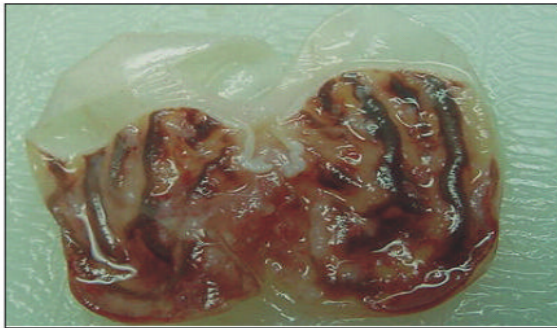


Fig. 1: Sever macroscopic necrosis of gastric mucosa. Gastric mucosal damage caused by absolute ethanol. Absolute ethanol produced extensive visible hemorrhagic necrosis of gastric mucosa in control group.

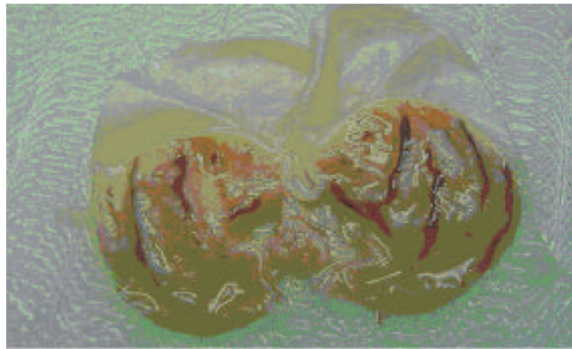


Fig. 2: Moderate macroscopic necrosis of gastric mucosa. Cytoprotection of aqueous extract 500 mg kg⁻¹ against absolute ethanol. Aqueous extract reduce the formation of gastric lesions induced by absolute ethanol.

to have several important properties that make it useful ideal as a remedy for antiulcer. We can suggest that it may be possible to use plant leaf extract as remedy to prevent ulcers. However, further investigations are required to elucidate their exact mechanism (s) of anti-ulcer activity.

In conclusion, this study reveals that the aqueous extract of *P. major* leaves is the most potent inhibitor of gastric mucosal lesions caused by absolute ethanol.

ACKNOWLEDGEMENTS

This study was financially supported by the University of Malaya through the grand 06-02-03-1026 (Oracle 8361026).

REFERENCES

- Nielsen, H., 1969. Laegeplanter og trolddomsurter. In: Kehler, S. (Ed.) Politikens Forlag, Kobenhavn. pp: 321-324.
- Samuelsen, A.B., B.S. Paulsen, J.K. Wold, S.H. Knutsen and H. Yamada, 1998. Characterization of a biologically active arabinogalactan from the leaves of *P. major* L. Carbohydrate Polymers. 35: 145-153.
- Roca-Garcia, H., 1972. Weeds: a link with the past. Arnoldia. 30: 23-24.
- Brondegaard, V.J. Folk og Flora, 1987. Rosenkilde and Bagger, Kobenhavn, pp: 68-77.
- Ong, H.C. and M. Nordiana, 1999. Malay ethno-medicobotany in Machang, Kelantan, Malaysia. Fitoterapia. 70: 502-513.
- Samuelsen, A.B., 2000. The traditional uses, chemical constituents and biological activities of *P. major* L. A Review. J. Ethnopharmacol., 71: 1-21.
- Yesilada, E., G. Honda and E. Sezik, 1995. Traditional medicine in Turkey. V. Folk medicine in the inner Taurus Mountains. J. Ethnopharmacol., 46: 133-152.
- Jain, S.K., 1991. Dictionary of Indian Folk Medicine and Ethnobotany. Deep Publications, New Delhi, pp: 145.
- Murai, M., Y. Tamayama, S. Nishibe, 1995. Phenylethanoids in the herb of *P. lanceolata* and inhibitory effect on arachidonic acid-induced mouse ear oedema. Planta Medica., 61: 479-480.
- Galvez, M., C. Martin-Cordero, M. Lopez-Lazaro, F. Cortes and M.J. Ayuso, 2003. Cytotoxic effect of *P. species* on cancer cell lines. J. Ethnopharmacol., 88: 125-130.

11. Galvez, M., C. Martin-Cordero, P.J. Houghton and M.J. Ayuso, 2005. Antioxidant activity of methanol extracts obtained from *Plantago sp.*. J. Agric. Food Chem., 53: 1927-1933.
12. Holetz, F.B., G.L. Pessini, N.R. Sanches, D.A. Cortez, C.V. Nakamura and B.P. Filho, 2002. Screening of some plants used in Brazilian folk medicine for the treatment of infectious diseases. Memorias do Instituto Oswaldo Cruz. 97: 1027-1031.
13. Chang, I.M., 1997. Antiviral activity of aucubin against hepatitis B virus replication. Phytotherapy Research. 11: 189-192.
14. Sasaki, H., H. Nishimura and T. Morota, 1989. Immunosuppressive principles of *Rehmannia glutinosa* var. *hueichingensis*. Planta Medica., 55: 458-462.
15. Samuelsen, A.B., B.S. Paulsen, J.K. Wold, H. Otsuka, H. Yamada and T. Espevik, 1995. Isolation and partial characterization of a biologically active polysaccharides from *P. major*. L. Phytotherapy Research. 9: 211-218.
16. Houghton, P.J. and J. Manby, 1985. Medicinal plants of the Mapuche. J. Ethnopharmacol., 13: 89-103.
17. Rivera, D. and C. Obon, 1995. The ethnopharmacology of Madeira and Porto Santo Islands, A Review. J. Ethnopharmacol. 46: 73-93.
18. Zennie, T.M. and C.D. Ogzewalla, 1977. Ascorbic acid and vitamin A content of edible wild plants of Ohio and Kentucky. Economic Botany. 31: 76-79.
19. Kauffman, G.L. and M.I. Grossma. 1978. Prostaglandin and cimetidine inhibit the formation of ulcers produced by parenteral salicylates. Gastroenterology. 75: 1099-1102.
20. Salim, A.S., 1990. Removing oxygen-derived free radicals stimulates healing of ethanol induced erosive gastritis in rats. Digestion. 47:24-28.
21. Guth, P.H., G. Paulsen and H. Nagata, 1984. Histologic and microcirculatory changes in alcohol-induced gastric lesions in the rat effect of prostaglandin cytoprotection. Gastroenterology. 87:1083-1090.
22. Miyase, T., M. Ishino, C. Ahahori, A. Ueno, Y. Ohkawa and H. Tanizawa, 1991. Phenylethanoid glycosides from *P. asiatica*. Phytochemistry. 30: 2015-2018.
23. Skari, K.P., K.E. Malterud and T. Haugli, 1999. Radical scavengers and inhibitors of enzymatic lipid peroxidation from *P. major*, a medicinal plant. Poster 495 at 2000 Years of Natural Products Research Past, Present and Future, Amsterdam, The Netherlands.
24. Bohm, H., H. Boeing, J. Hempel, B. Raab and A. Kroke, 1998. Flavonoids, flavones and anthocyanins as native antioxidants of food and their possible role in the prevention of chronic disease. Zeitschrift für Ernährungswissenschaft. 37: 147-163.
25. Gao, Z.H., K.X. Huang, X.L. Yang and H.B. 1999. Xu, Free radical scavenging and antioxidant activities of flavonoids extracted from the radix of *Scutellaria baicalensis* Georgei, Biochemia et Biophysica Acta- General Subjects. 1472: 643-650.
26. Ligumsky, M., M. Sestieri, E. Okon and I. Ginsburg, 1995. Antioxidants inhibit ethanol-induced gastric injury in the rat. Role of manganese, glycine and carotene. Scandinavian J. Gastroenterol. 30: 854-860.
27. Motilva, V., C. Alarcon de la Lastra, Martin M.J. Calero and J. Torreblanca, 1992. Effects of naringenin and quercetin on experimental chronic gastric ulcer in rat. Studies on the histological findings. Phytother. Res., 6: 168-170.