

Transverse Colon Perforation in Enteric Fever

¹D.E. Anushtup, ¹M.S. Prabal Roy, ²Shabnam Bashir,
²Rakesh Kaundal and ²Namit Kalra

¹Asian Institute of Medical Sciences, Faridabad, India

²Department of General and Minimally Invasive Surgery,
Fortis Escorts Hospital and Research Centre, 121001, Faridabad, India

Abstract: Typhoid intestinal perforation is an important cause of morbidity and mortality in many developing countries. Most of the perforations occur in the terminal ileum. However, rarely colonic perforations has also been reported to occur in which solitary caecal perforations is reported to be most common. The rare case of transverse colon perforation in enteric fever in a 10 year old child was observed. She was managed by exploratory Laparotomy and simple closure of perforation with thorough peritoneal lavage. Post operatively she developed left sided pneumonia and was managed conservatively. She was discharged on 14th postoperative day. To conclude, the possibility of colonic perforation should be kept in mind in patients of enteric perforation peritonitis before the diagnosis of sealed perforation is made.

Key words: Intestinal perforation, transverse colon, typhoid fever, discharge, morbidity, Faridabad

INTRODUCTION

Typhoid enteritis continues to be a significant cause of morbidity and mortality in children worldwide especially in developing countries (Sy *et al.*, 2001; Kouame *et al.*, 2004). It is a severe febrile illness caused by *Salmonella typhi* and occasionally *Salmonella paratyphi* and acquired by the faeco-oral route. The typical findings of typhoid fever include rose spots, relative bradycardia and stepwise fevers but unfortunately these signs are frequently absent. Gastrointestinal manifestations may include diffuse abdominal pain, perforation, cholecystitis and cholangitis.

The most serious surgical complication of enteric typhoid enteritis is typhoid intestinal perforation (Noorani *et al.*, 1997). The incidence in children varies with age, the highest frequency having been reported in 10-12 year olds (Onen *et al.*, 2002).

Terminal ileum is the commonest site of perforation (Chang *et al.*, 2006). However, reports illustrating colonic perforation with small bowel sparing in childhood has been few and sporadic (Sy *et al.*, 2001; Chang *et al.*, 2006). A case of transverse colon perforation in a 10 years old girl caused by typhoid fever is reported.

Case report: A 10 year old girl was admitted in the department with history of fever for 6-7 days, abdominal distension and inability to pass feces and flatus for 1 day. She was having multiple episodes of vomiting for 1 day.

On examination the general condition was poor, pulse 110 min⁻¹ and respiratory rate 26 min⁻¹. Abdominal distension was present with generalized guarding, rigidity over whole of abdomen. Rebound tenderness was also noted. Bowel sounds were absent. Erect Abdominal X-ray showed gas under diaphragm (Fig. 1). Abdominal ultrasonography showed free fluid in abdomen. Widal's test showed *S. paratyphi* BH Antigen <1:80 titre, *S. paratyphi* AH Antigen <1:80 titre. Hemogram showed normal Total count, Neutrophils 65% and Lymphocytes 30%. Her random blood sugar was found to be persistently high (264 mg dL⁻¹) on admission. Pediatrician consultation was sought, hourly sugar charting with intravenous HIR insulin was started. She was resuscitated with intravenous fluids and nasogastric suction and started on intravenous antibiotics (Inj ceftriaxone, Metrogyl and Amikacin). A provisional diagnosis of Enteric perforation peritonitis was made. Exploratory Laparotomy was done about 4 h after admission (05/01/2010). On exploration minimal contamination of peritoneal cavity with flakes over oedematous small bowel was seen. Initially the small bowel was inspected for perforation site but surprisingly no site could be found. Thereafter, the colon was searched starting from the ascending colon and we detected a <1 cm perforation in the mid transverse colon (Fig. 2). The edge of the perforation was freshened and primary repair of the perforation was done. The whole of small bowel and colon was again thoroughly inspected for any other site of

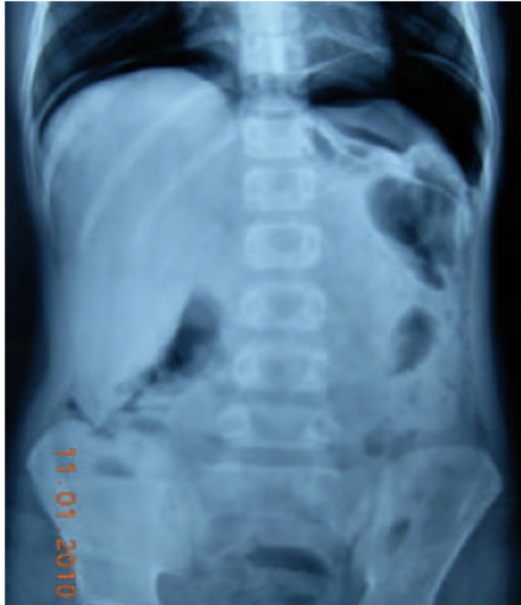

Fig. 1: X-ray abdomen shows Gas under Diaphragm

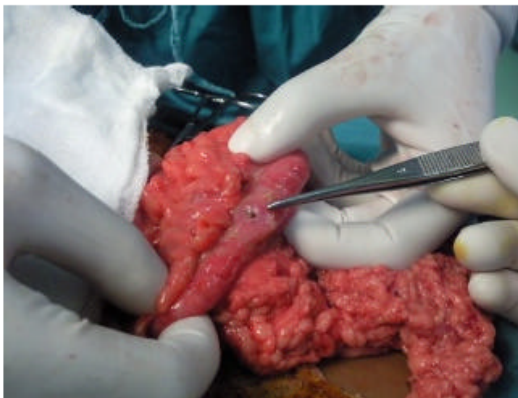


Fig. 2: Perforation in the mid transverse colon

perforation but none was detected. The patient was started orally on the 3rd post operative day as her bowel activity returned and intra abdominal drain was removed. The Blood culture sample sent on the day of surgery showed *Salmonella typhi* after 48 h incubation. However the patient continued to have persistent fever and developed left sided chest pain with dyspnoea on 4th post operative day.

Chest X-ray showed left side opacification with consolidation/collapse. Ultrasound Chest showed no effusion. Chest physician consultation was done and paediatrician reviewed. Bronchoscopy done and mucus plug removed. Intravenous antibiotic Ceftriaxone and Amikacin was stopped and Inj Imipenem (500 mg thrice

daily) was started on 5th postoperative day. Patients clinical condition and chest X-ray improved within 24 h. Blood cultures were sent but showed no growth after 48 h incubation. Fever subsided for 2 days but again recurred.

Ultrasound whole abdomen showed no collection. Chest X-ray showed clear lung fields. Inj Imipenem was stopped and started on Inj Cefepime 1.5 g twice daily on 11th post operative day as patient continued to have fever. Patient improved in 2 days of starting cefepime and became afebrile. Patient was discharged on the 14th post operative day.

Histopathology taken from the perforation site showed marked acute inflammation with focal necrosis with presence of bacterial colonies. On follow up after 2 weeks, patient is stable and afebrile and improved general condition.

DISCUSSION

Typhoid fever is endemic in India. A study conducted in an urban slum area showed that 1% of children up to 17 years old suffered from typhoid fever every year (Park, 2002). It is diagnosed clinicopathologically. A positive Widal's test is suggestive of Typhoid fever but a negative test does not rule it out.

However, bacterial isolation by culture from blood, stool or urine is confirmatory. It is also important to note that in cases of perforation, laboratory confirmation of clinical diagnosis by bacterial isolation is difficult due to prior treatment with antibiotics. In these patients Widal's test is more useful. In the hospital it takes 3 days to finish the analysis after blood is drawn therefore, the results of the Widal test are usually useless for preoperative diagnosis in cases of perforation peritonitis. They can only be helpful for final diagnosis.

Terminal ileum is the commonest site of perforation (Chang *et al.*, 2006). Histologically typhoid perforation is chronic but discrete inflammation around the perforation site with relatively mild to moderate mucosal changes. (Nguyen *et al.*, 2004). This finding was consistent with the study.

Although, Ileum is the commonest site of perforation, there has been few reports of colonic typhoid perforation. Caecum is reported to be the commonest site of colonic perforation in children (Chang *et al.*, 2006). Chang *et al.* (2006) reviewed the surgical options in the management of Colonic perforation in enteric fever in Childhood. In the study including 24 patients over a 10 year period, the surgical options included primary closure of the perforation with ileostomy (70.8%), wedge resection and

simple closure (20.8%) and partial colectomy with colostomy (4.2%). They performed wedge resection with primary closure in 5 patients while 6 underwent simple closure with ileostomy in patients with solitary caecal perforation. Clinical condition and preoperative symptoms were similar in both groups. However there was no incidence of wound dehiscence or intestinal leaks in patients undergoing simple closure without ileostomy. Consequently, any readmission for secondary operation to restore intestinal continuity in these patients was avoided. But it is to be noted that of 24 patients, 17 of them underwent routine ileostomy with simple closure of perforation with debridement. Significant factors contributing to mortality and morbidity are prolonged duration of perforation and operation time along with severe peritonitis (Kim *et al.*, 1975; Onen *et al.*, 2002).

This is aggravated by the lack of primary health care in developing countries causing delay in diagnosis, atypical presentation of typhoid fever and emergence of multi-drug resistant strains of *Salmonella typhi* (Ahmed *et al.*, 2006). Fluoroquinolones were widely regarded as the most effective drug for the treatment of typhoid fever (Parry *et al.*, 2002). But gradually some strains of *S. typhi* have shown reduced susceptibility to fluoroquinolones (Dutta *et al.*, 2001; Gupta *et al.*, 2001). With the development of Fluoroquinolone resistance, third generation cephalosporins such as ceftriaxone and cefotaxime were used in treatment but sporadic reports of resistance to these antibiotics also followed (Saha *et al.*, 1999). Imipenem and Azeotreonam are potential second line antibiotics for severe life threatening infections. Currently, the incidence of Multi drug resistant *S. typhi* varies from 25-55% in India (Gautam *et al.*, 2002).

The resistance to third generation cephalosporins in India ranges from 0-11% (Gautam *et al.*, 2002; Capoor *et al.*, 2006) in their study on *in vitro* activity of ciprofloxacin resistant *Salmonella typhi* showed 2% of the isolated were resistant to cefotaxime and 1% to cefepime on agar dilution Minimum Inhibitory Concentration (MIC) testing.

In their study, 2 strains of *S. typhi* were resistant to cefotaxime (MIC = 64,128 $\mu\text{g mL}^{-1}$, respectively) and a single strain of *S. typhi* was resistant to cefepime (64 $\mu\text{g mL}^{-1}$). However, although more studies on 4th generation cephalosporins activity in typhoid fever is still awaited, it may be a potential alternative in multi drug resistant *Salmonella typhi*.

CONCLUSION

To understand thoroughly the clinical course of typhoid fever is important. The possibility of colonic

perforation should be kept in mind during exploratory laparotomy in patients in whom no perforation is detected in small bowel.

In cases of small perforation with minimal contamination to peritoneal cavity, primary repair without a stoma may save the patient from a second procedure to restore intestinal continuity.

REFERENCES

- Ahmed, H.N., M.P. Niaz, M.A. Amin, M.H. Khan and A.B. Parhar, 2006. Typhoid perforation still a common problem: Situation in Pakistan in comparison to other countries of low human development. *J. Pak. Med. Assoc.*, 56: 230-232.
- Capoor, M.R., D. Nair, A.S. Hasan, P. Aggarwal and B. Gupta, 2006. Narrowing therapeutic options in typhoid fever, India. *Southeast Asian J. Trop. Med. Public Health*, 37: 1170-1174.
- Chang, Y.T., J.Y. Lin and Y.S. Huang, 2006. Typhoid colonic perforation in childhood: A ten-year experience *World J. Surg.*, 30: 242-247.
- Dutta, P., U. Mitra, S. Dutta, A. De, M.K. Chatterjee and S.K. Bhattacharya, 2001. Ceftriaxone therapy is ciprofloxacin treatment failure typhoid fever in children. *Indian J. Med. Res.*, 113: 210-213.
- Gautam, V., N.K. Gupta, U. Chaudhary and D.R. Arora, 2002. Sensitivity pattern of *Salmonella* serotypes in northern India. *Braz. J. Infect. Dis.*, 6: 1-9.
- Gupta, A., N.K. Swarnkar and S.P. Choudhary, 2001. Changing antibiotic sensitivity in enteric fever. *J. Trop. Pediatr.*, 47: 369-371.
- Kim, J.P., S.K. Oh and F. Jarrett, 1975. Management of ileal perforation due to typhoid fever. *Ann. Surg.*, 181: 88-91.
- Kouame, J., L. Kouadio and H.T. Turquin, 2004. Typhoid ileal perforation: Surgical experience of 64 cases. *Acta Chir. Belg.*, 104: 445-447.
- Nguyen, Q.C., P. Everest, T.K. Tran, D. House and S. Murch *et al.*, 2004. A clinical, microbiological and pathological study of intestinal perforation associated with typhoid fever. *Clin. Infect. Dis.*, 39: 61-67.
- Noorani, M.A., I. Sial and V. Mal, 1997. Typhoid perforation of small bowel: A study of 72 cases. *J. R. Coll. Surg. Edinb.*, 42: 272-276.
- Onen, A., A.I. Dokucu, M.K. Cigadem, H. Ozturk, S. Otcu and S. Yucesan, 2002. Factors effecting morbidity in typhoid intestinal perforation in children. *Pediatr. Surg. Int.*, 18: 696-700.

- Park, K., 2002. Epidemiology of Communicable Diseases: Typhoid Fever. In: Park's Text Book of Preventive and Social Medicine. Park, K. (Ed.). 15th Edn., Jabalpur Banarasi Das Bhaot, Jabalpur, pp: 178-181.
- Parry, C.M., T.T. Hien, G. Dougan, N.J. White and J.J. Farrar, 2002. Typhoid fever. *New Engl. J. Med.*, 347: 1770-1782.
- Saha, S.K., S.Y. Talukder, M. Islam and S. Saha, 1999. A highly Ceftriaxone resistant *Salmonella typhi* in Bangladesh. *Pediatr. Infect. Dis. J.*, 18: 387-387.
- Sy, E.D., C.S. Liu, S.M. Huang and Y.S. Shan, 2001. Cecal perforation presenting as abdominal-wall necrotizing fasciitis. *Pediatr. Surg. Int.*, 17: 215-217.