

Noninvasive Molecular Imaging of Apoptosis in Central Nervous System by Magnetic Resonance Imaging: Emerging to Clinical Practice

¹Abdolmajid Taheri, ²Daryoush Fatehi, ³Mohsen Mohammadi and ⁴Ayoob Rostamzadeh

¹Department of Radiology, Faculty of Medicine,

Shahrekord University of Medical Sciences, Shahrekord, Iran

²Department of Medical Physics, Shahrekord University of Medical Sciences,
Shahrekord, Iran

³Department of Pharmaceutical Biotechnology, Faculty of Pharmacy,
Loreastan University of Medical Sciences, Khorramabad, Iran

⁴Department of Anatomy and Neuroscience, Faculty of Medical Sciences,
Shahrekord University of Medical Sciences, Shahrekord, Iran

Abstract: Apoptosis involves a particular type of cell death that plays an important role in tissue turnover and homeostatic regulation. Remove unwanted cells in multicellular organisms and unicellular organized by this process. Cell apoptosis begins with the production and release of various factors. The effects of apoptosis depend on the environment in which is occur programmed cell death. Apoptosis in some cells also causes release of various factors such as cytokines and subsequently mediated activation of other protein mediators of immune and inflammatory response. Today, using genes, inducer metabolites and inhibitors involved in of apoptosis, or programmed cell death, can be immune system (the balance between cellular and humoral immune) is directed towards the desired immune response. There are different methods for detection of apoptotic cells and each of these methods alone cannot be used as the criterion of apoptosis. The activation of caspases also is a marker for cellular damage in diseases. Caspases as an indicator is specific apoptosis therefore determine the activation of caspase can be used to differentiate between necrosis and apoptosis. Molecular imaging is ideally suited to measuring early response by quantifying cellular metabolism, proliferation and apoptosis, activities altered early in treatment. There are now several possible Magnetic Resonance Imaging (MRI) based approaches for detecting apoptosis, in particular tumor apoptosis, which have the potential to be translated into clinical application. Detection of cellular lipid droplet accumulation, using localized Magnetic Resonance Spectroscopy (MRS) and changes in tissue architecture using Diffusion-Weighted Imaging (DWI) has the virtues that they are completely non-invasive and thus could be implemented in the clinical practice now. Potential disadvantages include a lack of specificity for apoptosis and the possibility that they may be limited in detecting relatively low but clinically relevant, levels of cell death. Finally using labeled molecular factors and inducer proteins and also measurement of metabolites by non-invasive medical imaging techniques such as magnetic resonance spectroscopy can be identified the actual mechanisms and pathways of apoptosis as well by manipulated these pathways may be effective in the prevention of diseases such as autoimmune and neurodegenerative disorders.

Key words: Apoptosis, caspase, magnetic resonance spectroscopy, diffusion-weighted imaging, molecular imaging

INTRODUCTION

Apoptosis was originally defined as a distinct mode of cell death on the basis of a series of characteristic ultrastructural features according a sequence of events starting from nuclear and cytoplasmic condensation and leading to cell fragmentation and phagocytosis. Initially

Kerr and coauthors used the term “shrinkage necrosis” to describe this form of cell death (Hale *et al.*, 1996). Subsequently they coined the word “apoptosis” (from the Greek = falling of the leaves), which indicates the dropping of leaves from trees or petals from flowers, to emphasize the occurrence in normal tissue turnover (Hale *et al.*, 1996, Kinloch *et al.*, 1999). Apoptosis is an

essential part of normal fetal development, growth of juveniles and control of cell numbers in adults where it exactly balances cell division. Apoptosis also occurs in a number of pathological conditions (Kinloch *et al.*, 1999, Evan and Vousden, 2001). This process has characteristic microscopic features and is a highly controlled and ordered mechanism that removes cells in a way that causes minimal disruption to the surrounding tissue. Apoptosis is brought about by different mechanisms than those causing necrosis, a mode of cell and tissue death that occurs only in pathological conditions (Hale *et al.*; 1996; Blankenberg *et al.*, 2000). A well-known example of necrosis is myocardial infarction, where heart muscle dies from lack of oxygen due to blockage of a coronary artery. Apoptosis is an active process requiring the expenditure of energy, while necrosis is characterized by the inability of cells to produce the energy (ATP) required maintaining homeostasis (Hale *et al.*, 1996; Evan and Vousden, 2001). When apoptosis occurs during development of the embryo or fetus it is often referred to as programmed cell death. Control of apoptosis is very finely balanced and a wide variety of triggers may initiate the process. The signal for apoptosis may be the binding of an external signal molecule to a membrane receptor (the “death receptor” known as Fas), or may arise from intracellular signals such as DNA damage, leading to the release of the enzyme cytochrome c from the mitochondria into the cytoplasm (Blankenberg *et al.*, 2000; Broughton *et al.*, 2009; Niizuma *et al.*, 2010). Within the cell many regulatory proteins control apoptosis including members of the bcl-2 and Inhibitors of Apoptosis (IAP) families (Evan and Vousden, 2001; Broughton *et al.*, 2009). Apoptosis is accompanied by a specific pattern of DNA damage that leads to the formation of low molecular weight DNA oligomers. These can be visualized after DNA extraction and electrophoresis in tissue extracts, or directly in tissue sections by the use of the TUNEL technique. Although a variety of extrinsic and intrinsic triggers may initiate apoptosis, at the molecular level the final common pathway is the activation of the caspase cascade. Caspases are a set of enzymes found in inactive form in all cells (Hale *et al.*, 1996; Blankenberg *et al.*, 2000; Vila and Perier, 2008). When the first in the series is activated, by cleaving off a short protein sequence, it is then able to activate the next enzyme in the series and so on. Because each enzyme is able to activate many copies of the next enzyme, the reaction is greatly amplified. This enzyme cascade mechanism is also seen in other situations requiring a rapid but controlled response, such as the blood clotting mechanism (the coagulation cascade) and the complement cascade (Broughton *et al.*,

2009; Niizuma *et al.*, 2010) (Fig. 1). At the same time, the cell shrinks away from its neighbors with loss of cell-cell contacts and increasing eosinophilia (pink staining) of the cytoplasm. The cytoplasmic organelles are still preserved at this stage. As the process continues, the nuclear material breaks into fragments (karyorrhexis) (Hale *et al.*, 1996; Blankenberg *et al.*, 2000; Niizuma *et al.*, 2010). This is accompanied by dissolution of the nuclear membrane. Cytoplasmic blebs B break away from the cell surface and eventually the entire cell breaks up (karyolysis) (d) to form membrane-bound fragments. Some of the cell fragments contain nuclear material and are known as apoptotic bodies A. These apoptotic bodies may be phagocytosed by tissue macrophages M, scavenger cells derived from the bone marrow and found in virtually every tissue in the body, or by their neighboring cells. In the rest of the organism, apoptosis is essential for organogenesis, sculpts digits and extremities and plays a role in determining polarity of structures by contributing to directional growth of cell populations (Hale *et al.*, 1996; Niizuma *et al.*, 2010; Vila and Perier, 2008).

Cell death in neural system: Thus, the first descriptions of cell death in neurons date back to the 1880s when Beard described the loss of a specific population of sensory neurons in fish and skate. These cells that are today referred to as Rohon-Beard neurons are specialized mechanoreceptors occurring during embryonic development in the dorsal spinal cord in fish and amphibians (Kinloch *et al.*, 1999; Niizuma *et al.*, 2010). A demonstration of neuron cell death in birds was given a few years later by Collin who, in 1906, reported the occurrence of Dorsal Root Ganglion (DRG) and motor neuron cell death during embryonic development of chicks (Kinloch *et al.*, 1999; Morrison *et al.*, 2003). Then, in 1926, Ernst was the first to recognize that an overproduction of neurons was followed by death of a substantial fraction in the retina, the trigeminal, facial and DRGs and in the anterior horn of the spinal cord. He was also the first to propose a general theory of neuron death during normal development of the nervous system, to obtain supporting evidence and to describe the existence of three main types of cell death during normal development: the first occurring during the regression of vestigial organs; the second during morphological modifications of organ anlagen; the third during tissue remodeling (Blankenberg *et al.*, 2000; Morrison *et al.*, 2003; Springer, 2002). A strong refractoriness to the idea of an intervention of cell death during development was, in fact, still present in textbooks of the 1930s dealing with the interpretation of one of the most widely used experimental paradigms to investigate the development of the nervous system, i.e., the removal or grafting of limbs

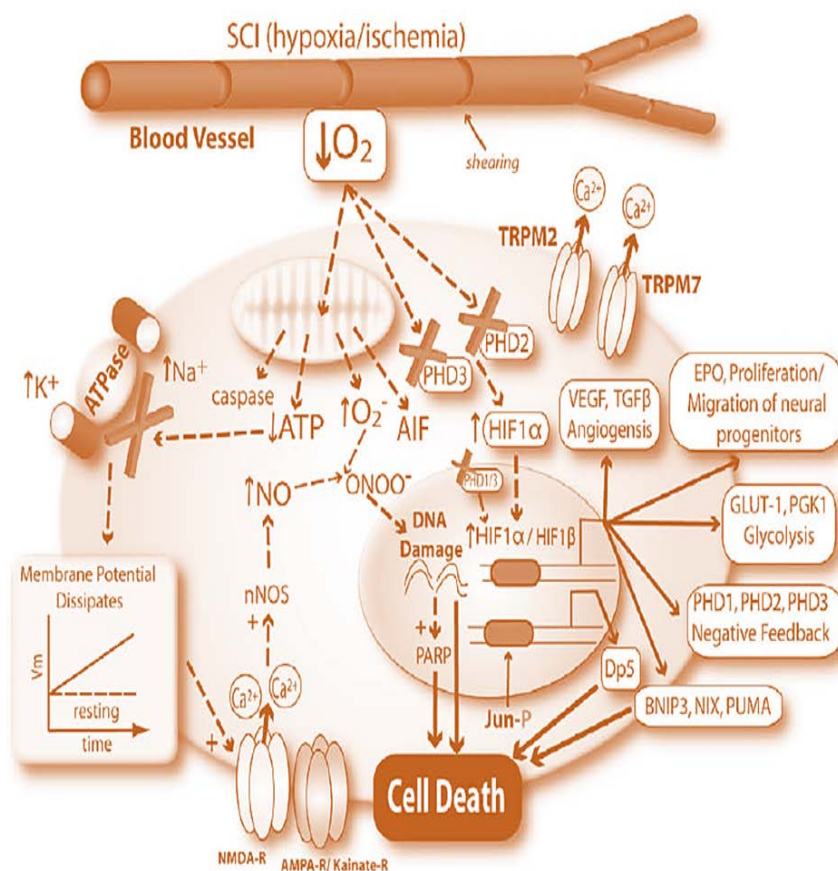


Fig. 1: Intrinsic and extrinsic pathways of apoptosis after spinal cord injury

to alter peripheral sensory and motor fields (Evan and Vousden, 2001; Morrison *et al.*, 2003). These experiments were shown to result in hypoplasia or hyperplasia, respectively and those results were consistently interpreted as consequences of altered proliferation of the nerve cells. After some studies, the concept that Programmed Cell Death (PCD) already expanded in abstract was occurring in the nervous system at different stages of development and growth independently of external insults started rapidly catching on (Martin, 2001; Springer, 2002). Thus PCD was recognized as a highly phylogenetically conserved general mechanism by which eukaryotic cells die following a stereotyped series of molecular and cellular events in nervous tissues (Morrison *et al.*, 2003; Springer, 2002).

Molecular mechanism of apoptosis in neural system:

Today, the concept that developmental cell death occurs during the course of central and peripheral nervous system maturation is fully established. In parallel, evidence is accumulating to indicate a major role of PCD during physiological aging and in neurodegenerative diseases. After PCD came to be recognized as a

widespread phenomenon in development, an ultrastructural study on several embryonic tissues proposed that there were three main types of cell death during normal development, on the basis of the role of lysosomes in cell disruption (Evan and Vousden, 2001; Vila and Perier, 2008; Morrison *et al.*, 2003). The different morphological types of cell death that have been so far described in neurons are associated with a series of cellular biochemical changes that display a certain degree of specificity. Therefore, it follows that it is theoretically possible to distinguish between each different type by the localization of specific components of the respective intracellular machineries (Vila and Perier, 2008; Martin, 2001). However, it must be remembered that PCD is a highly dynamic process and very often a cross-talk between different types of PCD is likely to occur, under either normal or pathological conditions, so that a combination of different approaches is always necessary to obtain an unequivocal proof of a given type of cell death taking place in specific neuronal populations and/or experimental contexts (Martin, 2001; Springer, 2002). A detailed description of the intracellular pathways specifically associated with any of the possible modalities of PCD in neurons is beyond the purpose of this

introductory chapter. Below, the most relevant features of each of the types of cell death described in the previous section will be briefly considered to set the ground for better understanding the arrays of technical approaches available to the study of PCD in neurons (Morrison *et al.*, 2003; Springer, 2002). The current view indicates that there are two main apoptotic pathways in neurons: the extrinsic or death receptor pathway and the intrinsic or mitochondrial pathway. However, it is now clear that these two pathways are intimately linked and that molecules in the death receptor pathway can influence the mitochondrial pathway and vice versa (Evan and Vousden, 2001; Springer, 2002). Both pathways then converge on the same execution (or terminal pathway) that is initiated by the cleavage of caspase-3 and eventually results in DNA fragmentation, degradation of cytoskeletal and nuclear proteins, cross-linking of proteins, formation of apoptotic bodies, expression of ligands for phagocytic cell receptors and, finally, uptake by phagocytic cells (Evan and Vousden, 2001; Broughton *et al.*, 2009; Martin, 2001). Generally, in organisms, two distinctly different cell death mechanisms can be observed. First, an uncontrolled necrotic cell death mechanism, which includes cell swelling and loss of cell energy and cell membrane integrity in the very early phases of the death process and secondly, apoptosis (or programmed cell death) which manifests with DNA fragmentation, nuclear condensation, cell shrinkage and the formation of membrane-encapsulated apoptotic bodies (Evan and Vousden, 2001; Morrison *et al.*, 2003). The intention of this article is to review non-invasive imaging strategies which have been used in histological and biochemical levels. Rather than focusing on an imaging method, or apoptosis mechanism, we describe and discuss the current status and possible future developments of imaging methods and technologies in apoptosis (Kinloch *et al.*, 1999; Niizuma *et al.*, 2010). Although at tissue level, apoptosis generally appears as a subtle process, the individual cells experience profound changes in morphology, structure and biochemistry brought forth by the activation of distinct proteases and lipases. It is exactly through these changes and the careful temporal orchestration of cell events that we are being provided with a wide array of markers and targets for visualizing apoptosis by modern imaging technologies (Martin, 2001; Hakumäki and Brindle, 2003; Laxman *et al.*, 2002). Image processing can be used in interpreting, this technique is different application in medicine and safety and health (Karchani *et al.*, 2015).

MATERIALS AND METHODS

Traditional assay methods: Apoptosis can be imaged using very different imaging modalities. The methods can

be divided into groups by the time scale of detection, the detection targets (proteins, DNA fragments, apoptotic bodies, tissue changes) (Kinloch *et al.*, 1999; Hakumäki and Brindle, 2003; Zhao, 2001). The exact method of choice depends on proliferation of cells, microscopy capabilities, the living cells or tissue section types and the detected phase event in the apoptotic time line (Hakumäki and Brindle, 2003). Apoptosis can be detected through enzyme expression, DNA fragmentation markers, membrane alterations, proteases (such as caspases), apoptotic proteins, plasma membrane leakage and/or certain metabolic activity. Although, all of the above techniques generally have their shortcomings, histological markers are often considered “gold standard” and must therefore normally be used as reference to other techniques, such as in vivo imaging (Laxman *et al.*, 2002; Zhao, 2001).

Imaging of apoptosis in vivo: Traditionally, assessment of apoptosis in tissue is based on microscopic methods. Microscopic sections must be taken from tissue invasively using biopsy or post mortem (Artemov, 2003; Zhao, 2001). Clearly, these are invasive and set limitations to many follow-up studies. More complex methods are needed to visualize apoptosis in living systems, laboratory animals or human bodies. It is perhaps surprising that a phenomenon as subtle as apoptosis can non-destructively be visualized in vivo. This has become reality within just a few years, however. The research on apoptosis imaging began with metabolic characterization of cells by Nuclear Magnetic Resonance (NMR) spectroscopy (MRS) in vitro (Zhao, 2001; Aloya *et al.*, 2006). Magnetic resonance imaging (MRI), MRS and nuclear imaging approaches then followed rapidly together with optical imaging and even ultrasound. The success of these techniques lies on the myriad of changes involving membrane composition, protein synthesis, glycolysis, phosphatidylcholine, phosphatidylserine and cell fatty acid turnover, energy levels and even intracellular pH throughout the execution of the “apoptotic program in vivo (Laxman *et al.*, 2002; Artemov, 2003; Zhao, 2001; Aloya *et al.*, 2006). These can all be addressed either by direct detection or by applying external targeted agents. With the advent of personalized molecular medicine, accurate imaging of the apoptotic process could become an important tool in selecting, e.g., non-responding patients from responders much earlier than is currently possible with anatomical imaging techniques only (Hakumäki and Brindle, 2003; Aloya *et al.*, 2006). Likewise, these techniques could prove helpful in drug development and preclinical testing. We will briefly introduce here the mainstream in vivo imaging techniques and describe some of the key imaging

targets facilitating the detection of apoptotic cells. Furthermore, the first MRI technique applied to the detection of apoptosis was lipid proton magnetic resonance spectroscopy (Artemov, 2003; Aloya *et al.*, 2006). These studies described apoptosis-specific changes, including a selective increase in CH₂ (methylene) relative to CH₃ (methyl) mobile lipid proton signal intensities at 1.3 and 0.9 ppm, respectively. The rise in CH₂ resonance occurred with a wide range of apoptotic drugs as well as apoptosis associated with serum (growth factor) deprivation. The CH₂/CH₃ ratio also had a strong linear correlation with other markers of programmed cell death, including fluorescent annexin V cytometry and DNA ladder formation (Zhao, 2001; Schellenberger *et al.*, 2002). Although, there was an increase in the methylene resonance, there was no detectable change in total lipid composition or new lipid synthesis, suggesting an increase in membrane mobility as opposed to increased amounts of lipids within cells. These observations have largely been confirmed in subsequent investigations, though the source of the increased methylene signal intensity seen with apoptosis has been determined to arise from the formation of osmophilic lipid (0.222.0 nm) droplets with the cytoplasm (Artemov, 2003; Schellenberger *et al.*, 2002; Bammer, 2003). These droplets contain variable amounts of polyunsaturated fatty acids associated largely with 18:1 and 18:2 lipid moieties and an accumulation of triacylglycerides. The accumulation of triacylglycerides is believed to be related to phospholipase A2 activation and the formation of ceramide (a regulatory molecule in the mediation of membrane-related apoptotic events with a long CH₂ chain). Diffusion-Weighted MRI (DWI) is an alternative MRI modality that can image apoptosis in response to radiation and chemotherapy without the need for a contrast agent. DWI generates image contrast by using the diffusion properties of water within tissues. Diffusion can be predominantly unidirectional (anisotropic) or not (isotropic) and can be restricted or free depending on the amount of water in the extracellular (relatively unrestricted) or intracellular (restricted) compartments (Bammer, 2003; Radermacher *et al.*, 2012). DWI illustrations can be acquired with magnetic gradients of different magnitudes, generating an Apparent Diffusion Coefficient (ADC) map. As increases in cellularity are reflected as restricted motion, DWI has been used in cancer imaging to distinguish between tumor (restricted microenvironment) and peritumoral edema (unrestricted). DWI may also be valuable in monitoring treatment where changes due to cell swelling and apoptosis are measurable as changes in ADC (Radermacher *et al.*, 2012). The magnitude of changes, however, is small (i.e.,

50% of control) and it may be difficult to separate tumor shrinkage, necrosis and other processes that can occur with therapy. Therefore, more studies are needed to confirm the validity of DWI as a marker of therapeutic efficacy in the clinic (Radermacher *et al.*, 2012; Saito *et al.*, 2016).

RESULTS AND DISCUSSION

At quick glance, it is apparent that the most numerous applications for *in vivo* imaging of apoptosis are based on marker molecules. This is not surprising given the fact that after all, marker molecules, i.e., biologically active dyes, are what also has made the histological detection of apoptosis possible. Magnetic resonance research into apoptosis started in the mid-nineties when several groups began looking at relevant metabolic indicators of apoptosis (Aloya *et al.*, 2006; Radermacher *et al.*, 2012; Saito *et al.*, 2016). Due to the poor relative sensitivity and spatial resolution of MRS, it is an absolute necessity to use markers with sufficient signal intensity. If this requirement is fulfilled, molecular markers can easily be mapped with techniques such as MRS (Radermacher *et al.*, 2012; Fatehi *et al.*, 2015). The information provided by MRI has long been mostly anatomical and the technology clearly excels at this. MRI has in fact, become an indispensable imaging modality that can probe tissue and its biophysical properties with exceptional in-plane resolution *in vivo*. It would therefore be extremely beneficial to combine chemical specificity (such as that obtained by nuclear imaging or MRS) with the much better resolution (>50 m) of MRI. Indeed, it has recently been shown that MRI contrast can be rationally adjusted with good biocompatibility by chemically malleable marker ligands linked to magnetically active compounds, such as Superparamagnetic Iron Oxide nanoparticles, i.e., (SPIO) or Gadolinium (Gd) chelates that have been used to detect the over expression of certain receptors in tumors (Zhao, 2001; Radermacher *et al.*, 2012; De Backer *et al.*, 2010; Blankenberg and Strauss, 2013). These are important breakthroughs clinically, where MRI is more widely available, accurate localization is required and the levels of therapeutically induced apoptosis may still be low (Radermacher *et al.*, 2012; Tanha *et al.*) (Fig. 2).

Confirmation of apoptosis is then based on other criteria, such as demonstration of the internucleosomal DNA fragmentation in electrophoresis or analysis of the morphological features. Electrophoresis does not specify the cell types undergoing apoptosis and it is not sensitive enough to detect small quantitative differences. Morphologic criteria are considered as the most reliable

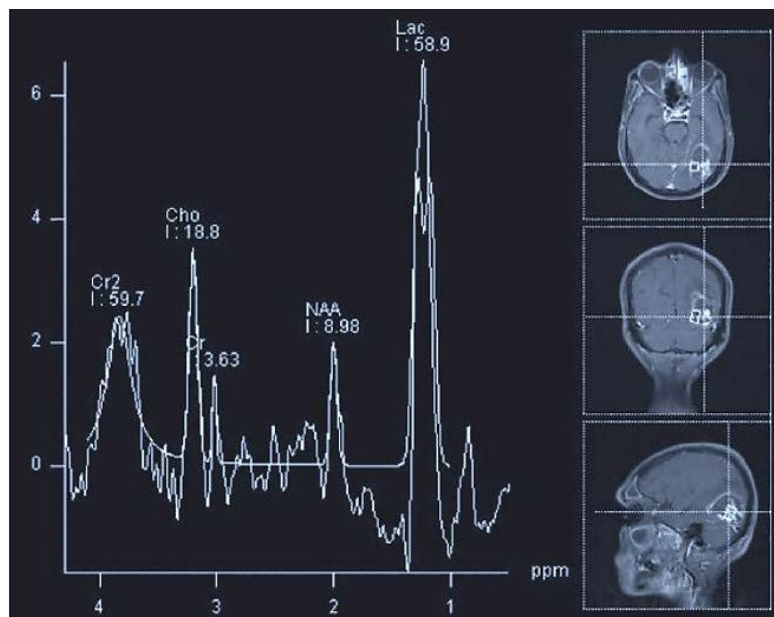


Fig. 2: MRS as reliable noninvasive tool can be presented important factors in apoptosis such as increased levels of lactate (Lac)

evidence of apoptosis (Blankenberg *et al.*, 2000; Zhao, 2001). Great progress has taken place in apoptosis imaging but we are essentially at the beginning. Much more experimental research with solid, consistent models and relevant oncological problems is required in the future. Clinical imaging applications for cancer need to be tested and developed more effectively. Independent measures of apoptosis such as flow cytometry and immunohistological stains still need to be kept abreast to confirm the localization, extent and kinetics of therapeutically induced apoptosis. The optimal time frames for imaging therapeutically induced apoptosis will have to be addressed as well (Radermacher *et al.*, 2012; Tanha *et al.*, 2016; Salehi *et al.* 2016). However, demonstration of complete apoptotic morphology by a single method is difficult. Nuclear condensation, shrinkage of the cell and fragmentation into apoptotic bodies can be visualized using light microscopy which is suitable for screening of large numbers of cells. Electron microscopy is required to demonstrate the loss of intact intracellular structures (Tanha *et al.*, 2016; Van Tilborg *et al.*, 2010). The major limitation of electron microscopy is that studying large numbers of cells is not feasible. Since the proportion of cells in the degradation phase of apoptosis at a single time point is small, finding even a single apoptotic cell by electron microscopy may be difficult. Due to its extremely high spatial resolution and true noninvasiveness, we expect a niche to remain for MRI agents as well, where optimal contrast generation

and agent delivery will preside as the main goals. For instance, SPIO-labeling despite its high sensitivity provides “negative” contrast, i.e., signal intensity reduction (Radermacher *et al.*, 2012; Van Tilborg *et al.*, 2010). This effect is more prone to artifacts and also difficult to interpret due to the often seen intrinsic heterogeneity of tumor masses on MRI. The conjugation of marker proteins with paramagnetic gadolinium based agents could be used to avert this problem with their “positive” contrast effect, i.e., brightening on MRI but the approach is plagued by severe sensitivity issues. NMR spectroscopic markers can be efficiently probed and more information gained by using advanced MRS techniques (Lindskog *et al.*, 2005). These are likely to reveal more information on the distribution and timeline of critical metabolic events during apoptosis *in vivo*. Among the potential application is lipid H MRS which is robust and practical. However, the metabolic factors governing NMR-visible lipid dynamics are poorly understood and theoretically, these signals could also arise from other cellular processes and from other endogenous cell types. The clinical use of ^{31}P appears unlikely due to its poor sensitivity, long acquisition times and inferior spatial resolution (Radermacher *et al.*, 2012; Fatehi *et al.*, 2015; Lindskog *et al.*, 2005). It is noteworthy however, that intracellular pH can currently be imaged non-invasively only by ^{31}P MRS. In the coming years, these developments in molecular imaging will undoubtedly be transformed into a better understanding of apoptosis in

cancer and its management, to the satisfaction of the clinician and to the benefit of the patient. Great progress has taken place in apoptosis imaging but we are essentially at the beginning (Niizuma *et al.*, 2010; Zhao, 2001; Van Tilborg *et al.*, 2010). Much more experimental research with solid, consistent models and relevant oncological problems is required in the future. Clinical imaging applications for cancer need to be tested and developed more effectively. Independent measures of apoptosis, such as flow cytometry and immunohistological stains still need to be kept abreast to confirm the localization, extent and kinetics of therapeutically induced apoptosis (Van Tilborg *et al.*, 2010). The optimal time frames for imaging therapeutically induced apoptosis will have to be addressed as well. Many more markers for apoptosis, with better sensitivity and specificity must also be explored.

CONCLUSION

As the field of apoptosis imaging is changing quite rapidly, it is difficult to make predictions about which set of tracers or imaging modalities will prove successful for clinical applications. For the time being, it appears that agents that bind to the surface of stressed or apoptotic cells, including Bcl₂ and its derivatives have the advantage with respect to sensitivity and specificity over metabolically directed tracers, such as caspase-related radiopharmaceuticals. NMR spectroscopic markers can be efficiently probed and more information gained by using advanced MRS techniques. These are likely to reveal more information on the distribution and timeline of critical metabolic events during apoptosis *in vivo*. Among the potential application is lipid 1H MRS, which is robust and practical. However, the metabolic factors governing NMR-visible lipid dynamics are poorly understood and theoretically, these signals could also arise from other cellular processes and from other endogenous cell types. The clinical use of 31P appears unlikely due to its poor sensitivity, long acquisition times and inferior spatial resolution. It is noteworthy however, that intracellular pH can currently be imaged non-invasively only by 31P MRS. We suggest a steady flow of new imaging applications to address apoptosis also in the clinical routine. However, for those involved with experimental studies and drug design, an even larger array of molecular imaging techniques is available. In the coming years, these developments in molecular imaging will undoubtedly be transformed into a better understanding of apoptosis in cancer and its management, to the satisfaction of the clinician and to the benefit of the patient. MR spectroscopy may be useful inside the brain and requires

no administration of contrast agent but its low sensitivity for DWI may be more robust outside the brain but, again, changes with cell death appear to be small and sensitive to many different types of artifacts. It is also unclear which are the best imaging applications for any given apoptosis directed agent in the clinic.

REFERENCES

- Aloya, R., A. Shirvan, H. Grimberg, A. Reshef and G. Levin *et al.*, 2006. Molecular imaging of cell death *in vivo* by a novel small molecule probe. *Apoptosis*, 11: 2089-2101.
- Artemov, D., 2003. Molecular magnetic resonance imaging with targeted contrast agents. *J. Cell. Biochem.*, 90: 518-524.
- Bammer, R., 2003. Basic principles of diffusion-weighted imaging. *Eur. J. Radiol.*, 45: 169-184.
- Blankenberg, F.G. and H.W. Strauss, 2013. Recent advances in the molecular imaging of programmed cell death: Part II-non-probe-based MRI, ultrasound and optical clinical imaging techniques. *J. Nucl. Med.*, 54: 1-4.
- Blankenberg, F.G., J.F. Tait and H.W. Strauss, 2000. Apoptotic cell death: Its implications for imaging in the next millennium. *Eur. J. Nucl. Med.*, 27: 359-367.
- Broughton, B.R.S., D.C. Reutens and C.G. Sobey, 2009. Apoptotic mechanisms after cerebral ischemia. *Stroke*, 40: e331-e339.
- De Backer, M.E., R.J.A. Nabuurs, M.A. van Buchem and L. van der Weerd, 2010. MR-based molecular imaging of the brain: The next frontier. *Am. J. Neuroradiology*, 31: 1577-1583.
- Evan, G.I. and K.H. Vousden, 2001. Proliferation, cell cycle and apoptosis in cancer. *Nature*, 411: 342-348.
- Fatehi, D., F. Naleini, M.G. Salehi, D. Afshari, S. Mirfendereski and M. Farzizadeh, 2015. Traumatic spinal cord injury; theranostic applications of advanced MRI techniques. *Biomed. Pharmacol. J.*, 8: 891-903.
- Hakunaki, J.M. and K.M. Brindle, 2003. Techniques: Visualizing apoptosis using nuclear magnetic resonance. *Trends Pharmacol. Sci.*, 24: 146-149.
- Hale, A.J., C.A. Smith, L.C. Sutherland, V.E.A. Stoneman, V.L. Longthorne, A.C. Culhane and G.T. Williams, 1996. Apoptosis: Molecular regulation of cell death. *Eur. J. Biochem.*, 236: 1-26.
- Karchani, M., A. Mazloumi, N.G. Saraji, A. Akbarzadeh and A. Niknezhad *et al.*, 2015. Association of subjective and interpretive drowsiness with facial dynamic changes in simulator driving. *J. Res. Health Sci.*, 15: 250-255.

- Kinloch, R.A., J.M. Treherne, L.M. Furness and I. Hajimohamadreza, 1999. The pharmacology of apoptosis. *Trends Pharmacol. Sci.*, 20: 35-42.
- Laxman, B., D.E. Hall, M.S. Bhojani, D.A. Hamstra, T.L. Chenevert, B.D. Ross and A. Rehemtulla, 2002. Noninvasive real-time imaging of apoptosis. *Proc. Natl. Acad. Sci. USA.*, 99: 16551-16555.
- Lindskog, M., C. Spenger, T. Klason, J. Jarvet and A. Graslund *et al.*, 2005. Proton magnetic resonance spectroscopy in neuroblastoma: Current status, prospects and limitations. *Cancer Lett.*, 228: 247-255.
- Martin, L.J., 2001. Neuronal cell death in nervous system development, disease and injury (review). *Int. J. Mol. Med.*, 7: 455-478.
- Morrison, R.S., Y. Kinoshita, M.D. Johnson, S. Ghatan, J.T. Ho and G. Garden, 2003. Neuronal Survival and Cell Death Signaling Pathways. In: *Molecular and Cellular Biology of Neuroprotection in the CNS*, Alzheimer, C. (Ed.). Springer, New York, USA., ISBN: 9781461501237.
- Niizuma, K., H. Yoshioka, H. Chen, G.S. Kim and J.E. Jung *et al.*, 2010. Mitochondrial and apoptotic neuronal death signaling pathways in cerebral ischemia. *Biochim. Biophys. Acta (BBA)-Mol. Basis Dis.*, 1802: 92-99.
- Radermacher, K.A., J. Magat, C. Bouzin, S. Laurent and T. Dresselaers *et al.*, 2012. Multimodal assessment of early tumor response to chemotherapy: Comparison between diffusion-weighted MRI, 1H-MR spectroscopy of choline and USPIO particles targeted at cell death. *NMR Biomed.*, 25: 514-522.
- Saito, A., M.M. Mekawy, A. Sumiyoshi, J.J. Riera, H. Shimizu, R. Kawashima and T. Tominaga, 2016. Noninvasive targeting delivery and *in vivo* magnetic resonance tracking method for live apoptotic cells in cerebral ischemia with functional Fe₂O₃ magnetic nanoparticles. *J. Nanobiotechnol.*, Vol. 14. 10.1186/s12951-016-0173-1
- Salehi, M.G., H. Masoumi, R.R. Tanha, F. Naleini, A. Gharib and A. Rostamzadeh, 2016. Role of diffusion tensor imaging as an imaging biomarker and theranostic tool in structural imaging of traumatic brain injury. *J. Chem. Pharmaceut. Sci.*, 9: 854-864.
- Schellenberger, E.A., A. Bogdanov Jr., D. Hogemann, J. Tait, R. Weissleder and L. Josephson, 2002. Annexin V-CLIO: A nanoparticle for detecting apoptosis by MRI. *Mol Imaging*, 1: 102-107.
- Springer, J.E., 2002. Apoptotic cell death following traumatic injury to the central nervous system. *J. Biochem. Mol. Biol.*, 35: 94-105.
- Tanha, R.R., O. Ghaderi, A. Gharib, M.A. Anzab and R. Ahmadi *et al.*, 2016. Increasing prevalence of multiple sclerosis: Biomarkers theranostic strategy from bench to bedside-A review. *J. Chem. Pharma. Sci.*, 9: 1-12.
- Van Tilborg, G.A., E. Vucic, G.J. Strijkers, D.P. Cormode and V. Mani *et al.*, 2010. Annexin A5-functionalized bimodal nanoparticles for MRI and fluorescence imaging of atherosclerotic plaques. *Bioconjugate Chem.*, 21: 1794-1803.
- Vila, M. and C. Perier, 2008. Molecular pathways of programmed cell death in experimental Parkinson's disease. *Parkinsonism Related Disorders*, 14: S176-S179.
- Zhao, M., 2001. Detection of apoptosis using magnetic resonance imaging. University of Cambridge, Cambridge, UK.