

Hepatoprotective and Haematopoietic Modulatory Efficacy of Leaf Extract of *Colocasia esculenta* in Albino Wistar Rats

¹Olalere Fatai Dayo, ²Blessing Chekwube Eluke, ²Ernest Okem Ukaejiofo,

¹Olatubosun Luqman Olayinka, ²Chukwu Ikechukwu Johnpaul,

³Ogunwale Ayobami Kolawole Tajudeen, ²Ikegwuonu Ifeoma Chinwe,

¹Lawal Sikiru Adetona, ⁴Nafiu Abdulrasak, ⁵Afolabi Onaolapo Olugbenga and

⁶Abioye Adesola Idowu Abdurraheem

¹Department of Haematology, University of Ilorin Teaching Hospital, Ilorin, Nigeria

²Department of Medical Laboratory Science, Faculty of Health Sciences and Technology,
College of Medicine, Enugu Campus, University of Nigeria, Enugu, Nigeria

³Department of Chemical Pathology, University of Ilorin Teaching Hospital, Ilorin, Nigeria

⁴Department of Physiology, University of Ilorin, Ilorin, Nigeria

⁵Department of Histopathology, University of Ilorin, Ilorin, Nigeria

⁶Department of Anatomy, Faculty of Basic Medical Sciences, University of Ilorin, Ilorin, Nigeria

Abstract: The study was done to investigate the haematopoietic and hepatoprotective modulatory effects of the leaf extract of *Colocasia esculenta* in Carbon tetrachloride (CCl₄) induced hepatotoxic Wistar rats. About 30 albino Wistar rats were divided into six groups of six per group for the study. Group 1 served as the control group and received no treatment while group 2 was the negative control and was treated with 0.5 mg/kg CCl₄ only. Group 3 served as the positive control and was treated with CCl₄ and 100 mg/kg silymarin. Groups 4-6 were all induced with CCl₄ and then administered with varying doses of the extract (100, 200 and 400 mg/kg, respectively). Blood samples were collected from all rats after 14 days under ether anesthesia following international guidelines on the use and handling of animals and were subjected to laboratory analysis according to standard techniques. The result obtained revealed that the Aqueous leaf Extract of *Colocasia esculenta* (AECE) at varying doses further significantly decreased all estimated markers of liver function (Aspartate Transaminase (AST) Alanine Transaminase (ALT) and Alanine Phosphatase (ALP) after the administration of CCl₄. The extracts equally showed increased in platelet (thrombocytosis), however, total White Cell count (WBC), Haemoglobin (Hb), Red Cell count (RBC), Packed Cell Volume (PCV) and red cell indices were statistically significantly reduced (p<0.05). Tissue morphology was restored by the AECE at varying doses. The findings revealed that leaf extract of *Colocasia esculenta* possesses potent hepatoprotective properties enhanced thrombopoiesis and is a potential agent to correct hepatotoxicity premised on its efficacy, affordability, safety and availability following standardization/clinical trials.

Key words: Haematopoietic, hepatoprotective, *Colocasia esculenta*, Wistar albino rats, availability, properties

INTRODUCTION

The healthy liver plays a vital function in the maintenance and regulation of homeostasis in the body. It is involved in the wide array of biochemical pathways that are involved in energy provision, growth, supply of nutrient, fight against disease and reproduction (Kmiec, 2001). Its major functions includes; protein, carbohydrate and fat metabolism, digestion, energy provision, detoxification and storage of vitamin and

secretion of bile (Vishal, 2013). Certain medicinal agents, when taken in overdose and sometimes when introduced within therapeutic ranges, may injure the liver (Shi *et al.*, 2010). Liver damage means that the functions of the liver become compromised. In traditional and unorthodox medicine, different herbs and plants are continuously used for various treatment modalities (Sharma *et al.*, 1991). Especially in Africa where economic conditions are dire and poverty defines a lot of actions. This condition has made people look for easier, cheaper alternative to modern

Corresponding Author: Blessing Chekwube Eluke, Department of Medical Laboratory Science,
Faculty of Health Sciences and Technology, College of Medicine, Enugu Campus, University of Nigeria,
Enugu, Nigeria

medicine (Subramoniam and Pushpangadan, 1999). Many plants may contain active pharmacological constituents that may protect the liver from hepatotoxicity while others elicit marked liver diseases (Stickel *et al.*, 2001). In this regard, *Colocasia esculenta* has been considered for its protective ability on liver and blood cells.

Colocasia esculenta is a common edible herbaceous perennial green leafy crop grown in humid tropics and widely used in Africa, Asia, India and South America. It is commonly called cocoa yam but the Yoruba people in Nigeria call it 'ewe koko'. In traditional setting, apart from its use as vegetable in cooking, its edible leaves and corn are used for hepatic treatment. *Colocasia esculenta* has been found to contain nutrients such as vitamins and mineral for example vitamin C, thiamine riboflavin, calcium, iron and phosphorus and has been reported to be a rich source of protein and dietary fiber (Lewu *et al.*, 2009). Other multiple uses of *Colocasia esculenta* in unorthodox practice include: as antidote to scorpion, snake bite, food poisoning in treatment of alopecia, hemorrhoids and constipations (Awasthi and Singh, 2000). Furthermore, other studies have demonstrated that *Colocasia esculenta* possesses antibacterial, antihyperlipidemic and antifungal activity (Ravikumar *et al.*, 2011; Yang and Yeh, 2005; Grindley *et al.*, 2002). Though local use of this plant is varied, its use as a hematoprotective and hepatoprotective agent has not been validated, hence this study.

MATERIALS AND METHODS

Plant materials and authentication: The plant leaves were obtained from a small scale farm at Oko-Erin' area in Ilorin, Kwara state, Nigeria. It was authenticated at the Botany Department of University of Ilorin, Ilorin, Nigeria by Mr. Bolu Ajayi and was given a voucher specimen number UIH 001\171. A specimen was further deposited at the herbarium unit of the university for future reference.

Preparation of plant extract (AECC): The leaves of *Colocasia esculenta* were air-dried at room temperature for 3 weeks after which it was macerated and milled into coarse powder. A portion of (225 g) of the powder was extracted in 5 L of distilled water followed by thorough mixing for 72 h. The mixture was then sieved using muslin cloth and Whatman filter paper was used to filter the final filtrate. The filtrate was subjected to condensation technique using rotary evaporator to give 56.4 g representing 25.1% yield of the starting material.

Preparation of dosage of the plant extract: About 20 g of *Colocasia esculenta* extract was dissolved in 100 mL of distilled water to make 20% of the leaf extracts (AECE) which equivalent to 200 mg/kg body weight (b.w.) .

Drugs and chemicals: Silymarin tablets were supplied by micro Labs Limite (92 Sipcot, Hosur-635 126 India) while CCl₄, a colourless nonflammable liquid of molecular weight 153.84 was obtained from LabTrade (Nig.) Company Limited, Ilorin. ALT, AST, TP, ALB, ALP and GGT kits were the products of AGAPPE Diagnostics Switzerland and was given in dose of 0.5 mL/kg CCl₄ (30% in Olive oil).

Experimental animals: Both sexes of albino wistar rats weighing approximately 170-200 g were obtained from animal house of Anatomy Department, College of Medicine, University of Ilorin, Kwara State, Nigeria. They were kept under normal temperature and humidity on a 12 h light/dark cycle. Food and water were made available ad libitum throughout the experiment. The experimental animals were allowed 2 weeks acclimatization and were housed in the appropriately designed cages suitably bedded with wood shavings.

Experimental design: The study adopted the experimental design. Thirty six albino Wistar rats were divided into 6 groups of six per group for the study. Group 1 served as the control group and received no treatment while group 2 was the negative control and was treated only with 0.5 mg/kg CCl₄. Group 3 served as the positive control and was treated with CCl₄ and 100 mg/kg silymarin. Groups 4-6 were all induced with CCl₄ and then administered with varying doses of aqueous leaf extract of *Colocasia esculenta* AECE (100, 200 and 400 mg/kg, respectively).

Group 1: Normal Control (NCNT) not treated; administered with only water and feed.

Group 2: Negative Control (NC) Hepatotoxic (drug) control, administered with only 0.5 mL/kg CCl₄ (carbon tetrachloride) as negative control.

Group 3: Positive Control (PC); group treated with 0.5 mL/kg of CCl₄ to induce Hepatotoxicity and then with 100 mg of silymarin standard drug.

Group 4: Test group (CE 100); group treated with 100 mg/kg of aqueous extract of *Colocasia esculenta* (AECE) and then with 0.5 mL/kg of CCl₄.

Group 5: Test group (CE 200) group treated with 200 mg/kg of aqueous extract of AECE and then with 0.5 mL/kg of CCl₄.

Group 6: Test group (CE 400) group treated with 400 mg/kg AECC and then with 0.5 mL/kg of CCl₄.

Blood collection and laboratory analysis: Blood samples were collected from all rats after 14 days treatment under ether anesthesia following international guidelines on the use and handling of animals. The 5 mL of blood was collected into plain and Ethylene Diamine Tetra Acetic acid (EDTA) anticoagulant tube for the analysis of haematological and biochemical parameters while liver biopsy was used for histology. All laboratory analysis were carried out according to standard procedures as demonstrated by Dacie and Lewis (2006).

Statistical analysis: All data generated were analyzed using SPSS (Statistical Package for Social Sciences) Version 19. Analysis of variance and Tukey post hoc analysis were the statistical technique used for analysis. $p < 0.05$ was considered significant were applicable and all data were presented as mean \pm standard deviation.

RESULTS AND DISCUSSION

The qualitative phytochemistry revealed the presence of terpenoids, glycosides, tannins, flavonoids, saponins, alkaloids, cellulose, quinine, steroids and phenols (Table 1). The result also showed a significant decrease ($p < 0.05$) in Packed Cell Volume (PCV), Red Blood Cell count (RBC count), total White blood cell count and Mean Cell Volume (MCV) when group 2 (treated with only CCl₄) and 3 (treated with CCl₄ and standard drug Silymarin) were compared with normal control. The mean values of PCV were significantly reduced when group 3 (positive control) and test group 4 (CE 100 mg/kg) were compared to negative control (group 2). The haemoglobin concentration was significantly ($p < 0.05$) reduced when groups 3-5 were compared to negative control (group 2) (Table 2).

There was significant reduction ($p < 0.05$) in mean levels of MCV in the group induced with CCl₄ hepatotoxicity (group 2) when compared with normal control. However, the MCV remained significantly ($p < 0.05$) lower after treatment with the reference drug (PC; silymarin 100 mg/kg) as compared to normal control.

Furthermore, treatment with test groups 4 and 5 (CE 100 and 200 mg/kg) significantly ($p < 0.05$) increased the MCV when compared to normal control. MCH was also

Table 1: Phytochemical Analysis of leaf extracts of *Colocasia esculenta*

Extracts	Secondary metabolite	Ethyl acetate
1	Phenols: FECl ₃ test	+
2	Tannin: FECl ₃ test	+
3	Flavonoid Alkaline reagent test	+
4	Saponins: foam test	+
5	Steroid	+
6	Quinone	+
7	Cellulose	+
8	Terpenoids	+
9	Glycosides	+
10	Alkanoids	+

(+) = Present; (-) = Absent

significantly increased by CE 100 and 400 mg/kg when compared to positive control. Meanwhile, only CE (200 mg/kg) significantly ($p < 0.05$) reduced MCHC compared to negative control (Group 2) while positive control and other treated groups remained relatively unchanged.

At all levels of treatment with the different doses of AECE (CE 100 and 200 mg/kg), there was a significant decrease ($p < 0.05$) in ALT and AST when compared to normal, positive control and negative control. It was also observed that total bilirubin concentration was only significantly reduced at test doses of 100 and 400 mg/kg when compared with positive control. Serum conjugate bilirubin decreased in values at all levels of tested groups of *Colocasia esculenta* but not statically significant. Serum GGT concentration was only significant at test dose CE 200 mg/kg body weight when compared to groups 1-3 while other groups remained unchanged.

There was also an observed increase in the serum albumin and protein concentration of the groups treated with the extracts at (100, 200 and 400 mg/kg) were significantly ($p < 0.05$) increased when compared to positive and normal control.

There is a clear indication of pathological changes such as extension of hepatic lobes, degeneration of hepatocytes, lobular inflammation by inflammatory cells and peri-portal inflammation for group 2 (negative control) that was administered with only CCl₄ (Fig. 1).

Colocasia esculenta is a common plant found in West Africa and is used for food and traditionally for the treatment of certain ailments (Azubike *et al.*, 2012; Vasant *et al.*, 2012). This study was carried out to evaluate the haematopoietic and hepatoprotective modulatory efficacy of leaf extracts of *Colocasia esculenta* in CCl₄ induced hepatotoxicity in Wistar albino rats. The parameters assessed were biochemical and haematological parameters. Histological assessment of the liver was also evaluated. Phytochemical studies on the aqueous extract of *Colocasia esculenta* leaves revealed the presence of potent phytochemicals such as phenol,

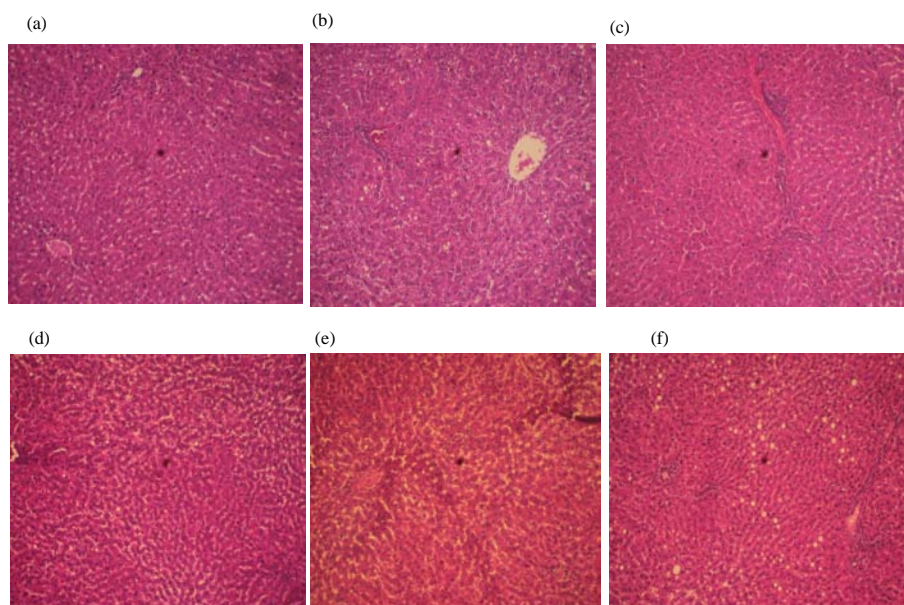


Fig. 1: The histo-architecture of the liver biopsies for the different groups (Plates a-f)

Table 2: Changes in White blood cells, neutrophils, lymphocytes and platelets after treatment of CCl₄ induced hepatotoxicity with *Colocasia esculenta* extract (100, 200 and 400 mg/kg) in rats

Treatment groups	White bloodcells ($\times 10^9/L$)	Neutrophils (%)	Lymphocytes (%)	Platelets ($\times 10^9/L$)	Packed cell volume (%)	Haemoglobin (g/dL)	Red blood cell ($\times 10^{12}/L$)
NCNT	7.97 \pm 2.64*	20.17 \pm 3.490	79.83 \pm 3.490	752.00 \pm 71.77*	47.50 \pm 2.88	13.73 \pm 0.63 [#]	7.83 \pm 0.34
NC (CCl ₄)	13.33 \pm 3.25	19.00 \pm 5.550	81.00 \pm 5.550	596.00 \pm 65.72	49.50 \pm 3.39	14.67 \pm 1.02	8.60 \pm 0.70
PC (Sly100 mg/kg)	7.43 \pm 1.15*	23.00 \pm 1.410	77.00 \pm 1.410	604.83 \pm 115.35	43.17 \pm 1.47*	12.15 \pm 0.76*	7.38 \pm 0.58
CE (100 mg/kg)	8.42 \pm 1.86*	11.67 \pm 1.370	88.33 \pm 1.370	775.33 \pm 64.05* [#]	43.67 \pm 3.01*	12.72 \pm 0.75*	7.43 \pm 0.71*
CE (200 mg/kg)	9.63 \pm 1.17*	24.83 \pm 13.36	75.17 \pm 13.36	1015.33 \pm 87.24* [#]	45.83 \pm 1.47	13.07 \pm 0.42*	7.82 \pm 0.46
CE (400 mg/kg)	9.12 \pm 0.78*	17.67 \pm 7.470	82.33 \pm 7.470	1003.8 \pm 112.02* [#]	45.67 \pm 2.81	13.37 \pm 0.55	7.77 \pm 0.61

CNT: Normal Control, NC: Negative Control, PC: Positive Control, CE: *Colocasia esculenta*, CCl₄: Carbon tetrachloride. Values represent mean \pm SD (n = 6). *[#] indicate significant difference as compared to NC and PC, respectively at p<0.05

tannin, saponins, steroid, quinolones flavonoids, cellulose, terpenoids, glycosides, alkaloids which are the substances that can help in regenerating liver damage. The constituent with this variety c.

There was a statistically significant increase (p<0.05) in the liver enzyme markers AST, ALT and ALP of the group administered with CCl₄ when compared to normal control group. Increase in serum enzymes is a well known indicator of liver damage because it shows evidence of cell membrane damage (Mitra *et al.*, 1998; Solter *et al.*, 2000). CCl₄ is one of the most widely experimental compounds employed in the induction of liver toxicity (Weber *et al.*, 2003). Action of microsomal cytochrome P-450 enzyme (CYP2E11) in the generation of trichloromethyl radical (CCl₃•), a reactive free radical of CCl₄ may lead to hepatic injury. Trichloromethyl radical can readily react with molecular oxygen to form trichloro methyl peroxy radical (CCl₃O₂•) which may initiate lipid peroxidation and thus liver damage (Recknagel *et al.*, 1989) (Table 3).

After treatment with CCl₄, the effect of *Colocasia esculenta* extracts was clearly demonstrated by the concentrations of serum biomarkers (ALT, AST and ALP). The findings of the current study revealed that AECE when administered to test groups 4 and 5 (CE 100 and 200 mg/kg body weight) was able to protect the liver cells. The assessment of liver enzyme markers showed a statistically significant decrease in the markers measured. This may mean that these enzymes originally present in higher concentration due to hepatopathy caused by CCl₄ were protected from severe liver injury as a result of the protection of liver cells with AECE. This is in agreement with other authors who had suggested that AECE may proffer some form of protection against liver damage (Vasant *et al.*, 2012). The phytochemical constituents of the extract as described here might have helped in imbuing this plant with such characteristic. It is a known fact that some plants have antioxidant activities which are able to protect against the action of free radicals.

Table 3: Changes in ALT, AST and Alkaline phosphatase after treatment of CCL₄ induced hepatotoxicity with *Colocasia esculenta* extract (100, 200 and 400 mg/kg) in rats. Changes in TB, CB and GGT after treatment of CCL₄ induced hepatotoxicity with *Colocasia esculenta* extract (100, 200 and 400 mg/kg) in rats. Changes in total protein and albumin after treatment of CCL₄ induced hepatotoxicity with *Colocasia esculenta* extracts (100, 200 and 400 mg/kg) in rats

Treatment groups	ALT (U/L) (mg/dL)	AST (U/L)	Total protein	Albumin (mg/dL)	ALK. PHOS (U/L)	TB (mg/dL)	CB (mg/dl)	GGT (U/L)
NCNT	7.83±5.19	1.83±0.98	74.67±8.19 [#]	27.50±2.07	573.67±63.91*	8.66±2.16*	2.83±1.17 [#]	3.16±2.40
NC (CCL ₄)	15.00±3.52	12.16±5.60	66.83±1.47	24.83±2.32	604.67±37.10*	14.00±1.41	6.83±1.17	2.16±2.04
PC (Silymarin 100 mg/kg)	14.16±14.83	9.50±2.58	62.17±1.47	26.33±1.03	267.17±30.16 [#]	12.83±1.72*	3.33±0.52	3.33±1.86
CE (100 mg/kg)	10.50±8.56*	2.83±0.75 [#]	74.17±2.71 [#]	38.00±18.71	423.83±23.64 [#]	9.50±1.04 [#]	3.17±0.75	2.83±2.22
CE (200 mg/kg)	3.66±2.16 [#]	5.50±4.37*	77.83±4.58 [#]	27.17±1.47	556.33±96.71*	9.16±1.27	5.00±0.89	10.83±4.70 [#]
CE (400 mg/kg)	19.66±11.23*	1.50±0.54*	76.67±6.80 [#]	33.17±1.94		9.83±1.16 [#]	3.50±1.50	2.66±1.36

NCNT-Normal Control; NC-Negative Control; PC-Positive Control; CE-*Colocasia esculenta*; Sly-silymarin; ALT-Alanine Aminotransferase; AST-Aspartate Aminotransferase; ALK PHOS-Alkaline Phosphatase; CCL₄-Carbon tetrachloride. Values represent mean±SD (n = 6). *[#]indicate significant difference as compared to NC and PC, respectively at p<0.05 NCNT-normal control; NC-Negative Control; PC-Positive Control; CE- *Colocasia esculenta*; Sly- Silymarin; TB-Total Bilirubin; CB-Conjugate Bilirubin; GGT- γ -Glutanyl Transferase; CCL₄-Carbon tetrachloride. Values represent mean±SD (n = 6). *[#]indicate significant difference as compared to NC and PC, respectively at p<0.05. CNT; Normal Control, NC; Negative Control, PC; Positive Control, CE; *Colocasia esculenta*, Sly; Silymarin.CCL₄; carbon tetrachloride.Values represent mean±SD (n = 6). GGT- γ -Glutanyl Transferase;*and [#] indicate significant difference as compared to NC and PC, respectively at p<0.05

Furthermore, in comparison, the positive group which was treated with the standard drug, silymarin after inducing hepatotoxicity with carbon tetrachloride had significant decreased levels of ALT, AST and ALP. Silymarin was used as a standard drug and was able to counter the effect of CCL₄. Silymarin, harnessed from the milk thistle plant and compounded by components such as taxifolin, silycristin, silydianin and isosilybin A and B is a drug of choice in the treatment of liver diseases (Abenavoli *et al.*, 2010). Its mechanism of action includes: scavenger of free radical (ROS), membrane stabilizing and hepatocyte regeneration, inhibition of 5 lipogenase pathway, suppression of Tumor Necrosis Factor alpa (TNF- α) and nuclear factor kappa B and DNA expression. stahas been proposed to be as due to its anti. This finding is in agreement with previous finding (Feher and Lengyel, 2012; Saller *et al.*, 2001; Pradhan and Girish, 2006; Wellington and Jarvis, 2001).

Similarly, it was observed that serum total bilirubin concentration was only significantly reduced at CE doses of 100 and 400 mg/kg when compared with positive control. However, serum conjugated bilirubin reduced in value at all levels of tested groups of *Colocasia esculenta* but not statistically significant. Serum GGT concentration was only significant at CE (200 mg/kg) while other groups remained unchanged. This is an indication of liver injury and the leaf extracts of CE did not show a positive effect on some tested groups. The observed significant increase (p<0.05) in the serum albumin and total protein concentration of the groups treated with the extracts when compared with the control can only further confirm that AECE may have protective effect on the liver. Liver is primarily responsible for the production of albumin (Doweiko and Nompoggi, 1991).

The histo-architecture of the liver biopsies for the different groups (Plates 1-6), revealed very clear

pathological changes such as extension of hepatic lobes, degeneration of hepatocytes, lobular inflammation by inflammatory cells and peri-portal inflammation. These are clear signs of hepatotoxicity caused by CCL₄ on hepatocytes and may lead to total loss of liver function. Eroschencho 2000 reported that cells died as a result of necrosis or apoptosis when they are challenged with toxins, noxious agent or injuries. The observed effects are also signs of progression towards cirrhosis which may be due to an increase in oxidative stress, in lipid peroxidation and in production of cytokines (Zimmerman, 1999). This findings correlate with the result of liver enzyme markers assay previously discussed.

The result further demonstrated a significant decrease in the white blood cell count of all test groups when compared to normal. The result of other haematological parameters shows a decrease in haemoglobin level, mean cell haemoglobin and red cell count across all groups when compared to normal group. The extract therefore, did not show any protection of blood cells. This is in contrast with some authors who had suggested that AECE have an antibacterial function (Yang and Yeh, 2005). These researchers have argued that extract of *Colocasia esculenta* is comparable to antimicrobial agent (Ravikumar *et al.*, 2011). However, platelet count significantly increased with all doses of *Colocasia esculenta* (100, 200 and 400 mg/kg) when compared with negative, normal and positive controls. Platelet are small fragments produced from precursor cell Megakaryocytes that play a major role in blood clotting when there is damage to the vascular endothelium (Machlus and Italiano, 2013; Pang *et al.*, 2005). The extracts may have exhibited potentials in activating platelet release since thrombopoietin that initiates thrombopoiesis is elaborated by the kidney and liver. Serum GGT concentration was only significant at CE (200 mg/kg) while other groups

remained unchanged. This is an indication of liver injury and the leaf extracts of CE did not show a positive effect on some tested groups.

CONCLUSION

Leaf extract of *Colocasia esculenta* possessed clear hepatoprotective properties while the modulatory effect on haemopoiesis was quite mild to be potent. This may mean that this extract compared favorably with standard drug.

REFERENCES

- Abenavoli, L., R. Capasso, N. Milic and F. Capasso, 2010. Milk thistle in liver diseases: Past, present, future. *Phytother Res.*, 24: 1423-1432.
- Awasthi, C.P. and A.B. Singh, 2000. Nutritional quality evaluation of edible leaves of some promising *Colocasia* and *Alocasia* collections. *Indian J. Agric. Res.*, 34: 117-121.
- Azubike, N.C., P.U. Achukwu and C.N. Okwuosa, 2012. Preliminary assessment of the phytochemicals and toxicity testing of *Colocasia esculenta*. *J. Applied Sci.*, 15: 10783-10796.
- Dacie, J.V. and S.M. Lewis, 2006. *Practical Hematology*. 10th Edn., Lewis, Bain and Bates, Churchill Livingstone, An Imprint of Elsevier, pp: 25-57.
- Doweiko, J.P. and D.J. Nompleggi, 1991. The role of albumin in human physiology and pathophysiology, Part III: Albumin and disease states. *J. Parenter. Enteral. Nutr.*, 15: 476-483.
- Feher, J. and G. Lengyel, 2012. Silymarin in the prevention and treatment of liver diseases and primary liver cancer. *Curr. Pharm. Biotechnol.*, 13: 210-217.
- Grindley, P.B.A., F. Omoruyi, H.N. Asemota and E.Y.S.A. Morrison, 2002. Carbohydrate digestion and intestinal ATPases in streptozotocin-induced diabetic rats fed extract of yam (*Dioscorea cayenensis*) or dasheen (*Colocasia esculenta*). *Nutr. Res.*, 22: 333-341.
- Kmieciak, Z., 2001. Cooperation of liver cells in health and disease. *Adv. Anat. Embryol. Cell. Biol.*, 161: 1-151.
- Lewu, M.N., P.O. Adebola and A.J. Afolayan, 2009. Effect of cooking on the proximate composition of the leaves of some accessions of *Colocasia esculenta* (L.) Schott in KwaZulu-Natal province of South Africa. *Afr. J. Biotechnol.*, 8: 1619-1622.
- Machlus, K.R. and J.E. Italiano, 2013. The incredible journey: From megakaryocyte development to platelet formation. *J. Cell Biol.*, 201: 785-796.
- Mitra, S.K., M.V. Venkataranganna, R. Sundaram and S. Gopumadhavan, 1998. Protective effect of HD-03, a herbal formulation, against various hepatotoxic agents in rats. *J. Ethnopharmacol.*, 63: 181-186.
- Pang, L., M.J. Weiss and M. Poncz, 2005. Megakaryocyte Biology and related disorders. *J. Clin. Invest.*, 115: 3332-3338.
- Pradhan, S.C. and C. Girish, 2006. Hepatoprotective herbal drug, silymarin from experimental pharmacology to clinical medicine. *Indian J. Med. Res.*, 124: 491-504.
- Ravikumar, S., N. Gracelin, A.A. Anandha, G.S. Palani and A. Kalaiarasi, 2011. In vitro antibacterial activity of coastal medicinal plants against isolated bacteria fish pathogen. *Intl. J. Pharma. Res. Devel.*, 3: 109-116.
- Recknagel, R.O., E.A. Glende, J.A. Dholak and R.L. Walter, 1989. Mechanism of carbon tetrachloride toxicity. *Pharmacol. Ther.*, 43: 135-135.
- Saller, R., R. Meier and R. Brignoli, 2001. The use of silymarin in the treatment of liver diseases. *Drugs*, 61: 2035-2063.
- Sharma, A., K.K. Chakraborti and S.S. Handa, 1991. Anti-hepatotoxic activity of some Indian herbal formulations as compared to silymarin. *Fitoterapia*, 62: 229-235.
- Shi, Q., H. Aong, J. Senior and W. Tong, 2010. Biomarker for drug-induced liver injury. *Expert Rev. Gastroenterol. Hepatol.*, 4: 225-234.
- Solter, P., Z. Liu and R. Guzman, 2000. Decreased hepatic ALT synthesis is an outcome of Subchronic microcystin-LR toxicity. *Toxicol. Appl. Pharmacol.*, 164: 216-220.
- Stickel, F., H.K. Seitz, E.G. Hahn and D. Schuppan, 2001. Liver toxicity of drugs of plant origin. *Z. Fur Gastroenterologie*, 39: 225-232.
- Subramoniam, A. and P. Pushpangadan, 1999. Development of phytomedicines for liver disease. *Indian J. Pharmacol.*, 31: 166-175.
- Vasant, O.K., B.G. Vijay, S.R. Virbhadrappa, N.T. Dilip, M.V. Ramahari and B.S. Laxamanrao, 2012. Antihypertensive and diuretic effects of the aqueous extract of *Colocasia esculenta* Linn. leaves in experimental paradigms. *Iran. J. Pharm. Res.*, 11: 621-634.
- Vishal, R., 2013. Protective role of Indian medicinal plants against liver damage. *J. Phytopharmacology*, 2: 1-3.

- Weber, L.W., M. Boll and A. Stampfl, 2003. Hepatotoxicity and mechanism of action of haloalkanes: Carbon tetrachloride as a toxicological model. *Crit. Rev. Toxicol.*, 33: 105-136.
- Wellington, K. and B. Jarvis, 2001. Silymarin: A review of its clinical properties in the management of hepatic disorders. *Bio. Drugs*, 15: 465-489.
- Yang, A.H. and K.W. Yeh, 2005. Molecular cloning, recombinant gene expression and antifungal activity of cystatin from taro (*Colocasia esculenta* cv. Kaosiung no. 1). *Planta*, 221: 493-501.
- Zimmerman, H., 1999. *Hepatotoxicity: The Adverse Effects of Drugs and other Chemicals on the Liver*. 2nd Edn., Lippincott Williams and Wilkins, Philadelphia, Pennsylvania, USA., ISBN:0-7817-1952-6, Pages: 791.