

Feed Based Infectious Bursal Disease Vaccination in Broiler Chickens

M. Hair-Bejo, K. K. Chan and C. C. Wong
Faculty of Veterinary Medicine, Universiti Putra Malaysia,
43400 UPM Serdang, Selangor, Malaysia

Abstract: Infectious bursal disease (IBD) is an important viral disease of chickens due to significant economic losses in the industry resulting from high mortality and immunosuppression. An experiment was conducted to determine the efficacy of an attenuated live "intermediate" strain IBD vaccine of Malaysian isolate given to broiler chickens via feed. One hundred and twenty day old broiler chicks were divided into 3 groups namely: group A (feed based IBD vaccination), group B (IBD vaccination via intraocular route) and group C (control). The chickens in groups A and B were vaccinated at day 14 with an attenuated live "intermediate" strain IBD vaccine of Malaysian isolate ($10^{4.5} \text{EID}_{50}/0.1 \text{ml}$) via feed (about 0.1ml/chick) and intraocular route (0.1ml/chick), respectively. Feed and water were given ad libitum, and the chickens were monitored for any clinical abnormalities throughout the trial. Eight chicks in the control group were sacrificed at 1, 7, 14, 21, 28, 35 and 42 days of age. Eight chickens each from the groups A and B were sacrificed at 21, 28, 35 and 42 days of age. Body weights were taken and serum samples were collected for IBD antibody detection using enzyme linked immunosorbent assays (ELISA) prior to necropsy. On necropsy, the gross lesions were recorded and the bursa of Fabricius was weighed and fixed in 10 % buffered formalin for histopathology examination. The study showed that no clinical sign of IBD observed in all groups throughout the trial. The body weights in all groups were not significantly different ($p < 0.05$). Gross lesions were confined to the bursa of Fabricius at day 21 of age in the group A, and at days 21 and 28 of age in the group B. The bursa weight and bursa to body weight ratio in groups A and B were generally lower than control group throughout the post vaccination period. The lesions scores in group A remained mild to moderate throughout post vaccination period and showed sign recovery at day 42. The lesions score in the group B was moderate at day 21 of age and reduced to mild to moderate thereafter. Both routes of vaccination were able to induce protective immunity against IBD infection at days 35 and 42 of age. It was concluded that the feed based IBD vaccination at 14-day-old broiler chickens using attenuated live "intermediate" strain IBD vaccine of Malaysian isolate is safe and successfully induce protective level of IBD antibody.

Key words: Infectious bursal disease, feed based vaccination, broiler chickens, bursa lesion scoring, ELISA

Introduction

Infectious bursal disease (IBD) or Gumboro disease, an acute contagious viral disease in susceptible 3 to 6 week old chickens, was first recognized as a clinical entity in 1957 in USA (Congrove, 1962). To date, IBD has become an important viral disease in the poultry industry worldwide due to significant economic losses resulting from high mortality, impaired growth, excessive carcass condemnation and profound immunosuppression leading to increase susceptibility to other pathogens and interfere with the effectiveness of vaccination programme against other highly virulent diseases. IBD is caused by Birnavirus, a non-enveloped, icosahedral virion with dsRNA genome with two segments: segment A (3.1kbp) and segment B (2.9 kbp). The virus is about 50 to 55 nm in diameter with a single shell. IBD virus (IBDV) is very stable to chemical and physical agents and it can remain for long in a contaminated environment.

Outbreak of IBD due to very virulent IBDV (vvIBDV) was first reported in Malaysia in 1991 (Hair-Bejo, 1992, 1993; Phong *et al.*, 2003). Since then, the disease spread throughout the country in both the vaccinated and non vaccinated chickens. To date, more than 46 types of imported IBD vaccines are used for the control of the disease in West Malaysia (Chin, 1993). They are subjectively classified into the "mild", "intermediate" and "hot" strains of attenuated live IBD vaccines based on their pathogenecity and immunogenicity. "Mild" vaccines are low in their invasiveness of the bursa of Fabricius and may easily be neutralized by high maternally derived antibody (MDA) (Winterfield and Thacker, 1978). "Intermediate" and "hot" vaccines are high in invasiveness and even with the presence of MDA (Haffer, 1982). The standard and ideal criteria for safety and potency of attenuated live IBD vaccine have been suggested previously (Thornton and Pattison, 1975). The vaccine should cause no clinical effects when administered at day old and confer protection within 10 days of vaccination. The vaccine also should cause no more than slight and temporary reduction in the bursa to body weight ratio with partial and temporary lymphocytes depletion in the bursa and no significant immunosuppression effects.

Intraocular and oral routes via drinking water are the common routes for IBD vaccination in commercial broiler chickens. Subcutaneous or vent-drop administration was also been reported to be effective against IBDV challenged (Winterfield and Thacker, 1978). The effectiveness of in-ovo vaccination in 18-day-old embryonated chicken eggs, at time the eggs are routinely transferred to hatching tray, was reported previously (Hair-Bejo *et al.*, 2000). In-ovo

vaccination can eliminate the need for post hatch vaccination that is stressful to the chicks. In free-range chickens, feed based vaccine is believed to be the best route of vaccination. Food pellet Newcastle disease vaccine was successfully developed previously (Aini, 1989). However, the safety and immunogenicity of the IBD vaccine through feed is unknown. The characteristic of IBDV which is non envelope virus, very stable to chemical and physical agents and can remain for long in environment are of advantages when use as feed based vaccine. It was the objective of the study to determine the safety and immunogenicity of an attenuated live "intermediate" strain IBD vaccine of Malaysian isolate given to broiler chickens via feed.

Materials and Methods

Experimental chickens: One hundred twenty day old broiler chicks were reared in slatted floor experimental house. Feed and water were given ad libitum and any clinical abnormalities were recorded. The chicks were randomly divided into 3 groups namely: group A (feed based IBD vaccination), group B (IBD vaccination via intraocular route), and group C (control). They were reared in separate experimental house started at day 14 of age. The chickens in groups A and B were vaccinated at day 14 with an attenuated live "intermediate" strain IBD vaccine of Malaysian isolate ($10^{4.5}$ EID₅₀/0.1ml) via feed (about 0.1ml/chick) and intraocular routes (0.1ml/chick), respectively. Eight chicks in the control group were sacrificed at 1, 7, 14, 21, 28, 35 and 42 days of age. Eight chickens each from the groups A and B were sacrificed at 21, 28, 35 and 42 days of age. Body weights were taken and serum samples were collected for IBD antibody detection using enzyme linked immunosorbent assays (ELISA) prior to necropsy. On necropsy, the gross lesions were recorded and the bursa of Fabricius was weighed and fixed in 10 % buffered formalin for histopathological examination.

Method for Feed based IBD Vaccination: Thirty two 14-day-old chickens in the group A were estimated to received about 0.1 ml/chick of an attenuated live "intermediate" strain IBD vaccine of Malaysian isolate ($10^{4.5}$ EID₅₀/0.1ml). The chickens were off feed for 2 hours (7.00 a.m. to 9.00 a.m.) prior vaccination. The IBD vaccine was prepared by mixing the vaccine (3.6 ml) in feed (720 g) and offered to the chicken (9.00 am). Three hours later (12.00 noon) about 80% of the feed offered were eaten and the remaining feed was withdrawn, and the chickens were offered the normal diet.

Histopathology: The bursa tissues were fixed in 10 % buffered formalin, processed and stained with Haematoxylin and Eosin (HE). The tissues were examined using x4, x10 and x40 objectives for histological changes. The bursal lesions were subjectively scored as normal (0), mild (1), mild to moderate (2), moderate (3), moderate to severe (4) and severe (5) by a modified scoring method previously established (Hair-Bejo *et al.*, 2000).

IBD Antibody Titre: The enzyme linked immunosorbent assays (ELISA) technique was carried out according to the methods described by IDEXX Laboratories Incorporation, USA. Briefly, the antigen coated plates and the ELISA kit reagents were adjusted at room temperature prior to the test. The test sample was diluted to five hundred folds (1:500) with sample diluent prior to the assay. A 100 μ l of diluted sample was then put into each well of the plate. This was followed by 100 μ l of undiluted negative control into well A1 and A2, 100 μ l of undiluted positive control into well A3 and A4. The plate was incubated for 30 minutes at room temperature. Each well was then washed with approximately 350 μ l of distilled water for 3 times. Goat anti-chicken conjugate (100 μ l) was dispensed into each well. The plate was incubated in room temperature for 30 minutes, followed by washing each well with 350 μ l distilled water for 3 times. TMB solution (100 μ l) was dispensed into each well. The plate was then incubated at room temperature for 15 minutes. Finally, 100 μ l of stop solution was dispensed into each well to stop the reaction. The absorbance values were measured and recorded at 650nm. IBD antibody titre was calculated automatically, using software by Blankfard and Silk (Blankfard and Silk, 1989).

Statistical Analysis: Analysis of variance (ANOVA) was conducted using SPSS v.8.0 (Norusis,1997).

Results

Clinical Signs: No clinical signs of IBD were observed in all groups of chickens throughout the trial.

Body Weight: The body weights of the chickens from control group were significantly increased ($p < 0.05$) from day 7 (121.6 ± 4.2 g) to day 42 (1958.8 ± 64.7 g) (Fig. 1). The body weight of the chickens from groups A and B followed the same increment pattern throughout the trial. The differences among the body weight of the 3 groups were statistically insignificant ($p > 0.05$).

Gross Lesions: The gross pathological changes observed were confined in the bursa of Fabricius of the chickens in group A and group B at day 21 of age and thereafter. No gross lesion was found in the control group throughout

the trial. Some of the affected bursa in group A were oedematous with yellowish transudate covered the mucosal and serosal surfaces at day 21. Whitish necrotic spots on the mucosal surface of the organ were also observed. Some bursa of the chickens in group B showed slight elongation with mild serosal and mucosal oedema at day 21. At day 28, two of the bursa from the group showed mild serosal oedema. The bursa of chickens from groups A and B were generally smaller than the control group at day 21 and thereafter.

Bursa Weight: The bursa weight of the chickens from the control group was significantly increased ($p < 0.05$) from day 1 ($0.05 \pm 0.01g$) to day 28 (3.81 ± 0.23) and remained high thereafter (Fig. 2). The bursa weight of the chickens in group A was increased to 1.91 ± 0.21 at day 21 and remained no significantly different ($p < 0.05$) at days 28, 35 and 42. In group B, the bursa weight changes followed the same pattern as group A with 1.38 ± 0.20 at day 21 and remained no significantly different ($p > 0.05$) thereafter. The bursa weight of the chickens in groups A and B were not significantly different ($p > 0.05$), but were significantly ($p < 0.05$) lowered than the control group at day 21 and thereafter.

Bursa to Body Weight Ratio (10^{-3}): The ratio were increased gradually from day 1 (1.49 ± 0.17) to day 21 (3.71 ± 0.26) in control group (Fig. 3). The ratio was decreased significantly ($p < 0.05$) at day 28 (2.75 ± 0.19), but the decreased at day 35 and day 42 were not significant ($p > 0.05$). In the group A the ratio was decreased at day 21 (2.41 ± 0.24) and further decreased ($p < 0.05$) at day 28 (1.43 ± 0.27). The ratio for day 35 and day 42 were not significantly ($p > 0.05$) differ from day 21. The ratio changes in group B followed the same pattern of group A. The ratio was decreased at day 21 (1.87 ± 0.31) and further decreased ($p < 0.05$) to 0.92 ± 0.08 at day 28. However, ratio at day 35 and day 42 were not significantly ($p > 0.05$) differing from day 28. Throughout the post vaccination period, the ratio for group A and group B were significantly ($p < 0.05$) lower than the control group, but were not significantly different ($p < 0.05$) between the two groups.

Histological Lesions: The histological lesions of bursa of Fabricius in the control group remained normal to mild throughout the trial (Fig.4). The lesions scores in group A remained moderate throughout the first 21 days of post vaccination period (2.38 ± 0.26 , 2.50 ± 0.19 and 2.63 ± 0.26 at days 21, 28 and 35 of age, respectively) and mild to moderate lesions was observed at day 42 (2.00 ± 0.27). The lesions score at day 21 for group B increased to 3.25 ± 0.41 (moderate). At day 28, the lesions score was decreased significantly ($p < 0.05$) to 2.63 ± 0.18 and further decreased to 2.25 ± 0.25 at day 35. The lesions score at day 42 remained mild to moderate (1.50 ± 0.27).

IBD Antibody Titre: The IBD antibody titre for control group decreased significantly ($p < 0.05$) from day 1 (3894 ± 299) to day 14 (341 ± 126) and persisted to the lower level at day 21 (53 ± 19) and thereafter (Fig. 5). The antibody in group A started to rise at day 21 (844 ± 196) and further increased at day 35 (1626 ± 303) and day 42 (2049 ± 391). The antibody titre for group B started to increase to 248 ± 62 , 489 ± 101 , 1426 ± 304 and 2658 ± 423 at days 21, 28, 35 and 42, respectively. The antibody titre in group A was significantly higher ($p < 0.05$) than control group at days 28, 35 and 42. The group B had days 35 and 42 significantly higher ($p < 0.05$) than control group. The antibody titre between groups A and B was not significantly ($p > 0.05$) different throughout the trial.

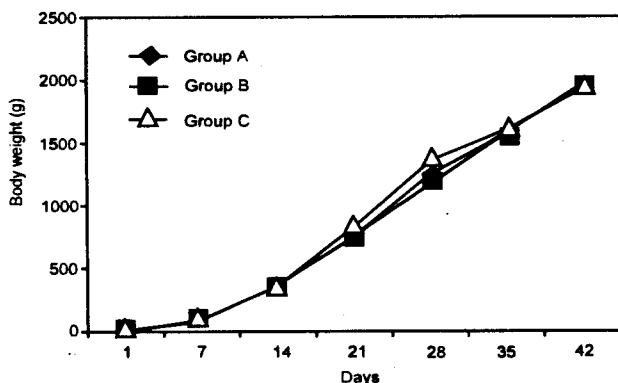


Fig. 1: Body weight of the chickens throughout the trail

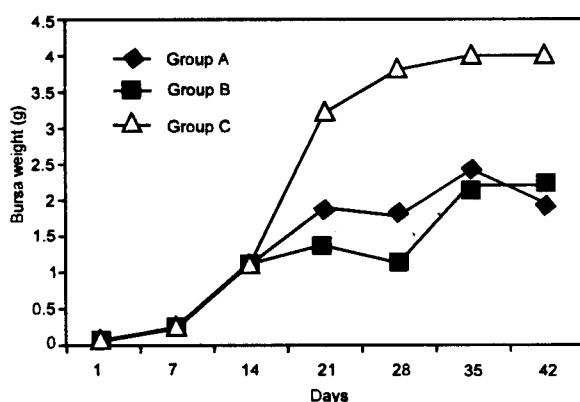


Fig. 2: Bursa weight of the chickens throughout the trial

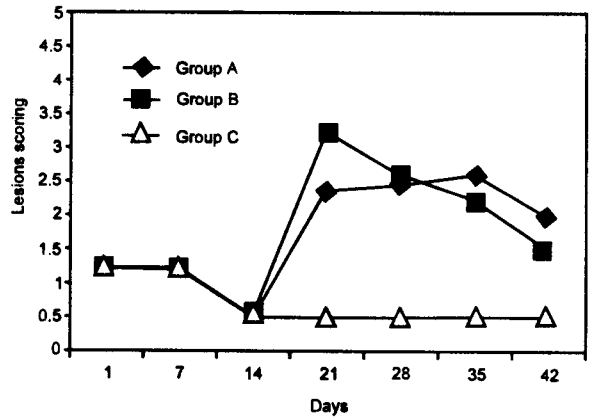
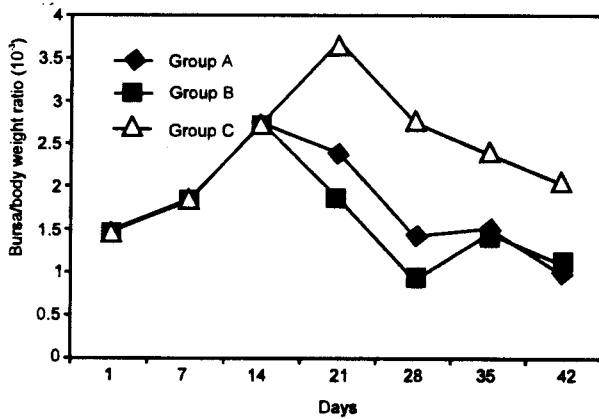


Fig. 3: Bursa to body weight ratio of the chickens throughout the trial

Fig. 4: Bursa of Fabricius lesions scoring throughout the trial

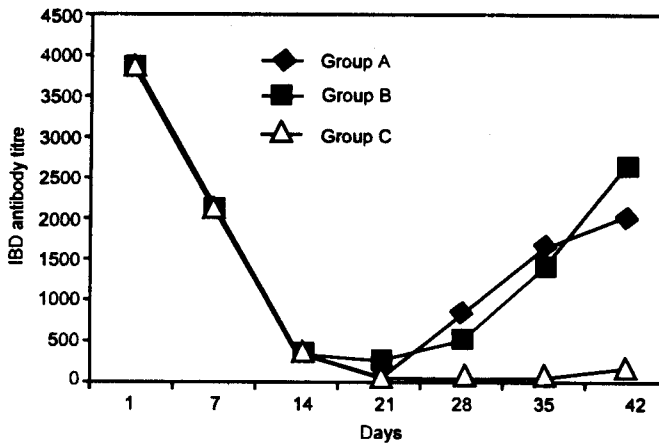


Fig. 5: IBD antibody titre of the chickens throughout the trial

Discussion

The study showed that an attenuated live "intermediate" strain IBD vaccine of Malaysian isolate is safe and effective to be used as feed based vaccination at 14-day-old commercial broiler chickens. The vaccination did not affect body weight or performance of the chickens when compared to the intraocular and the control groups. The bursa weight and bursa to body weight ratio of the feed and intraocular vaccination groups were lower than the control group indicated that there were lymphoid tissue reactions in the bursa towards the invasion of the vaccine virus. However, the changes is reasonable for an "intermediate" IBD vaccine that still maintained certain degree of its pathogenicity which caused mild gross lesions in the bursa of Fabricius, but absent of any clinical signs of IBD in the chickens. Certain degree of virulence is importance for "intermediate" strain of IBD vaccine which enables the vaccine virus to penetrate or neutralize MDA especially when given in the early age of the chickens. It is interesting to note on the pattern of lesions scoring recorded in groups A and B. It appears that the multiplication of virus in bursa was far more rapid and causing more damage in intraocular route of vaccination at first week post vaccination when compared to feed based vaccination. The bursa lesion scoring in the group A was mild to moderate (2.38 ± 0.26), whilst moderate lesion scoring (3.25 ± 0.41) was recorded in group B. Recovery of the bursa of Fabricius was evident in both group at day 42. Following feed based vaccination, the vaccine virus may replicates principally in the B-lymphocytes and macrophages in the gut associated lymphoid tissue leading to primary viraemia as those suggested previously, following oral route of IBD vaccination (Weiss and Kaufer, 1994). The virus was then localized and replicate massively in the bursa of Fabricius, the main target organ for IBDV leading to the induction of high and protective level of IBD antibody (with ELISA titre of above 1000). The study showed that the feed based vaccination (1626 ± 303) can induce protective level of IBD antibody as high

as the intraocular route (1426 ± 304) at day 35 of age and thereafter (at day 42). Thus, feed based vaccination can be of choice and more practical when compared to other conventional routes of vaccination for IBD in the control and prevention of IBDV infection in free-range chickens such as in village chickens or chickens kept under organic farming system. Losses due to IBD outbreaks were reported previously in village chickens in Poland (Minta and Daniel, 1994) and Malaysia (Thu-Zar, 1996) and in free-range broilers in France in 1993 (Drouin *et al.*, 1994). In Panisular Malaysia the standing population of village chickens is about 6.56 million (Supramaniam, 1987). The traditional system of poultry keeping is still considered quite efficient in the rural areas. The capital and labour inputs are extremely low, so that even though production levels are low, the actual costs of production per egg or per bird produced are negligible. The indigenous chickens are usually fed once or twice a day with kitchen leftover such as rice or used coconut pulp. They are also fed any food material that is cheap and easily available in the village. Some farmers provide supplementary commercial in very limited amount or grains such as broken maize, broken rice, rice bran or wheat. For the rest of the day, the chickens are free to find their own food (Aini, 1989).

It was concluded that the feed based IBD vaccination at 14-day-old broiler chickens using attenuated live "intermediate" strain IBD vaccine of Malaysian isolate is safe and successfully induce protective level of IBD antibody.

References

- Aini, I., 1989. Vaccination of village chickens against Newcastle disease. Ph D Thesis, University Pertanian Malaysia, Malaysia.
- Blankford, M. and B.C. Silk, 1989. ELISA Software, KPL, Gaithersburg, Md., USA.
- Chin, P.H., 1993. List of approved animal vaccines and biologics for importation, sales and use in West Malaysia. First Edition. Veterinary Association Malaysia.
- Congrove, A.S., 1962. An apparently new disease of chickens - Avian nephrosis. *Avian Diseases*, 6:385-389.
- Drouin, P., J.Y. Toux, J.P. Picault, N. Etteradossi, M. Guittet and A. Bennejean, 1994. Epidemiology of infectious bursal disease in France. Proceedings of International Symposium on Infectious Bursal Disease and Chicken Infectious Anemia, June 21-24 1994, Reuschholzhausen, Germany, pp:215-218.
- Haffer, K., 1982. Field test studies of the 2512 strain of infectious bursal disease. *Avian Diseases*, 26:847-851.
- Hair-Bejo, M., 1992. An outbreak of infectious bursal disease in broilers. *Jurnal Veterinar Malaysia*, 4:168.
- Hair-Bejo, M., 1993. Infectious bursa disease in broilers: pathological changes and virus detection. *Jurnal Veterinar Malaysia*, 5: 49-51.
- Hair-Bejo, M., S. Salina, H. Hafiza and S. Julaida, 2000. in ovo vaccination against infectious bursal disease in broiler chickens. *Jurnal Veterinar Malaysia*, 12: 63 -69.
- Minta, Z. and A. Daniel, 1994. Epidemiology of infectious bursal disease in France. Proceedings of International Symposium on Infectious Bursal Disease and Chicken Infectious Anemia, June 21-24 1994, Reuschholzhausen, Germany, pp:208-214.
- Norusis, M.J., 1999. SPSS base system user's guide version 10.0. SPSS Inc., Chicago.
- Phong, S.F., M. Hair-Bejo, A.R. Omar and I. Aini, 2003. Sequence analysis of Malaysian infectious bursal disease virus isolate and the use of reverse transcriptase nested polymerase chain reaction enzyme-linked immunosorbant assay for detection of VP2 hypervariable region. *Avian Diseases*, 47:154-162.
- Supramaniam, P., 1987. Malaysia: Poultry Production. Newcastle Disease in Poultry. Copland, J.W. (Editor). A new food pellet vaccine. ACIAR Monograph No.5, Canberra. pp: 81-82.
- Thorton, D.H. and M. Pattison, 1975. Comparison of vaccine against infectious bursal disease. *J. Comparative Pathology.*, 85:597-610.
- Thu Zar, T. and H. Hafiza, 1996. Isolation, identification and pathogenecity studies of local isolates of IBD virus. Master Thesis, University Pertanian Malaysia, Malaysia.
- Weiss, E. and I. Kaufer-Weiss, 1994. Pathology and pathogenesis of infectious bursal disease. Proceedings of International Symposium on Infectious Bursal Disease and Chicken Infectious Anemia, June 21-24 1994, Reuschholzhausen, Germany, pp:116-118.
- Winterfield, R.W. and H.I. Thacker, 1978. Immune response and pathogenecity of different strains of infectious bursal disease virus applied as vaccine. *Avian Diseases*, 22:721-731.