

Evaluation of Ethyl Alcohol in Treatment of Cystic Echinococcosis Using Puncture, Aspiration, Introduction, Reaspiration (PAIR) Technique

¹P. M. F. Mbithi, ^{1,2}E.M. Njoroge, ¹J.M. Gathuma, T. M. Wachira,
³J. K. Magambo, ¹S. Njiru, ²E. Zeyhle

¹University of Nairobi, P.O. Box 29053, Nairobi, Kenya

²African Medical and Research Foundation (AMREF), P.O. Box 30125, Nairobi, Kenya

³Institute of Tropical Medicine and Infectious Diseases, KEMRI, Nairobi, Kenya

Abstract: This study was carried out to evaluate the effect of 95% ethyl alcohol in PAIR technique. Animals with natural infection were randomly divided into two groups. In the test group, cysts (n=7) were punctured, cyst fluid drained and injected with 95% ethyl alcohol while in the control group, cysts (n=9) were only punctured and cysts fluid drained. The procedure was done under ultrasound guidance. Ultrasound showed collapse of endocysts after cyst puncture in both groups. One month later, there was decrease in cyst size, increased echogenicity and complete or partial detachment of the endocyst. Post mortem examination of the cysts in test group showed gross degeneration with marked fibrosis of the surrounding liver tissue. Incision of the cysts revealed turbid yellow cystic contents and degenerated endocysts. Microscopically, only debris and dead protoscoleces with detached hooks were seen. In the Control group, the cysts appeared grossly intact but flaccid. Incision of the cysts showed clear fluid with intact endocysts. However, microscopic examination of the cyst fluid showed that the protoscoleces were dead with detachments of hooks. In the test group, histopathology showed marked host cell reaction consisting of infiltration of the adventitial layer with neutrophils, eosinophils and plasma cells. In addition, the liver tissue was destroyed and replaced with young fibroblasts and mesenchymal cells. In the control group, histopathology showed detachment of the laminate layer of the cyst from the adventitia, inflammatory cells in both the adventitia and the liver tissues. However the degree of inflammation was markedly less in the control than in the test group. The findings suggest that puncture alone may be sufficient to kill the protoscoleces, possibly due to detachment of the endocyst from the host wall.

Key words: Cystic echinococcosis, PAIR, ethyl alcohol, sheep, goats

Introduction

In the past, the puncture of echinococcal cysts in humans was strongly discouraged because of risks of anaphylactic shock and spillage of the fluid with subsequent peritoneal seeding of protoscolices to form new cysts. However, with numerous cases of either accidental or deliberate *Echinococcus* cyst puncture (Brunetti *et al.*, 1995; Salama *et al.*, 1995 and Akhan *et al.*, 1996), these risks have not been reported. Minor complications such as pruritus, rash and abdominal pain have been reported in 0.5% - 22% of the cases (Bret *et al.*, 1988 and Xiaozhi *et al.*, 1994). Puncture of the *Echinococcus* cyst and aspiration of the cyst fluid, coupled with addition of a scolicidal solution to kill the protoscolices, has therefore become one of the surgical techniques used in treatment of cystic echinococcosis in humans (Filice and Brunetti, 1997 and Zeyhle, 2000).

Some of the scolicidal agents that have been used to kill the protoscoleces include cetrimide bromide, hypertonic saline, hydrogen peroxide and ethyl alcohol. Whereas cetrimide bromide has been effective against protoscoleces, it has been reported to have an adverse effect of causing methaemoglobinuria (Barake *et al.*, 1980). Hydrogen peroxide has equally been effective but is known to cause collapse of the patient after injection (Belghiti *et al.*, 1986). Use of hypertonic saline is not known to have any side effects but a 4% rate of recurrence was reported (Gargouri *et al.*, 1990). In experimental animals using rats, hypertonic saline caused mortalities of 70-90%. Some rats had convulsions due to intracranial bleeding, necrosis and myelinolysis (Kayaalp *et al.*, 2001). However, detailed information on the efficacy and possible adverse effects of ethyl alcohol when used in Puncture, aspiration, introduction and re-aspiration (PAIR) technique is lacking. The aim of this study was to evaluate 95% ethyl alcohol, (the concentration used in humans) in the PAIR technique using sheep and goat models.

Materials and Methods

PAIR Procedure: Hair was shaved from the abdomen of sheep and goats and a coupling gel applied. Ultrasound examination was performed with a real time B-mode scanner with a 3.5 MHz linear assay transducer with electronically variable focus. Scan images were recorded on a graphic printer.

Each animal was then put under heavy sedation, using 0.5mg/kg bwt xylazine HCl (Xylalin[®], Apharmo B.V. Netherlands) IV and 0.025mg/kg bwt atropine sulphate given SC to minimise hypersalivation. Each animal was also given 0.8mg/kg bwt Dexamethasone (Agrar[®])(Agrar, Holland B.V.) to control possible anaphylactic shock due to cyst rupture and 20mg/kg bwt tetracycline to control cyst infection. The animal was then covered with sterile drapes to minimise external contamination. Contamination of the surgical site by ultrasound transducer was minimised by wiping the surfaces with a swab containing 70% surgical spirit. After locating the *Echinococcus* cyst with ultrasound, a stab incision was made on the skin to allow penetration of the canula. An 18G 6-inch metallic canula was used to puncture the cyst per cutaneously under ultrasound guidance (Fig. 1). The canula was attached to a 60ml syringe and the cyst fluid was aspirated with the syringe. The aspirated cyst fluid was stored in sterile kidney dish and examined in the laboratory within 15 minutes. The cyst fluid aspirated was replaced with 95% ethyl alcohol. The alcohol introduced into the cyst was left for 20 to 30 minutes before reaspiration of the cyst fluid/alcohol mixture. The animals were then maintained for one month before scanning with ultrasonography to determine the changes in shape and size of the cysts.

Animals in the control group were subjected to similar treatment as those in the test group except that no ethyl alcohol was introduced into the cyst. Puncture of the cysts was done in a similar manner to the test group and the cyst fluid aspirated. The cysts were then left

without introducing any scolicedal reagent. The animals were maintained for one month under close observation. After one month, ultrasound scanning was carried out and then animals euthanised for post mortem examination.

Laboratory analysis of the cyst fluid: Aspirated fluid from the cyst was examined under a light microscope at low magnification (X40). Viability of the protoscoleces was determined by flame cell motility and eosin dye exclusion (Macpherson, 1981).

Interpretation of the findings: Both ultrasound appearance and post mortem findings were used to evaluate the efficacy and possible adverse effects of 95% ethyl alcohol. Each cyst was examined as a separate entity and the overall interpretation was based on the findings of all the cysts. A comparison of the treatment group and the controls was carried out using cysts subjected to puncture and 95% ethyl alcohol as test group and cysts subjected to puncture alone as controls. Interpretation of post mortem findings was based on both gross and microscopic observations of the cyst and liver tissues.

Results and Discussion

A total of 6 animals (4 sheep and 2 goats) were used in this study. The animals were randomly divided into 2 groups of 3 (2 sheep and 1 goat each group) and allocated as either test or control. In the test group, cysts (n=7) were punctured and injected with 95% ethyl alcohol while in the control, cysts (n=9) were only punctured.

Ultrasound findings: In both test and control groups there was collapse of the endocyst after cyst puncture. One month later, the cysts showed decrease in size, increased echogenicity and complete or partial detachment of the endocyst (Fig. 2).

Post mortem findings: In the test group, the cysts were grossly degenerated with marked fibrosis of the surrounding liver tissue. Incision of the cysts revealed turbid yellow cystic fluid and degenerated endocysts. On microscopic examination of the cyst fluid, the protoscoleces were dead, with detached hooks. In the control group, the cysts appeared grossly intact but flaccid. Incision of these cysts showed clear fluid with intact endocysts. However, microscopic examination of the cyst fluid showed that the protoscoleces were dead with detachments of hooks.

Histopathological findings: In all the cysts injected with 95% ethyl alcohol there was marked host cell reaction consisting of infiltration of the adventitial layer with neutrophils, eosinophils and plasma cells. In addition, the liver tissue was severely destroyed and replaced with young and disorganized fibroblasts and mesenchymal cells. In most necrotic areas, the laminate layer could not be collected together with adherent liver tissue and the adventitial layer appeared completely degenerate and was replaced by acute inflammatory cells.

In the cysts where puncture alone was carried out, there was detachment of the laminate layer of the cyst from the adventitia. Additionally, inflammatory cells were observed in the adventitia and the liver tissues. However the degree of inflammation was markedly less than in the test group. Inflammatory cells were identified only in small parts of the liver tissues while most of the tissues were intact with hepatocytes being predominant in an organised appearance.

In the past, 95% ethyl alcohol has been assumed to be a safe scolicedal agent for use in human patients. It has been widely used in the PAIR technique in different hospitals (Filice *et al.*, 1999). However, its safety and possible adverse side effects have not been adequately studied (Palowski, 1997 and Filice *et al.*, 1999). One of the difficulties that studies in humans are faced with is that once treated, a human being cannot be subjected to surgery to study the side effects of a scolicedal agent.

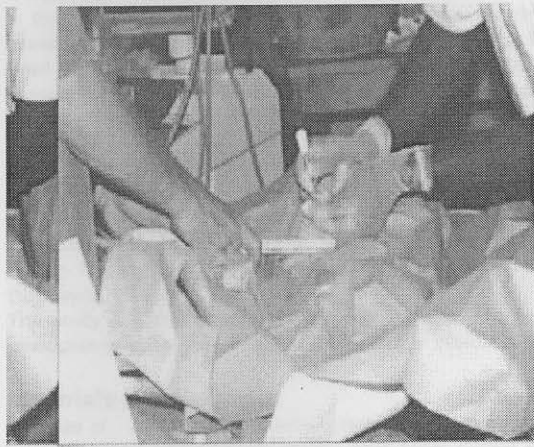


Fig. 1: Puncture of *Echinococcus* cyst under ultrasound guidance

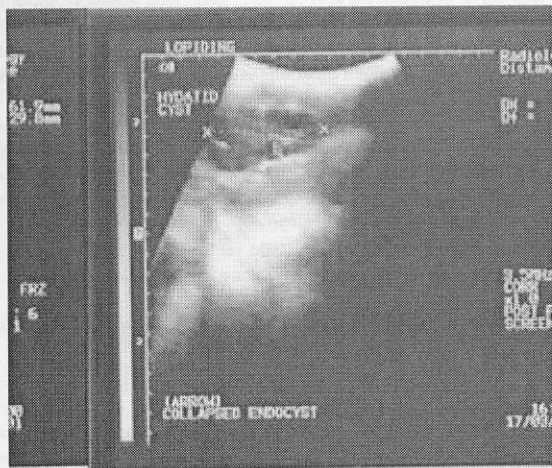


Fig. 2: A sonogram of an *Echinococcus* cyst after puncture shows collapsed endocyst (arrow)

The only indicator of any side effects of a scolicedal agent would be deterioration of the patient and the clinical picture. This difficulty can only be overcome by using an appropriate animal model where a post mortem examination can be carried out. The present study is one of the first studies of the effects of 95% ethyl alcohol using sheep and goat models.

In the present study, all the cysts subjected to puncture and 95% ethyl alcohol injection were severely degenerated and the protoscolices were dead, a desired outcome for any scolicidal agent. However, it adversely caused severe damage of liver tissues, a feature reflected by, grossly, severe fibrosis and, by histopathology, marked infiltration of the tissues by inflammatory cells that replaced normal hepatocytes. This was absent in the control group where the protoscolices were also dead as a result of puncture alone. These findings suggest that 95% ethyl alcohol may be causing severe liver damage in human patients who are subjected to the PAIR technique. What may not be clear from the present study is whether the damage to the liver by 95% ethyl alcohol significantly affects its functions and whether the liver is able to heal and resume its efficiency in function. The findings also suggest that puncture alone may be sufficient to kill the protoscolices, possibly due to detachment of the endocyst from the host wall.

Acknowledgements

This Study was funded by DAAD Germany.

References

- Akhan, O., M. N. Ozmen, A. Dincer, Y. Sayek and A. Gocmen, 1996. Liver hydatid disease: Long-term results of percutaneous treatment. *Radiology*, 198: 259-262
- Barake, A., F. Yamut, N. Wakid, 1980. Cetrimide-induced methemoglobinuria after surgical excision of hydatid cysts. *Lancet*: (ii) 88
- Belghiti, J., R. Lesage and F. Feket, 1986. Collapsus pre-operatoire apres ijection d'eau oxygenee dans un kyste hydatique hepatic. *Le Presse Medicale*, 15: 136
- Bret, P. M., A. Fond, E. Bretagnolle, P. J. Valette, P. H. Thiesse, R. Lambert and M. Labadie, 1988. Percutaneous aspiration of and drainage of hydatid cysts in the liver. *Radiology*, 168: 617-620
- Brunetti, E., M. Tinelli, C. Meloni, F. D'Andrea and C. Filice, 1995. P.A.I.R: State of art. Abstracts of the XVII International congress of hydatidology. 6-10 Limassol, Cyprus
- Filice, C. and E. Brunetti, 1997. Use of PAIR in human cystic echinococcosis. *Acta Tropica*, 64: 95 – 107
- Filice, C., E. Brunetti, F. Crippa and R. Bruno, 1999. Treatment of echinococcal abdominal cysts. *Ultrasound Quarterly*, 15: 223-233.
- Gargouri, M., N. Ben Amor, F. Ben Chehida, 1990. Percutaneous treatment of hydatid cyst (*Echinococcus granulosus*). *Cardiovascular Intervention Radiology*, 13: 169-173
- Kayaalp, C., M. Balkan, C. Aydin and M. Pakcan, 2001. Can hypertonic saline be used as a scolicidal agent for irrigation of intra-abdominal perforation of hydatid disease? XXth International Congress of hydatidology 4-8 June 2001. *International Archives of the Hydatidosis*, 214
- Salama, H., M. F. Abdel-Wahad and G. T. Strickland, 1995. Diagnosis and treatment of hepatic hydatid cysts with the aid of echo-guided percutaneous puncture. *Clinical Infectious Diseases*, 21: 1372-1376
- Palowski, Z. S., 1997. Critical points in the clinical management of cystic echinococcosis: A revised review. In *Compendium on cystic Echinococcosis in Africa and in Middle Eastern Countries with special reference to Morocco*, edited by Andersen F. L., Ouhelli, H. and Kachani, M. Brigham Young University, Provo, UT 84602, USA, 119-135
- Xiaozhi, W., L. Yongshou, F. Sheng, Y. Shengen, 1994. Clinical treatment of hepatic and abdominal hydatidosis with percutaneous puncture drainage and curretage. (Report of 869 cases). *Chinese J. Parasitology and Parasitic Diseases*, 12: 285 – 287