

Oral Administration of Lasalocid Causes Peripheral Neuropathy in Sprague Dawley Rats: Effect of Water Salinity on Lasalocid-induced Peripheral Neuropathy

¹Asim Kart, ²Stanley Leon Vanhooser, Subbiah Sangiah

¹Department of Physiological Sciences; ²Animal Disease Diagnostic Laboratory,
College of Veterinary Medicine, Oklahoma State University, OK, USA

Abstract: Lasalocid toxicity was associated with several neurotoxicity cases in animal species. Incidence of lasalocid neurotoxicity shows a higher rate in chickens during heat stress with increased water salinity. In the present study, It studied the effect of lasalocid with or without 0.9 % NaCl in male Sprague Dawley. The rats were given 0, 10, 20, 40 mgkg⁻¹ of lasalocid two times a day for 3 days with or without 0.9 % saline in the drinking water. Rats showed ataxia in the 20 and 40 mgkg⁻¹ dose groups with higher death rate in group receiving 40 mgkg⁻¹ of lasalocid. Dietary salt did not affect ataxia induced by lasalocid. While the optimum dose to produce ataxia (without high mortality) appears to be 20 mgkg⁻¹ of lasalocid, increasing salinity of water has no effect on the neurotoxicity of lasalocid.

Key words: Lasalocid, ataxia, neurotoxicity, heat stress, salinity

INTRODUCTION

A number of toxicity cases have been reported in horses, cattle, sheep, cat, pig and avian species^[1,7]. Ionophores are generally safe and effective if used at recommended levels. However, ionophore toxicity might occur due to accidental overdose, misuse and mixing errors in the ration^[7]. Lasalocid (LA) is a polyether ionophore which is used to prevent coccidiosis in poultry and to increase feed efficiency in ruminants. When administered above therapeutic levels, LA can induce toxicity in animal species^[1]. Ingestion of cat food which was accidentally contaminated with the ionophore salinomycin resulted in outbreak of acute polyneuropathy in the Netherlands in 1996^[5]. Clinical symptoms of the affected cats were acute lameness and paralysis of hindlimbs followed by forelimbs. Histopathologic examination of the affected cats showed that peripheral nerves of both hind- and forelimbs were affected. The changes included swelling, fragmentation and loss of axon and digestion chambers in myelin^[5]. Furthermore, Gregory *et al.*,^[2] reported that chickens fed a ration containing LA under heat-stressed conditions had lesions in the sciatic nerve including swollen and shrunken axons and also vacuole formation in the myelin sheath.

Several studies reported toxic effect of ionophores in rodent species. Gad *et al.*,^[9] reported that some ionophores including LA caused central and peripheral nervous system effects leading to tonic and clonic convulsions and aggressive behaviors in CD-1 mice and Fisher 344 rats.

In the poultry industry, it is known that incidence of

LA toxicosis is higher during the hot summer period with increased water salinity. With the combination of environmental stress factors, increased temperature and water deprivation may play a role for higher rate of LA neurotoxicity and cardiotoxicity^[8]. Therefore, we investigated also the effect of 0.9 % NaCl in drinking water on LA toxicity in rats.

MATERIALS AND METHODS

Twenty eight male Sprague Dawley rats with approximate body weight 175-200 g (46-49 day-old) were obtained from a commercial source (Harlan, Oregon, WI). All rats upon arrival were acclimatized 7 days before the start of experiment and food and water were provided ad libitum. Following the acclimatization period, the rats were divided into 8 Groups containing 4 rats each. Two days before the experiment, water was discontinued and 0.9 % NaCl solution was given to groups 2, 4, 6 and 8 until the end of experiment.

Lasalocid (Sigma Chemical Company, MO, USA) dissolved in dimethyl sulfoxide (Sigma Chemical Company, MO, USA) was given (2 times a day for 3 days by gavage) with or without 0.9 % NaCl in the drinking water to group 1 (0 mgkg⁻¹ LA), group 2 (0 mgkg⁻¹ LA+ 0.9 % NaCl), group 3 (10 mgkg⁻¹ LA), group 4 (10 mgkg⁻¹ LA+ 0.9 % NaCl), group 5 (20 mgkg⁻¹ LA), group 6 (20 mgkg⁻¹ LA+ 0.9 % NaCl), group 7 (40 mgkg⁻¹ LA) and (40 mgkg⁻¹ LA+ 0.9 % NaCl),

Starting from day 1, all rats were observed daily 2 times a day until they were sacrificed (day 8). All treatment groups were evaluated for the development of

ataxia and behavioral changes. Individual rats were graded blind to assign an ataxia score. Each rat was placed on the ground and allowed to acclimate to the environment for a couple of minutes. Then the rats were observed without further disturbance for behavioral changes. To determine gait abnormalities and degree of ataxia, the rats were allowed to move freely. Then they were forced to walk to detect slight ataxia and to determine if the degree of ataxia increased. Ataxia scores were given according to clinical ataxia scoring system as follows: No ataxia (score 1), Slight ataxia (score 2), ataxia (score 3), non-ambulatory but alert (score 4), non-ambulatory but not alert (score 5).

Determination of foot splay was carried out by the method of Edwards and Parker (1977). Briefly, both feet were pressed onto an inkpad, and the rat was held horizontally in dorso-ventral position with the body 32 cm above the surface of a table. The rat was then released from the top, and the distance between the ink marks was measured upon landing. The procedure was repeated 3 times for each rat and the average of 3 readings was used, and analysis of variance procedure was used to test statistically significant difference among the groups ($p < 0.05$).

For the histopathological examinations, the rats were killed in a CO₂ chamber. The sciatic nerve were dissected and fixed in 2.5 % buffered glutaraldehyde. Sections of skeletal muscle were taken and placed in fixative. Sections for histopathologic examination were embedded in paraffin, cut 4-6 μm thick and stained with hematoxylin and eosin (H andE). All sections of tissue were examined by light microscopy and lesions scored blind.

RESULTS

Table I shows the median ataxia scores in the characterization of oral dose response and effect of dietary salt on lasalocid toxicity in male Sprague Dawley rats. Rats in control groups (0 mgkg⁻¹ of LA with or without 0.9 % NaCl solution) appeared normal clinically. All rats in these groups were active and alert, and showed

Table 1. Median Ataxia scores and mean foot splay distance in the treatment groups

Groups	Median Ataxia Score	Mean foot splay distance (cm)
1	0	8.3
2	0	7.8
3	0	6.9
4	0	8.7
5	1	8.4
6	1	7.2
7	3	7.8
8	3	8.7

No difference among the treatment groups in mean foot Splay distance, $p < 0.05$.

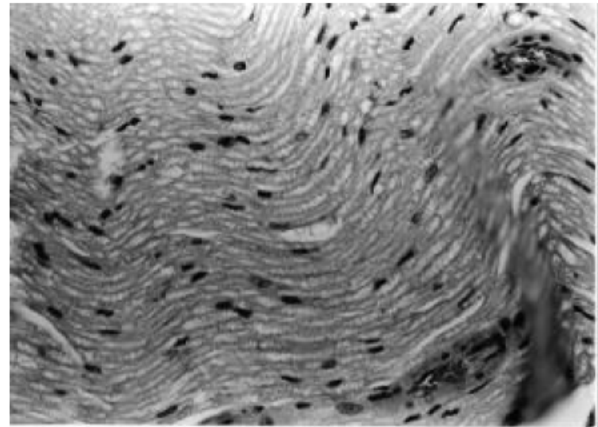


Fig.1: Light micrograph of a sciatic nerve from an ataxic rat treated with lasalocid. Vacuolation of myelin sheath (Arrow). (H andE, X 200)

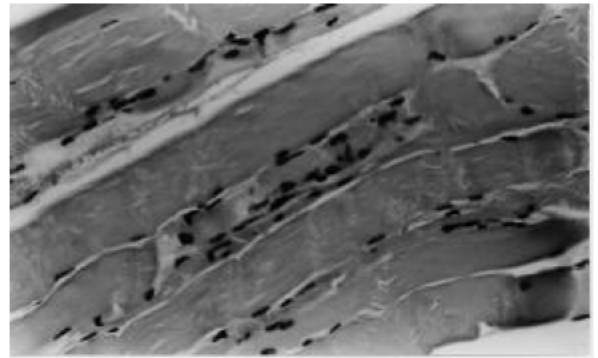


Fig.2: Light micrograph of a muscle tissue from a rat treated with lasalocid (40 mgkg⁻¹ 2 times a day for 3 days) and 0.9 % NaCl in drinking water. Necrosis of the tissue with loss of striation and fragmentation of myofibers (Arrows) (H andE, X 200)

no behavioral changes or gait abnormalities. No mortality was observed. While only one rat LA (10 mgkg⁻¹ in DMSO 2 times for 3 days + 0.9 % NaCl) in 10 mgkg⁻¹ LA dose-group showed ataxia with the score of 2, remaining rats in this dose group appeared normal (Fig. 2). Some rats treated with 20 and 40 mgkg⁻¹ of LA with or without 0.9 % NaCl solution (Group 5, 6, 7 and 8) developed ataxia. Ataxia was more prominent in groups treated with 40mgkg⁻¹ LA with or without 0.9 % NaCl solution. Some rats in these groups developed diarrhea following the next day (day 2) of LA treatment. Clinically affected rats were reluctant to move and less active compared to controls and the rats given 10 mgkg⁻¹ LA with or without NaCl. Rats with ataxia scores 4 had difficulty to stay erect with no righting reflex. Rats in this condition were unable to move hind limbs; however they attempted to move with

front legs. Foot-splay determination showed that no difference was present between control rats and the treatment groups (Table 1). Mean foot-splay values of ataxic birds were similar to the controls and were not affected by the treatment.

Figure 1 shows a light micrograph of a sciatic nerve from an ataxic rat treated with lasalocid (20mgkg⁻¹ 2 times a day for 3 days). Lesions were minimal and consisted of random vacuolation of myelin sheets. Mild necrosis of skeletal muscle was observed. In the affected areas, loss of striation, fragmentation, hypertrophic satellite cells and edema between myofibers were present. Muscle lesions were only present in groups treated with the highest dose group of lasalocid (40 mg/kg) with 0.9 % NaCl in drinking water. No muscle lesions were observed in any other groups.

DISCUSSION

In present studies, LA (20 mg/kg, p.o., 2 times a day for 3 days) induced slight to moderate ataxia in rats. At this dose, no mortality was observed and it can be suggested that 20 mgkg⁻¹ of lasalocid given by oral gavage 2 times a day for 3 days is the optimum dose to produce ataxia in male Sprague Dawley rats. It is known that incidence of LA toxicosis is higher with increased water salinity in broiler chickens during hot summer period. With the combination of environmental stress factors, increased temperature and water deprivation may play an important role for higher rate of LA neurotoxicity^[8]. Addition of 0.9 % NaCl in drinking water had no effect on neurotoxicity of lasalocid in rats. Although we did not observe any detrimental effect of 0.9 % of NaCl in drinking water, the percentage of NaCl used in this study may not be sufficient to produce additional effect on lasalocid neurotoxicity. Increasing NaCl ratio or water deprivation may be needed to see enhanced toxic response. The field reports indicating the effect of increased water salinity on LA neurotoxicity might be related to disruption of intracellular elemental composition of Na⁺ and Ca⁺⁺. There is increasing evidence that the structural and functional consequences of variety of injury processes to target cells might be mediated by a disruption of intracellular distribution of Na⁺, K⁺ and Ca⁺⁺ and water regulation (MacKnight^[11]). Using electron probe X-ray microanalysis, it was demonstrated that a correlation exists between cellular morphological structure and elemental composition and water content^[12]. It has been shown that various types of neuropathies caused by drugs, toxins and diabetes can be mediated via disruption of subcellular elemental composition of Na⁺, K⁺ and Ca⁺⁺ in the peripheral nerves. It was hypothesized that there is an

increase in intra-axonal Na⁺, preceded by an inhibition of Na⁺-K⁺-ATPase activity leading to reduced conduction of nerve impulses. Furthermore, it was also suggested that accumulation of increased axoplasmic Ca⁺⁺ may be responsible for peripheral nerve axon damage and degeneration resulting from several types of injury as it is seen in acrylamide toxicity and transection^[12,16]. The increased intra-axonal Ca⁺⁺ is mediated by intracellular Na⁺ and subsequent influx of Ca⁺⁺ ions through reverse operation of Na⁺-Ca⁺⁺ exchanger^[16]. In addition, it was shown that in transected nerves, ultrastructural changes are mediated by Na⁺ and Ca⁺⁺ concentration in the media. Sodium in the media of damaged dendrites causes dilation of the Golgi cisternae and increased mitochondrial electron opacity similar to neurons incubated with monensin^[17].

CONCLUSIONS

In conclusion, the results of our study showed that LA induces ataxia and pathological changes in the sciatic nerve. Addition of 0.9 % NaCl in drinking water has no effect on ataxia induced by LA.

REFERENCES

1. Galitzer, S.J. and F.W. Oehme, 1984. A Literature review on the toxicity of Lasalocid, A Polyether antibiotic. *Vet. Human Toxicol.*, 26: 322-326.
2. Galitzer, S.J., S.M. Kruckenberg, J.R. Kidd, 1986. Pathological changes associated with experimental lasalocid and monensin toxicosis in cattle. *Am. J. Vet. Res.*, 47: 2624-2626.
3. Hanson, L.J., H.G. Eisenbeis, S.V. Givens, 1981. Toxic effect of Lasalocid in Horses. *Am. J. Vet. Res.*, 42: 456-461.
4. Oehme, F.W. and J.A. Pickrel, 1999. An Analysis of the Chronic oral toxicity of polyether ionophore Antibiotics in Animals. *Vet. Human Toxicol.*, 41: 251-257.
5. Van der Linde-Sipman, J.S., T.S.G.A.M. Van den Ingh, J.J. Van Nes, H. Verhagen, J.G.T.M. Kersten, A.C. Beynen, and R. Plekkringa, 1999. Salinomycin-induced polyneuropathy in Cats: Morphologic and Epidemiologic data. *Vet. Pathol.*, 36: 152-156.
6. Halvorson, D.A., C. Van Dijk and P. Brown, 1982. Ionophore Toxicity in Turkey Breeders. *Avian Diseases.*, 26: (634-639).
7. Novilla, M.N., 1992. The Veterinary Importance of the Toxic Syndrome Induced by Ionophores. *Vet. Hum Toxicol.*, 34: 66-70.

8. Gregory, D.G., S.L. Vanhooser and E.L. Stair, 1995. Light and Electron microscopic lesions in peripheral nerves of broiler chickens due to Roxarsone and Lasalocid Toxicoses. *Avian Diseases.*, 39: 408-416.
9. Gad, S.C., C. Reilly, K. Siino and F.A. Gavigan, 1985. Thirteen Cationic Ionophores: Their Acute Toxicity, Neurobehavioral and Membrane Effects. *Drug and Chem. Toxicol.*, 8: 451-468.
10. Edwards P.M and V.H. Parker, 1977. A simple, sensitive, and objective method for early assessment of acrylamide neuropathy in rats. *Toxicol. Appl. Pharmacol.*, 40: 589-91.
11. MacKnight, A.D.C., 1987. Volume maintenance in osmotic conditions, in: *Current Topics in Membranes and Transport*. Academic Press, New York, pp: 3-45.
12. LoPachin, Jr. R.M., A.J. Sauberman, 1990. Disruption of cellular elements and water in neurotoxicity: Studies using electron probe X-ray microanalysis. *Tox. Appl. Pharmacol.*, 116: 355-377.
13. LoPachin, Jr. R.M., C.M. Castiglia, A.J. Sauberman, 1992a. Acrylamide disrupts elemental composition and water content of rat tibial nerve: I. myelinated axons. *Tox. Appl. Pharmacol.*, 115: 21-34.
14. LoPachin, Jr. R.M., C.M. Castiglia, A.J. Sauberman, 1992b. Perturbation of axonal elemental composition and water content: Implications for neurotoxic mechanisms. *Neurotoxicol.*, 13: 123-138.
15. LoPachin, Jr. R.M. and E.P. Lehning, 1994. Acrylamide-induced distal axon degeneration: a proposed mechanism of action. *Neurotoxicol.*, 15: 247-249.
16. Lehning, E.M., R. Doshi, N. Isaksson, P.K. Stys and Jr. R.M. LaPoachin, 1996. Mechanism of injury-induced calcium entry into peripheral nerve myelinated axons: Role of reverse sodium calcium exchange. *J. Neurochem.*, 66: 493-500.
17. Emery, D.J., J.H. Lucas, G.W. Gross, 1991. Contributions of sodium and chloride to ultrastructural damage after dendrotomy. *Exptl. Brain Res.*, 86: 60-72.