

Effect of Oral Administration of Formalin on Blood Gases Parameters in Rats

¹O.K. Al Omari, ²W.A. Khamas and ¹A. Elbeteiha

¹Department of Applied Biological Sciences, Faculty of Science,
 Jordan University of Science and Technology, P.O. Box 3030, Irbid, 22110, Jordan

²College of Veterinary Medicine, Western University of Health Sciences,
 Pomona, CA 91766-1854, USA

Abstract: Forty Sprage-Dawely rats of both sexes (4 to 5 months of age) were used in this experiment. Formalin solution was provided with drinking water ad libitum for 8-12 weeks. Fourteen rats received a daily dose of 80 mg/kg/day, 13 rats received 150 mg kg⁻¹ day while another 13 rats were given tap water. Animals weights, food and water consumption were monitored throughout the experiment. The concentration of the test substance in the solutions were adjusted weekly on the basis of mean body weight and liquid consumption to maintain a target intake of 80 and 150 mg/kg/day throughout the experiment. Arterial blood after eight weeks were collected from hypnotized rats given Midazolam-3 mg kg⁻¹ intra-peritoneally (Dormicum F. Hoffmann-La Roche, Ltd, Switzerland, 2371081). Animals became partially anesthetized and blood was collected by cardiac puncture from the left ventricle. Standard procedure was followed to store the blood and immediately transported to the laboratory. The samples were analyzed with blood gas analyzer (Omni 4: AVL, Graz., Austria 2493) pH, HCO₃⁻, PO₂, PCO₂, O₂ Saturation, BE (Base Excess). The same procedure and parameters were followed and tested after 12 weeks of exposure with the blood collected from the tip of the tail of unanesthetized rats. Besides, blood samples were collected for reticulocytes counts and stained with retic stain (brilliant cresyl blue). Liver and kidney were excised and weighed and the relative organ weights were calculated. Histological examinations were performed on kidney and liver after routinely processed for normal histological procedure. Sections were stained with hematoxylin and eosin stain. Body weight, food and water consumption showed a dose related decrease which were reflected on the general animal health. There were no clear statistical differences between treated and control groups in respect to most blood gases parameters used with the exception of the pH and PCO₂. A significant decrease in pH and PCO₂ in rats ingested 150 mg/kg/day formalin solution for 12 weeks were evident. Liver and kidneys showed no histological changes in treated rats of all groups. It was observed that reticulocytes percentage decreased significantly in a non-dose related manner. In conclusion, the effect of the exposure to formalin differ from species to species and from system to system according to the availability, activity and amount of the enzyme formaldehyde dehydrogenase present in that specific species or system.

Key words: Formalin, blood gases, rats, parameters, reticulo cytes, hematoxylin

INTRODUCTION

Formaldehyde is the smallest member of the aldehyde series (HCOH), It contains only one carbon atom, described as a colorless flammable gas with a strong pungent suffocating odor. It bears the highest reactivity amongst the aldehyde, polymerizes with itself spontaneously and undergoes many reactions like condensation, oxidation and reduction. It is known by other names like formalin when dissolved in water and paraformaldehyde, which is the solid polymer of the compound (Gerberich *et al.*, 1980).

Formaldehyde is used principally to produce so many products and used in large amounts in industry (Madestau, 1987). It is used as both preservative and

fixative of anatomical, histological and pathological specimens. Subjects in such occupations are candidates to chronic exposures of effective concentrations. All of us are continuously exposed to formaldehyde as it results from cigarette, cosmetics and even food preservatives (Feinman, 1988).

Formaldehyde exists in physiological systems in minute concentrations through the metabolism of amino acids and nucleic acids. It is metabolized by the enzyme formaldehyde dehydrogenase; a specific enzyme distributed all over the body with a higher concentration in the liver and blood that converts formaldehyde to formic acid then to CO₂ and water (Restani *et al.*, 1992). This mechanism of elimination face exhaustion when respectful amount are challenged through different routes.

The need for estimation of blood gases parameters would provide useful information on the pathophysiologic toxicity of formaldehyde and would acquire attention to a different potential of the toxin. The aim of the present study is to evaluate the subchronic toxicity of formaldehyde on acid-base balance (if any) and the effect on circulating reticulocytes.

MATERIALS AND METHODS

Animals: Forty Sprague-Dawley male and female rats age 4 to 5 months were used in this experiment. Rats were provided by the animal house unit at the Faculty of Medicine, Jordan University of Science and Technology. They were maintained in a controlled atmosphere 21±1°C under 12 h light: 12 h darkness schedule. Food and tap water were obtained from the facility and provided ad libitum.

Animals apparently healthy and normal with regards to general body condition. Three rats were selected randomly for gross examination of internal organs after being sacrificed by cervical dislocation under light ether anesthesia. No abnormalities or disorders of any kind were detected in these animals. Animals were divided into groups for different treatment (Table 1).

Test substance: Paraformaldehyde, prilled 95% formaldehyde was obtained from Aldrich Chemical Company (Milwaukee, WI 53233, USA). Paraformaldehyde was dissolved in tap water by continuous stirring and heating at 80°C until the solution was clear. The stocks were prepared once a week and stored in the refrigerator at 4°C.

Formalin solution provided to 30 rats ad libitum for 8-12 weeks. Fourteen rats received a daily dose of 80 mg/kg/day, 13 received 150 mg/kg/day and 13 rats were given tap water and served as a control group. Animals were weighed throughout the experiment on a weekly basis. Food and water consumption were measured every day for the first week then for three random days per week for the remaining period.

The concentration of the test substance in the solutions was adjusted weekly on the basis of mean body weight and liquid consumption to maintain a target intake of 80 and 150 mg/kg/day throughout the experiment.

Arterial blood: After 8 weeks of formalin ingestion, 14 animals were hypnotized using Midazolam (Dormicum F. Hoffmann-La Roche Ltd, Switzerland, 2371081). Midazolam (3 mg kg⁻¹) was injected intraperitoneally using insulin syringes. After 10-15 min of injection, the animals became partially anesthetized. Using heparinized 5 mL syringes, blood was collected by cardiac puncture from the left ventricle. The needles were then bent, capped, placed in cold icebox (4°C) and immediately transported for analysis with an average time of 50±10 min. The samples were analyzed using blood gas analyzer (Omni 4: AVL, Graz., Austria 2493) for the measurement of pH, bicarbonate (HCO₃⁻), Base Excess (BE), oxygen and carbon dioxide partial pressure (PO₂ and PCO₂) and saturation O₂.

Capillary blood: After 12 weeks of formalin oral administration, capillary blood samples were collected from the tip of the tail of 13 rats. Blood samples were collected from unanaesthetized rats from all groups. Blood was collected in heparinized capillary tubes. They were agitated thoroughly to prevent coagulation through ensure mixing with heparin and processed as mentioned above.

Reticulocyte counts: Animals ingested 150 mg kg⁻¹ were assigned at the end of the experiment for reticulocytes count. Animals were anaesthetized and blood was collected in syringes by cardiac puncture and placed in vacutainers containing EDTA. Samples were immediately processed as follows: for each sample of 50 µL blood was transferred to eppendorf tube, followed by the addition of equivalent volume of brilliant cresyl blue (retic stain). The mixture was vortexed for few seconds and placed in a 37°C incubator for 15 min. A drop was placed over a glass slide edge and smeared using a cover slip to prepare a blood film. Ten fields from each sample were examined under oil immersion lens. The counts were then expressed as percentages according to the following equation:

$$\text{Reticulocyte percentage} = \frac{X}{n} \times y \times 100$$

n = Number of fields examined
x = Total number of reticulocytes for all fields
y = Average number of cells per field

Table 1: Number of rats used in each group and type of treatment

| Formalin dose mg kg ⁻¹ | Number of animals 8 weeks exposure | Number of animals 12 weeks exposure | Number of animals for reticulocytes stain | Histological examination of the liver and kidneys |
|-----------------------------------|------------------------------------|-------------------------------------|---|---|
| 0 | 6 | 7 | 7 | 7 |
| 80 | 8 | 6 | 6 | 6 |
| 150 | 6 | 7 | 7 | 7 |
| | 20 | 20 | 20 | 20 |

Gross anatomy and histology: The same thirteen rats ingested 150 mg kg⁻¹ were sacrificed by cervical dislocation under light ether anesthesia. Liver and kidneys were excised and weighed and the relative organ weights were calculated. Histological examinations using standard technique were performed on kidneys and liver. Staining of all histological tissues were carried out using hematoxylin and eosin stain (Bancroft and Gamble, 2005).

RESULTS

General health and gross pathology: General health of rats was estimated through the evaluation of body weights, food and water consumption. Weight gain was significantly reduced in both treatment groups (Fig. 1).

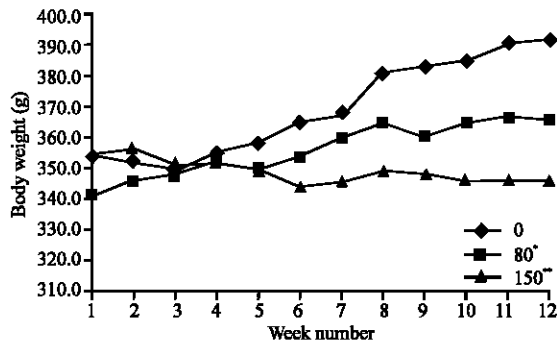


Fig. 1: Effect of formalin oral ingestion on body weights of adult male rats, Ingestion of formalin for 12 weeks resulted in a significant decrease in weight gain of rats, which ingested 80 and 150 mg/kg/day in a dose related manner (*p<0.05, **p< 0.01)

The three parameters (body weight, food and water consumption) showed a dose related decrease demonstrating a direct effect of formalin on general health (Table 2). A dose related change was demonstrated in yellow discoloration on the fur that was highly noticeable in the high dose group (150 mg/kg/day) and to a lesser extent in the low group (80 mg/kg/day).

Blood gas analysis: After eight weeks, the data obtained by cardiac puncture did not establish any significant statistical differences in the measured parameters among treated and control groups (Table 3). While, after 12 weeks of oral administration, blood samples were collected from the tip of the tail of unanaesthetized rats were analyzed for the same parameters mentioned above. The analysis showed a statistically significant decrease in PCO₂ and pH in rats, which ingested 150 mg/kg/day formalin solution (Table 4).

Reticulocytes counts: Formalin ingestion for twelve weeks caused a significant increase in the reticulocyte percentage in a non-dose related manner (Fig. 2). The average percentage of reticulocyte in the control group was 1.5 % whereas in the treated groups were 3.3% (p<0.01) and 2.9% (p< 0.01) in the groups ingested 80 and 150 mg/kg/day, respectively.

Liver and kidney relative weights: In rats ingested 80 mg/kg/day, a clear significant reduction in relative weights took place in both the liver (p<0.05) and the kidney (p<0.001). The average relative weights of the liver and kidneys were 3.00 mg ±0.17 and 0.55 mg⁻¹ ±0.05, respectively. On the other hand, liver and kidney relative

Table 2: Effect of twelve weeks ingestion of formalin via drinking water on average body weight, water and food consumption in rats exposed to formalin in drinking water for 12 weeks

| Formalin dose (mg/kg/day) | Body weight (g)s | Water consumption mL kg ⁻¹ b | Foodconsumption g kg ⁻¹ c |
|---------------------------|------------------|---|--------------------------------------|
| 0 | 391.5±40.2 a | 29.38±2.21 (76.51±5.66) ^b | 28.32±0.49 (72.16±1.27)c |
| 80 | 365.3±38.7 | 20.48±0.50*** (56.03±1.38**) | 18.32±0.81*** (49.73±2.21***) |
| 150 | 345.8±38.2 | 17.23±0.37*** (49.88±1.02**) | 17.16±2.52** (50.03±7.30*) |

a Results are expressed as mean±standard deviation. b Relative water consumption (mL kg⁻¹). c Relative food consumption (g kg⁻¹). *p<0.05, **p<0.01, ***p<0.001 (student t-test)

Table 3: Arterial blood gas values of rats ingested 0, 80, 150 mg/kg/day formalin solution for eight weeks

| Formalin Dose (mg/kg/day) | No. of animals | PO ₂ (mm Hg) | PCO ₂ (mm Hg) | pH | HCO ₃ ⁻ (mmol L ⁻¹) | SO ₂ (%) | BE [†] (mmolL ⁻¹) |
|---------------------------|----------------|-------------------------|--------------------------|-------------|---|---------------------|--|
| 0 | 6 | 77.5±.5 ^a | 35.6±2.2 | 7.431±0.016 | 23.2±1.5 | 95.6±1.0 | -0.6±1.3 |
| 80 | 8 | 75.9±11.2 | 35.9±2.8 | 7.446±0.039 | 24.1±1.2 | 95.2±2.1 | 0.5±1.6 |
| 150 | 6 | 80.3±10.8 | 34.7±4.4 | 7.427±0.029 | 22.4±2.8 | 95.6±1.8 | -1.3±2.5 |

a Results are expressed as mean±standard deviation. † Base excess

Table 4: Capillary blood gas values of rats ingested 0, 80, 150 mg/kg/day formalin solution for twelve weeks

| Formalin dose (mg/kg/day) | No. of animals | PO ₂ (mm Hg) | PCO ₂ (mm Hg) | pH | HCO ₃ ⁻ (mmol L ⁻¹) | SO ₂ (%) | BE [†] (mmolL ⁻¹) |
|---------------------------|----------------|-------------------------|--------------------------|--------------|---|---------------------|--|
| 0 | 7 | 30.8±3.5* | 55.4±2.9 | 7.381±0.013 | 2.1±1.2 | 57.9±7.1 | 5.4±0.9 |
| 80 | 6 | 35.4±10.0 | 58.5±9.8 | 7.357±0.045 | 31.7±3.0 | 61.7±17.1 | 4.5±1.6 |
| 150 | 7 | 30.6±6.2 | 61.0±6.3* | 7.354±.018** | 33.2±3.3 | 54.5±12.6 | 5.6±2.7 |

*p<0.05, **p<0.005 (student t-test).[†]Results are expressed as mean±standard deviation.[†] Base excess

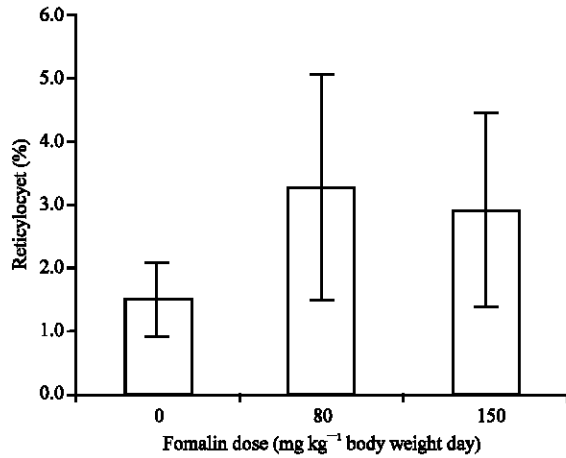


Fig. 2: Effect of 12 weeks ingestion of formalin on blood reticulocytes percentage. Data show a significant increase in percentage of reticulocytes in both treated groups compared to the control (p<0.01 for both)

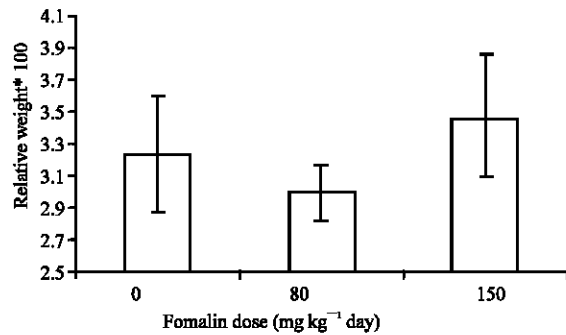


Fig. 3: Effect of 12 weeks oral ingestion of formalin solution on relative liver weights (organ weight (g)/(100g)). Rats that ingested 80 mg kg day showed a significant decrease in liver relative weight (p<0.05)

weights of the control groups were 3.32 mg±0.37 and 0.65 mg±0.27, respectively. Liver and kidney relative weights of rats ingested 150 mg/kg/day were 3.47±0.39 and 0.63±0.04, respectively did not differ statistically from their control counterpart (Fig. 3 and 4).

Histological examination: Light microscopic study of the liver and kidneys of rats showed no pathological changes

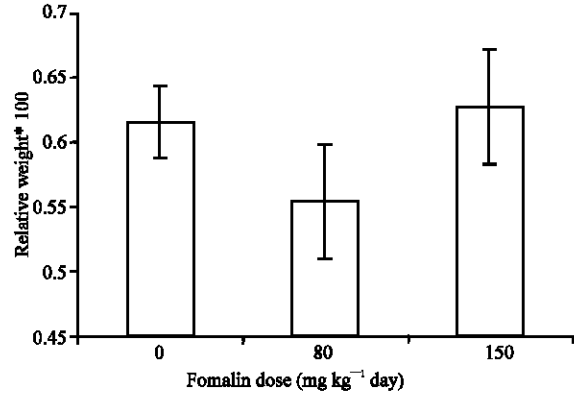


Fig. 4: Effect of 12 weeks oral ingestion of formalin on relative kidney weight (organ weight (g)/(100g)). Rats that ingested 80 mg kg day showed a significant decrease in kidney relative weight (p<0.05)

of any kind in all groups ingested formalin ingestion with regard to the present experiment.

DISCUSSION

Body weight and water consumption were significantly reduced in a dose-related manner when compared to control. Water consumption is probably due to the high rejection of the formalin solution by rats. These changes were also observed in other study for 4 weeks in rats ingested 125 mg/kg/day (Til *et al.*, 1988). Johanssen *et al.* (1986) administered formalin to male and female rats and dogs via drinking water for three months. Their results demonstrated that no decrease in food intake, yet water consumption and body weights decreased at 100 and 150 mg kg⁻¹ body weight/day. The differences between rats and dogs in food consumption and feed efficiency are related to some variations in how these two species metabolize formaldehyde.

In a chronic toxicity study, formalin solution (300 mg/kg/day) was administered orally to rats for 24 months. Accelerated death rates, retarded growth, decreased food and water intake were observed (Tobe *et al.*, 1989).

Beall and Ulsamer (1984) suggested that exposure to formaldehyde by various routes including oral administration might be associated with hepatotoxicity in

several animal species. Other studies could not find any hepatotoxic activities in organ weight, histological analysis and liver enzyme activities (Til *et al.*, 1988, 1989; Hurni and Ohder, 1973; Johannsen *et al.*, 1986). In the present study, histology of the liver and kidney were evaluated and the results obtained are in agreement with the previous studies in which no histological changes for both organs were observed in all treatment groups. It seems that formalin action is decreased in the blood and liver to a level that can be tolerated by these organs at the concentration used in this experiment.

Two methods were used in the present study to evaluate the acid-base disturbances caused by formalin ingestion with regard to sampling techniques, arterial (cardiac) and capillary (tail).

Arterial blood showed no clear statistical correlation between treated and control groups in respect to blood gases parameters and formalin ingestion.

Capillary blood samples were collected from the tip of the tail of unanesthetized rats. Data showed significant decrease in blood pH ($p < 0.005$) in rats ingested 150 mg/kg/day and increase in PCO_2 ($p < 0.05$) in the same group. Blood pH of the high dose group indicates a state of acidosis. Unfortunately, data obtained from PCO_2 alone is insufficient to interpret the changes in pH or to identify its nature because PCO_2 is a respiratory component and can only indicate a respiratory abnormal action. Neither of the tests showed a difference in $[HCO_3^-]$ between control and treated groups which made it difficult to interpret the exact kind of slight acidosis observed in this experiment.

Steave and Haskins (1977) demonstrated that blood samples stored in ice water can maintain pH values, PCO_2 and PO_2 without change for 3.5 and 6 h, respectively. Arterial blood samples were collected after the animals were heptonized but not fully anesthetized to minimize the influence of anesthesia on acid base equilibrium knowing that anesthesia tends to cause ventilatory depression and thus raise the PCO_2 values (Bar-Ilan and Marder, 1980, Brun-Pascaud *et al.*, 1982) (although a slight decrease in pH is expected by heptonization yet to lesser degree). However, both control and treated groups were treated the same way, therefore, changes were most probably due to the formalin. In contrast, samples collected from the tip of the tail overcome the influence of dilution because the volume of heparin and blood are constant for all samples. Yet, awake rats may vary remarkably with regard to stress and ventilatory rate but the effect of heptonization is eliminated.

Rats have slightly more alkaline blood than humans do (Upton and Morgan, 1975). In the present study, arterial blood samples showed a pH of 7.43 and a capillary blood samples of pH value 7.38. The difference of pH

between the two samples is attributed to the low concentration of the HCO_3^- in the arterial blood compared to the capillary blood. Moreover, PO_2 and O_2 saturation are much higher in arterial blood than capillary blood while PCO_2 of capillary blood is greater than that in arterial blood sample.

The half-life of formaldehyde in the blood is very short (1.5 min) where it will be converted to formic acid by the enzyme formaldehyde dehydrogenase (Restani *et al.*, 1992). This mechanism of elimination face exhaustion when respectful amount are challenged through different routes. It seems that 80 and 150 mg kg^{-1} are bearable in rats in respect to blood gases parameters with few exceptions.

In the present experiment, reticulocyte percentage was examined. It was evident that formalin ingestion caused a rise in reticulocyte percentage. This might be attributed to the additive stress effluence of the test substance over the animals, which may affect the capability of the red blood cells to carry enough oxygen and thus results in a premature release of reticulocytes into the blood stream.

It seems that each system and each species has its own threshold for formalin. Concentration of formalin used and duration in rats were tolerable in most cases under current study.

ACKNOWLEDGMENT

The authors would like to extend their sincere thanks and appreciation to the Deanship of Research, Jordan University of Science and Technology for their kind support of this study (45/2000).

REFERENCES

- Beall, J. and A. Ulsamer, 1984. Formaldehyde and hepatotoxicity: A Rev. *J. Toxicol. Environ. Health.* 14: 1-21.
- Bar-Ilan, A. and J. Marder, 1980. Acid base status in unanesthetized, unrestrained guinea pigs. *Pflugers Arch*, 384: 93-97.
- Beetham, R. 1982. A review of blood PH and blood gas analysis, *Ann. Clin. Biochem.*, 19: 198-213.
- Bancroft, J.D. and M. Gamble, 2005. Theory and practice of histological techniques. (5th Edn.), Churchill Livingstone, Philadelphia, USA.
- Bran-Pascaud, M., C. Gaudebout, M. Blanyo and J. Pocidato, 1982. Arterial blood gases and acid-base status in awake rats. *Resp. Physiol.*, 48: 45-57.
- Feinman, S., 1988. Formaldehyde Toxicity. In: Formaldehyde Sensitivity and Toxicity. Eds. Feinman, S. CRC Press. Florida, pp: 156-158.

- Gerberich, H., A. Stautzenberger and W. Hopkins, 1980. Formaldehyde. In: Kirk-Othmer Encyclopedia of Chemical Technology. Eds. Mark, H., D. Othmer, C. Overberger and G. Seaborg, John Wiley and Sons. New York, 11: 231-247.
- Hurni, H. and H. Ohder, 1973. Reproduction study with formaldehyde and hexamethylenetetramine in beagle dogs. *Food Cosmet. Toxicol.*, 11: 459-462.
- Johannsen, F., G. Levinskas and A. Tegeris, 1986. Effects of formaldehyde in the rat and dog following oral exposure. *Toxicol. Lett.*, 30:1-6.
- Koppang, H., T. Stene, T. Solheim, T. Larheim, A. Wisnes, E. Monn and O. Stokke, 1984. Dental features in congenital persistent renal tubular acidosis of proximal type. *Scand. J. Dent. Res.*, 92: 489-495.
- Madestau, L., 1987. Formaldehyde. In: McGraw-Hill Encyclopedia of Science and Technology. (Eds.), Parker, S. McGraw-Hill. New York, 7: 368-369.
- Maxwell, M., C. Kleeman and R. Narins, 1987. Acid-Base Disorders. *Clinical Disorders of Fluid and Electrolyte Metabolism*. McGraw Hill. New York, pp: 625-627.
- Restani, P., A. Restelli and C. Galli, 1992. Formaldehyde and hexamethylenetetramine as food additives: Chemical interactions and toxicology. *Fd. Add. Cont.* 9: 597-605.
- Preston, T., E. Rattray and F. White, 1960. Effects of feeding formalin-treated skim milk to calves. *Anim. Prod.*, 2: 33-45.
- Steave, C. and D. Haskins, 1977. Sampling and storage of blood for pH and blood gas analysis. *JAVMA.*, 170: 429-433.
- Trocho, C., R. Pardo, I. Rafecas, J. Virgili, X. Remesar, J. Fernandez-Lopez, and M. Alemany, 1998. Formaldehyde derived from dietary aspartame binds to tissue components *in vivo*. *Life Sci.*, 63: 337-349.
- Tobe, M., K. Naito and Y. Kurokawa, 1989. Chronic toxicity study on formaldehyde administered orally to rats. *Toxicology*, 58: 79-86.
- Til, H., R. Woutersen and V. Feron, 1988. Evaluation of the oral toxicity of acetaldehyde and formaldehyde in a 4-week drinking water study in rats. *Fd. Chem. Toxicol.*, 26: 447-452.
- Til, H., R. Woutersen, V. Feron, H. Hollanders and H. Flake, 1989. Two year drinking water study of formaldehyde in rats. *Fd. Chem. Toxicol.*, 27: 77- 87.
- Takahashi, M., R. Hasegawa, F. Furukawa, K. Toyoda, H. Sato and Y. Hayashi, 1986. Effects of ethanol, potassium metabisulfite, formaldehyde and hydrogen peroxide on gastric carcinogenesis in rats after initiation with N-methyl-N'-nitro-N-nitrosoguanidine. *Gann.*, 77: 118-124.
- Upton, P. and D. Morgan, 1975. The effect of sampling technique on some blood parameters in the rat. *Lab. Anim.*, 9: 85-91.