

## Co-Existence of Besnoitiosis and Dermatophilosis in Indigenous Cattle Slaughtered at Zaria Abattoir

<sup>1</sup>S.J. Sambo, <sup>1</sup>N.D.G. Ibrahim, <sup>1</sup>K.A.N. Esievo, <sup>2</sup>J.O. Hambolu, <sup>1</sup>S.B. Oladele,  
<sup>3</sup>A.K.B. Sackey and <sup>4</sup>S.M. Makoshi

<sup>1</sup>Department of Veterinary Pathology and Microbiology,

<sup>2</sup>Department of Veterinary Anatomy,

<sup>3</sup>Department of Veterinary Surgery and Medicine, Faculty of Veterinary Medicine,  
 Ahmadu Bello University, Zaria, Nigeria

<sup>4</sup>Department of Veterinary Physiology and Pharmacology,

Faculty of Veterinary Medicine, University of Ibadan, Ibadan, Nigeria

**Abstract:** A total of 518 cattle were examined and sampled at Zaria abattoir from November, 2001 to October, 2002. Skin specimens obtained after slaughter from the neck region were fixed in 10% buffered neutral formalin, processed, sectioned at 5 µm thickness and stained with Haematoxylin and Eosin (H and E) technique. At ante mortem examination 5(2.5%) of the cattle were found with gross lesions of besnoitiosis, 103 (19.8%) were diagnosed with dermatophilosis and 50 (9.7%) with tick infestation. Twenty-nine ( 5.6 %) cattle had both dermatophilosis and tick infestation. Histopathological examination confirmed that the 5 cattle clinically diagnosed with besnoitiosis really had cysts of *B. besnoiti* in skin sections. Four ( 2.1%) additional cattle had similar cysts in their skin sections although they had no clinical signs of besnoitiosis. Three ( 1.5%) of these had gross lesions of dermatophilosis and 1 (0.2%) had ticks on the body. Microscopic examination of crusts from the skin specimens confirmed the presence of filaments of *D. congolensis*. It was concluded that some cases of besnoitiosis may pass unnoticed at clinical examination where the skins are severely affected with dermatophilosis.

**Key words:** Besnoitiosis, dermatophilosis, co-existence, indigenous cattle, Zaria abattoir

### INTRODUCTION

Besnoitiosis in cattle, sheep, goats and rabbits is caused by *Besnoitia besnoitii*, a unicellular protozoan organism of the genus *Besnoitia* which belongs to the family Sarcocystidae (Pols, 1960). Members of this genus are known to be transmitted by ingestion of water or feed contaminated with oocysts in faeces of the final host (Soulsby, 1982). The mode of transmission of *B. besnoiti*, however, has not been fully elucidated, although it has been shown that the disease could be experimentally induced when cystozoites of the parasite are injected with a hypodermic needle into a susceptible host (Pols, 1960).

The disease manifests clinically as fever, anorexia, depression, subcutaneous edema, enlarged lymph nodes, nasal discharges and respiratory distress in the acute phase (Pols, 1960; Bigalke, 1968). It was observed that survivors from this phase may develop the chronic signs such as hardening, wrinkling, cracking with encrustations and sero-sanguinous exudates on the skin due to the

formation of subcutaneous nodules. Severely affected cattle, harboured conjunctival cysts, were emaciated and practically unproductive for all purposes (Pols, 1960) representing a total economic loss.

Furthermore, cattle with besnoitiosis had similar thickening, wrinkling and cracks on the scrotal skin, loss of libido and terminal sterility (Bargai *et al.*, 1980; Sekoni *et al.*, 1992). The sterility was thought to have resulted from an increased scrotal temperature, arrested spermatogenesis, devitalization and gangrene of testes, as observed in Bunkure ranch, Kano State of Nigeria (Kumi *et al.*, 1989). On the other hand, it was found that the disease was not important in causing infertility in cows (Nobel *et al.*, 1981).

Clinical reports of besnoitiosis from Zaria involved cattle exotic to Nigeria (Sekoni *et al.*, 1992; Kumi *et al.*, 1989; Sannusi, 1991) and no other disease condition was said to have co-existed in affected victims. Among indigenous cattle examined in University of Ibadan Dairy Farm located in the Southern part of Nigeria an inapparent

form of besnoitiosis was reported to have co-existed with dermatophilosis (Oduye, 1974). This study reports, for the first time, the co-existence of *B. besnoiti* and *D. congolensis* in skin, observed during a survey of besnoitiosis in indigenous cattle slaughtered at Zaria abattoir, in Northern part of Nigeria.

**MATERIALS AND METHODS**

A total of 518 cattle were examined and sampled at Zaria abattoir, from November, 2001 to October, 2002. An average of two cattle was examined daily, for 5 days a week, during the period. A careful ante-mortem examination for the presence of gross lesions of besnoitiosis was made. Observations and tentative diagnoses were recorded on separate data forms for each animal. Where necessary, photographs were taken to illustrate the gross lesions described. Skin specimens obtained after slaughter from the neck regions were fixed in 10% buffered neutral formalin. The specimens were processed, sectioned at 5 µm thick and stained with Haematoxylin and Eosin (H and E) (Luna, 1968) in the Department of Veterinary Pathology and Microbiology, Ahmadu Bello University, Zaria, Nigeria. The stained sections were examined with light microscope, while the photomicrograph was taken at X250 magnification in the Department of Biological Sciences, Ahmadu Bello University, Zaria, Nigeria for illustration.

Skin specimens were also examined for the presence of *D. congolensis*. Crusty lesions of dermatophilosis on the skin of cattle, found positive for *B. besnoiti* were crushed on glass slides, Gram stained and examined under the light microscope in the Department of Veterinary Pathology and Microbiology, Ahmadu Bello University, Zaria.

**RESULTS**

The ante mortem examination, during the study, revealed clinical signs of besnoitiosis in Case Nos. 002, 272, 282, 373 and 379 (5, 2.5%) of the cattle. The signs include wrinkling of skin around the neck, irregular areas of alopecia at the maxillary and mandibular areas of the face and presence of skin nodules. There were no clinical signs of dermatophilosis in any of these *B. besnoiti* infected cattle. On the other hand, there were 103 (19.8%) of the cattle with thick scabs on the skin all over the body or at the axillary and inguinal areas; clinically diagnosed as cases of dermatophilosis. A total of 50 (9.7%) cattle were found with tick infestation at ante mortem inspection, of which 29 (5.6%) were among those which had dermatophilosis.

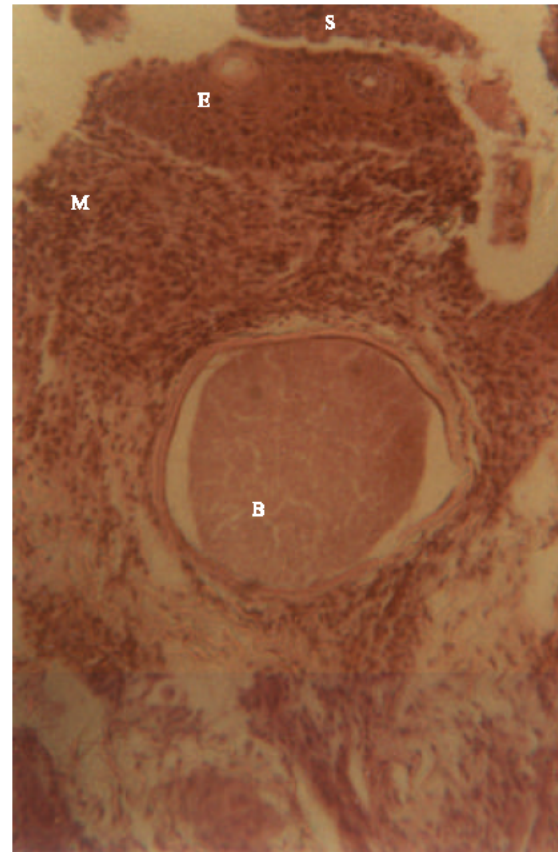


Fig. 1: Scanned coloured photomicrograph of bovine skin section. Note a *B. besnoiti* cyst (B) from Case no. 360 found positive of *D. congolensis*. Note the Scab remnant (S) over the necrotized Epidermis (E) and diffused Mononuclear cellular infiltration (M) within the dermis. H and E stain. Original magnification×250

Table 1: Cattle found infected with *B. besnoiti* during the survey

Case no.	Sex	Source	Description of skin condition
002	M	Kafur	Wrinkling and bruises of skin on the neck
176	F	Kafur	No gross lesions
222	F	Anchau	Scabs on the skin all over the body
272	M	Katsina	Wrinkling of the skin on the neck
282	M	Kafur	Nodules at the base of the right ear and wrinkling of skin at the neck region
304	M	Kafur	Rough hair coat and thick scabs at axillary and inguinal areas
360	M	Anchau	Scabs and ticks on the skin
373	F	Makarfi	Rough hair coat and wrinkles on the skin neck and thighs
379	M	Zaria	Wrinkling of the skin around the neck region and alopecia on the neck

During microscopic examination it was confirmed that 5 cattle grossly diagnosed with besnoitiosis had typical *B. besnoiti* cysts in their skin sections. In addition, similar cysts (Fig. 1) were observed in skin sections from

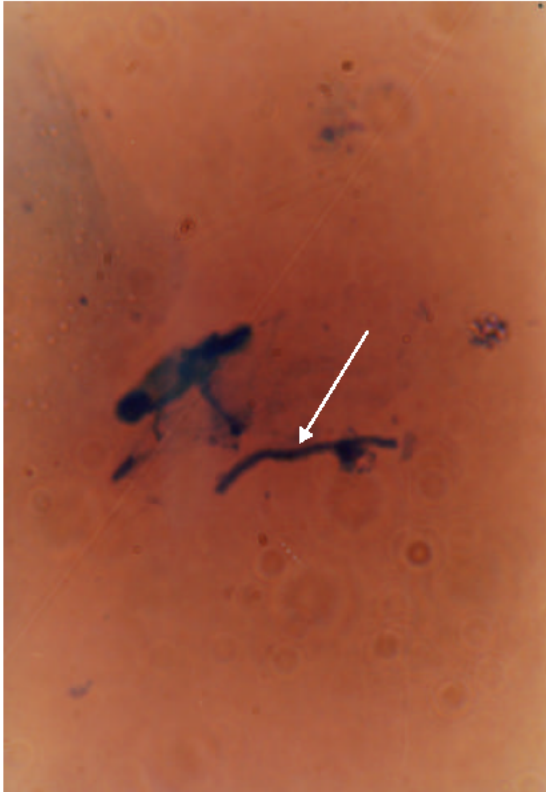


Fig. 2: Scanned photograph of *D. congolensis* (arrow) on a smear from the same bull in Fig. 1. Gram stain. Original magnification  $\times 1000$

4 (2.1%) other cattle (Case Nos. 176, 222, 304 and 360) which had no clinical signs of besnoitiosis (hereby referred to as inapparent besnoitiosis). Case Nos. 222, 304 and 360 (3, 1.5%) were among those that had gross lesions of dermatophilosis and confirmed to have had filaments of *D. congolensis* (Fig. 2). Therefore, the total number of cattle infected with *B. besnoiti* was 9 (4.6%) as shown on Table 1 while the rate of co-existence of besnoitiosis, dermatophilosis observed in cattle during the study was 3 (1.5%). Case no. 360 (1, 0.2%) was also found infested with ticks identified as *Amblyomma variegatum*.

#### DISCUSSION

The co-existence of besnoitiosis with dermatophilosis in this study seems to suggest that agents of the two diseases may be transmitted by the same vectors. Biting insects with strong mouth parts, such as tabanid flies were strongly incriminated in the transmission of *B. besnoiti* in cattle (Pols, 1960) while ticks were said to have contributed significantly in the occurrence of dermatophilosis (Saidu, 1986).

Previously, it was also found that 0.08% of cases of dermatophilosis in cattle co-existed with besnoitiosis (Saidu, 1986) but our present observation showed a 1.5% co-existence involving the 2 diseases. There appears to be a slight increase in their concurrence but when tick infestation was considered a low prevalence (0.2%) was recorded, indicating that the factors which lead to the co-existence have not significantly changed, at least around Zaria which is located in the semi-arid savannah zone of Nigeria.

All the cases of besnoitiosis which co-existed with dermatophilosis in this study were incidentally among those examined and sampled during the dry season. Probably, the affected cattle may have been infected during the rainy season which favours insect activity and increases the risk of exposure of susceptible hosts to the parasite.

#### CONCLUSION

This study notes that cases of besnoitiosis in cattle may pass unnoticed at clinical examination, where the skin is severely affected with dermatophilosis. The co-existence of besnoitiosis and dermatophilosis incriminates ticks and biting flies in the transmission of both *B. besnoiti* and *D. congolensis* in and around Zaria.

#### REFERENCES

- Bargai, U., S. Pearl and E. Mayer, 1980. Sterility in bulls due to besnoitiosis: Clinical, radiological and pathological findings. 11th International Congress on diseases of Cattle, Tel-Aviv., 1: 742- 746.
- Bigalke, R.D., 1968. New concepts on epidemiological features of bovine besnoitiosis as determined by laboratory and field investigations. Onderstepoort. J. Vet. Res., 34: 306-316.
- Kumi-Diaka, J., S. Wilson, A. Sannusi, C.E. Njoku and D.I.K. Osori, 1989. Bovine besnoitiosis and its effects on the male reproductive system. Theriogenology, 16: 523-530.
- Luna, L.G., 1968. In: Manual of Histologic Staining Methods of the armed forces Institute of Pathology, (3rd Edn.), McGraw-Hill Book Company, New York, pp: 34-36.
- Nobel, T.A., U. Klopfer, S. Perl, A. Nyska, M. Neuman and G. Brenner, 1981. Histopathology of genital besnoitiosis of cows in Israel. Vet. Parasitol., 8: 271- 276.
- Oduye, O.O., 1974. Occurrence of inapparent cutaneous besnoitiosis in cattle in Nigeria. J. Nig. Vet. Med. Assoc., 3: 92-96.

- Pols, J.W., 1960. Studies on bovine besnoitiosis with special reference to the aetiology. Onderstepoort J. Vet. Res., 28: 265-328.
- Saidu, S.N., 1986. Role of ticks and acaricides in the epidemiology of Dermatophilosis in Nigeria. Ph.D dissertation, Ahmadu Bello University, Zaria.
- Sannusi, A., 1991. A simple field diagnostic smear test for bovine besnoitiosis. Vet. Parasitol., 39:185-188.
- Sekoni, V.O., A. Sannusi, M.O.I. Abatan, E.O. Oyedipe, P.I. Rekwot and L.O. Eduvie, 1992. Loss of libido and terminal sterility in a Friesian bull naturally infected with *Besnoitia besnoiti* in Northern Nigeria. Theriogenology, 37: 533-549.
- Soulsby, E.J.L., 1982. In: Helminths, Arthropods and Protozoa of Domestic Animals (6th Edn.), Bailliere Tindall, London, pp: 497-499.