

## Pathological Study on the Capability of *Toxoplasma gondii* to Induce Oxidative Stress and Initiation a Primary Lesion of Atherosclerosis Experimentally in Broiler Chickens

E.R. Al-Kennany

Department of Pathology, College of Veterinary Medicine, University of Mosul, Mosul, Iraq

**Abstract:** This research was conducted to explore the ability of *Toxoplasma gondii*, that isolated recently from backyard chickens in Mosul city- Iraq, to induce oxidative stress and searching of any atheromatous lesions that developed in aorta of experimentally infected broiler chickens. The results elucidated a lipid peroxidation status in aortic and heart tissues of infected broilers. This status characterized by a significant increasing in Malondialdehyde (MDA) level and a significant decrease in glutathione concentrations of that tissues. Histological inspection of these tissues revealed the presence of tachyzoit and tissue cyst. Furthermore, histological picture of these aortas shows, hypertrophy of the endothelial lining as well as hypertrophy and proliferation of vascular smooth muscle cells from media to ward aortic intima; and accumulation of lipid vacuole concomitant with foamy cells in both media and intima. In conclusion, this study may revealed the capability of the *Toxoplasma gondii* for induction a similar pathophysiological alterations in both mammals and avies.

**Key words:** *Toxoplasma gondii*, oxidative, stress, atherosclerosis, broiler chickens

### INTRODUCTION

Atherosclerosis is a chronic degenerative and accumulative inflammatory response occur in large and medium sized arteries such as aorta, coronary and carotid arteries (Cheville, 1988). Etiological agents of this pathological condition consist a complex of genetic epidemiologic factors and biological or non biological agents (Ross, 1999). The initiating events in atherogenesis was the endothelial dysfunction caused by different risk factors like, hypertension, hyperlipidemia, diabetes mellitus, homocytinemia and inflammation (Gilbert and Rothe, 1984). Recent evidence suggest that infectious agents may be blamed for induction a primary lesions of atherosclerosis (Ruef *et al.*, 1999; Minick *et al.*, 1979). A number of pathogens was considered to be an etiological agents in the pathogenesis of atherosclerosis in human and animals; *Chlamydia pneumoniae*; *Enterococcus faecalis*; *Helicobacter pylori* and *Toxoplasma gondii* (Ruef *et al.*, 1999; Morre *et al.*, 2000).

It has been reported previously, that CU2 isolate of MDV developed lesions in chickens that were closely resembling those of chronic atherosclerosis in humans (Dubey *et al.*, 1998). In our current researches, we investigate that 0.5% hydrogen peroxide (H<sub>2</sub>O<sub>2</sub>)-treated drinking water for broiler chickens for 4 weeks period,

revealed an early atheromatous lesions similar to that of humans (Hassan *et al.*, 2000; Stocker and Keaney, 2004). Recently, *Toxoplasma gondii* have been shown to induce an oxidative stress that lead to endothelial injury and initiation of atheromatous lesions experimentally in both mice and cats (Nenseter *et al.*, 1994; Morre *et al.*, 2000).

In this study, we try to determine the capability of a local avian isolate of *Toxoplasma gondii*, recently isolated from Mosul city, for induction of oxidative stress and atherogenesis in experimentally infected broiler chickens.

In accordance to our current research work conducted on oxidative stress and its correlation with atheromatous lesions in different species, this study try to determine the capability of a local avian isolate of *Toxoplasma gondii*, recently isolated from Mosul city, for induction of oxidative stress and atherogenesis in experimentally infected broiler chickens.

### MATERIALS AND METHODS

***Toxoplasma gondii* isolate:** Isolation of *T. gondii* was carried out from brain and heart of backyard chickens at Mosul city, Iraq, following a procedures described previously (Al-Kennany, 2004). Each brain and liver were cuts into small pieces, that were mixed with equal volume

of normal saline and grinded. Thereafter, the collected solution was filtrated using cotton. One thousand unite of penicillin and 100 mg of streptomycin were added to the filtrates in order to prevent contamination. The inoculums for broilers as 1 mL of this filtrates containing 50 tissue cysts and given Intraperitoneally (IP).

**Animals:** This study used 20 of 45-days old male broiler chickens (Cobb-500) that divided randomly into 2 groups; Group 1 (G1) considered as a control and Group 2 (G2) that is infected IP by *Toxoplasma gondii*. All experimental chickens left under observation for 45 days during which subjected to *ad libitum* supply for diet and drinking water.

At the end of the experiment, chickens were bled and plasma samples were analyzed for the lipid profile; pieces of aorta and heart were collected for the estimation of Malondialdehyde (MDA) and Glutathione (GSH) and aortic and heart tissue sections were processed for histopathological examination (Portugal *et al.*, 2004).

This study performed at the department of Pathology and Microbiology/College of Veterinary Medicine, University of Dohuk, Iraq, during the periods November 2006- March 2007. This study performed at the department of Pathology and Microbiology/College of Veterinary Medicine, University of Dohuk, Iraq, during the periods November 2006- March 2007.

**Lipid profile assays:** All blood samples were collected after overnight fasting (12-14 days) and analysis performed on fresh heparin-treated plasma. The lipid parameters that include Total cholesterol (Tch), Triglycerides (TGS) and High-Density Lipoprotein (HDL-C), were determined using a standard enzymatic assay (Bio Merieux, Marcy-1, Etoil, France). Whereas, Low-Density Lipoprotein (LDL-C) was calculated by the Friedewald formula:

$$LDL-C = Tch - HDL-C - TGS/5$$

Table 1: Lipid profile of broiler chickens infected with *Toxoplasma gondii*

Groups	Total cholesterol mg dL <sup>-1</sup>	Triglycerides mg dL <sup>-1</sup>	HDL-C mg dL <sup>-1</sup>	LDL-C mg dL <sup>-1</sup>	VLDL-C mg dL <sup>-1</sup>	Atherogenic index
Control	117±0.23	105.3±1.28	42.06±2.72*	53.88±1.25	21.06±0.02	2.78±0.12
Infected	478±0.30*	192.3±0.48*	33.36±1.04	406.81±1.04*	38.49±1.28*	14.17±0.81*

-Broiler chickens infected intraperitoneally by 1 mL containing 50 tissue cyst of *T.gondii*, -Values are expressed as means ± SD of 10 broiler chickens per group

- (\*) significant difference at p≤0.05, - HDL-C= High Density Lipoprotein - Cholesterol, LDL- C= Low Density Lipoprotein- Cholesterol, VLDL-C = Very Low Density Lipoprotein- Cholesterol

Table 2: Levels of Malondialdehyde (MDA) and Glutathione (GSH) in aorta and heart of broiler chickens infected with *Toxoplasma gondii*

Groups	MDA ( nmol g <sup>-1</sup> wet tissue)		GSH ( mmol g <sup>-1</sup> wet tissue )	
	Aorta	Heart	Aorta	Heart
Control	125±1.05	105±0.33	0.622±0.022*	0.773±0.026
Infected	529.8±2.32*	455.3±0.43*	0.273±0.01	0.421±0.031

-Broiler chickens infected intraperitoneally by 1 mL containing 50 tissue cyst of *T.gondii*, -Values are expressed as means±SD of 10 broiler chickens per group - (\*) significant difference at p≤0.05

**Assessment of tissue MDA and GSH:** Lipid peroxidation in aorta and heart was measured by Thiobarbituric Acid (TBA) test that previously described (Al-Kennany, 2006). GSH of aorta and heart was measured according to the procedures described by Luna (1968).

**Autopsy:** Chickens were killed by cervical dislocation and immediately after death, aorta was dissected from the arch, rinsed with normal saline and opened along the intercostals. The opened aortas were flattened on strips of paper with the intimal side up. The vessels were fixed face down overnight with 10% buffered formalin at room temperature. For remarking areas of atheroma, fixed aortas were stained with Sudan IV.

**Statistical analysis:** One way ANOVA were used for testing control and infected groups. Differences of p≤0.05 were considered significant.

## RESULTS

**Isolation and identification of parasite:** *Toxoplasma gondii* was detected by direct microscopical examination of impression smears from brain and heart of infected backyard chickens and stained with Giemsa stain. In experimentally infected broilers, parasite have been isolated 72 h post intraperitoneal infection.

**Lipid profile assay:** Table 1 illustrates that all lipid profile of *Toxoplasma gondii* infected broilers were significantly increased, except HDL-C, where it revealed significant decrease as compared with the control group.

**Tissue MDA and GSH levels:** Aortic and heart TBA reactive substances, the end product of lipid peroxidation essentially MDA, were significantly increased in infected broilers at 45 days P.I. as compared with control group (Table 2). The greatest increasing was seen in aorta in comparison with heart (529.8±2. 32 vs 455±0.43).

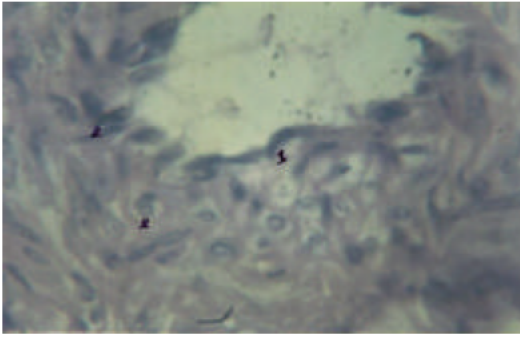


Fig. 1: Photomicrograph in aorta of infected broilers with *T. gondii* after 45 days, revealed hypertrophy of endothelial cells in intima (1) and presence of tachyzoit in intima and media (2). H and E. 1000X

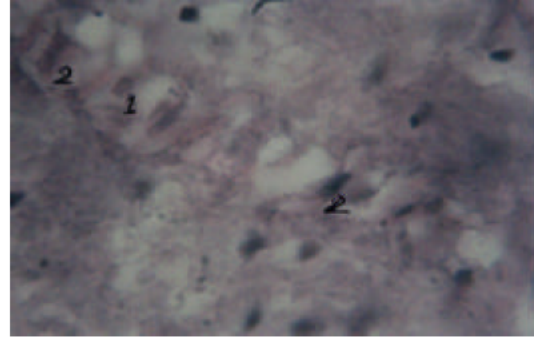


Fig. 4: Photomicrograph in aorta of infected broilers with *T. gondii* after 45 days, revealed proliferation of VSMCs (1) and localization of lipid vacuoles in media (2). H and E. 400X

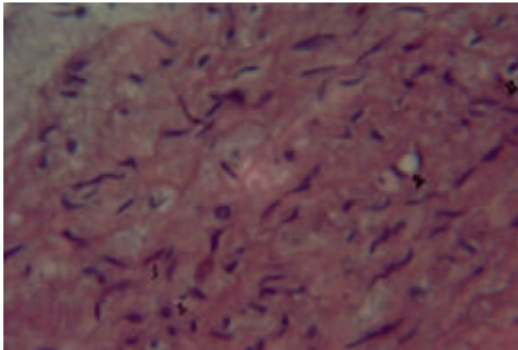


Fig. 2: Photomicrograph in aorta of infected broilers with *T. gondii* after 45 days, revealed accumulation of tachyzoit in intima and media (1) and localization of lipid vacuole in media (2). H and E. 400X

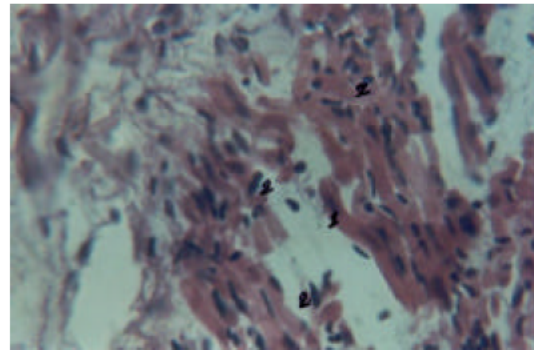


Fig. 5: Photomicrograph in heart of infected broilers with *T. gondii* after 45 days, revealed hypertrophy of myocardial cells (1) and presence of tachyzoit between muscle bundles (2). H and E. 400X

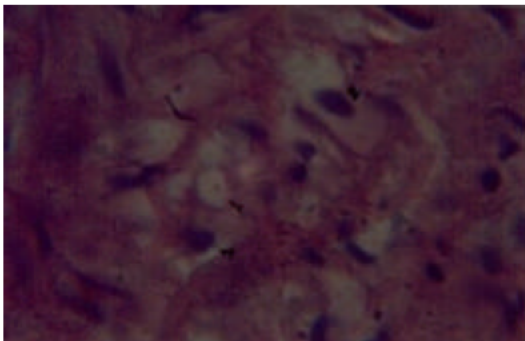


Fig. 3: Photomicrograph in aorta of infected broilers with *T. gondii* after 45 days, revealed Foam cells in media (1) and presence of tachyzoit (2). H and E. 1000X

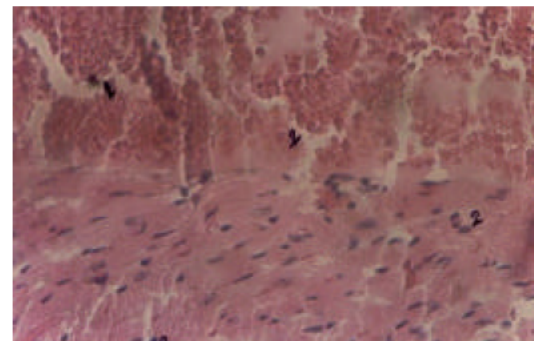


Fig. 6: Photomicrograph in heart of infected broilers with *T. gondii* after 45 days, revealed congestion and invasion of tachyzoit into RBC (1) and presence of tachyzoit between muscle fiber (2). H and E

In other side, GSH levels of these tissues (aorta and heart) in infected broilers were significantly decreased as compared with the control one (Table 2).

#### Pathological changes

**Macroscopically:** Aortic intimal fatty streaks were present in broilers infected with *T. gondii*, which

detected only after Sudan IV staining (Sudanophilia) and appear as a flat or very slightly elevated intimal streaks and spots of sharply demarcated Sudanophilia as compared with control group. The heart of infected broilers revealed cardiomegaly with presence of small white necrotic foci.

**Microscopically:** In the infected broilers, aortic lesions represented by thickening in the wall due to localization and accumulation of lipid vacuoles in media extend towards intima associated with proliferation and hypertrophy of Vascular Smooth Muscle Cells (VSMCs), hypertrophy of endothelial cells with invasion of tachyzoit in these cells. Some aortic sections revealed accumulation of tachyzoit in the cytoplasm of VSMCs as well as presence of foamy cells between these muscle cells with fragmentation of elastic lamellae and infiltration of lymphocytes (Fig. 1-4).

Heart sections of infected broilers with *T. gondii* shows infiltration of inflammatory cells represented by lymphocytes; accumulation of tachyzoit around the blood vessels and some of tachyzoit have been invading red blood cells; myocardial cell swelling that become hypertrophied and tissue cyst well recognized between muscle fibers (Fig. 5 and 6).

## DISCUSSION

This study revealed successful results confirming that *T. gondii* induce an oxidative stress status in experimentally infected broilers. This confirmation approved by: The lipid profile picture (Table 1), which revealed hypercholesterolemia and hypertriglyceridemia and the lipid peroxidation status that characterized by significant increase in MDA level, which considered as a secondary byproduct of lipid peroxidation, concomitant with a significant decrease of GSH level, in both aortic and heart tissues of *T. gondii* infected broilers (Table 2). However, the hypercholesterolemia that induced in *T. gondii* infected broilers can not be explained this time and may need further study for its clarification.

These observation may carry more evidence for supporting the hypothesis that suggest the role of *T.gondii* in atherogenesis via the induction of lipid peroxidation (Morre *et al.*, 2000). Parallely, these observations were in accordance with those seen in mice and cats infected by *T. gondii* (Nenseter *et al.*, 1994; Morre *et al.*, 2000). Moreover, the oxidative stress status achieved in broilers of this study resemble the oxidative status observed in chickens treated orally with 0.5% H<sub>2</sub>O<sub>2</sub> (Hassan *et al.*, 2000; Stocker and Keane, 2004).

It has been hypothesized that *T. gondii* may cause endothelial injury during its invasion and proliferation releasing phospholipids which contributes to further Reactive Oxygen Species (ROS), e.g., NO and oxidized lipoprotein which enhancing the oxidative stress status, resembling that mentioned in mice (Moron and Depierre, 1979). These events may be associated with production of hepatic lipoprotein lipase (after invasion the hepatocytes by tachyzoit), leading to elevation of cholesterol, triglycerides and, VLDL levels in plasma. This suggestion needs more evidence. Increasing level of LDL-C in the circulation may exert endothelial dysfunction (Al-Kennany, 1998) then, LDL-C which accumulate in the sub endothelial space, in the presence of tachyzoit and the action of ROS, LDL will become oxidized (ox-LDL). They were reported previously that the chemotactic effect of ox-LDL for monocytes and tissue macrophages were significantly decreased in the presence of HDL-C (Moron and Depierre, 1979). Our results revealed that *T. gondii* infection reduced levels of HDL-C in aorta and heart tissues of infected broilers (Table 1). It was suggested that HDL-C can prevent the oxidative modification of LDL-C and its role in cholesterol metabolism by facilitating reverse cholesterol transport was clearly documented (Halliwell, 1999).

Histological examination of the aorta of the infected broilers elucidates the existence of primary atheromatous lesions (Fig. 1-4). This facts in part may confirm the induction theory of endothelial injuries induced by oxidative stress status generated by *T. gondii* and on the other side, these pathological lesions resemble those generated by this parasite in mice and cats (Nenseter *et al.*, 1994; Morre *et al.*, 2000). Atherogenesis induced during *T. gondii* infection of broiler, may include the activation of procoagulant factors like Hugman factor (platelet aggregation), leading to the formation of parasitic thrombi at the site of endothelial injury. Furthermore, oxidative stress status stimulate the generation of growth factor for VSMCs and active vascular substances represented by Nitric Oxide (NO), that activate the endothelial vascular tension and enhancing the mitogenic events and proliferation of VSMCs (Hajjar *et al.*, 1987). These events regarded as the first primary change in atherosclerosis.

## CONCLUSION

In conclusion, this study remarked the oxidative role of *T. gondii* in experimentally infected broiler chickens. The oxidative status characterized by quite clear hypercholesterolemia and the capability of this oxidation to induce atherosclerotic lesions in aorta of these chickens.

**REFERENCES**

- Al-Kennany, E.R., 1998. A study on the capability of oxidative stress by hydrogen peroxide to induce atheromatous lesions experimentally in chickens. Ph.D. Thesis, University of Mosul, Mosul, Iraq.
- Al-Kennany, E.R., 2004. Role of oxidative stress associated with experimental *Enterococcus faecalis* infection for initiation and development of atherosclerosis in rat. *Iraqi J. Vet. Sci.*, 18: 135-144.
- Al-Kennany, E.R., 2006. Capability of toxoplasma gondii to induce an oxidative stress and initiation of atherosclerotic lesions in cats experimentally infected. *Iraqi J. Vet. Sci.*, 20: 165-176.
- Cheville, N.F., 1988. Cell Pathology. (2nd Edn.), The Iowa State University Press. Ames, Iowa.
- Dubey, J.P., D.S. Lindsay and C.A. Speer. 1998. Structure of toxoplasma gondii tachyzoites, bradyzoites and sporozoites and biology and development of tissue cysts. *Clin. Microbiol. Rev.*, 11: 267-299.
- Gilbert, S.D.D. and J.R. Rothem, 1984. A method to correct for errors caused by generation of interfering compounds during erythrocyte lipid peroxidation. *Ann. Biochem.*, 137: 282-286.
- Hajjar, D.P., Z.K.B. Pomerant, D.J. Falcone, B.B. Weksler and A.J. Grant, 1987. Herpes simplex virus infection in human arterial: implications in atherosclerosis. *J. Clin. Invest.*, 80: 1317-1321.
- Halliwell, B., 1999. Antioxidant and human disease: A general introduction. *Nutr. Rev.*, 55: 544-599.
- Hassan, S.M., E.R. Al-Kennany and H.A.K. Al-Hafez, 2000. Hydrogen peroxide induced atherosclerosis in chickens: Effects of vitamin C. *Iraqi J. Vet. Sci.*, 13: 249-270.
- Luna, L.G., 1968. Manual Histological Staining Methods of AFIPath. (3rd Edn.), New York, MacGraw-Hill book Co.
- Minick, C.R., C.G. Fabricant, J. Fabricant and M.M. Litrenta, 1979. Atherosclerosis induced by infection with a herpesvirus. *Am. J. Pathol.*, 96: 673-706.
- Moron, M.S. and J.W. Depierre, 1979. Mennervik. level of glutathione reductase and glutathione S-transferase activities in rats lung and liver. *Biochem. Biophys. Acta.*, 582: 67-78.
- Morre, S.A., W. Stooker, W.K. Lagrand, A.J.C. Vanden Brule and H.W.M. Niessen. 2000. Microorganisms in the etiology of atherosclerosis. *J. Clin. Pathol.*, 53: 647-654.
- Nenseter, M.S., O. Gumundsen, K.E. Malterud, T. Beg and C.A. Drevon, 1994. Effect of cholesterol on the susceptibility of lipoprotein to oxidative modification. *Biochem. Biophys. Acta.*, 1213: 207-214.
- Portugal, L.R., L.R. Frenandes, G.C. Cesar, H.C. Santiago, D.R. Oliverra, N.M. Silva, A.A. Silva, J. Lanes-Viera, R.M.E. Avantes, R.T. Gazzinelli and J.I. Alvarez-Leite. 2004. Infection with toxoplasma gondii increase atherosclerosis lesion in Apo E, deficient mice. *Infect. Immun.*, 72: 3571-3576.
- Ross, R., 1999. Atherosclerosis-an inflammatory disease. *N. Engl. J. Med.*, 340: 115-126.
- Ruef, J., K. Peter, T.K. Nordt, M.S. Rungs, W. Kubler and C. Bode, 1999. Oxidative stress and atherosclerosis: Its relationship to growth factors, thrombus formation and therapeutic approaches. *Thromb. Haemost.*, 82: 32-37.
- Stocker, R. and J.F. Keaney, 2004. Role of oxidative modification in atherosclerosis. *Physiol. Rev.*, 84: 1381-1478.