

Histopathological Absorption Trend Comparison Between Chronic Catgut Suture Materials Produced by Different Companies in Rabbits

¹N. Hadjipour, ²M. Marjani, ³R. Sedaghat and ⁴S.H. Marjanmehr

¹School of Veterinary Medicine, Islamic Azad University,
Science and Research Branch, Tehran, Iran

²Department of Surgery, Islamic Azad University, Karaj Branch, Karaj, Iran

³Department of Pathology, Faculty of Medicine, Shahed University, Tehran, Iran

⁴Department of Pathology, Faculty of Veterinary Medicine, Tehran University, Tehran, Iran

Abstract: The chronic catgut sutures are the most common suture materials in surgical operations. The purpose of this *in vivo* study was to histopathologically evaluate the inflammatory reactions incited by five different kinds of catgut suture materials. Five different catgut suture materials from five companies were compared with each other. Thirty five adult New Zealand white rabbits, fed a solid diet, were divided into five groups of five rabbits each. Five kinds of catgut suture materials were implanted into the back and thigh muscles. After 1, 3, 7, 14 and 28 days, the animals were sacrificed and the suture materials plus the subcutaneous and muscle tissues were removed from the implanted areas. Results revealed that there were significant differences between the granulomatous inflammatory reactions of used suture materials ($p < 0.05$). Statistical analysis to compare each two suture materials were performed and in the most of them the differences were significant. Furthermore, statistical analysis were performed to compare all of the 5 suture materials. As a result, it can be considered that because raw materials of these sutures which are from the intestine of particular animals are different, the pathological effects of these materials are variable and this matter is not matched with the rules of standards about the materials being used in medicine and veterinary medicine. So, these suture materials had better not be recommended anymore.

Key words: Chronic catgut, granulomatous inflammation, histopathological

INTRODUCTION

Suture materials are widely used in surgical operations and role of absorbable ones are extremely important (Turner, 1995). Regarding the wide usage of chronic catgut suture materials especially in third world countries, this study looked necessary.

Regarding the various source of these materials production (animals intestines), the products are various too, so that catgut suture materials produced in different companies show various characteristics, even one company's products sometimes have different outcomes. Synthetic absorbable and nonabsorbable suture materials have an equal production formula and trend, so equal and standard situations can be determined for them. But because of various source of catgut suture materials, diet variations, species, different climates and geographical situations, genetical variations and etc., there is no equal and integrated production of catgut suture materials.

It has been showed that, in equal surgery situations by one surgeon, the results taken from catgut suture materials are different (Marjani and Hashemi, 2006). So, we decided to investigate the histopathological affections and absorption trend of five different catgut suture materials in rabbits and confirm the inappropriacy of these materials to be used in surgeries.

MATERIALS AND METHODS

At first, 36 adult New Zealand white rabbits, weighing 2/5 B 3/5 were chosen and randomly divided in six groups based on time (days 1, 3, 7, 14 and 28) and a group as control so that 6 rabbits were placed in every group.

The considered catgut suture materials were coded as A, B, C, D and E. Then 8 areas on every rabbit were determined, 6 areas on back of the animal (3 every side) and one area on every thigh. It should be indicated that the method of implanting of the suture materials on the back of rabbits was passing method. That is, they were

passed by a needle through the muscles longitudinally without any incision. But one incision was made in every thigh muscle and the suture material was used to suture the incision.

Then, every group's rabbits were scarified on the predetermined days and histopathological samples were taken and after being fixed, histopathological slides were provided (H and E).

RESULTS AND DISCUSSION

Then provided slides were examined by light microscope. Naturally, granulomatous inflammation was an equal property of all the slides. The studied factors in every slide included: Capsule thickness, inflammation expansion, Inflammation severity, angiogenesis, absorption level and swelling level, which were scored in 0-3 by defined criteria. These criteria included:

Capsule thickness:

- No observation of connective tissue and fibers around the suture material.
- Observing connective tissue and fibers with <50 µm thickness.
- Observing connective tissue and fibers with between 50 B 100 µm thickness.
- Observing connective tissue and fibers with more than 100 µm thickness.

Inflammation expansion:

- No observation of inflammatory cells.
- Observing inflammatory cells in 1 or 2 microscopic sights.

- Observing inflammatory cells in 2-5 microscopic sights.
- Observing inflammatory cells in more than 5 microscopic sights.

Inflammation severity:

- No observation of inflammatory cells.
- Observing inflammatory cells with high empty spaces between them.
- Observing inflammatory cells with low empty spaces between them.
- Observing inflammatory cells with almost no empty spaces between them.

Angiogenesis:

- No observation of new blood vessels in 10 microscopic sights (400x).
- Observation average of 1-5 blood vessels in 10 microscopic sights.
- Observation average of 5-10 blood vessels in 10 microscopic sights.
- Observation average of more than 10 blood vessels in 10 microscopic sights.

Then the written scores were analyzed by statistical tests (Table 1).

As it was seen, every factor in different suture materials showed some significant and insignificant differences and varieties. The results didn't show any equality in every catgut suture material or between them in studied factors. Some slides views are shown here as examples (Fig. 1-5).

Table 1: An example of suture materials comparison based mean differences about Inflammation expansion

Dependent variable	(I)	(J)	Mean differences (I-J)	Std. Error	p-value	95% confidence interval	
						Lower bound	Upper bound
Swelling expansion	A	B	0.0280	0.14731	0.851	-0.2793	-0.3353
		C	-0.6880*	0.14731	0.000	-0.9953	-0.3807
		D	-0.4860*	0.14731	0.004	-0.7933	-0.1787
		E	-0.1040	0.14731	0.488	-0.4113	0.2033
		A	-0.0280	0.14731	0.851	-0.3353	-0.2793
	B	C	-0.7160*	0.14731	0.000	-1.0233	-0.4089
		D	-0.5140*	0.14731	0.002	-0.8213	-0.2067
		E	-0.1320	0.14731	0.381	-0.4393	0.1753
		A	0.6880*	0.14731	0.000	0.3807	0.9953
		B	0.7160*	0.14731	0.000	0.4087	1.0233
	C	D	0.2020	0.14731	0.185	-0.1053	0.5093
		E	0.5840*	0.14731	0.001	0.2767	0.8913
		A	0.4860*	0.14731	0.004	0.1787	0.7933
		B	0.5140*	0.14731	0.002	0.2067	0.8213
		C	-0.2020	0.14731	0.185	-0.5093	0.1053
D	E	0.3820*	0.14731	0.017	0.0747	0.6893	
	A	0.1040	0.14731	0.488	-0.2033	0.4113	
	B	0.1320	0.14731	0.381	-0.1753	0.4393	
	C	-0.5840*	0.14731	0.001	-0.8913	-0.2767	
	D	-0.3820*	0.14731	0.017	-0.6893	-0.0747	

*The mean difference is significant at the 0.05 level

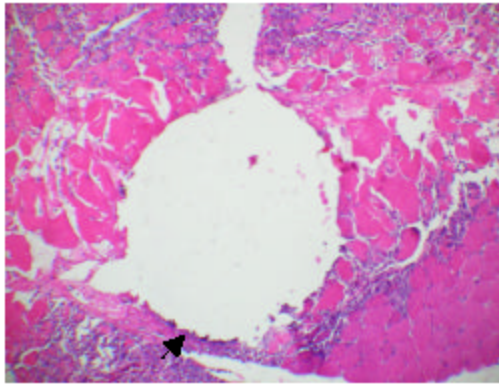


Fig. 1: A microscopic view of passage place of catgut suture material B by passing method on 3rd day. An obvious layer of capsule formed around the suture material is shown by the arrow 100x (H and E)

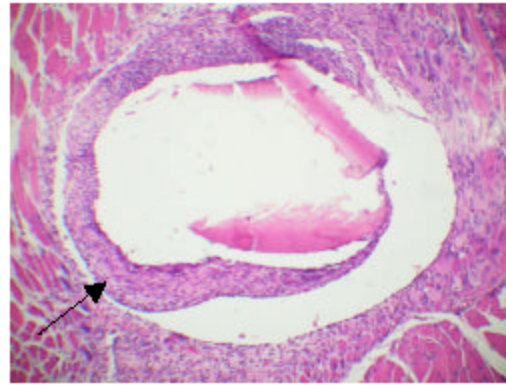


Fig. 3: A microscopic view of passage place of catgut suture material D by suturing method on 14th day. Fibrous capsule is shown by the arrow and the remains of the suture material is centrally seen in pink color 100x (H and E)

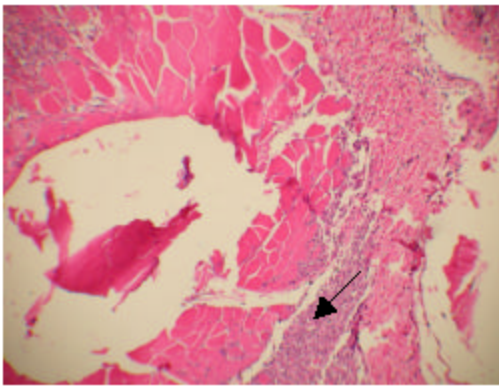


Fig. 2: A microscopic view of passage place of catgut suture material D by suturing method on 7th day. Granulomatous Inflammation is obviously seen around it with high accumulation of inflammatory cells are shown by the arrow 40x (H and E)

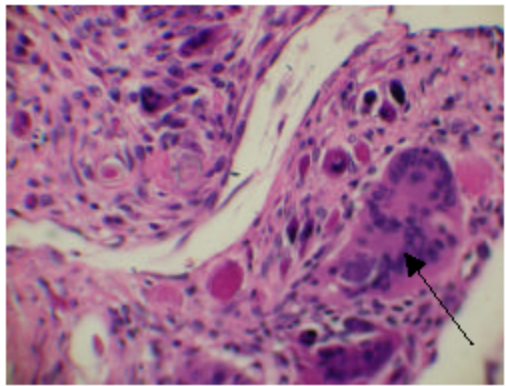


Fig. 4: A microscopic view of passing place of catgut suture material C by suturing method on 14th day. A typical giant cell with multiple nucleuses is shown by the arrow which is a certain sign of granulomatous inflammation 400x (H and E)

As it was seen, the inflammation expansion in five catgut suture materials showed five different results. It has been shown that catgut suture materials show the highest inflammatory reactions and expansion compared with the synthetic ones such as Vicryl and Polypropylene and were identified as the most inconvenient suture materials (Yaltrik *et al.*, 2003). But in another study, it was seen that between catgut suture materials, One of them (Ethicon) had higher quality than others, however, differences between the kinds of them did exist (Kranopolsky and Shvets, 1994). In one different study, there was no significant difference between the catgut suture materials available in markets (Engels, 2000), which are completely opposite the results of this study and other ones.

There were significant differences between the catgut suture materials with respect to Inflammation expansion and severity in one recent study (Marjani and Hashemi, 2006), which this study confirms its results.

About absorption and swelling levels, some significant and insignificant differences were found which showed the lack of one defined rate of absorption in catgut suture materials. In scoring the slides about swelling, the more score, the more swelling, the suture material had and therefore, induced more tissue damage. And in absorption score, the more score, the earlier absorption the suture material had and therefore, it was absorbed faster even before forming a sufficient healing. In these two factors, different scores were found. It has

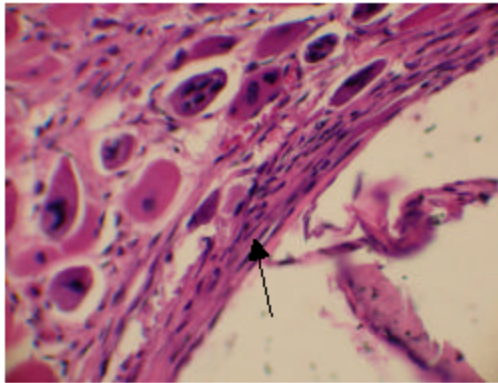


Fig. 5: A microscopic view of the tissue around the passing place of suture material C on 14th day. The fibrous capsule is shown by the arrow 400x (H and E)

been proved that catgut suture materials aren't well enough to be used because of high level of absorption speed and swelling (Luis *et al.*, 1998). Also, it has been shown that because of high probability of cesarean sutures opening after operations, catgut suture materials aren't convenient for cesarean (Spencer and Grant, 1986; Spencer, 1991).

In some studies done in two different places, catgut suture materials were identified inconvenient to be used in surgeries because of high inflammation severities and expansions (Johnson and Issever, 2000).

It should be said that in this study, only in two suture materials, a reasonable level of angiogenesis was seen and also, little differences between the capsule thicknesses but not significant existed.

By all these statements, it can be said that like in other studies, different and various results about each examined factor were found and the results were different rabbit by rabbit, time by time and material by material. So, it is reasonable to think better about synthetic suture materials. It has been indicated that synthetic suture materials compared with catgut ones had a better and considerable priority (Joseph *et al.*, 2003). Also, in another study, a synthetic suture material (Polyglactin 910) made better results than catgut one in cervix surgery (Nathalie and Leroux, 2006). So, it is suggested that

surgeons, especially the countries which still use catgut suture materials, tend to synthetic absorbable ones which offer better and predictable results.

REFERENCES

- Engels, M., 2000. Intracutaneous skin sutures using Vicryl Rapide in the infant and young child. Somerville, NJ: Ethicon Inc., 7 (6): 1054-1059.
- Johnson, M. and H. Issever, 2000. A technological innovation among absorbable sutures. Gateway, 9 (8): 765-768.
- Joseph, G., D. Gary and D. Becker, 2003. Comparison of absorbable with nonabsorbable sutures in closure of facial skin wounds. Arch. Facial. Plast Surg, 5 (6): 488-490.
- Kranopolsky, V. I. and R. I. Shvets, 1994. Utilization of the new synthetic dissolving sutures caproag in obstetrics and gynecology. Med. Technol., 3: 38-40. PubMed 7934731.
- Luis, E., S. James and A. Patterson, 1988. Comparison of Maxon suture with Vicryl chromic catgut and PDS sutures in fascial closure in rats. BJOD, 71: 418-422.
- Marjani, M. and M. Hashemi, 2006. Histopathologic comparison of catgut suture materials in rabbits. Ph.D. Thesis, pp: 120-130.
- Nathalie, M.D. and Leroux, 2006. Impact of chromic catgut versus polyglactin 910 versus fast-absorbing polyglactin 910 sutures for perineal repair: A randomized controlled trial. OVID, 194 (6): 1585-1590.
- Spencer, J. and A. Grant, 1986. A randomized comparison of glycerol-impregnated chromic catgut with untreated chromic catgut for the repair of perineal trauma. BJOG, 93 (5): 426-430. DOI: 10.1111/j.1471-0528.1986.tb08651.x.
- Spencer, J., 199. Comparison of different catgut sutures. BJOG, 122: 420-423.
- Turner, S., 1995. Techniques in Large Animals Surgery. 2nd Edn., pp: 73-85.
- Yaltrik, L., K. Dedeoglu and B. Bilgic, 2003. Comparison of four different suture materials in soft tissues of rats. In: Blackwell, P., 9 (6): 284-286. DOI: 10.1034/j.1601-0825.00954.x.