

## Partial Pancreatectomy in Dogs

<sup>1</sup>E. Paz, <sup>1</sup>C. Romero, <sup>1</sup>A.C. García, <sup>1</sup>G.D. Mendoza, <sup>1</sup>F.X. Plata and <sup>2</sup>N. Ramírez

<sup>1</sup>Departamento de Produccion Agricola y Animal,

Universidad Autónoma Metropolitana, Mexico City, Mexico

<sup>2</sup>Facultad de Medicina, Universidad Autonoma del Estado de Mexico,

Toluca City, Mexico

**Abstract:** Partial pancreatectomy was performed in 7 dogs to obtain viable tissue as an alternative treatment of Diabetes Mellitus using a step denominated omentalization to avoid the formation of adhesions, reducing vomit and pancreatitis reported in other procedures. The results did not show pathognomic signs of Exocrine Pancreatic Insufficiency (EPI) or pancreatitis. The pain was alleviated with Meloxicam ( $0.2 \text{ mg kg}^{-1}$ ) IV and ketamine (intravenous infusion  $0.5 \text{ mg/kg/hour}$ ). Glycemic values post surgery in the dogs stayed between 100 and  $110 \text{ mg dL}^{-1}$  until the tenth day that concluded the study (mean  $106.9 \text{ mg dL}^{-1}$ ). The test of plasma turbidity was realized to discard the EPI, being negative when there was a presence of turbidity 2 h after the administration of food added with corn oil. The technique of partial pancreatectomy in canine can be used to future transplants of islets of Langerhans. The glucose blood levels indicated that the resection of the left lobe of the pancreas did not affect the functional stability of the patient in short term.

**Key words:** Pancreatectomy, dogs, surgery, pancreas, transplant

### INTRODUCTION

Diabetes Mellitus is an endocrinopathy which alters the metabolism of carbohydrates, caused by a dysfunction of the islets of Langerhans from the pancreas causing a reduction of insulin secretion, resulting in hyperglycemia and glycosuria (Hall, 1997). The etiology is multi-factorial with different environment and genetic factors such as obesity which predispose the presentation of clinical diabetes (Loste *et al.*, 2001).

Recent studies have demonstrated that insulin therapy and a fibrous diet are not enough to compensate the glucose level in blood, reason why it has been explored the pancreas transplant as an alternative to compensate the damages caused by the partial or absolute deficiency of beta cells insulin producers (Liu and Herold, 2000; White *et al.*, 2001). A pancreas transplant is a surgery to implant to a healthy pancreas from donor into patient with diabetes and give the patient the opportunity to become independent of insulin injections. The pancreas canine is characterized to show a substantial regenerative capacity. The resection in 75-90% of pancreatic tissue has demonstrated functionality, as long as the conducts have not been damaged during the intervention (Slatter, 2004).

Partial pancreatectomy, also well-known as distal pancreatectomy or hemipancreatectomy, is a surgical technique indicated in company animals for treatment of neoplasias, cysts, abscesses, traumatismos or biopsy (Stagner *et al.*, 1991) and has been used in dogs since 1962 (Zefirov, 1962). Other procedures did not use the omentalization (Johnson and Mann, 2006) and present problems such as adhesions, autolysis by pancreatic enzymes, pancreatitis and vomit (Allen *et al.*, 1989; Balcom *et al.*, 2002; Ettinger and Feldman, 2002; Slatter, 2004).

Therefore, the objective was to perform partial pancreatectomy in dogs with omentalization to obtain viable tissue and diminish post surgical complications as a previous step in the pancreas transplant procedure.

### MATERIALS AND METHODS

Procedures were realized in the Veterinary Clinic Unit of the Autonomous Metropolitan University Xochimilco. The anesthesia was in accordance with the Veterinary Clinic Unit, as accepted by the research and medical ethics committees of the Veterinary School. Six male and one female crossbred dog with age between 2 and 5 years, with a mean weight of 15 kg were used.

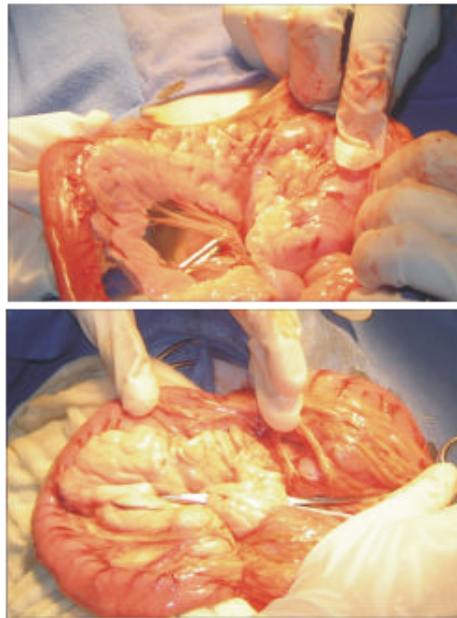


Fig. 1: Retraction of the greater omentum to display the pancreas covered with dampened compress of saline solution

During the first 2 days the dogs were bathed, housed in individual cages and fed with commercial diets ( $4140 \text{ kcal ME d}^{-1}$ ) and water ad libitum. The third day were fasted (food and water) during 10 h to perform the surgical technique of partial pancreatectomy.

Dogs were initially dosed with Acepromacin  $0.1 \text{ mg kg}^{-1} \text{ i.m}$  and Butorfanol  $0.1 \text{ mg kg}^{-1} \text{ s.c}$ . The anesthesia was inducted with Propofol  $2 \text{ mg kg}^{-1} \text{ i.v}$  and maintained with Isoflurano diluted in oxygen at 100% (Plumb and Pharm, 2002).

The surgical procedure started in the abdominal cavity performing an incision on the middle line. Then the fat and the subcutaneous tissue were dissected until the visualization of the white line. Then the omentum was retracted cranially to observe the pancreas (Fig. 1). Later the gastocolic ligament was separated being exhibited both pancreatic lobes right and left, which were covered with compress dampened in saline solution at 0.9%. It was dissected the plane between the portal mesenteric and the later face of the neck of the pancreas (Fig. 2) using an absorbent polyglycolic acid suture (3-0) around the same realizing a surgeon knot applying the suture technique of fracture. On this way, the left lobe was free to be sectioned. At the end of surgical procedure, the remaining portion of the pancreas was covered with the greater omentum which was sutured with absorbent material

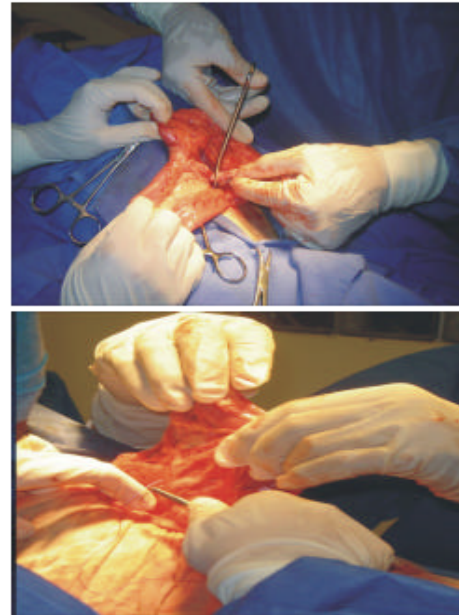


Fig. 2: Dissection of the pancreatic left lobe and remaining of the pancreas covered the greater omentum (omentalization) sutured with absorbent material

polyglycolic acid suture (3-0) in order to provide irrigation to the pancreas. Finally, the cavity was closed by planes using the suture absorbent (3-0).

After 1 h of the surgery, sanguineous samples were collected to determine blood glucose levels with reactive strips (Dextrostix®) every 2 h during the first days. Then during the following 6 days, glucose levels were checked twice per day (08:00 and 16:00). The dogs were maintained with solid restriction during 2 days. Subsequent to those days, the feeding began with the water ingestion and with canned food later with the diet for diabetic dogs from Hill's Pet Nutrition, Inc.

On day 9, tests were realized to discard Exocrine Pancreatic Insufficiency with the assay of turbidity of the plasma, observing the appearance of plasma (lipemia) that occurs 2 h after oral administration of  $2 \text{ mL com oil kg}^{-1}$  body weight. After 10 days, dogs were euthanatized using sodic pentobarbital (Sedalport®)  $25 \text{ mg kg}^{-1} \text{ i.v}$ . (Thurmon *et al.*, 1996). Post mortem examination was conducted to determine presence of pancreatitis, adhesions and ulcers, focal Inflammation or multifocal Inflammation caused by the distal pancreatectomy.

## RESULTS AND DISCUSSION

In difference to other procedures reported in literature (Allen *et al.*, 1989; Balcom *et al.*, 2002), it was

used a tie technique fractures, to only retire a portion of pancreas (left lobe), without having to sacrifice the donor. The main difference in this procedure was step denominated omentalization (Johnson and Mann, 2006), that consists in placing the omentum on the zone of incision of the pancreas (Fig. 2). This action avoids the formation of adhesions and accelerates the healing process, reducing autolysis by pancreatic enzymes. This procedure result in abolition of vomit (Ettinger and Feldman, 2002) and pancreatitis reported in other procedures (Allen *et al.*, 1989; Slatter, 2004). The omentalization has been used to treat pancreatic abscess in dogs (Johnson and Mann, 2006).

During the first 2 days after surgery, all the dogs showed pain degree five according to Holton (2001), manifesting vocalizations, pale mucous, retraction of the labial commissures, muscular tremor generalized, resistance to movement, bent position and “prayer” position, accentuating more in 2 dogs (numbers 1 and 2). Pain was associated to the manipulation of the pancreas (García, 2001).

The administration of Meloxicam 0.2 mg kg<sup>-1</sup> i.v. and ketamine in infusion intravenously (0.5 mg kg<sup>-1</sup> of BW) during 24 h was satisfactory to alleviate the pain, showing improvements after 24 h post-administration. Only 2 dogs loss weight (numbers 1 and 4) and at the end of the period, most of the dogs shoed a positive energy balance (Table 1).

The blood glucose levels in the dogs during the experiment stayed between 100 and 110 mg dL<sup>-1</sup> without any episodes of hyperglycemia or hypoglycemia (Table 1). Those valued indicated that the pancreas maintained its function integrally after the surgery.

The vomit was observed in two dogs the second day and in one the 3rd day post surgery, when solid food was offered in small portions. Diarrhea was presented in one dog on the seventh day. None of the dogs show any sign of Exocrine Pancreatic Insufficiency (EPI) according to the qualitative test of turbidity of the plasma. It is possible that EPI signs were not detected because it appears 3 months after the intervention of the pancreas (Kogire *et al.*, 1993) which is an autoimmune process with total destruction of pancreatic parenquimal. However, there was no presence of any sign such as dramatic weight loss, intake disorders and feces voluminous which indicates the presence of EPI (Wiberg and Westermarck, 2002; Moeller *et al.*, 2002).

On day 3 after the intervention, all the dogs responded positively accepting water for drink and solid food, without diarrhea or flatulence. The emesis and anorexia was not associated with pancreatitis (Allen *et al.*, 1989). Ettinger and Feldman (2002) have associated the

Table 1: Characteristics of the dogs and mean glucose concentration in blood during 10 days after pancreatectomy

No.	Age (year)	Sex	Initial weight (kg)	Final weight (kg)	Glucose (mg dL <sup>-1</sup> )
1	5	Male	29.8	28.0	107.5
2	4	Male	22.0	23.6	103.7
3	2	Male	9.3	9.3	108.7
4	4	Male	17.8	16.0	106.2
5	6	Male	15.8	15.0	107.5
6	2	Male	9.7	12.2	106.2
7	3	Female	24.5	24.6	108.7

vomit and the diarrhea with inflammation of the small intestine in the procedure of partial pancreatectomy.

The post-mortem examination showed adhesions from the greater omentum with the ventral part of the stomach and duodenum, without characteristic lesions of pancreatitis. Allen *et al.* (1989) reported lesions of pancreatitis in dogs subjected to pancreatectomy. In this study, none canine presented hemorrhage. Only 1 dog showed pancreatitis, presence of focal and multifocal fibrosis and an apparent pancreatic fistula. Balcom *et al.* (2002) reported the formation of pancreatic fistulae as a consequence of the partial pancreatectomy, from 15-25% of the cases. This complication was avoided using synthetic absorbent material in the portion of the pancreas which is separated.

## CONCLUSION

The procedure to perform a partial pancreatectomy described here can be used to obtain viable pancreatic tissue as a previous step in a pancreas transplant in dogs. The blood glucose levels indicated that the integrity of the pancreas was not affected in the dogs. The post mortem examination indicated that the complications of pancreatic fistula represented only 14% (1 in 7 dogs) which is lower percentages reported with the procedure. In short term Exocrine Pancreatic Insufficiency was not presented, however, long term studies are required to evaluate the complete efficacy of this procedure.

## REFERENCES

- Allen, S.W., L.M. Cornelius and E.A. Mahaffey, 1989. A comparison of two methods of partial pancreatectomy in the dog. *Vet. Surg.*, 18: 274-278.
- Balcom, H.J., T. Keck, B. Antoniu, L.A. Warshaw, G.F. Cook, C. Fernández del Castillo and M.A. Boston, 2002. Prevention of clinical significant pancreatic fistulae with a new synthetic, absorbable sealant after distal pancreatectomy in the normal dog. *Dig. Dis. Week*, 195: 490-496.

- Ettinger, J.S. and C.E. Feldman, 2002. *Tratado de Medicina Veterinaria. Enfermedades del perro y gato*. 5th Edn. Mc Graw Hill Interamericana, pp: 129-139.
- García, F.P., 2001. *Terapéutica del Dolor. Canis et Felis*, 52: 1-80.
- Hall, G., 1997. *Fisiología Médica*. McGraw Hill Interamericana, pp: 736.
- Hess, S.R., H.P. Kass and R.C. Ward, 2000. Breed distribution of dogs with diabetes mellitus admitted to a tertiary care facility. *J. Am. Vet. Med. Assoc.*, 16: 1414-1417.
- Holton L.L., J. Reid, E.M. Scott, P. Pawson and A.M. Nolan, 2001. Development of a behaviour-based scale to measure acute pain in dogs. *Vet. Rec.*, 148: 525-531.
- Johnson, M.D. and F.A. Mann, 2006. Treatment for pancreatic abscesses via omentalization with abdominal closure versus open peritoneal drainage in dogs: 15 cases (1994-2004). *J. Am. Vet. Med. Assoc.*, 228: 397-402.
- Kogire, M., K. Inoue, R. Doi, S. Sumi, K. Takaori, M. Yun, R. Hosotani and T. Tobe, 1993. Pancreatic exocrine deficiency alters partial pancreatectomy in conscious dogs. *Eur. J. Surg.*, 159: 283-286.
- Liu, H.E. and C.K. Herold, 2000. Transplantation of the Islets of Langerhans: New Hope for Treatment of Type 1 Diabetes Mellitus. *TEM*, 11: 379-382.
- Loste, A., M.M. Pérez and A. Unzueta, 2001. Clinical value fructosamine measurements in non-healthy Ddgs. *Vet. Res. Comm.*, 25: 109-115.
- Moeller, E.M., J.M. Steiner, L.A. Clark, K.E. Murphy, KR.T. Famula, D.A. Williams, E.M. Stankovics and S.A. Vose, 2002. Inheritance of pancreatic acinar atrophy in German Shepherd Dogs. *Am. J. Vet. Res.*, 10: 1429-1434.
- Plumb, C.D. and D. Pharm, 2002. *Veterinary Drug and Book. Handbook*. 4th Edn. University of Minnesota. pp: 1312.
- Slatter, D., 2004. *Textbook of Small Animal Surgery*. W B Saunders Co. 3rd Edn. pp: 753-763.
- Stagner, J.L. and E. Samols, 1991. Deterioration of islet beta-cell function after hemipancreatectomy in dogs. *Diabetes*, 40: 1472-1479.
- Thurmon, C.J., J.W. Tranquilli and J.G. Bendon, 1996. *Lumb and Jones Veterinary Anesthesia*. 3rd Edn. L.P Pincott William and Wilkins, pp: 862-896.
- White, S.A., R. Kimber, S.P. Veitch and L.M. Nicholson, 2001. Surgical treatment of diabetes mellitus by isles cell and pancreas transplantation. *Postg. Med. J.*, 177: 383-387.
- Wiberg, E.M. and E. Westermarck, 2002. Subclinical exocrine pancreatic insufficiency in dogs. *J. Am. Vet. Med. Assoc.*, 220: 1183-1187.
- Zefirov, L.N., 1962. The effect of partial pancreatectomy on the electrocardiogram in dogs. *Pathol. Physiol. Gen. Physiol.*, 54: 45-50.