

## Effects of the Bovine Amniotic Membrane on Corneal Healing with Acute Alkali Burns in Rabbits

<sup>1</sup>Ramazan Gonenci, <sup>1</sup>Muhammed Enes Altug, <sup>2</sup>Ahmet Koc, <sup>3</sup>Huseyin Oksuz and <sup>4</sup>Hayati Yuksel

<sup>1</sup>Department of Surgery, <sup>2</sup>Department of Histology and Embryology,  
Faculty of Veterinary, Mustafa Kemal University, 31040, Hatay, Turkey

<sup>3</sup>Department of Eye Diseases, Faculty of Medicine, Mustafa Kemal University, Hatay, Turkey

<sup>4</sup>Department of Pathology, Afyon Kocatepe University, Afyonkarahisar, Turkey

---

**Abstract:** The Bovine Amniotic Membrane (BAM) was transplanted on the right cornea of 8 adult rabbits after an alkali burn was created with 2.5 N NaOH. Density and area of the corneal opacity, area of the corneal epithelial defect, vascularization and complications were clinically evaluated. Left corneas of the same animals were used as active control group. At the end of the experiment, all the eyes were extirpated and histologically examined on light microscopy. BAM has decreased density and area of the corneal opacity and increased reepithelialisation, but promoted episcleral vasodilatation more prominently in clinical examination. Histologically; the distribution of Polymorphonuclear (PMN) leucocytes, corneal thicknesses, edema, keratinization, neovascularization and inflammation were significantly reduced by BAM compared to active control group. BAM was highly found to be effective to restore the corneal surface with acute alkali burns in the rabbit.

**Key words:** Bovine Amniotic Membrane, BAM, transplantation, cornea, alkali burn, rabbit

---

### INTRODUCTION

Limbal, conjunctival and corneal epithelia together maintain the ocular surface integrity with the tear film presence to protect the anterior segment of the eye (Kim and Tseng, 1995; Kozak *et al.*, 2002; Shenoy *et al.*, 2006). The most important prognostic factors in clinical evaluation of the chemical eye injuries are assessment of the corneal transparency and the status of the limbal stem cells (Kozak *et al.*, 2002). In alkali burns; proteinase, glycosidase, metalloproteinase, plasminogen activator and latent collagenase are produced by both injured epithelial and stromal keratocytes and PMN leucocytes. These enzymes play pivotal roles in formation of corneal ulceration and perforation (Kim *et al.*, 2000). The partial presence of limbal stem cells causes so-called conjunctival transdifferentiation (Kozak *et al.*, 2002). The loss of limbal stem cells results in recurrent epithelial defects with tear film abnormalities, neovascularization, conjunctivalization and ulceration with possible spontaneous corneal perforation (Kim and Tseng, 1995; Kozak *et al.*, 2002).

The amniotic membrane, which is the innermost layer of the fetal membranes and in contact with the fetus has

unique properties including antiadhesive effects, antiinflammatory reaction, reepithelialisation activity and bacteriostatic properties (Chen *et al.*, 2000; Kim *et al.*, 2000; Prabhasawat *et al.*, 2001; Shimazaki *et al.*, 1998). It also reduces corneal vascularization, scarring and pain and inhibits protease activity on wound healing, whereas, it can not prevent the loss or repopulate limbal stem cells (Azuara-Blanco *et al.*, 1999; Kim *et al.*, 2000; Kozak *et al.*, 2002; Shimazaki *et al.*, 1998). Another characteristic of it is the lack of immunogenicity (Azuara-Blanco *et al.*, 1999; Kim and Tseng, 1995; Shimazaki *et al.*, 1998). Amniotic Membrane Transplantation (AMT) was commonly used for reconstruction of the burned ocular surface (Kim *et al.*, 2000; Kobayashi *et al.*, 2003; Nakamura *et al.*, 2004). In cases of total limbal stem cell deficiencies and autoimmune disorders, the amniotic membrane fails and is required additional surgical interventions and it must be combined with limbal autograft transplantation or other alternative techniques in severe injuries because of the deficiency (Chen *et al.*, 2000; Hanada *et al.*, 2001; Kozak *et al.*, 2002; Shimazaki *et al.*, 1998). Recently, human (Azuara-Blanco *et al.*, 1999; Chen *et al.*, 2000; Prabhasawat *et al.*, 2001; Shimazaki *et al.*, 2002) and animal (Barros *et al.*, 2005; Kozak *et al.*, 2002) amniotic

membranes as a transplant and human amniotic fluid (Gonenci *et al.*, 2009; Herretes *et al.*, 2006) as a therapeutic agent have been commonly used in the eye for a few last decades.

The aim of the study was to clinically and histologically evaluate the effects of the Bovine Amniotic Membrane (BAM) on healing of corneal injuries exposed to acute alkali burns and to ascertain the outcome of the transplantation for a month in the rabbit.

## MATERIALS AND METHODS

Ten healthy female New Zeland white rabbits aged 7-8 months and weighing 2-3 kg were used in the study. The amniotic membrane with attached placenta was obtained from a healthy pregnant cow of 7 months of gestation age immediately after slaughtering. It was washed in saline solution, detached from the chorion by blunt dissection and cut to pieces 5×5 cm under aseptic conditions. The samples were placed in isotonic saline solution containing 1 mg mL<sup>-1</sup> sefazolin (®Cefamezin, Eczacibasi), taken to a refrigerator at a temperature of 2°C to minimize potential bacterial proliferation in the samples and used the following day. For premedication, 0.1 mg kg<sup>-1</sup> atropine (®Atropin, Vetas) and 5 mg kg<sup>-1</sup> xylazine (®Rompun, Bayer) were administered intramuscularly and then 40 mg kg<sup>-1</sup> ketamine (®Alfamine, Alfasan) was intramuscularly given. After general anesthesia and stabilization of the right eye globe, caustic 2.5 N NaOH (Sodium hydroxide) solution was applied to both central corneas of each rabbit for 30 sec using a 6 mm diameter filter paper ring immersed with 2.5 N NaOH and the burned area was washed by isotonic saline solution (0.9% NaCl) for 3 min to remove the residual chemical agent and protein coagulum. Surgery was done on day one after chemical burning to right eyes in 8 animals and the other eyes of these 8 animals were left as active control group. The 4 eyes of 2 rabbits left were extirpated the day after creation alkali burns for histopathological examination to establish passive control group.

All the eyes of animals were assigned to three groups as passive control (2 left and 2 right eyes, n = 4), active control (Left eyes, n = 8) and treatment (BAM, right eyes, n = 8) groups. The surgical procedure was done under the same general anesthesia in BAM group. Following the 360° peritomy, the amniotic membrane was placed on the right cornea with epithelial-side up and secured to the edge of limbus circumferentially by interrupted 10-0 nylon sutures. In the postoperative period, rabbits received lomefloxacin (®Okacin, Novartis) and sycloplegin (®Sikloplejin, Abdi Ibrahim) eye drops 3 times daily to both eyes for 2 weeks. The transplant eyes also received

dexamethasone (®Cebedex, Abdi Ibrahim) 3 times a day for 2 weeks. At the injury day and post injury days 15 and 30th, the eyes were photographed with a machine (Olympus DP12, Japan) attached to a stereomicroscope (Olympus SZ2-ILST, Japan) at magnification making the eye clearly seen after each eye is centered in the screen. Also, broken sutures were renewed in first 2 weeks in the treatment group.

In the clinical assessment, density and area of the corneal opacity, area of the corneal epithelial defect, neovascularization and presence of any complications of ocular surfaces were evaluated at the injury day and post injury days 15 and 30th by the instillation of sodium fluorescein in both eyes of each animal after excess fluorescein was rinsed away with one ml of isotonic saline solution and then photographs were taken.

All left and right eyes of the animals in active control and treatment groups were enucleated at the end of the treatment for histopathological evaluation, corneal thickness measurements and plasma cell counting. These eyes were fixed in 10% neutral buffered formalin solution for 24 h and prepared for paraffin embedding. Sections (6 µ) of corneas were stained with heamatoxylin and eosin (H and E). Methyl-green pyronin staining was also done to identify the plasma cells. These sections were evaluated by light microscopy for cell death and the structures of the basement membrane, epithelium and stroma. A corneal thickness, the distance between the epithelial surface and inner endothelial layer, was measured directly from paraffin sections using an ocular micrometer. For each cornea, four measurements (two peripheral and two central regions) were made. The plasma cells were counted in five randomly selected fields (×400) in sections stained with the methyl-green pyronin by an observer unaware of all groups in the stromal layers. For statistical analyses, SPSS for windows version 13 was used. Histologic results were analyzed using the Kruskal-Wallis one-way analysis of variance and intergroup comparisons were made by Mann Whitney U test. All results were expressed as mean±standard deviation and differences were considered significant when p<0.05.

## RESULTS

Every rabbit was followed up during 30 days after alkali burn creation. The clinical reports were done on days zero, 15 and 30th after the injury. Assessment categories including corneal neovascularization, reepithelialisation, opacification and complications were evaluated by the investigators independently. In general consideration, BAM was to be highly effective to restore the corneal surface with acute alkali burns in the rabbit.

**Clinical evaluation:** Density and area of the corneal opacity have decreased in BAM group, whereas, they both have not changed in active control group in clinical examination. Additionally, the edges of opacification gradually disappeared in treatment group at 15 and 30th day. But, it did almost not change throughout the whole follow up period in the active control. Iris and pupil of all burned eyes were obscured in burned regions throughout the study in the active control. The obscurity has slightly decreased at 15 and 30th day, respectively in BAM group. The epithelial defect generally decreased at 15th day and it completely disappeared at 30th day after the injury in both groups. Episcleral vasodilatation improved the day immediately after burning in all eyes. But other assessment days, it was more prominent in BAM group than the other.

Further, this vascularization has gradually decreased until the end of the experiment. The membrane did generally not create any problems in 1st week. Then, loose or broken sutures were encountered in each eye of the treatment group. In 3rd week of the study, the membranes have begun to dissolve and lost their integrity completely until the end of the experiment. Only in one BAM case, partial hyphema and hypopion were observed following the infection (Fig. 1).

**Histological evaluation:** Plasma cell numbers, distribution of inflammatory cells, corneal thicknesses and microscopic findings such as keratinization, edema, vascularization and inflammation were histologically assessed.

In the passive control group, the corneal epithelium of multilayer views was lost and some epithelial cells were swollen. The epithelium had only one layer that occurs vacuolated basal cells. The collagen fibers had lost their regular appearances in the stroma and the fibroblastic activity of the stroma was very low. The stroma was edematous with enlarged pericellular spaces. No plasma and inflammatory cells had infiltrated the anterior stroma, but there were many PMN and plasma cells in the area of the limbus. The corneas showed no keratinization and abnormal vessels were also not seen in the anterior stroma. The mean corneal thickness in this group was  $216.50 \pm 21.10 \mu\text{m}$  (Fig. 2a).

In the active control group, the epithelium layer had quite become indistinct with the irregularity of basal cells. The basal cells had lost their columnar appearances. The collagen fiber had lost their regular appearances in the stroma. The stromal edema (pericellular spaces) was more reduced than the passive group. A few inflammatory and

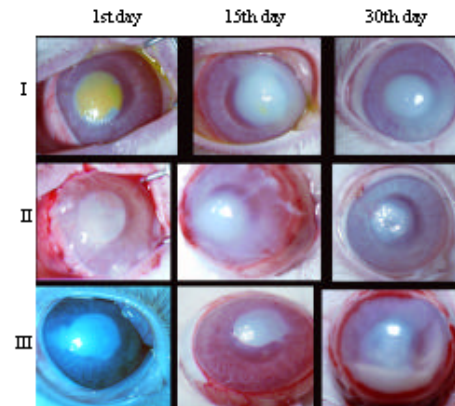


Fig. 1: A representation of the corneal damage for BAM and control groups of all the assessment days. I. Active control group: An eye with fluorescein staining immediately after burning, the corneal defect almost disappeared at 15th day and unchanged corneal opacity at 30th day evaluation are observed. II. Treatment group: Bovine amniotic membrane transplantation performed immediately after burning, the membrane initiated to dissolve at 15th day and corneal opacification slightly lost density both peripherally and centrally in some areas at 30th day examination are appeared. III. Complications: The eye without fluorescein staining immediately after burning, neovascularization and partial hyphema at 15th day and hypopion at 30th day examination are seen. It was appeared that reepithelial completion and reduction of corneal opacification were more favourable in BAM group than in the other

plasma cells ( $11.12 \pm 2.73 \text{ mm}^{-3}$ ) had infiltrated the anterior stroma. The corneas showed a bit keratinization. There were very few abnormal vessels in the anterior stroma. In some regions of the corneal epithelial layer were appeared detachments. There is markedly abnormal and distorted epithelium, often with a single layer of cells. The mean corneal thickness measured in the group was  $383.87 \pm 22.99 \mu\text{m}$  (Fig. 2b).

In the BAM group, histologic sections of the BAM transplanted corneas received showed differences compared to the other corneas. Despite the decrease of blood vessels in the stroma, a significant increase ( $p < 0.005$ ) in the number of plasma cell infiltration ( $36.62 \pm 7.38$ ) according to other groups was observed and also a decrease in inflammatory cells have been identified in this group. The number of inflammatory cells in suture areas was abundant (Fig. 2d). The recovery of the epithelium layer was highly close to normal. The BAM had completely responsible for reepithelialisation. Stromal

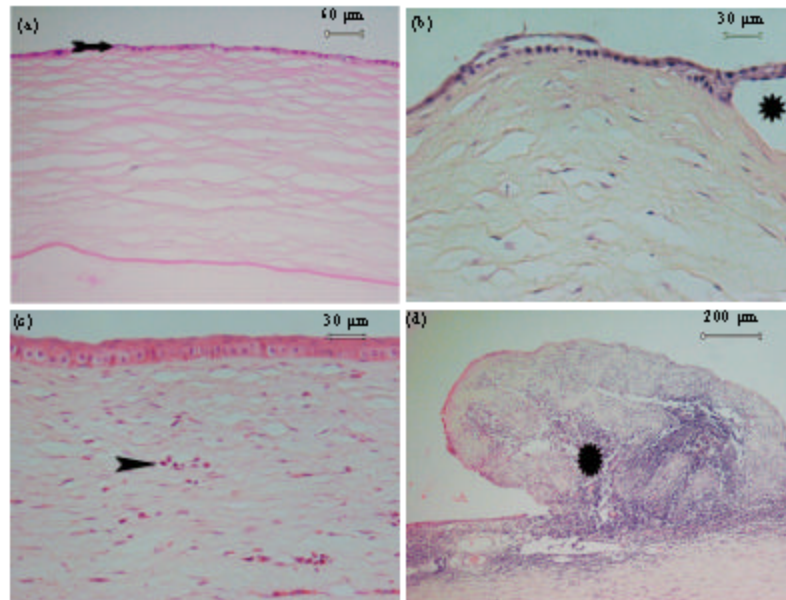


Fig. 2: a): The view of the corneal epithelium of the passive control group. The stroma contained irregularly arranged collagen fibers. Arrow: Vacuolated basal cells. b): An abnormal histologic appearance in the active control group. Note the irregularity of basal cells. Asterisks: The partial epithelial detachment. c): A view of BAM group. The recovery of the epithelium layer was close to normal corneal epithelium. Arrow head: Cluster of the plasma cells. d): A view of the suture area. Inflammatory cells have accumulated around the suture. Asterisk: Note few inflammatory cells. Histological sections of the cornea stained with H and E

Table 1: Measurements of mean corneal thicknesses and mean numbers of plasma cells in rabbit corneas of passive control, active control and treatment groups

Groups	Corneal thicknesses (µm) mean±SE	Plasma cell counts (per mm <sup>2</sup> ) mean±SE
Passive control	216.50±21.10	0.0±0.0
Active control	383.87±22.99*	11.12±2.73
Treatment (BAM)	340.00±22.67 <sup>#</sup>	36.62±7.38 <sup>##</sup> *

\*p<0.005 versus passive control, <sup>#</sup>p<0.05 versus passive control, <sup>##</sup>p<0.01 versus active control

fibroblast activity was returned to normal and keratinization in the epithelium layer had almost disappeared. The basal cells had returned to the normal structure and edema in the stroma was nearly correct. The mean corneal thickness was 340.00±22.67 µm (Fig. 2c) in treatment group.

**Corneal thicknesses:** Although, the increase was not significant in BAM group (340.00±22.67 µm), the mean corneal thickness in active control (383.87±22.99 µm) was significantly increased (p<0.005) compared to passive control group (216.50±21.10). Briefly, the treated group with BAM had beneficial effects on corneal thicknesses compared to passive control eyes (Table 1).

## DISCUSSION

The amniotic membrane used in an ophthalmic surgery facilitates proliferation, differentiation and

migration of newly formed epithelial cells, reinforces adhesion of the basal cells and promotes cell differentiation. Several supportive growth factors produced by the basement membrane also stimulate reepithelialisation. The membrane suppressed transforming growth factor-β signaling DNA synthesis and subsequent myofibroblast differentiation of normal corneal and limbal fibroblasts, together with the inhibition of new vessel invasion by the avascular stroma, prevent scar formation and reduces corneal haze especially, following keratectomy (Azura-Blanco *et al.*, 1999; Chen *et al.*, 2000; Prabhasawat *et al.*, 2001; Shenoy *et al.*, 2006). The stromal matrix of the membrane can also exclude inflammatory cells and contains various forms of protease inhibitors, actions important for preparing the stroma to support limbal stem cells to be transplanted at the same time or later (Barros *et al.*, 2005; Chen *et al.*, 2000; Prabhasawat *et al.*, 2001). This is why corneal neovascularization is mitigated and stromal inflammation is reduced.

The amniotic membrane has been successfully transplanted in a number of surgical procedures in ophthalmology, including burns, corneal ulceration, pterygium surgery, symblepharon lysis and conjunctival surface reconstruction for restoration of the ocular surface and also in glaucoma filtration surgery (Barton *et al.*, 2001; Hanada *et al.*, 2001;

Kobayashi *et al.*, 2003; Shimazaki *et al.*, 1998, 2002). Action mechanism and application of the membrane become more understood. But the full potential of transplantation techniques is not known, thereby requiring further prospective randomized studies including control and treatment groups to determine the effectiveness of AMT in acular surface disorders as repeated in previous reports (Hanada *et al.*, 2001). In addition, the success rate for human AMT has been reported as 66.7% for chemical burns (Shenoy *et al.*, 2006). That is why a burn model was preferred here as a right choice. Corneal alkali burns produced in this study were mild to moderate, episcleral vasodilatation, corneal opacification and epithelial defects were the major clinical findings and they did not induce consistent neovascularization and hyphema adding to episcleral vasodilatation. So, BAM treated corneas in the study have moderate haze and also iris details and the pupil were not enough visible, whereas, the control eyes have dense and large opacities in corneas and also obscured iris and pupil have not changed for one month period.

Although, amniotic membranes yield a good cosmesis and is relatively easy to perform (Prabhasawat *et al.*, 2001) and this biological tissue has been found to be an effective functional substrate (Shenoy *et al.*, 2006), the transplantation has not been without complications. Post-operative infections, corneal irritation, scarring, graft loss due to membrane shrinkage, membrane dislocation as a result of loose or broken sutures, early disintegration of the membrane, haemorrhage under the membrane or sutures, corneal calcification and problems related to processing have been the main postoperative complications (Anderson *et al.*, 2003; Szurman *et al.*, 2006). Herein, we observed an infection only in a case leading to partial hyphema and hypopyon later, dislocation of membrane in 3 cases because of broken sutures and haemorrhage on the sclera in 5 cases during application of the stitches.

The amniotic membrane, when used as a biological dressing, usually disintegrates within 2- 4 weeks after the operation (Azura-Blanco *et al.*, 1999; Kozak *et al.*, 2002). The results in this study were generally consistent with these reports. But, loose or broken sutures detached in a week as a result of constant rubbing of the eye were particularly tedious and required additional surgical intervention. Therefore, several alternative options, such as a purse string running suture placed around the limbus and anchored to both the upper and lower lid margins by running sutures to prevent the early detachment from the ocular surface (Kobayashi *et al.*, 2003), a cyanoacrylate tissue adhesive combined with an amniotic membrane to seal a corneal perforation (Prabhasawat *et al.*, 2001;

Su and Lin, 2000) and progressive corneal ulcerations restrictively (Golubovic and Parunovic, 1990) and a new sutureless technique for amniotic membrane fixation onto the corneal surface by using fibrin glue maintaining stable adherence until epithelialisation is completed, increasing biocompatibility, yielding better epithelialization pattern and minimizing the membrane shrinkage (Szurman *et al.*, 2006), are suggested in the study. Nevertheless, the toxicity of cyanoacrylate glue must be kept in mind for the corneal endothelium and lens when it comes into direct contact with these structures (Golubovic and Parunovic, 1990).

However, cryopreservation decreases the production and potency of growth factors and limits the ability of the graft to exhibit its properties (Shenoy *et al.*, 2006) and requires an expensive and bulky -80°C deep freezer. Also, proper sterilization of the membrane is vital because of various pathogenic organisms and it should be easily to obtain, transport and store for long periods without deterioration. It should be sterile and free of contamination as reported (Nakamura *et al.*, 2004) for clinical use to prevent these problems which are barriers to the wider use of it.

In the early period of corneal wound healing after alkali burns, fibroblasts migrate actively to the wounded zone after amniotic membrane patching, whereas, only weak migration of fibroblasts is observed during the same period to wounds without patching (Kim *et al.*, 2000). In this study, we found that although the fibroblast activity of the stroma was weak in the first day, this activity had increased in later days. So, findings of Kim *et al.* (2000) show similarities with our findings. Following the corneal alkali burn, PMNs enter the wound from limbal capillaries by migration through the stroma and release proteolytic enzymes into the wound tissue (Kim *et al.*, 2000). After initial healing, alkali wounded corneal epithelium shows two characteristic findings as frequent blister formation and recurrent epithelial defects (Chung, 1988). Also, the stromal repair involves the resolution of chemically broken down collagen (Chung and Fagerholm, 1989). In our study, AMT prevented local inflammatory responses, reduced initial inflammatory damages to the stroma and repaired the destruction of epithelium in the BAM group very faster than the other.

It appears from the histological findings that, the immigration of PMN cells, corneal thicknesses, edema, neovascularization and inflammation are reduced by BAM after alkali burns compared to other controls and these results were in good accordance with previous reports (Kim and Tseng, 1995; Nakamura *et al.*, 2004). On the other words, it is shown us that the increase in the number of plasma cells has become chronic inflammation.

Nevertheless, limitation of the studies about alkaline concentration, dislocation problems, preservation and biological activity of the BAM; degrees of the corneal damage and additional surgical procedures, such as, suturless and combination techniques to the transplantation also require further studies.

### CONCLUSION

The BAM was highly found to be effective to restore the corneal surface with acute alkali burns in the rabbit. But, it was needed after this study that AMT would have been performed using suturless techniques to prevent some complications, especially, membrane dislocation due to loose or broken sutures and needle trauma leading to haemorrhage on the sclera.

### REFERENCES

- Anderson, S.B., R.F. De Souza, C. Hofmann-Rummelt and B. Seitz, 2003. Corneal calcification after amniotic membrane transplantation. *Br. J. Ophthalmol.*, 87: 587-591. DOI: 10.1136/bjo.87.5.587. PMID: 12714401. <http://bjo.bmj.com/cgi/content/full/87/5/587>.
- Azuara-Blanco, A., C.T. Pillai and H.S. Dua, 1999. Amniotic membrane transplantation for ocular surface reconstruction. *Br. J. Ophthalmol.*, 83 (4): 399-402. DOI: 10.1136/bjo.83.4.399. PMID: 10434859. <http://bjo.bmj.com/cgi/content/full/83/4/399>.
- Barros, P.S.M., A.M.V. Safatle, C.A. Godoy, M.S.B. Souza, L.F.M. Barros and D.E. Brooks, 2005. Amniotic membrane transplantation for the reconstruction of the ocular surface in three cases. *Vet. Ophthalmol.*, 8(3): 189-192. DOI: 10.1111/j.1463-5224.2005.00391.x. PMID: 15910372. [http://www.ingentaconnect.com/search/article;jsessionid=1wcjcllvroad.alice?title=symblepharon&title\\_type=tka&year\\_from=1998&year\\_to=2009&database=1&pageSize=20&index=5](http://www.ingentaconnect.com/search/article;jsessionid=1wcjcllvroad.alice?title=symblepharon&title_type=tka&year_from=1998&year_to=2009&database=1&pageSize=20&index=5).
- Barton, K., D.L. Budenz, P.T. Khaw and S.C.G. Tseng, 2001. Glaucoma filtration surgery using amniotic membrane transplantation. *Invest. Ophthalmol. Vis. Sci.*, 42(8): 1762-1768. PMID: 11431440. <http://www.iovs.org/cgi/content/full/42/8/1762>.
- Chen, H.J., R.T.F. Pires and S.C.G. Tseng, 2000. Amniotic membrane transplantation for severe neurotrophic corneal ulcers. *Br. J. Ophthalmol.*, 84 (8): 826-833. DOI: 10.1136/bjo.84.8.826. PMID: 10906085. <http://bjo.bmj.com/cgi/content/full/84/8/826>.
- Chung, J.H., 1988. Experimental corneal alkali wound healing. *Acta Ophthalmol. Suppl.*, 187: 1-35. PMID: 2848391. <http://www.ncbi.nlm.nih.gov/pubmed/2848391>.
- Chung, J.H. and P. Fagerholm, 1989. Treatment of rabbit corneal alkali wounds with human epidermal growth factor. *Cornea*, 8 (2): 122-128. PMID: 2469551. [http://www.ncbi.nlm.nih.gov/pubmed/2469551?ordinalpos=&itool=EntrezSystem2.PEntrez.Pubmed.Pubmed\\_ResultsPanel.SmartSearch&log\\$=citation\\$=sensor](http://www.ncbi.nlm.nih.gov/pubmed/2469551?ordinalpos=&itool=EntrezSystem2.PEntrez.Pubmed.Pubmed_ResultsPanel.SmartSearch&log$=citation$=sensor).
- Golubovic, S. and A. Parunovi, 1990. Cyanoacrylate glue in the treatment of corneal ulcerations. *Fortschr. Ophthalmol.*, 87 (4): 378-381. PMID: 2210567. [http://www.ncbi.nlm.nih.gov/pubmed/2210567?ordinalpos=&itool=EntrezSystem2.PEntrez.Pubmed.Pubmed\\_ResultsPanel.SmartSearch&log\\$=citation\\$=sensor](http://www.ncbi.nlm.nih.gov/pubmed/2210567?ordinalpos=&itool=EntrezSystem2.PEntrez.Pubmed.Pubmed_ResultsPanel.SmartSearch&log$=citation$=sensor).
- Gonenci, R., M.E. Altug, A. Koc and A. Yalcin, 2009. Effects of bovine amniotic fluid on acute corneal alkali burns in the rat. *J. Anim. Vet. Adv.*, 8 (4): 617-623. <http://www.medwelljournals.com/fulltext/java/2009/617-623.pdf>.
- Hanada, K., J. Shimazaki, S. Shimmura and K. Tsubota, 2001. Multilayered amniotic membrane transplantation for severe ulceration of the cornea and sclera. *Am. J. Ophthalmol.*, 131 (3): 324-331. PMID: 11239864. <http://www.ncbi.nlm.nih.gov/sites/entrez>.
- Herretes, S., O. Suwan-Apichon, A. Pirouzmanesh, J.M.G. Reyes, A.T. Broman, M. Cano, P.L. Gehlbach, E.D. Gurewitsch, E.J. Duh and A. Behrens, 2006. Use of topical human amniotic fluid in the treatment of acute ocular alkali injuries in mice. *Am. J. Ophthalmol.*, 142(2): 271-278. DOI: 10.1016/j.ajo.2006.03.025. PMID: 1687650. [http://www.sciencedirect.com/science?\\_ob=ArticleURL&\\_udi=B6VK5-4KJM WX1-F&\\_user=1560078&\\_rdoc=1&\\_fmt=&\\_orig=search&\\_sort=d&view=c&\\_acct=C000053703&\\_version=1&\\_urlVersion=0&\\_userid=1560078&md5=8fd540d6117d37bbb31cf98655eb433a](http://www.sciencedirect.com/science?_ob=ArticleURL&_udi=B6VK5-4KJM WX1-F&_user=1560078&_rdoc=1&_fmt=&_orig=search&_sort=d&view=c&_acct=C000053703&_version=1&_urlVersion=0&_userid=1560078&md5=8fd540d6117d37bbb31cf98655eb433a).
- Kim, J.C. and S.C.G. Tseng, 1995. The effects on inhibition of corneal neovascularization after human amniotic membrane transplantation in severely damaged rabbit corneas. *Korean J. Ophthalmol.*, 9 (1): 32-46. PMID: 7674551. <http://pdf.medrang.co.kr/paper/pdf/Kjo/Kjo009-01-06.pdf>.
- Kim, J.S., J.C. Kim, B.K. Na, J.M. Jeong and C.Y. Song, 2000. Amniotic membrane patching promotes healing and inhibits proteinase activity on wound healing following acute corneal alkali burns. *Exp. Eye Res.*, 70 (3): 329-337. DOI: 10.1006/exer.1999.0794/ PMID: 10712819. [http://www.sciencedirect.com/science?\\_ob=ArticleURL&\\_udi=B6WFD-45F4J93-43&\\_user=1560078&\\_rdoc=1&\\_fmt=&\\_orig=search&\\_sort=d&view=c&\\_acct=C000053703&\\_version=1&\\_urlVersion=0&\\_userid=1560078&md5=79d9569371fff730a77bf83a4b9c08e4](http://www.sciencedirect.com/science?_ob=ArticleURL&_udi=B6WFD-45F4J93-43&_user=1560078&_rdoc=1&_fmt=&_orig=search&_sort=d&view=c&_acct=C000053703&_version=1&_urlVersion=0&_userid=1560078&md5=79d9569371fff730a77bf83a4b9c08e4).

- Kobayashi, A., Y. Shirao, T. Yoshita, K. Yagami, Y. Segawa, K. Kawasaki, M. Shozu and S.C.G. Tseng, 2003. Temporary amniotic membrane patching for acute chemical burns. *Eye*, 17 (2): 149-158. DOI: 10.1038/sj.eye.6700316. PMID: 12640400. <http://www.nature.com/eye/journal/v17/n2/pdf/6700316a.pdf>.
- Kozak, I., A. Trbolova, Z. Sevcikova, T. Juhas and V. Ledecsky, 2002. Superficial keratectomy, limbal autotransplantation and amniotic membrane transplantation in the treatment of severe chemical burns of the eye. *Acta Vet. Brno*, 71: 85-91. [http://vfu-www.vfu.cz/acta-vet/vol71/pdf/71\\_085.pdf](http://vfu-www.vfu.cz/acta-vet/vol71/pdf/71_085.pdf).
- Nakamura, T., M. Yoshitani, H. Rigby, N.J. Fullwood, W. Ito, T. Inatomi, C. Sotozono, T. Nakamura, Y. Shimizu and S. Kinoshita, 2004. Sterilized, freeze-dried amniotic membrane: A useful substrate for ocular surface reconstruction. *Invest. Ophthalmol. Vis. Sci.*, 45: 93-99. DOI: 10.1167/iovs.03-0752. PMID: 14691159. <http://www.iovs.org/cgi/content/full/45/1/93>.
- Prabhasawat, P., N. Tesavibul and W. Komolsuradej, 2001. Single and multilayer amniotic membrane transplantation for persistent corneal epithelial defect with and without stromal thinning and perforation. *Br. J. Ophthalmol.*, 85 (12): 1455-1463. DOI: 10.1136/bjo.85.12.1455. PMID: 11734521. <http://bjo.bmj.com/cgi/reprint/85/12/1455>.
- Shenoy, R., A. Bialsiewicz, A. Al-Muniri and A. Thakral, 2006. Preserved human amniotic membrane transplantation in patients with trachoma: A retrospective analysis. *Asian J. Ophthalmol.*, 8: 191-194. <http://www.seagig.org/toc/v8n5/v8n5p191.pdf>.
- Shimazaki, J., N. Shinozaki and K. Tsubota, 1998. Transplantation of amniotic membrane and limbal autograft for patients with recurrent pterygium associated with symblepharon. *Br. J. Ophthalmol.*, 82 (3): 235-240. DOI: 10.1136/bjo.82.3.235. PMID: 9602618. <http://www.pubmedcentral.nih.gov/picrender.fcgi?artid=1722509&blobtype=pdf>.
- Shimazaki, J., M. Aiba, E. Goto, N. Kato and S. Shimmura, 2002. Transplantation of human limbal epithelium cultivated on amniotic membrane for the treatment of severe ocular surface disorders. *Ophthalmol.*, 109 (7): 1285-1290. DOI: 10.1016/S0161-6420(02)010898. PMID: 12093651. [http://www.ncbi.nlm.nih.gov/pubmed/12093651?ordinalpos=&itool=EntrezSystem2.PEntrez.Pubmed.Pubmed\\_ResultsPanel.SmartSearch&log\\$citationsensor](http://www.ncbi.nlm.nih.gov/pubmed/12093651?ordinalpos=&itool=EntrezSystem2.PEntrez.Pubmed.Pubmed_ResultsPanel.SmartSearch&log$citationsensor).
- Su, C.Y. and C.P. Lin, 2000. Combined use of an amniotic membrane and tissue adhesive in treating corneal perforation: A case report. *Ophthalmic Surg. Lasers*, 31 (2): 151-154. PMID: 10743929. <http://www.ncbi.nlm.nih.gov/pubmed/10743929>.
- Szurman, P., M. Warga, S. Grisanti, S. Roters, J.M. Rohrbach, S. Aisenbrey, R.T. Kaczmarek and K.U. Bartz-Schmidt, 2006. Sutureless amniotic membrane fixation using fibrin glue for ocular surface reconstruction in a rabbit model. *Cornea*, 25 (4): 460-466. PMID: 16670486. <http://www.ncbi.nlm.nih.gov/pubmed/16670486>.