

## Effects of Diclofenac Sodium on the Rat Liver in Postnatal Period

<sup>1</sup>Cennet Ragbetli, <sup>2</sup>Atif Aydinlioglu, <sup>3</sup>Mikail Kara, <sup>3</sup>Murat Cetin Ragbetli and <sup>4</sup>Fatma Ilhan

<sup>1</sup>Children Science Association, <sup>2</sup>Department of Anatomy,

<sup>3</sup>Department of Histology-Embriology,

Faculty of Medicine, University of Yuzuncu Yil, Van 65100, Turkey

<sup>4</sup>Department of Pathology, Faculty of Veterinary,

University of Yuzuncu Yil, Van 65100, Turkey

---

**Abstract:** Diclofenac Sodium (DS) is a nonsteroidal anti-inflammatory drug used in painful conditions, trauma, dysmenorrhoea, rheumatoid arthritis, degenerative joint disease and ankylosing spondylitis. There is the paucity of the research investigating DS effect on the rat liver in the fetal period. The present study aimed to investigate the possible postnatal effects of DS on the liver tissues of the offspring of rats. DS was administered to pregnant rats for 15 days from the 5th-20th day of pregnancy. After mating day, pregnant female rats were separated into the control and DS treated groups. DS (1 mg kg<sup>-1</sup> daily) was injected intraperitoneally to the drug-treated group and physiological saline (1 mL kg<sup>-1</sup>) to the control group. Liver tissues were collected from pups at the 20th week and paraffin sections were dyed with hematoxylen-eosin. DS caused proliferation of bile ducts, enlargement of periportal area, dilatation of sinusoids and the central vein, parenchymal degeneration and mononuclear cell infiltration. Significant changes between the control and the treated groups were found ( $p < 0.05$ ). However, no significant difference was observed between the sexes in both groups. This study using DS with low dose did not show parenchymal cell death, as a different finding from the previous studies. However, these observations need to be confirmed by further studies using different doses of DS during pregnancy.

**Key words:** Diclofenac sodium, pregnancy, rat, liver, fetus

---

### INTRODUCTION

Nonsteroidal Anti-Inflammatory Drugs (NSAIDs) have been widely used for many years in palliation of pain and decreasing inflammation and fever throughout the world (Simon, 1994). Diclofenac (sodium-[o-[2,6-dichlorophenyl]-amino]phenyl]-acetate) (DS) is an NSAID and the treatment choice for alleviation of fever and inflammation in rheumatoid arthritis, degenerative joint disease and ankylosing spondylitis. Nonsteroidal anti-inflammatory drugs are also used in painful conditions, trauma, dysmenorrhoea, dental medicine and in the treatment of pain resulting from minor surgery (Brogden *et al.*, 1980; Machiko *et al.*, 2001; Power *et al.*, 2007).

DS inhibits Cyclo-Oxygenase (COX) and hence, the Prostaglandin (PG) production (Vane, 1971), which has the potential to cause negative maternal and fetal effects during pregnancy. Maternal effects include prolongation of pregnancy and labour. DS also causes the ductus

arteriosus constriction, renal dysfunction and hemostatic abnormalities in the fetus and neonates. DS passes through the placental barrier and shows its effect on fetus (Ostensen, 1998). NSAIDs also affect central nervous development and compromise the neural activity, such as the impairment of sciatic nerve morphology (Canan *et al.*, 2008). Diclofenac is mainly metabolized in the liver (Castel *et al.*, 1997) and causes liver damage of the mammals and avian species (Reddy *et al.*, 2006). DS is also used widely in the women of child-bearing age for the treatment of common gynecological problems. On the other hand, the toxicity of diclofenac has been confirmed on rat embryos (Chan *et al.*, 2001). There is the paucity of the work investigating DS effect on the rat liver in the fetal period. In the pups of the rats treated with DS during pregnancy, 4 weeks after birth, significant morphological changes were observed in the liver (Gokcimen *et al.*, 2001). The aim of the present study was to examine the postnatal hepatic effects of DS administered during pregnancy.

**MATERIALS AND METHODS**

This study was approved by the Animal Use Ethics Commission from Yuzuncu Yil University and all procedures were performed according to the Animal Experimentation Ethics Committee.

**Animals and experimental procedures:** In the present study, male and female Wistar rats (150-200 g) were used. Animals were grouped into the control and diclofenac sodium group. Each group was separately left to mating in the same day. After observing the vaginal plug produced by male vesicular and coagulating gland secretions in the next day, the animals were accepted as pregnant rats (Ragbetli *et al.*, 2007). Pregnant animals were kept in a standard plastic cage on sawdust bedding in an air-conditioned room (20°C), under a 12/12 h light/dark cycle and fed *ad libitum*.

After mating day, pregnant rats from the control group (n = 20) received physiologic saline (1 mL kg<sup>-1</sup>) and the rats of the treatment group (n = 20) were injected with DS (1 mg kg<sup>-1</sup>) for 15 days from the 5-20th day of pregnancy. From each group, 12 (6 male, 6 female) offspring were chosen randomly after delivery and housed for 20 weeks. On the 21st day after the birth, under anesthesia, intracardiac perfusion was performed with 0.9% saline and 10% formaline from a total of 24 offspring. Tissue samples were processed by graded alcohol and xylene and then, embedded in paraffin blocks. Tissue sections (4 µm) were taken and stained with hematoxylen and eosin for histological examination. The preparations were examined with a light microscope (Zeiss axioskop 40). Observations concerning bile duct proliferation, mononuclear cell infiltration, enlargement in the periportal area, sinusoidal dilatation, vena centralis dilatation and paranchym degeneration were evaluated by the researchers of this study and a pathology expert. The evaluation of the changes mentioned above was made according to the method described by Gokcimen *et al.* (2001). Briefly (-) normal appearance (+) mild = 0-25% degeneration (++) moderate = 25-50% degeneration (+++) severe = 50-75% degeneration (++++ very severe = >75% degeneration (Table 1).

**Table 1: Hepatic changes found in the control and the treated groups (DS)**

Parameters	Control	DS	p-value
Bile duct proliferation	-	++	<0.001
Enlargement of periportal area	-	++	<0.001
Sinusoidal dilatation	+	+++	<0.001
Vena centralis dilatation	+	+++	<0.001
Parenchymal degeneration	-	+	<0.050
Mononuclear cell infiltration	-	++	<0.001
Fibrosis	-	-	>0.050

Histopathologic assessments of the experimental parameters were graded as follows: (-) showing no changes (+) (++) and (+++) indicating mild, moderate and severe changes, respectively; The number of specified parameters was counted under the light microscope (n = number of observations)

**Statistical analysis:** The data from the present study was compared for two groups and sexes by a statistician. Mann-Whitney U-test for comparison was used, converting the finding to numeric counterpart.

**RESULTS**

There was full agreement on yes/no choice among the observers. Significant changes between the control and the treated groups were found in terms of pathological changes in present study (p<0.05) (Fig. 1-3). However, no significant changes were observed between

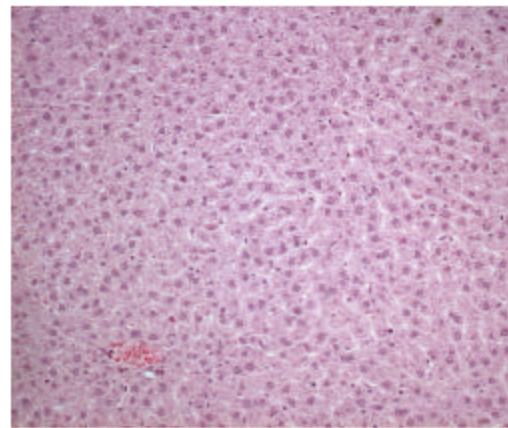


Fig. 1: Histologic structure of the liver of a rat from the control group (HE x20)

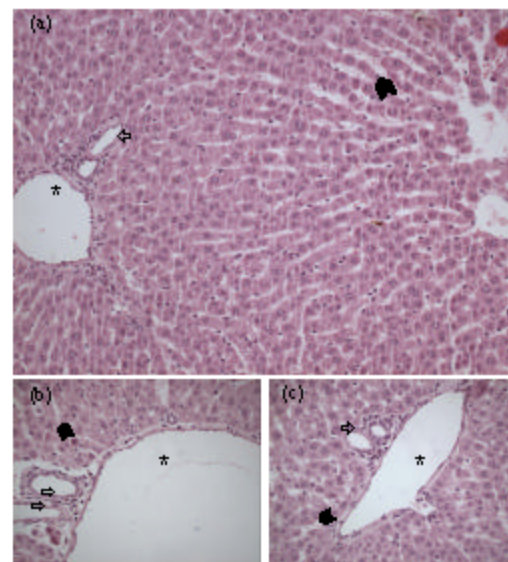


Fig. 2: a-c) Bile duct proliferation of portal area (→), dilatation of vena centralis (\*) and sinusoidal dilatation (◼) in the liver of a rat from the DS group (HE x40)

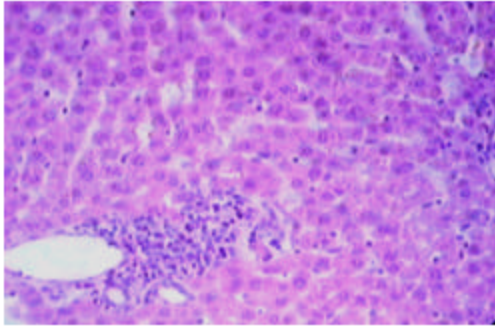


Fig. 3: Mononuclear cell infiltration of portal area of the liver of a rat from the DS group (HE  $\times 40$ )

the sexes in both groups. The male and female rats were equally affected by DS in the treated group. With the little change, the same appearance was observed between the sexes in the controls. Briefly, no significant difference were observed between the sexes in both the control and DS-treated group for bile duct proliferation, mononuclear cell infiltration, enlargement in the periportal area, sinusoidal dilatation, vena centralis dilatation and paranchym degeneration.

Mild to moderate enlargement in the portal area and mononuclear cell infiltration ( $p < 0.001$ ), mild to severe changes in bile duct proliferation ( $p < 0.001$ ), moderate to severe changes in sinusoidal dilatation and vena centralis dilatation, ( $p < 0.001$ ) and mild changes in paranchym degeneration were observed in both male and female rats treated with DS compared to the controls. Mild changes in sinusoidal dilatation, vena centralis dilatation and paranchym degeneration from the control group were seen in both sexes (Table 1).

## DISCUSSION

Diclofenac sodium as a Nonsteroidal Anti-Inflammatory Drug (NSAIDs) is one of the safest agents of its kind for the treatment of a broad range of rheumatic conditions (Willkens, 1985). On the other hand, NSAIDs are contraindicated during pregnancy because of their teratogenic potential. Nonsteroidal anti-inflammatory drugs given during pregnancy prolong the pregnancy and labour, inhibiting cyclooxygenase (Ostensen, 1998). All Non-Steroidal Anti-Inflammatory Drugs (NSAIDs) are prostaglandin inhibitors, which explain their foetal toxicity (Bavoux, 1992). These drugs are either avoided or given in a low dose in the first trimester of pregnancy.

The present study showed significant morphologic changes in the liver of the 20 weeks old offspring of the DS-administrated rats. In rats, diclofenac decreases hepatic ATP content and induces hepatocyte apoptosis

(Bort *et al.*, 1999). The adverse gastrointestinal effects and hepatic toxicity were also observed in pregnant rat administrated orally with non-selective COX inhibitors (Buradan *et al.*, 2004). Gokcimen *et al.* (2001) reported histopathologic changes including enlargement in the periportal area, pyknosis in the nucleus of hepatocytes and vacuolar degeneration in parenchymal cells of the 4 weeks old pups of DS-treated rats. Although, these findings are generally similar to those of this study, pyknosis was not observed in the present study in postnatal 20th week. The occurrence of the pyknosis in the liver of 4-weeks-old offspring was attributed directly to the influence of DS metabolites (Gokcimen *et al.*, 2001). We are unable to give commentary for the absence of the pyknosis in DS-treated group. However, if the pyknosis has taken place, a possible improvement of the parenchymal cell might occur in the postnatal period between 4 and 20th week.

These findings clearly demonstrate that a 15-days maternal administration of DS during pregnancy has significant negative effects on the developing liver compared to control, such as mild to moderate regressive structural changes. This study also showed that gestation period was significantly prolonged in DS-treated rats, similar to Kokcu *et al.* (1992) and Gokcimen *et al.* (2001). With light microscopy, no significant alterations were observed in this control group, 20-weeks-old rats. Because of the parenchymal degeneration, however, some of the hepatocytes have the appearance of clearing, swelling and fuzzy in the present study (Fig. 2 and 3).

DS appears to have some negative effect on both development and differentiation of liver cells. After partial resection or massive injury, unlike other organs, the mammalian liver can rapidly regenerate and regain its original size, structure and function (Chung *et al.*, 2006).

The toxic effect of diclofenac on hepatocytes may be caused by drug-induced mitochondrial impairment, together with a futile consumption of NADPH (Bort *et al.*, 1999). Recent studies using rat liver mitochondria and freshly isolated rat hepatocytes showed that diclofenac decreased hepatic ATP content and induced hepatocyte apoptosis (Chung *et al.*, 2006).

## CONCLUSION

We found that DS treatment during pregnancy caused mild to moderate bile duct proliferation and mononuclear cell infiltration and enlargement in the periportal area in 20 weeks-old female and male rats. This study did not find pyknosis, which is a different finding from that of previous studies and suggests that DS does not cause a parenchymal cell death in low doses.

However, these observations should be confirmed by further studies using different doses of DS during pregnancy.

#### ACKNOWLEDGEMENTS

The authors thank Aydin HIM for valuable comment and correct use of language as well as Siddik KESKIN for statistical analysis.

#### REFERENCES

- Bavoux, F., 1992. Fetal toxicity of non steroidal anti inflammatory agents. *Presse Med.*, 21 (40): 1909-1912. PMID: 1293602.
- Bort, R., X. Ponsoda, R. Jover, M.J. Gomez-Lechon and J.V. Castell, 1999. Diclofenac Toxicity to Hepatocytes: A role for drug metabolism in cell toxicity. *J. Pharmacol. Exp. Therapeutics*, 288 (1): 65-72. DOI: 0022-3565/99/2881-0065\$03.00/0.
- Brogden, R.N., R.C. Heel, G.E. Pakes, T.M. Speight and G.S. Avery, 1980. Diclofenac sodium: A review of its pharmacological properties and therapeutic use in rheumatic diseases and pain of varying origin. *Drugs*, 20 (1): 24-48. PMID: 6772422.
- Buradan, F., J. Zumilo, R. Klepacz, J. Dudka, A. Korobowicz, E. Tokarska, M. Cendrowska-Pinkosz, B. Madej and L. Klepacz, 2004. Gastrointestinal and hepatic toxicity of selective and non-selective cyclooxygenase-2 inhibitors in pregnant and non-pregnant rats. *Pharmacol. Res.*, 50 (5): 533-543. DOI: 10.1016/j.phrs.2004.04.008.
- Canan, S., A. Aktas, M.B. Ulkay, S. Colakoglu, M.C. Ragbetli, M. Ayyildiz, S. Geuna and S. Kaplan, 2008. Prenatally expose to a non-steroidal anti-inflammatory drug or saline solution impairs sciatic nerve morphology: A stereological and histological study. *Int. J. Develop. Neurosci.*, 26 (7): 733-738. PMID: 18678241.
- Chan, L.Y., P.Y. Chiu, S.S.N. Siu and T.K. Lau, 2001. A study of diclofenac-induced teratogenicity during organogenesis using a whole rat embryo culture model. *Human Reprod.*, 16 (11): 2390-2393. DOI: 10.1016/S0890-6238(02)00047-3.
- Castel, J.V., M.J. Gomez-Lechon, X. Ponsoda and R. Bort, 1997. The use of cultured hepatocytes to investigate the mechanism of drug hepatotoxicity. *Cell. Biol. Toxicol.*, 13: 331-338. PMID: 9298253.
- Chung, H., H.J. Kim, K.S. Jang, M. Kim, J. Yang, J.H. Kim, Y.S. Lee and G. Kong, 2006. Comprehensive analysis of differential gene expression profiles on diclofenac-induced acute mouse liver injury and recovery. *Toxicol. Lett.*, 166: 77-87. DOI: 10.1016/j.toxlet.2006.05.016.
- Gokcimen, A., G. Aydin, E. Karaoz, M.A. Malas and M. Oncu, 2001. Effect of diclofenac sodium administration during pregnancy in the postnatal period. *Fetal Diagnosis Ther.*, 16: 417-422. DOI: 10.1159/000053951.
- Kokcu, A., C. Ustun, S. Çoksenim and O. Balat, 1992. Gebe Ratlara Uygulanan Diklofenak Sodyum'un Fetüs Sayisi ve Gebelik Süresine Etkisi. *Türkiye Klinikleri J. Gynecol. Obst.*, 2: 295-297. [http://jinekoloji.turkiyeklinikleri.com/abstract-tr\\_32480.html](http://jinekoloji.turkiyeklinikleri.com/abstract-tr_32480.html).
- Machiko, N., Y. Shoji and A. Hitoshi, 2001. Effect of diclofenac sodium on osteoclast formation. *Oral Therapeutics Pharmacol.*, 20 (3): 196-198. DOI: 02A-0477211.
- Ostensen, M., 1998. Nonsteroidal anti-inflammatory drugs during pregnancy. *Scand. J. Rheumatol. Suppl.*, 107: 128-132. PMID: 9759151.
- Power, I., W.A. Chambers, A. Greer, D. Ramage and E. Simon, 2007. Platelet function after intramuscular diclofenac. *Anaesthesia*, 45 (11): 916-919. DOI: 10.1111/j.13652044.1990.tb14618.
- Ragbetli, M.C., B. Ozyurt, H. Aslan, E. Odaci, A. Gokcimen, B. Sahin and S. Kaplan, 2007. Effect of prenatal exposure to diclofenac sodium on Purkinje cell numbers in rat cerebellum: A stereological study. *Brain Res.*, 1174: 130-135. DOI: 35400016200553.0140.
- Reddy, P.N.C., Y. Anjaneyula, B. Sivasankari and A.K. Rao, 2006. Comparative toxicity studies in birds using nimesulide and diclofenac sodium. *Environ. Toxicol. Pharmacol.*, 22: 142-147. DOI: 10.1016/j.etap.2006.10.001.
- Simon, L.S., 1994. Actions and toxic effects of the nonsteroidal anti-inflammatory drugs. *Curr. Opin. Rheumatol.*, 6: 238-251. PMID: 8060759.
- Willkens, R.F., 1985. Worldwide clinical safety experience with diclofenac. *Semin. Arthritis Rheum.*, 15 (2): 105-110. PMID: 3909410.
- Vane, J.R., 1971. Inhibition of prostaglandin synthesis as a mechanism of action for aspirin-like drugs. *Nat. New Biol.*, 231: 232-235. PMID: 5284360.