

Acute Myotoxic Effects of by Infusion of Prilocaine and Lidocaine in Rats

¹M.C. Ragbetli, ²M. Yalama, ¹E. Erdogan, ¹N. Cengiz, ²I. Kati and ³C. Ragbetli

¹Department of Histology-Embryology, ²Department of Anesthesiology,
Faculty of Medicine, Yuzuncu Yil University, Van, 65200 Turkey

³Department of Pharmacology/Toxicology, Van, 65100, Turkey

Abstract: We assumed to examine the acute myotoxic effects of infusion of the local anesthetic lidocaine and prilocaine on the gluteus maximus muscle after continuous peripheral nerve blockade in rats. Eight adult female Sprague-Dawley average weighing 150-200 g rats were used in this study. Firstly, all of the animals were anesthetized with ketamine (50 mg kg⁻¹) for 6 h. Then, prilocaine (right) and lidocaine (left) were used in equal volume (5 mg mL⁻¹) for continuous peripheral nerve blockades of the posterior extremity at a rate of 0.3 mL h⁻¹ for a total period of 6 h in 5 animals. The remaining 3 animals as control group were treated with physiological saline on both sides at 0.3 mL h⁻¹ for a total period of 6 h. For routine histological observation, the infusion area was dissected and tissue samples including peripheral muscle were taken. For routine histological observation, the infusion area was dissected and tissue samples including peripheral muscle were taken. Method histological hazards as myotoxicity were not observed in skeletal muscle tissue after the infusion of prilocaine and lidocaine. There were no complications cases of local anesthesia. Prilocaine and lidocaine as local anesthetics might be applied safely by infusion.

Key words: Prilocaine, lidocaine, myotoxic effect, rat, infusion

INTRODUCTION

Clinically, local anesthetics are used in relatively large, axonal-blocking concentrations for local irrigation after many types of operations (Pietruck *et al.*, 2003). Skeletal muscle toxicity is a side effect of local anesthetic drugs and intramuscular injections of these agents regularly result in reversible myonecrosis. The extent of muscle damage is dose dependent and worsens with serial or continuous administration. All local anesthetic agents that have been examined are myotoxic; procaine produces the least and bupivacaine the most severe muscle injury. Skeletal muscle damage must be considered a potentially serious complication of local and regional anesthesia, as recent studies have revealed that certain techniques are related to a relatively frequent postoperative incidence of significant muscular dysfunction directly caused by these drugs. The subcellular pathomechanisms of local anesthetic myotoxicity are not completely understood; however, excessively increased intracellular Ca²⁺ levels have been shown to play a key role in myocyte injury. Local anesthetics induce Ca²⁺ release from the Sarcoplasmic Reticulum (SR) and simultaneously inhibit Ca²⁺ reuptake into the SR, resulting in persistently increased Ca²⁺ levels (Zink *et al.*, 2005). The histologic pattern and the time course of skeletal muscle injury

appear rather uniform: hyper contracted myofibril become evident directly after injection, followed by lytic degeneration of striated muscle SR and then by myocyte edema and necrosis (Zink and Graf, 2004).

During recent years, catheter techniques for the continuous application of long-acting local anesthetics have been well established in regional anesthesia. In the previous studies, there is a paucity of enough information related to the myotoxic effect of the infusion of the local anesthetics (prilocaine and lidocaine). Therefore, we investigated the acute myotoxic effects of lidocaine and Prilocaine on skeletal muscle tissue using an infusion technique of continuous peripheral neural blockade.

MATERIALS AND METHODS

This study was approved by the Animal Use Ethics Commission from Yuzuncu Yil University and all procedures were performed according to the Animal Experimentation Ethics Committee.

Animals: Eight female rats (150-200 g) were kept in a standard plastic cage on sawdust bedding in an air-conditioned room (22°C), under a 12/12 h light/dark cycle and fed *ad libitum*.

Experimental procedures: The animals were anesthetized by Ketamine Hydrochloride (50 mg kg^{-1}) intraperitoneally without muscle relaxation and placed in prone position. The rats were separated as a control ($n = 3$) and experiment ($n = 5$) groups. Under the general anesthesia, with a skin incision parallel to long axis, gluteus maximus muscle and then sciatic nerve were exposed (Fig. 1).

Plexus catheters (20 gauges) were inserted into the sciatic nerve sheaths and fixed bilaterally into two extremities along the sciatic nerve trace. After this procedure, skin and subcutaneous tissue were closed by single stitches. The catheters were fixed bilateral into two extremities from along the sciatic nerve trace by single stitches and their exact positions were documented.

After placing the catheters, with the help of an infusion pump (Fig. 2) (Braun, R-fin perfusor, Germany), 5 animals were administered lidocaine (5 mg mL^{-1}) in left side and prilocaine (5 mg mL^{-1}) in right side, with a rate of 0.3 mL h^{-1} for a total period of 6 h. In control group ($n = 3$), the animals were treated with normal saline by same rate and doses on both sides. After 1 h from this procedure, the sciatic nerve with $0.5 \times 1 \text{ cm}$ volume was cut out with surrounding tissues by removing the stitches and withdrawing the catheters and then, under the ether inhalation, the animals were sacrificed.

For histological process, the specimens from each infusion site were subsequently fixed by immersion in 10% phosphate-buffered formalin (pH 7.5) for 12 h, embedded in paraffin, cut into $5 \mu\text{m}$ and stained with Hematoxylin and Eosin (H and E). Additionally, representative sections were exposed to an apoptosis-specific staining kit (indirect TUNEL labeling assay: In Situ Cell Death Detection Kit APTM; Roche Diagnostics, Germany) according to the manufacturer's guidelines. Painted sections for TUNEL 488 nm, for DAPI uv Fluorescence emission filter in the microscope (Zeiss Axiocvert 200 M) was used. Preparations as digital images (Zeiss Axiocam HRC) has been received and recorded.

The sections were evaluated by two independent examiners. To assess the specific extent of skeletal muscle changes, 8 cross-sections per infusion site in both treated group and 16 in control group were randomly chosen. The specimens were scored as follows Benoit *et al.* (1980):

- No fiber damage
- Localized and/or sparsely scattered fiber destruction or damage limited in depth to 1 or 2 fibers
- More extensive necrosis following major connective tissue planes and involving numerous muscle fascicles or destruction extending 3-5 fibers from the surface
- Destruction of essentially the entire muscle mass or generalized damage/necrosis of >5 fibers' depth

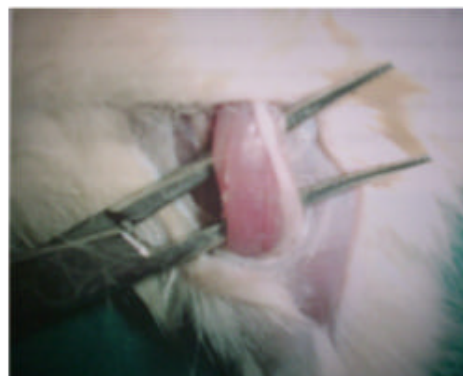

Fig. 1: Gluteus maximus muscle and sciatic nerve



Fig. 2: Infusion pump (Braun R-fin, Germany)

Statistical analysis: Quantitative differences in muscle tissue changes between lidocaine (right) and Prilocaine (left) treatment groups were assessed by using nonparametric Wilcoxon signed-rank test and $p < 0.05$ were considered significant. Differences in muscle tissue changes between Lidocaine-plecabo and Prilocaine-plecabo groups were assessed by using Mann-Whitney U-test and $p < 0.05$ were considered to be significant.

RESULTS AND DISCUSSION

In the study, the interstitial and connective tissue edema was observed on histological sections from the region applied isotonic infusion in both treated and control groups (Fig. 3-5). The myonecrosis, the fibril degeneration, apoptosis and the edema observed in both lidocaine and prilocaine group were found to be insignificant ($p > 0.05$) (Fig. 6-8).

Local anesthetics are neurotoxic and myotoxic at large concentrations during continuous administration (Pietruck *et al.*, 2003). After applied, local anesthetics cause some histological damages (edema and necrosis) on skeletal muscle tissue. In the earlier studies, procaine,

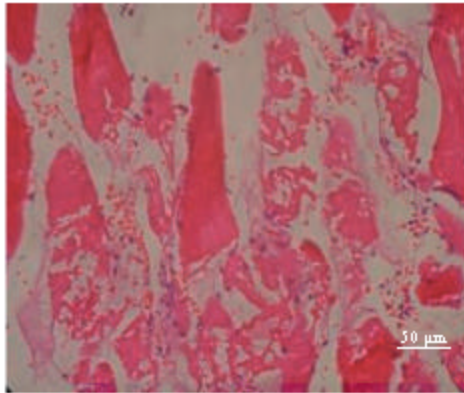


Fig. 3: Skeletal muscle degeneration zone by Prilocaine, $\times 400$ (H and E)

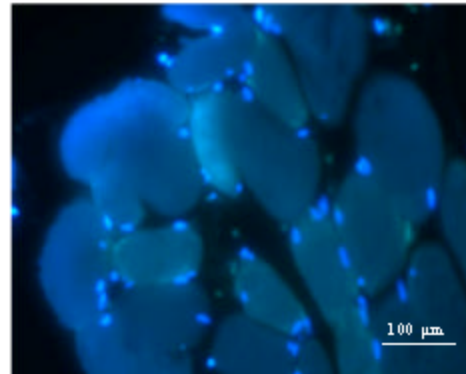


Fig. 6: Muscle sections of control group ($\times 200$), apoptotic nucleuses stained with green

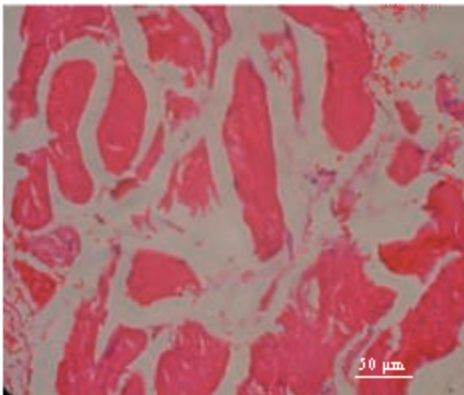


Fig. 4: Muscle sections of Lidocaine group (H and E $\times 400$)

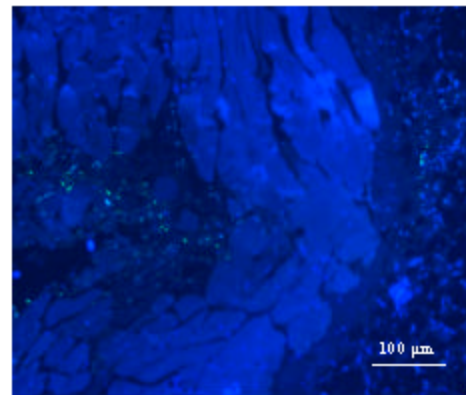


Fig. 7: Muscle sections of Lidocaine group ($\times 200$), apoptotic nucleuses stained with green




Fig. 5: Morphological degeneration in control group (H and E)

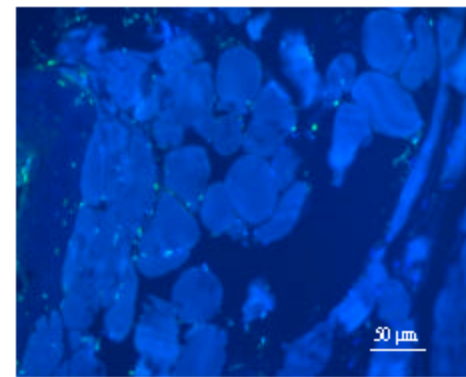


Fig. 8: Muscle sections of Prilocaine group ($\times 400$), apoptotic nucleuses stained with green

tetracaine, lidocaine and bupivacaine produced effects that were confined principally to the muscle fiber (Foster and Carlson, 1980). Intra-Muscular (IM) injections of local anesthetics regularly result in striated muscle

damage and reversible myonecrosis. Muscle damage extents with dose dependent and continuous administration. Histologically, hyper contracted myofibril become evident several minutes after injection, followed

by lytic degeneration of striated muscle sarcoplasmic reticulum, myocyte edema and myonecrosis (Zink *et al.*, 2005).

In this study, the comparison between the infusion of lidocaine and/or Prilocaine and the placebo shown no significant difference in histological structure ($p>0.05$), which means that the complication does not occur. Apoptosis in the myofibril by lidocaine was found much more than by Prilocaine ($p>0.05$) (Fig. 6-8).

Hunter *et al.* (1995) reported, three cases of the inferior oblique muscle contracture caused by local anesthetic myotoxicity, which resulted from anesthetic toxicity directly to the nerve innervating the muscle.

There may be differences in myotoxic potential between agents. For example; statin-associated myotoxic effects include the impairment of cell membrane structure and function, mitochondrial dysfunction and impaired myocyte duplication (Evans and Rees, 2002).

Using by the tunnel technique, no evidence of apoptotic ultrastructures in the myocyte was found. DNA fragmentation occurs in the myocyte that had already shown irreversibly oncotic, but not apoptotic, ultrastructures with ischemia and/or reperfusion (Duchen, 2000; Ohno *et al.*, 1998).

Breuninger *et al.* (2000) reported that anesthetic solutions injected via Subcutaneous Infusion Anesthesia (SIA) may be safely use as without complication in case of vulnerable patients and children.

CONCLUSION

We found no significant myotoxicity in the present study. According to our findings, it suggests that the infusion of highly diluted local anesthetics is appropriate in use.

ACKNOWLEDGEMENT

The researchers would like to thank Dr. Irfan Bayram for her opinion on the pathological subject.

REFERENCES

- Benoit, P.W., A. Yagiela and N.F. Fort, 1980. Pharmacologic correlation between local anesthetic-induced myotoxicity and disturbances of intracellular calcium distribution. *Toxicol. Applied Pharmacol.*, 52: 187-198. DOI: 10.1016/0014-4886(72)90173-2.
- Breuninger, H., F. Schimek and P. Heeg, 2000. Subcutaneous infusion anesthesia with diluted mixtures of Prilocaine and ropivacaine. *Langenbecks Arch. Surg.*, 385 (4): 284-289. DOI: 10.1007/s00423000138.
- Duchen, M.R., 2000. Mitochondria and calcium: From cell signaling to cell death. *J. Physiol.*, 529: 57-68. DOI: 10.1111/j.1469-7793.2000.00057.x
- Evans, M. and A. Rees, 2002. The myotoxicity of statins. *Curr. Opin. Lipidol.*, 13 (4): 415-420. DOI: 10.1007/s11883-003-0079-x.
- Foster, A.H. and B.M. Carlson, 1980. Myotoxicity of local anesthetics and regeneration of the damaged muscle fibers. *Anesth. Analg.*, 59: 727-736. PMID: 7191645.
- Hunter, D.G., G.C. Lam and D.L. Guyton, 1995. Inferior oblique muscle injury from local anesthesia for cataract surgery. *Ophthalmology*, 103 (4): 545-546. DOI: 10.1016/S0161-6420(95)30994-3.
- Ohno, M., G. Takemura, A. Ohno, J. Misao, Y. Hayakawa, S. Minatoguchi, T. Fujiwara and H. Fujiwara, 1998. Apoptotic myocyte in infarct area in rabbit hearts may be oncotic myocyte with DNA fragmentation: Analysis by immunogold electron microscopy combined with *in vitro* nick end-labelling. *Circulation*, 98:1422-1430. DOI: 10.1161/01.RES.0000067471.95890.
- Pietruck, C., S. Grond, G.X. Xie and P.P. Palmer, 2003. Local anesthetics differentially inhibit sympathetic neuron-mediated and C fiber-mediated synovial neurogenic plasma extravasation. *Anesth. Analg.*, 96: 1397-1402. PMID: 12707141.
- Zink, W. and B.M. Graf, 2004. Local Anesthetic Myotoxicity. *Reg. Anesth. Pain Med.*, 1: 333-340. DOI: 10.1016/j.rapm.2004.02.008.
- Zink, W., J.R.E. Bohl, N. Hacke, B. Siner, E. Martin and B.M. Graf, 2005. The long term myotoxic effects of bupivacaine and ropivacaine after continuous peripheral nerve blocks. *Anesth. Analg.*, 101: 548-554. DOI: 10.1213/01.ANE.0000155956.59842.0A.