

Protective Effect of Vitamin E and Melatonin Against Radiation Induced Damage in Testes of Rats

¹F.R. Yalcinkaya, ¹A. Gokce, ¹E.O. Guven, ¹M. Davarci, ²G. Cikim, ³H. Yekeler and ¹M.D. Balbay

¹Department of Urology, Faculty of Medicine, Mustafa Kemal University, Turkey

²Kahramanmaraş Gynecology and Obstetric Hospital, Turkey

³Department of Pathology, Faculty of Medicine, Fırat University, Turkey

Abstract: To investigate the effects of vitamin E and melatonin on gamma ray induced damage in testes of rats. A total of 40 Wistar type rats were divided into 4 groups, each including 10 rats. Total body radiation was applied to the first 3 groups with 90 cm, 90% isodose curve using Cobalt 60 apparatus. The period of exposure time was 11 min 30 sec and a total of 360 cGy gamma radiation was administered in each session. Following radiation exposure, intraperitoneal injection of vitamin E (100 mg/kg/day), melatonin (100 mg/kg/day), 0.9% saline (100 mg/kg/day) were done in group 1-3, respectively. Group 4 was the control group and intraperitoneal 0.9% saline (100 ml/kg/day) was administered without any radiation. Five days after the procedure testes were removed and analyzed to measure Malondialdehyde (MDA) levels and degree of histopathological injury. Tissue MDA level measured in rats receiving melatonin did not show significant difference when compared to control group ($p>0.05$). Similarly, there was no significant tissue injury on histopathological examination between melatonin administered and control groups. However, compared to the control group both tissue MDA level and tissue injury were found to be significantly increased in groups, which received vitamin E and 0.9% saline solution ($p<0.05$). Melatonin displays a remarkable tissue protective effect by inhibiting the damage mediated by free radicals after radiation. The same effect could not be obtained with Vitamin E. Thus, the cytoprotective effect of melatonin can be of value in preserving testicular functions after radiation exposure.

Key words: Vitamin E, melatonin, radiation, testicular damage, oxidation, malondialdehyde

INTRODUCTION

Testes are among the most sensitive tissues to radiation and may undergo marked functional impairment with exposure to radiation. Tissue injury associated with radiation can result either due to direct exposure to radiation of the testes or, more frequently, from low doses of radiation that affect testes during radiation of other organs (Howell and Shalet, 2005). There is continuing effort to develop cytoprotective agents in order to prevent radiation side effects in other organs of the cancer patients who have longer survival chance.

Both biological and lethal radiation primarily target cellular DNA with associated lipid and protein damage (Daly *et al.*, 1999; Reiter *et al.*, 2000). Since, water represents 70% of the chemical composition of the adult body and 90% of the infant body, its chemical transformation by ionizing radiation merits serious damage. Damage is mainly formed by reactive equated electrons, monatomic hydrogen atoms, hydroxide radical, hydrogen peroxide and protonated water as well as

superoxide (O_2^-) and hydroperoxide radical in the presence of oxygen. Hydroperoxide radical, hydroxyl radical, monatomic hydrogen and equated electrons have very short half-lives of the order of milliseconds and consequently, react rapidly with cellular components in reduction, oxidation, initiation, insertion, propagation with further reactions causing loss of function and the need for biochemical replacement and/or repair. Ionizing radiation can also, impair bringing enough energy to all biochemicals thereby causing hemolytic bond breaking within tissue (Sorenson *et al.*, 2001). In order to limit these effects of reactive oxygen species and the damage they cause, antioxidant defense systems of the metabolism are activated (Cheeseman and Slater, 1993). In case of excessive free radical production and/or low antioxidant defenses, oxidative stress cause chemical, structural and functional alterations in biomolecules (Taysi *et al.*, 2003).

Melatonin and Vitamin E (Vit. E) are the most potent antioxidants known and recognized as free radical scavengers (Reiter *et al.*, 2000). It was reported in previous studies that Vit. E, through its antioxidant effect,

inhibited oxidative reaction initiated by oxygen radicals and acts as a cell protector (McCay and King, 1980). Similarly, melatonin was reported to protect the DNA against free radical damage induced by ionizing radiation (Reiter *et al.*, 1996). The mechanism, by which melatonin detoxifies highly reactive oxidants is explained by its donation of an electron to these electrophilic compounds. Therefore, the indolylation formed by the transfer of one electron in the presence of the O_2^{\bullet} becomes the metabolite kynuramine. The protective effects against lipid peroxidation by melatonin has been evaluated extensively utilizing xenobiotic substances such as paraquat and diquat, substances that in presence of p450 NADPH-cytochrome reductase induces the generation of O_2^{\bullet} (9).

In the present study, we aimed to investigate the effects of vitamin E and melatonin on gamma ray induced damage in testes of rats.

MATERIALS AND METHODS

Animals: This study was conducted on 40 male Wistar type rats, weighing between 200 and 250 g, aged between 10 and 12 weeks, acquired from Experimental Research Center of Selcuk University Medical School. The rats were kept in the Experimental Animals Laboratory of Selcuk University Medical School in separate cages located in a room temperature of $22\pm 2^\circ C$ and exposure to 12 h light and 12 h dark. The feed and water to rats were given *ad-libitum*. The study strictly observed the principles of experimental animal studies ethical rules of the Helsinki Declaration.

Radiation procedure: Total body radiation was applied with 90 cm, 90% isodose curve using Cobalt 60 apparatus (Picker ATC C9). Thirty-two cGy/min gamma radiations was applied to an area of 40×40 cm of where, 5 rats were placed. The period of exposure time was 11 min 30 sec and a total of 360 cGy gamma radiation was administered in each session.

Study groups: Forty rats were randomly divided into 4 group each containing 10 rats and first 3 groups received gamma radiation.

Group 1: Rats were administered Intraperitoneal (IP) Vit. E (100 mg/kg/day) with 12 h intervals for 5 days after radiation.

Group 2: Rats in this group received IP Melatonin (100 mg/kg/day) with 12 h intervals for 5 days after radiation.

Group 3: The group, which was administered IP saline (100 mL/kg/day) with 12 h intervals for 5 days after radiation (Sham group).

Group 4: The group, which was administered only IP SP (100 mL/kg/day) with 12 h intervals for 5 days without receiving radiation (Control group).

Tissue examination: The experimental animals were anesthetized with 2 mL kg^{-1} ketamine hydrochloride for the orchiectomy procedure. After the rats were placed into dorso-lithotomy position and appropriate antiseptics applied, bilateral orchiectomy was performed. The tissue was excised, weighted, divided into small pieces and then homogenized in 50 mM Tris-HCl, pH 7.4, containing 150 mM KCl and 250 mM sucrose by using motor driven Teflon with Elvenjem-Potter Homogenizer (Du Pont Instruments, Sorwall Homogenizer, USA) at a ratio of 1g wet weight of tissue/3 mL of buffer. The homogenate centrifuged at $10,000\times g$ for 20 min at $4^\circ C$. The pellet was discarded and the supernatant was used for further biochemical assays. MDA analysis at a later stage and rest of the tissue was kept in 10% formalin for histopathologic evaluation. Following tissue removal, all rats were sacrificed by cervical dislocation.

MDA analysis: Lipid peroxidation was measured by the method of Ohkawa *et al.* (1979). Briefly, the reaction mixture contained Tris HCl buffer (50 mM, pH7.4), BHP (500 mM in ethanol) and 1mM $FeSO_4$. After incubating the tissue sample with reaction mixture at $37^\circ C$ for 90 min, the reaction was stopped by adding 2 mL of 8% sodium dodesil sulphate followed by 1.5 mL of 20% acetic acid (pH 3.5). The amount of malondialdehyde formed during incubation was estimated by adding 1.5 mL of 0.8% Thiobarbutiric Acid (TBA) and heating the mixture at $95^\circ C$ for 45 min. After cooling, samples were centrifuged and the TBA Reactive Substances (TBARS) were measured in supernants by spectrophotometer (Shimadzu UV-1201V) at 532 nm using the extinction coefficient value of $1.53\times 10^5 M/cm$. Lipid peroxidation was expressed in terms of nanomoles of TBARS/mgprotein/90 min.

Histopathologic evaluation: The testes were surgically removed and fixed in Bouin's fluid. The tissue was embedded in a paraffin block after dehydrating with increasing concentrations of 70, 90 and 100% ethanol. Five micrometer (μm) sections were cut using hand microtome, placed on glass slide and stained with Harris Haematoxylin and eosin. Stained tissue sections were

observed under light microscope (Olympus) to determine histopathological changes. Testicular injury and spermatogenesis were graded as described by Johnsen (1970). A score of 1 indicated no seminiferous epithelial cells and tubular sclerosis. A score of 2 indicated no germ cells, only Sertoli cells. A score of 3 indicated spermatogonia only. A score of 4 indicated no spermatids, few spermatocytes and arrest of spermatogenesis at the primary spermatocyte stage. A score of 5 indicated no spermatids and many spermatocytes. A score of 6 indicated no late spermatids, few early spermatids and arrest of spermatogenesis at the spermatid stage and disturbance of spermatid differentiation. A score of 7 indicated no late spermatids and many early spermatids. A score of 8 indicated few late spermatids. A score of 9 indicated many late spermatids and disorganized tubular epithelium. A score of 10 indicated full spermatogenesis (Yurtcu *et al.*, 2008).

Statistical analysis: Mann-Whitney U test was used in the comparison of histopathologic tissue damage points and MDA levels between groups and $p < 0.05$ was accepted significant. Spearman correlation analysis was used in the analysis of the correlation between histopathologic tissue damage and MDA levels in each group.

RESULTS

All rats survived until the end of study. The level of MDA in all groups and extent of histopathologic injury in all rats were presented in Table 1. There was a positive correlation between histopathologic score and MDA levels in all groups (Table 1). Both histopathologic scores and MDA levels were found to be most significantly increased in group 3, which was administered saline after radiation. In contrast, the lowest level of MDA was encountered in group 2, which was administered melatonin when compared to the control group (Table 1) ($p < 0.05$).

When, the groups were compared in terms of histopathologic scores, no significant difference was found between the group, which was administered saline

after radiation (Fig 1) and the Vit. E-administered group (Fig 2), whereas the scores were lower in the melatonin-administered group than in the groups, which were administered saline and Vit. E following radiation ($p < 0.05$) (Table 1). No significant difference was observed between melatonin-administered group (Fig 3) and the control group (Fig. 4) ($p > 0.05$) (Table 1). Both histopathologic scores and MDA levels in Vit. E and saline administered groups were higher than those in group 4 (control group) indicating the damage induced by ionizing radiation ($p < 0.05$) (Table 1).

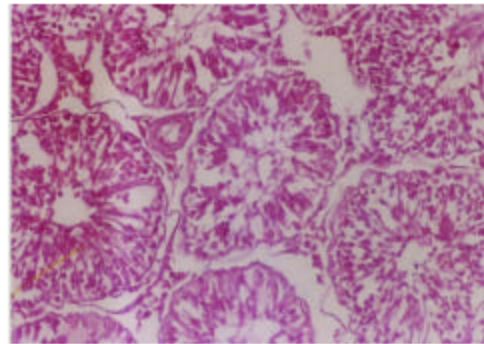


Fig. 1: Rat testes radiation + Serum Physiologic (SP) (HE ×100)

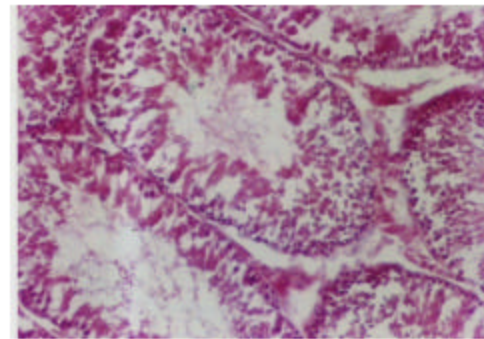


Fig. 2: Rat testes radiation + Vit. E (HE ×100)

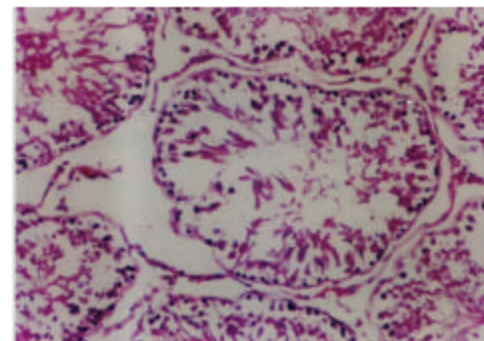


Fig. 3: Rat testes radiation + melatonin (HE ×100)

Table-1: Tissue MDA levels and histopathologic scores in groups

Groups	Mean±SD		
	MDA (nmol)	Histopathologic scores	Correlation (r)
G ₁ (Radiation +Vit. E)	4.9±0.1 ^a	5.1±0.5 ^a	0.623
G ₂ (Radiation + Melatonin)	3.5±0.6 ^b	6.1±0.7 ^c	0.782
G ₃ (Radiation + SP)	5.9±0.3 ^c	4.2±0.7 ^d	0.584
G ₄ (Only SP)	3.4±0.3 ^b	7.7±0.5 ^e	0.771

^aDifferent superscripted letters in the same column indicate statistical significance between groups. ** : MDA: Malondialdehyde, Vit. E: Vitamin E, SP: Serum Physiologic, G: Group

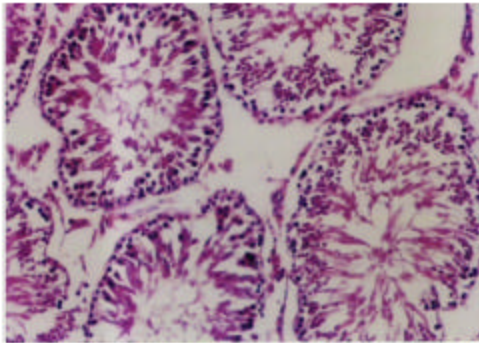


Fig. 4: Normal rat testes tissue (HE stained $\times 100$)

DISCUSSION

Exposure to radiation in a dose-dependent manner increases tissue-specific MDA levels in all organs and the magnitude of oxidative stress imposed by irradiation is usually measured by the degree of lipid peroxidation. Lipid peroxidation within the membrane has a devastating effect on the functional state of the membrane because it alters membrane fluidity, typically decreasing it and thereby allowing ions such as Ca ion to leak into the cell (Manda *et al.*, 2007). Malondialdehyde, which is the end product of lipid peroxidation is highly toxic to cells. Similarly, the peroxide radical formed due to lipid peroxidation attacks membrane proteins and enzymes thereby increasing damage to cell (Manda *et al.*, 2007).

Melatonin is a strong antioxidant and has free radical scavenging property. Its small molecular structure and high lipophilic characteristic allow melatonin to pass easily through biological membranes and reach all compartments of the cell. There is strong evidence suggesting that melatonin has protective effects on DNA, proteins and lipids in cases of endogenous and exogenous free radical formation (Reiter *et al.*, 1995). In a review study on melatonin, it was stated that melatonin is relatively non-toxic and protects against ionizing radiation injury (Reiter, 1999). Melatonin, the acetylated methoxyether of Serotonin, 5-hydroxytryptamine and produced 75% survival in LD00/30 9.5 Gy whole-body irradiated male Swiss ND4 mice.

The protective effect of melatonin was found to be more than that was obtained by serotonin since, serotonin could only increase 20% increase in survival (Blickenstaff *et al.*, 1994). Intraperitoneal treatment of these mice with soybean oil solutions or suspensions of 1.1 mmol kg⁻¹ acetyl (Melatonin), propionyl, butanoyl, pentanoyl, hexanoyl, octanoyl, decanoyl, or hexadecanoyl analogs of 5-methyltryptamine 30 min before irradiation

produced survivals of 0, 43 ($p = 0.0045$), 32, 75, 95, 65, or 48%, respectively. Radio-protective activities of different melatonin derivatives were significantly higher than vehicle treated mice.

The increase in radio protective activity was greatest for the hexanoyl and octanoyl derivatives, showing an increase in activity with increasing lipophilicity (Karbownik and Reiter, 2000). Melatonin and its acyl homologs were reported to be highly potent against radiation induced cellular damage in circumstances of human radiation injury (Sorenson *et al.*, 2001). Reiter *et al.* (2000) reported that melatonin could have a protective effect against the damage ionizing radiation caused in DNA (Reiter, 1999). In the present study, we found similar results consistent with the literature and histopathological and biochemical results revealed that melatonin reduced the damage caused by gamma radiation in the testicular tissue of rats.

Vitamin E (Vit. E), with its antioxidant effects, prevents the oxidative damage of cell membrane that was caused by oxygen free radicals (Cheeseman and Slater, 1993; Taysi *et al.*, 2003). Kodentsova *et al.* (1997) reported that plasma Vit. E-levels significantly increased in the testicular tissue of rats during 42 h following gamma radiation when compared to rats, which did not receive any radiation (Kodentsova *et al.*, 1997). In another study, antioxidant properties of melatonin and Vit. E in various tissues were examined. Pieri *et al.* (1994) stated that one molecule of melatonin neutralized four molecules of free radicals formed due to radiation, whereas one molecule of Vit. E could neutralize two radicals thus, indicating melatonin is a much more potent antioxidant than Vit. E (Pieri *et al.*, 1994).

In our study, we also compared the protective effects of these two molecules on testicular tissue in the presence of gamma radiation injury and found that melatonin administration caused significant decrease in the level of MDA and improved histopathologic scores. The same effects could not be shown for Vit. E. There was a slight reduction in MDA levels after vitamin E administration in rats after gamma radiation. Although, this reduction was statistically significant when compared to saline injection group, histopathological examination in rats receiving Vitamin E showed no significant improvement.

These insufficient protective effects of vitamin E at tissue level can be explained considering several factors: Siu *et al.* (1998) compared the antioxidant capacity of melatonin and vitamin E and determined that antioxidant capacity of both agents were dose-dependent (Siu *et al.*, 1998). Although, in our study, we did not measure the

dose-dependent effects of Vit. E, we believe that 100 mg kg⁻¹ dose of Vit. E was enough to observe the protective effects. Moreover, Vit. E dose we used induced significant decrease in MDA levels however, we did not find significant restoration on histopathologic scores, which suggests that melatonin is more potent than Vit. E in respect to protection against radiation injury.

CONCLUSION

Our findings revealed that use of vitamin E did not have tissue protective effects on radiation induced injury of rat testes whereas, testicular tissue of rats receiving melatonin was protected from the radiation induced injury. Melatonin administration reduced tissue MDA levels to the same level that was observed in rats receiving no radiation.

Similarly, histopathological examination showed no significant difference between rats receiving melatonin and rats that were not administered any radiation. This suggests that melatonin had significant protective effects against testicular damage induced by radiation. However, studies with large series, including controlled trials are necessary to validate its use in clinical cases.

REFERENCES

- Blickenstaff, R.T., S.M. Brandstadter, S. Reddy and R. Witt, 1994. Potential radioprotective agents. 1. Homologs of melatonin. *J. Pharm. Sci.*, 83(2): 216-218. DOI: 10.1002/jps.2600830220. PMID: 8169792.
- Cheeseman, K.H. and T.F. Slater, 1993. An introduction to free radical biochemistry. *Br. Med. Bull.*, 49(3): 481-493. PMID: 8221017.
- Daly, J.M., M. Bertagnoli, J.J. De Cosse and D.L. Morton, 1999. Oncology. 7th Edn. In: Schwartz, S.I. (Ed.). *Principles of Surgery*, pp: 335-345, McGraw-Hill. New York, USA. ISBN: 0070580855.
- Howell, S.J. and S.M. Shalet, 2005. Spermatogenesis after cancer treatment: Damage and recovery. *J. Natl. Cancer Inst. Monogr.*, 34: 12-17. DOI: 10.1093/jncimonographs/lgi003. PMID: 15784814.
- Johnsen, S.G., 1970. Testicular biopsy score count: A method for registration of spermatogenesis in human testes: Normal values and results in 335 hypogonadal males. *Hormones*, 1(1): 2-25. PMID: 5527187.
- Karbownik, M. and R.J. Reiter, 2000. Antioxidative effects of melatonin in protection against cellular damage caused by ionizing radiation. *Proc. Soc. Exp. Biol. Med.*, 225(1): 9-22. PMID: 10998194.
- Kodentsova, V.M., O.A. Vrzhesinskaia, I.V. Gmoshinskii, S.N. Radchenko, L.M. Iakushina and V.K. Mazo, 1997. Vitamin metabolism in rats in the early period after a single whole-body gamma irradiation. *Radiats Biol. Radioecol.*, 37(3): 360-365. PMID: 9244523.
- Manda, K., M. Ueno, T. Moritake and K. Anzai, 2007. Alpha-Lipoic acid attenuates x-irradiation induced oxidative stress in mice. *Cell Biol. Toxicol.*, 23(2): 129-137. DOI: 10.1007/s10565-006-0137-6. PMID: 17094020.
- McCay, P.B. and M.M. King, 1980. Vitamin E, Its role as a biological free radical scavenger and its relationship to the microsomal mixed function oxidase system. In: Machalin, L.J. (Ed.). *Vitamin E: A Comprehensive Treatise*. Marcel Dekker. New York, USA, pp: 289-317. ISBN: 0824768426.
- Ohkawa, H., N. Ohishi and K. Yagi, 1979. Assay for lipid peroxides in animal tissues by thiobarbituric acid reaction. *Anal Biochem.*, 95(2): 351-358. PMID: 36810.
- Ortiz, G.G., G.A. Benitez-King, S.A. Rosales-Corral, F.P. Pacheco-Moises and I.E. Velazquez-Brizuela, 2008. Cellular and Biochemical Actions of Melatonin, which Protect Against Free Radicals: Role in Neurodegenerative Disorders. *Curr Neuropharmacol.* 6(3): 203-214. DOI: 10.2174/157015908785777201. PMID: 19506721.
- Pieri, C., M. Marra, F. Moroni, R. Recchioni and F. Marcheselli, 1994. Melatonin: A peroxy radical scavenger more effective than vitamin E. *Life Sci.*, 55(15): PL271-276. DOI: 10.1016/0024-3205(94)00666-0. PMID: 7934611.
- Reiter, R.J., D. Melchiorri, E. Sewerynek, B. Poeggeler, L. Barlow-Walden, J. Chuang, G.G. Ortiz and D. Acuña-Castroviejo, 1995. A review of the evidence supporting melatonin's role as an antioxidant. *J. Pineal. Res.*, 18(1): 1-11. DOI: 10.1111/j.1600-079X.1995.tb00133.x. PMID: 7776173.
- Reiter, R.J., 1999. Oxidative damage to nuclear DNA: amelioration by melatonin. *NEL Review. Neuro Endocrinol Lett.*, 20(3-4): 145-150. http://www.nel.edu/20_34/nel20_34rev2reiter.htm. PMID: 11462105.
- Reiter, R.J., D.X. Tan, C. Osuna and E. Gitto, 2000. Actions of melatonin in the reduction of oxidative stress. A review. *J. Biomed. Sci.*, 7: 444-458. DOI: 10.1007/BF02253360. PMID: 11060493.
- Reiter, R.J., L.D. Chen, B. Poeggeler, L. Barlow-Walden, E. Swerynek and D. Melchiorri, 1996. Antioxidant Actions of Melatonin and Structurally Related Compounds. In: Cadenas, E. and L. Packer (Eds.). *Handbook of Antioxidants*. Marcel Dekker, New York, USA, pp: 513-526. ISBN: 0824705475.

- Siu, A.W., R.J. Reiter and C.H. To, 1998. The efficacy of vitamin E and melatonin as antioxidants against lipid peroxidation in rat retinal homogenates. *J. Pineal. Res.*, 24 (4): 239-244. DOI: 10.1111/j.1600-079X.1998.tb00539.x. PMID: 957 2534.
- Sorenson, J.R., L.S. Soderberg, L.W. Chang and R.B. Walker, 2001. Essential metalloelement chelates facilitate repair of radiation injury. *Met Based Drugs.*, 8: 215-234. DOI: 10.1155/MBD.2001.215. PMID: 18475999.
- Taysi, S., M. Koc, M.E. Buyukokuroglu, K. Altinkaynak and Y.N. Sahin, 2003. Melatonin reduces lipid peroxidation and nitric oxide during irradiation-induced oxidative injury in the rat liver. *J. Pineal Res.*, 34(3):173-177. DOI:10.1034/j.1600-079X.2003.00024.x. PMID: 12614476.
- Yurteu, M., A. Abasiyanik, M.C. Avunduk and S. Muhtaroglu, 2008. Effects of melatonin on spermatogenesis and testicular ischemia-reperfusion injury after unilateral testicular torsion-detorsion. *J. Pediatr. Surg.*, 43 (10): 1873-1878. DOI: 10.1016/j.jpedsurg.2008.01.065. PMID: 18926224.