

## Mushroom Poisoning by *Inocybe fastigiata* in a Maltese Dog

<sup>1</sup>Seungkeun Lee, <sup>2</sup>So-Jeong Nam, <sup>2</sup>Ran Choi and <sup>2</sup>Changbaig Hyun

<sup>1</sup>Korea Animal Hospital, Cheongju 361-829, South Korea

<sup>2</sup>Section of Small Animal Internal Medicine, School of Veterinary Medicine,  
Kangwon National University, Chuncheon 200-701, South Korea

**Abstract:** A 10-years-old male Maltese dog was presented with severe vomiting, diarrhea, bradycardia and respiratory difficulty, after the ingestion of a poisonous wild mushroom (*Inocybe fastigiata*). No remarkable abnormalities in complete blood cell counts and serum biochemistry were observed except hemoconcentration. The dog was treated with gastric lavage, anti-cholinergics (atropine) and fluid therapy (0.9% saline) for 48 h. The dog was released after 48 h of emergency treatment. This is the 1st case report related to poisoning from *Inocybe fastigiata* mushroom in a dog.

**Key words:** Mushroom poisoning, dog, atropine, *Inocybe fastigiata*

### INTRODUCTION

Poisoning from toxic mushrooms often occurs in dogs (Bernard, 1979; Cole, 1993; Kirwan, 1990; Liggett and Weiss, 1989). Clinical consequences from mushroom poisoning vary from mild gastrointestinal upsets to fatal death, depending on the type of mycotoxins ingested. *Inocybe fastigiata* (also known as *Inocybe rimosa*) is a kind of mycorrhiza (a symbiotic association between a fungus and the roots of a plant) and categorized broadly in complex genus of mushrooms (Malone and Brady, 1987). *Inocybe* sp. are not considered suitable for consumption, because many species contain large doses of muscarine, which causes profuse sweating (in humans), lacrimation, bradycardia and respiratory failure (Malone and Brady, 1987; McPartland *et al.*, 1997; Wilson, 1947). Some other *Inocybe* sp. are also hallucinogenic and contain psilocybin, which acts as a serotonin agonist (Malone and Brady, 1987).

To date, over 80 mushroom species in the world have been identified as containing significant toxins (Benjamin, 1995), although, the majority of mushroom poisonings are not fatal. Probably, the majority of fatal poisonings are attributable to the *Amanita phalloides* mushroom in humans and animals (Cole, 1993; Liggett and Weiss, 1989; Puschner *et al.*, 2007; Ridgway, 1978; Vetter, 1998). *Amanita phalloides* mushroom contains  $\alpha$ -amanitin (known as phallotoxins) and causes severe hepatic and renal (rarely) damage (Vetter, 1998). Other than *Amanita phalloides*, mushroom

poisoning from Psilocybin mushrooms (magic mushroom) and false morel (*Gyromitra esculenta*) have been also reported in dogs (Bernard, 1979; Kirwan, 1990). This case report described acute mushroom intoxication in dogs, because of accidental feeding of a muscarine containing mushroom (*Inocybe fastigiata*).

### MATERIALS AND METHODS

**Animals:** A 10-years-old male Maltese dog (2.5 kg of body weight) was presented at the Veterinary teaching hospital of Kangwon National University with primary complaints of severe vomiting, diarrhea and respiratory difficulty. According to the owner, the dog showed marked salivation followed by frequent vomiting, severe lacrimation in eyes, watery diarrhea, restlessness and weakness about 1 h after the ingestion of wild mushrooms (5-10 raw mushrooms) collected from a mountain near the owner's house.

**Physical examination and laboratory tests:** At physical examination, the dog showed moderate abdominal pain in palpation. The respiratory rate was rapid (80 breaths  $\text{min}^{-1}$ ) with periodic apnea. The femoral pulse was irregular in interval and intensity. The pupils were equal, neither constricted nor dilated, but there was a sluggish reaction to light. No remarkable abnormalities in complete blood cell counts and serum biochemistry were observed except hemoconcentration (51.4% of hematocrit; reference range 37-45%). Diagnostic imaging studies

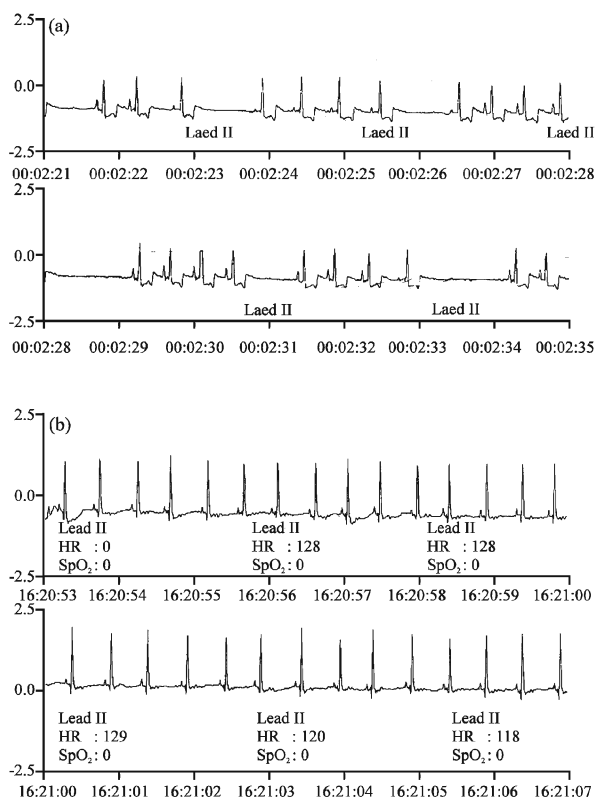


Fig. 1: The Electrocardiogram (ECG) recorded from this dog, a: Recorded at the presentation. The ECG showed Sinoatrial (SA) exit blocks and sinus arrest at the rate of 80-90 beats  $\text{min}^{-1}$ , b: Recorded 16 h after treatment. The ECG showed normal sinus beats at the rate of 120-130 beats  $\text{min}^{-1}$



Fig. 2: The poisonous mushroom (*Inocybe fastigiata*) causing clinical sings in this dog

found small urinary stones in the urinary bladder and mildly mineralized right kidney. The electrocardiogram revealed Sinoatrial (SA) exit blocks and sinus arrest with 80-90 beats of ventricular rate (Fig. 1a). Our university biologist identified the ingested mushrooms as *Inocybe fastigiata*, based on the photo taken by the owner (Fig. 2).

## RESULTS

**Treatment and follow-up:** The dog was immediately treated with administration of atropine sulphate ( $0.2 \text{ mg kg}^{-1}$ , SC) and gastric lavage until the fluid was returned clear. Fluid (0.9% saline) was administered at the rate of 5-10 mL/kg/h for the first 24 h. The dog was kept in an oxygen cage (at the flow rate of  $5 \text{ L min}^{-1}$ ). Two hours after the initial treatment, the pattern of respiration was returned to normal and the heart rhythm was returned to normal sinus beats at the rate of 120-130 beats  $\text{min}^{-1}$  (Fig. 1b). No further lacrimation and salivation were observed. The dog was released after 48 h of emergency treatment.

## DISCUSSION

Muscarine is a natural substance found in certain mushrooms (e.g., *Inocybe* sp., *Clitocybe* sp. and *Omphalotus* sp.) (Benjamin, 1995; Malone and Brady, 1987). Muscarine was 1st isolated from *Amanita muscaria* and acted biologically as parasympathomimetics (Benjamin, 1995). Although, the clinical signs from intoxication differ by the amount of mushroom ingested, it causes profound activation of the peripheral parasympathetic nervous system that may result in convulsions and death (Benjamin, 1995; Diaz, 2005). Muscarine mimics the action of the neurotransmitter acetylcholine at muscarinic acetylcholine receptors, although, it does not affect the central nervous system due to its inability to cross the blood-brain barrier.

Mushroom poisoning containing muscarine is characterized by increased salivation, sweating and lacrimation within 15-30 min after ingestion of the mushroom in humans (Diaz, 2005). If the amount of ingested mushrooms is substantial, these symptoms may be followed by abdominal pain, severe nausea, diarrhea, blurred vision and labored breathing. Most muscarinic mushroom intoxication subsides within a few hours, but it can be fatal if the patients have cardiac or respiratory failure (Benjamin, 1995; Diaz, 2005). Anti-cholinergic agents, such as atropine, are the effective antidote for most muscarinic mushroom intoxications (Diaz, 2005).

According to old human literature, muscarinic effects in *Inocybe* sp. differed by types of subspecies

(Wilson, 1947). Although, *Inocybe fastigiata* was categorized into a subspecies that had no muscarinic effect, later studies revealed *Inocybe fastigiata* contained very high amounts of muscarine (Wilson, 1947).

We initially, believed this dog showed acute food poisoning because of marked salivation accompanied acute gastrointestinal upset. However, the dog showed labored rapid breathing with bradyarrhythmias, despite no evidence of trauma, electrolyte abnormalities and acid-base imbalances. Therefore, we interrogated the owner what she fed before the initiation of clinical signs. She confessed that she fed several pieces of uncooked mushrooms to this dog. The dog started to vomit about 1 h after the ingestion of mushrooms. She initially believed the mushrooms fed were tufted coincap mushroom (*Collybia confluens*), which is edible and non-poisonous. In reality, the appearance of *Collybia confluens* and *Inocybe fastigiata* was similar and indistinguishable in the eye of a non-expert. Clinical signs from mushroom poisoning in this dog were consistent with muscarine poisoning in humans. Dramatic improvement of clinical signs after atropine administration led us to confirm muscarinic mushroom poisoning in this dog. Bradyarrhythmias (SA exit blocks and sinus arrest) in this dog might also be attributed from increased parasympathetic tone due to muscarine intoxication and was abolished by the administration of anti-cholinergic agents (e.g., atropine). Although, few case reports described poisonous mushroom intoxication in dogs (Bernard, 1979; Cole, 1993; Kirwan, 1990; Liggett and Weiss, 1989), this is the 1st case report that described acute poisoning from *Inocybe fastigiata* in dogs.

## REFERENCES

- Benjamin, D.R., 1995. Mushrooms: Poisons and Panaceas. W.H. Freeman and Company, New York, pp: 23-35. ISBN: 13-978-0716726494.
- Bernard, M.A., 1979. Mushroom poisoning in a dog. Can. Vet. J., 20: 82-83. PMID: 436103. <http://www.pubmedcentral.nih.gov/articlerender.fcgi?tool=pubmed&pubmedid=436103>.
- Cole, F.M., 1993. A puppy death and *Amanita phalloides*. Aust. Vet. J., 70: 271-272. DOI: 10.1111/j.1751-0813.1993.tb08052.x. PMID: 8368976. <http://www3.interscience.wiley.com/journal/120740461/abstract>.
- Diaz, J.H., 2005. Syndromic diagnosis and management of confirmed mushroom poisonings. Crit. Care Med., 33:427-36. DOI:10.1097/01.CCM.0000153531.69448.49. PMID: 15699849. <http://www.ccmjournal.com/pt/re/ccm/abstract.00003246-200502000-00021.htm;jsessionid=JzLTxGWxh41pT9Wz2QFHv6Qh95TGywtbW13vWbVMYzZzQQg287T7t!-32953442!181195629!8091!-1>.
- Kirwan, A.P., 1990. Magic mushroom' poisoning in a dog. Vet. Rec., 126: 149. PMID: 2316139. <http://veterinaryrecord.bvapublications.com/cgi/gca?allch=&SEARCHID=1&TITLE=%27Magic+mushroom%27+poisoning+in+a+dog&FIRSTINDEX=0&hits=10&RESULTFORMAT=1&gca=vetreco%3B126%2F6%2F149-b#126/6/149-b>.
- Liggett, A.D. and R. Weiss, 1989. Liver necrosis caused by mushroom poisoning in dogs. J. Vet. Diagn. Invest., 1: 267-269. PMID: 2488352. <http://www.jvdi.org/cgi/reprint/1/3/267>.
- Malone, M.H. and L.R. Brady, 1987. Relative muscarinic potency of 5 *Inocybe* sp. Proc. West. Pharmacol. Soc., 30: 193-195. PMID: 3628276. [http://www.unboundmedicine.com/medline/ebm/record/3628276/full\\_citation/Relative\\_muscarinic\\_potency\\_of\\_five\\_Inocybe\\_species](http://www.unboundmedicine.com/medline/ebm/record/3628276/full_citation/Relative_muscarinic_potency_of_five_Inocybe_species).
- McPartland, J.M., R.J. Vilgalys and M.A. Cubeta, 1997. Mushroom poisoning. Am. Fam. Physician, 55: 1797-1800, 1805-1809, 1811-1812. PMID: 9105206.
- Puschner, B., H.H. Rose and M.S. Filigenzi, 2007. Diagnosis of *Amanita toxicosis* in a dog with acute hepatic necrosis. J. Vet. Diagn. Invest., 19: 312-317. PMID: 17459866. <http://www.jvdi.org/cgi/content/full/19/3/312>.
- Ridgway, R.L., 1978. Mushroom (*Amanita pantherina*) poisoning. J. Am. Vet. Med. Assoc., 172: 681-682. PMID: 640930.
- Vetter, J., 1998. Toxins of *Amanita phalloides*. Toxicol., 36: 13-24. DOI: 10.1016/S0041-0101(97)00074-3. PMID: 9604278. [http://www.sciencedirect.com/science?\\_ob=ArticleURL&\\_udi=B6TCS-3SY99SJ-2&\\_user=945111&\\_rdoc=1&\\_fmt=&\\_orig=search&\\_sort=d&view=c&\\_acct=C000048950&\\_version=1&\\_urlVersion=0&\\_userid=945111&md5=54ba1f4d1bef3213e409241aa70f66634](http://www.sciencedirect.com/science?_ob=ArticleURL&_udi=B6TCS-3SY99SJ-2&_user=945111&_rdoc=1&_fmt=&_orig=search&_sort=d&view=c&_acct=C000048950&_version=1&_urlVersion=0&_userid=945111&md5=54ba1f4d1bef3213e409241aa70f66634).
- Wilson, D., 1947. Poisoning by *Inocybe fastigiata*. British Med. J., 2: 297. PMC: 2055394. <http://www.pubmedcentral.nih.gov/pagerender.fcgi?artid=2055394&pageindex=1>.