

## Clinical and Microbiological Evaluations of Efficacy of Combination of Natural Honey and Yarrow on Repair Process of Experimental Burn Wound

<sup>1</sup>Hossien Tajik, <sup>2</sup>Farnood Shokouhi Sabet Jalali, <sup>2</sup>Sharam Javadi,

<sup>1</sup>Yasser Shahbazi and <sup>2</sup>Masoumeh Amini

<sup>1</sup>Department of Food Hygiene and Quality Control, <sup>2</sup>Department of Clinical Sciences, College of Veterinary Medicine, Urmia University, P.O. Box 57155/1177, Urmia, Iran

**Abstract:** There are not any reports in related to evaluation of the efficacy of a combination of natural honey and medicinal plants in the therapeutic usages. The aim of this study was performed to evaluate the accelerating effect of a combination of honey and aqueous extract of yarrow on the burn wound healing in rabbit. Twenty adult white rabbits, with mean weight of  $1900 \pm 220$  g were studied. Burn wounds ( $20 \times 25$  mm<sup>2</sup>) were created in dorsal region of each animal, according to Hoekstra model. The experiment wounds were included: In A group, wounds were treated with 5 mL of natural honey every day for 21 days. In B group, wounds were treated with 5 mL of aqueous extracts of yarrow every day for same time. In C group, wounds were treated with 5 mL of a combination of honey-aqueous extracts of yarrow (50-50%) every day for same time. The control wounds were only washed with the same amount of normal saline. Clinical and microbiological examinations of the burn wounds were carried out on 0, 7, 14 and 21 days of the experiment. The wounds were photographed and compared for rate of wound contraction with digital scanning software. Base on the results of this study, significant differences were seen between the experiment (A, B and C) and control groups for the rate of contractions ( $p < 0.05$ ). Moreover, experimental wounds have lesser total bacterial count in compared to the control wounds on the day 21 ( $p < 0.05$ ). But in the experimental groups, there are not significant differences between sub-groups (A, B and C) and the combination of honey-yarrow has not any benefit than two other sub-groups (A, B) from clinical and microbiological aspects. In spite of these results, honey and yarrow still can be separately considered as low cost, easily available and potent topical agents for treatment of burn wounds.

**Key words:** Honey, yarrow, burn wound, rabbit, clinical and microbiological evaluations

### INTRODUCTION

Annually many thousands of people suffer from different kinds of burn wounds, throughout of the world. People on modern life and technological progress are in more exposed danger of burning (Subrahmanyam, 1998; Subrahmanyam *et al.*, 2001).

Heat injury, with creation of conclusive necrosis in the skin layers, prepares an environment that is suitable for a bacterial infection as a result of low tissue perfusion and high protein content. Wound infection, in addition to changing low degree burn into complete thickness necrosis, facilitates the microbe penetration into vital tissues and infection spreading as a result of skin barrier injury. Researches show that the most frequent reason (over 50%) of death resulting from burn is infection (Subrahmanyam, 1994).

While current approach to burn injury management have improved patient prognosis, increased morbidity and mortality still remains a major challenge for clinicians. There are still a small number of burn units routinely using antibiotics as a prophylactic for prevention of wound infection because of concerns regarding the high incidence of antibiotic resistance, high cost and the risk of adverse drug effects (Edwards-Jones *et al.*, 2000).

The current progress made in the analytical studies and in the field of biotechnology has led to a renewed interest in pharmacotherapy based on biogenic components. Today, more attentions have been given to medicinal plants and bee products. Honey has been used as a wound treatment agent for >2000 years (Mathews and Binning, 2002; Pierper, 2002). Honey inhibits the growth of gram-positive and gram-negative organisms (Alcaraz and Kelly, 2002; Cooper *et al.*, 1999) and

promotes epithelialization and helps in healing of the burn wounds (Cooper, 2001; Fox, 2002; Lusby *et al.*, 2002; Misirlioglu *et al.*, 2003; Shokouhi *et al.*, 2007). Yarrow (*Achillea millefolium*), belonging to the Asteraceae family, is used widely in many parts of the world (Chevallier, 1996). For many centuries various species of genus *Achillea* have been used as folk medicines for the curing of various diseases (Saeidnia *et al.*, 2005). Yarrow now has one of the widest ranges of applications of any herb used in the west. It is used for disorders of the respiratory, digestive, hepatobiliary, cardiovascular, urinary and reproductive systems (Bradley, 1992; Bown, 1995; Blumenthal *et al.*, 1998). Extracts of yarrow have demonstrated antimicrobial activity against a wide range of bacteria. Studies were carried out on the antioxidant and antimicrobial properties of yarrow and its derivatives such as essential oil and water-soluble compounds (Barel *et al.*, 1991).

In ancient cultures such as Persian, Egyptians, Assyrians, Chinese, Greeks and Romans, honey was used with combination some medicinal herbs in treatment wounds and diseases, but today, these traditional medicinal agents were studied and used alone in therapeutic applications. There is not any report in related to evaluation of a combination of them on healing process of wounds.

The aim of this study was to evaluate efficacy a combination of aqueous extract of *Achillea millefolium* and natural honey for promotion of burn wound healing in the rabbit as an animal model.

## MATERIALS AND METHODS

**Honey:** Honey samples used in this study were harvested during spring 2007, from Urmia (Northwest province of Iran) Bee Keeping Corporations. Each sample was first filtered with a sterile mesh to remove debris and stored at 2-8°C until used. The average composition of the honey is given in Table 1.

**Plant material:** Aerial parts of yarrow were collected in July 2007, during the flowering period and the vegetative phase, from Urmia area in west north of Iran. Taxonomic identity of the plant was confirmed by comparing collected voucher specimen with those of known identity in the herbarium of the Department of Botanical Sciences, Investigation Institute of Agriculture Organization of Iran. Aqueous extracts were also prepared by macerating 100 g of dried and finely ground aerial parts in 1 L absolute distilled water overnight, respectively. Aqueous dried residues were obtained by freeze-drying. Water extracts of *A. millefolium* were sterilized by filtration. The preparation of yarrow extract used was based on Aburjai and Hudaib (2006).

Table 1: Average composition of Urmia honey

Component	Average (%)
Reductant sugars	83.22
Sucrose	2.12
Fructose/glucose	0.93
Diastase	+
Commercial glucose	-
Mineral components	0.05
Moisture	15.08
Concentration	82.92
Total acid	12.50
pH	3.96

**Animals:** In this investigation, we studied 20 male white rabbits, weighing a mean of 1900±220 g standard deviation, all 4-6 months old. The rabbits were obtained from the experimental animal laboratory, Urmia university, Urmia. The animals were randomly divided into control and experimental (A, B and C) groups. Rabbits were housed under standard laboratory conditions (12 h light, 12 h dark cycles, with lights on at 8:00 am; 23°C) and maintained on standard laboratory food and water *ad libitum*. The experimental protocol was also approved by the animal ethics committee of the university. The model of the burn wound was produced according to Hoekstra standard (Brans *et al.*, 1994). On day zero, each rabbit was anesthetized by 50 mg kg<sup>-1</sup> ketamine hydrochloride, intramuscularly injected, along with 5 mg kg<sup>-1</sup> diazepam. Animals were positioned in ventral recumbency and hair just behind the shoulders was shaved from the backs then, skin was prepared for aseptic surgery.

**Experiment protocol:** All animal were subjected to the rectangular burn wounds (20×25 mm<sup>2</sup>) using a hot (180°C) brass brick weighing 300 g, which was pressed against the shaved skin for 10 sec. In the honey treated wounds (A group), as a daily procedure, wounds were washed with normal saline. Subsequently 5 mL of pure, unprocessed, undiluted, natural honey was applied in a thin layer to the wounds. In the yarrow treated wounds (B group), as a daily procedure, after washing wounds with normal saline, 5 mL of aqueous extracts of yarrow was applied in a thin layer to the wounds.

In yarrow-honey treated wounds (C group), after washing wounds with normal saline, 5 mL of a combination of yarrow (50%)-honey (50%) was applied in a thin layer to the wounds.

In the control group, the wounds were only washed with the same amount of normal saline. All the wounds were bandaged with a non-adhesive dressing, which was held in place with an elastic wrap. No antibiotic was used as a pre- or post-operative prophylaxis.

**Assessment:** The clinical assessment was done throughout the duration of the study and covered the general health conditions as well as the reaction to environment. The process of burn wound healing was especially carefully assessed. The appearance and processes taking place in the tissue surrounding the wounds were evaluated as well as the granulation tissue formation and the process of scar formation. The wounds were photographed on days 0, 7, 14 and 21. All the photographs were scanned and wound areas were measured using digital scanning software (Sigma Scans Pro 5.0, SPSS Science, Chicago, IL).

Variable analyzed included the rates of wound contraction (percent decrease of wound area) (wound area on day 0 minus wound area on day n, divided by the wound area on day 0 expressed as a percentage). The data retrieved from experiment wounds were compared with the control using ANOVA test. Differences were considered significant if  $p < 0.05$  (SPSS for windows, release 11.0.01, SPSS Science, Chicago, IL).

**RESULTS**

Wound healing was uneventful during the experiment period. The animals revealed a normal reaction to the environment and showed no symptoms of suffering due to burn wounds at day after operation.

The clinical evaluation showed visible differences in the process of wound healing after applying the above mentioned medications. The rates of wound contraction (percent decrease of wound area) in experiment and control wounds are revealed in Fig. 1 and Table 2.

Results of microbiological examinations of burn wounds of control and treatment groups (A, B and C sub-groups) are shown in Fig. 1.

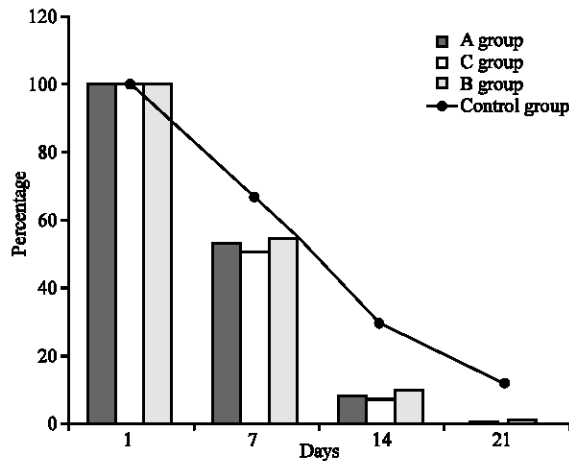


Fig. 1: Comparative diagram of wounds surfaces of control and experimental groups (A, B and C)

**DISCUSSION**

Today, there is a public interest to usage of natural and traditional therapies such as medicinal plants and biological products (Molan, 2000). Honey and yarrow were specially considered as natural therapeutic bio-products. There are many reports of efficacy of both these agents in treatment of various diseases but there is not any document in relate to therapeutics effects of a combination of them (Al-Jabri *et al.*, 2003; Ceyhan and Ugur, 2001; Haffejee and Moosa, 1985; Obi *et al.*, 1994; Tajik *et al.*, 2008). The aim of this study was to evaluate the efficacy of a combination of these natural bioactive components on the healing of experimental burn wounds. According to the results of this study, wound contraction in all groups (control and experiment groups (A, B and C sub-groups)) occurred at during days 7 through 21, which indicates that the percentage change in wound area was constant during this period. These findings suggest that application of biological products (honey and yarrow) on experimental burn wound significantly increased both the rate and amount of wound contraction. Figure 1 showed that the decrease in wound area was significantly greater in the treatment groups (A, B and C sub-groups) (99.24, 98.78 and 99.59%, respectively) compared to the control (88.18%) at day 21 ( $p < 0.05$ ). But there are not significant differences between wounds surfaces in experimental group (A, B and C sub-groups). Also, at the same time, the results of total bacterial count in control and experimental groups were comparatively shown in Fig. 2. Base on these results, on the 21st day, the total number of isolated microorganisms in treated wound (A, B and C sub-groups) was significantly lesser than control group ( $p < 0.05$ ).

Antimicrobial activity of honey is thought to be due to physicochemical properties (high content of reducing

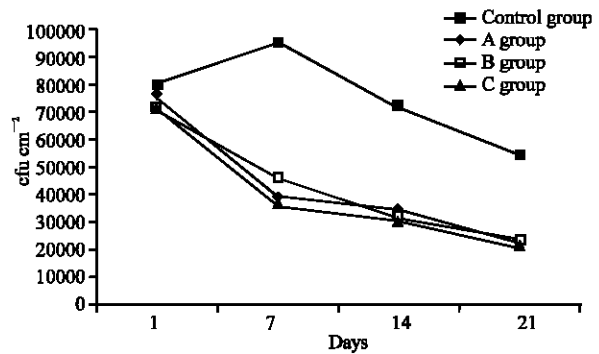


Fig. 2: Comparative diagram of total bacterial count of burn wounds of control and experimental groups (A, B and C)

Table 2: Comparison of wound area (mm<sup>2</sup>) (mean±SD) and percent decrease in the experiment (A, B and C) wounds and control wounds

Groups	Days			
	0	7	14	21
A groups	544.4±22.14	290.4±62.24*	44.22±24.12*	4.12±6.24*
Percent decrease in the wounds	(00.00)	(46.66)	(91.87)	(99.24)
B groups	524.2±62.24	284.4±82.22	51.64±40.42	6.42±4.66
Percent decrease in the wounds	(00.00)	(45.75)	(90.15)	(98.78)
C groups	554.2±24.22	280.64±22.12	40.22±42.20	2.24±0.26
Percent decrease in the wounds	(00.00)	(49.31)	(92.74)	(99.59)
Control groups	562.2±24.04	374.42±12.04	164.22±26.06	66.44±24.14
Percent decrease in the wounds	(00.00)	(33.40)	(70.61)	(88.18)

\*Statistical significant (p<0.05)

sugars, high viscosity, high osmotic pressure, low pH, low Water Activity (AW), low protein content) and hydrogen peroxide (Snowden and Cliver, 1996; Molan and Cooper, 2000). Also Radwan *et al.* (1984) attributed the antibacterial activity to the specific chemicals in honey. The nature of these chemicals and the mechanisms of their action are not fully understood even though Thin Layer Chromatography (TLC), Polyacrylamide Gel Electrophoresis (PAGE) or High Performance Liquid Chromatography (HPLC) have shown that honey contains fatty acids, lipids, amylases and ascorbic acids (Radwan *et al.*, 1984).

Yarrow also contains many bioactive compounds which have antibacterial properties. Linalool, found at up to 26% of the essential oil fraction in hexaploids, which are the most common subspecies of *A. millefolium*, has been shown to inhibit 17 types of bacteria and 10 fungi (Pattnaik *et al.*, 1997). An investigation of extracts of yarrow revealed the presence of 5 unsaturated hitherto unknown guaianolides with peroxidal property. These components also have inhibitory effect on some microorganisms (Hausen *et al.*, 1991). Furthermore, *A. millifolium* has been reported to contain some flavonoids with antibacterial efficacy such as rutin and glucosides of apigenin, luteolin and acacetin (Aljancic *et al.*, 1999).

The findings of this study were shown topical application of the natural therapeutic agents (honey, yarrow and honey-yarrow combination) in treatment of burn wounds not only accelerates the healing procedure but has valuable antimicrobial effect in promoting the recovery of this kind of wounds.

In view of the fact that the present study is very likely the first experimental investigation on the therapeutic effects of the combination of honey and yarrow as a promoter of burn wound healing, our results are not comparable with those of previous research. On the basis of the results, in the experimental groups, there are not significant differences between sub-groups (A, B and C) and the combination of honey-yarrow has not any benefit than 2 other sub-groups (A, B).

In spite of these results, honey and yarrow still can be separately considered as low cost, easily available and potent topical agents for treatment of all kind wounds, especially burn wound.

## REFERENCES

- Aburjai, T. and M. Hudaib, 2006. Antiplatelet, antibacterial and antifungal activities of *Achillea falcata* extracts and evaluation of volatile oil composition. *Pharmacognosy Mag.*, 2 (7): 191-198. PMID: 17097250.
- Alcaraz, A. and J. Kelly, 2002. Treatment an infection venous leg ulcer with honey dressing. *Br. J. Nurs.*, 11 (13): 859-866. PMID: 12131839.
- Al-Jabri, A.A., B. Nzeako, Z. Al Mahrooqi, A. Al Naqdy and H. Nsanze, 2003. *In vitro* antibacterial activity of Omani and African Honey. *Br. J. Biomed. Sci.*, 60 (1): 1-4. PMID: 12680622.
- Aljancic, I., V. Vajs and N. Menkovic, 1999. Flavones and sesquiterpene lactones from *Achillea atrata* subsp. *multifida*: Antimicrobial activity. *J. Natl. Prod.*, 62 (6): 909-911. PMID: 10395518.
- Barel, S., R. Segal and J. Yashphe, 1991. The antimicrobial activity of the essential oil from *Achillea fragrantissima*. *J. Ethnopharmacol.*, 33 (1-2): 187-191. PMID: 1943167.
- Blumenthal, M., M. Busse and A. Goldberg, 1998. The Complete German Commission E Monographs: Therapeutic Guide to Herbal Medicines. Am. Botanical Council, Austin, TX, pp: 55-56.
- Bown, D., 1995. *Encyclopaedia of Herbs and their Uses*. Dorling Kindersley, London, pp: 101-105.
- Bradley, P., 1992. *British Herbal Compendium*. British Herbal Medicine Association, Dorset, Great Britain, pp: 227-229.
- Brans, A., D. Dutrieux, M.J. Hoekstra, 1994. Histopathological evaluation of scalds and contact burns in the pig model. *Burns*, 20: 548-551. PMID: 8198744.

- Ceyhan, N. and A. Ugur, 2001. Investigation of *in vitro* Antimicrobial Activity of Honey. *Riv. Biol. B. Forum*, 94 (2): 363-371. PMID: 11702659.
- Chevallier, A., 1996. The Encyclopedia of Medicinal Plants. Dorling Kindersley, London, pp: 102-105.
- Cooper, R., 2001. How Does Honey Heal Wounds? Honey and Healing. In: Munn, P. and R. Jones (Eds.). Cardiff, International Bee Research Association, pp: 27-34. PMID: 10776224.
- Cooper R.A., P.C. Molan and K.G. Harding, 1999. Antibacterial activity of honey against strains of *Staphylococcus aureus* from infected wounds. *J. Royal Soc. Med.*, 92 (6): 283-5. PMID: 10472280.
- Edwards-Jones, V., M.M. Dawson and C.A. Childs, 2000. Survey into TSS in UK Burns Units. *Burns*, 26: 323-333. PMID: 10751699.
- Fox, C., 2002. Honey as a dressing for chronic wounds in adults. *Br. J. Commun. Nurs.*, 7 (10): 530-534. PMID: 12399705.
- Haffejee, I.E., A. Moosa, 1985. Honey in the treatment of infantile gastroenteritis. *Br. Med. J.*, 290: 1866-1867. PMID: 3924286.
- Hausen, B.M., J. Bheuer, J. Weglewski and G. Rucker, 1991.  $\alpha$ -Peroxyachifolid and other new sensitizing sesquiterpene lactones from yarrow (*Achillea millefolium* L., Compositae). *Contact Dermatitis*, 24 (4): 274-280. PMID: 1868717.
- Lusby, P.E., A. Coombes and J.M. Wilkinson, 2002. Honey a potent agent for wound healing. *Wound, Ostomy Continence Nurs.*, 22 (6): 273-274. PMID: 12439453.
- Mathews, K.A. and A.G. Biming, 2002. Wound management using honey. *Compend. Con. Edu.*, 24 (1): 53-59.
- Misirlioglu, A., S. Eroglu, N. Karacaoglan, M. Akan and B. Akoz, 2003. Use of honey as an adjunct in the healing of Split-Thickness skin graft doner site. *Dermatol. Surg.*, 22 (2): 168-172. PMID: 12562348.
- Molan, P.C. and R.A. Cooper, 2000. Honey and suger as a dressing for wounds and ulcers. *Trop. Doct.*, 30: 249-251. PMID: 11075670.
- Obi, L., E.O. Ugoji and S.A. Edun, 1994. The antibacterial effect of honey on diarrhea causing bacterial agent isolated in Lagos, Nigeria. *Afr. J. Med. Sci.*, 36: 283-284. PMID: 7604751.
- Pattnaik, S., V.R. Subramanyam and M. Bapaji, 1997. Antibacterial and antifungal activity of 10 essential oils *in vitro*. *Microbios*, 89: 39-46. PMID: 8893526.
- Pierper, B., 2002. Honey: A potent agent for wound healing? *J. Wound. Ostomy. Continence. Nurs.*, 22 (6): 295-300. PMID: 12439448.
- Radwan, S.S, A.A. El-Essawy and M.M. Sarhan, 1984. Experimental evidence for the occurrence in honey of specific substances active against micro-organisms. *Zentralblatt fur Mikrobiologie*, 139: 249-255. PMID: 6475343.
- Saeidnia, S., A.R. Gohari, N. Yassa and A. Shafiee, 2005. Composition of the volatile oil of *Achillea Conferta* from Iran. *DARU.*, 13 (1): 34-36.
- Shokouhi, S.J.F., H. Tajik and A. Tehrani, 2007. Experimental evaluation of repair process of burn wound treated with aqueous extract of *Achillea millefolium* on animal model: Clinical and histopathological study. *J. Anim. Vet. Adv.*, 6 (12): 1357-1361.
- Snowden, J.A. and D.O. Cliver, 1996. Microorganisms in honey. *Int. J. Food Microbiol.*, 31: 1-26.
- Subrahmanyam, M., 1994. Honey-impregnated gauze versus amniotic membrane in the treatment of burns. *Burns*, 20 (4): 331-333. PMID: 7945822.
- Subrahmanyam, M., 1998. A prospective randomized clinical and histological study of superficial burn wound healing with honey and silver sulfadiazine. *Burn*, 24: 157-161. PMID: 9625243.
- Subrahmanyam, M., A.G. Sahapure, N.S. Nagane, V.R. Bhagwat and J.V. Ganu, 2001. Effects of topical application of honey on burn wound healing. *Annals of Burns and Fire Disasters*, XIV (3): 15-16.
- Tajik, H., F.S.S. Jalali, A. Sobhani, Y. Shahbazi and M.S. Zadeh, 2008. *In vitro* assessment of antimicrobial efficacy of alcoholic extract of *Achillea millefolium* in comparison with penicillin derivatives. *J. Anim. Vet. Adv.*, 7 (4): 508-511.