

## Effects of Onion Juice Administration on Electrocardiogram in Dogs

Ebubekir Ceylan, Ismail Aytekin, Ihsan Keles and Nuri Altug

Department of Veterinary Internal Medicine, Faculty of Veterinary Medicine,  
University of Yuzuncu Yil, 65080 Van, Turkey

**Abstract:** The purpose of this study, was to investigate the effects of Onion Juice Administration (OJA) on Electrocardiogram (ECG) in dogs. Five clinically healthy street dogs were used in this study. Onion juice was given through oro-gastric tube of 400 g onion kg<sup>-1</sup> body weight dose in 500 mL water. Blood samples were collected at just before and after (6, 12 and 24th h) Onion Juice Application (OJA). PCV, heart beats counts and electrocardiograms of the animals in the same time were determined. PCV values gradually, decreased and these decreases were significant at 6th (p<0.01), 12th (p<0.01) and 24th (p<0.001) h after OJA. Bradycardia was observed at 6th (p<0.05) and 12th (p<0.001) h after OJA whereas tachycardia was observed at 24th h (p<0.001). Before and 6th h after OJA heart rates were within normal limits in this study. First degree heart block occurred 12th h after OJA and aritmia was obvious at this time. P-Q interval also increased. Bradycardia developed in some derivations. The mean heart rate was approximately 60 beats min<sup>-1</sup>. Twenty-four hours after OJA tachycardia developed and the mean heart rate was 130 beats min<sup>-1</sup>. In summary, OJA caused the anemia (reduction in the PCV values,) 1st degree heart block, tachycardia in dogs. Further studies on this issue, might be helpful for determining the effects of OJA on ECG in different species.

**Key words:** Dog, onion juice, electrocardiography, heinz body, hemolytic anemia, experimental study

### INTRODUCTION

Oral administration of onion has been reported to cause Heinz body hemolytic anaemia by several workers in different domestic animals such as cattle, horses, dogs, sheep (Harvey and Rackear, 1985; Jain, 1993; Agaoglu *et al.*, 1998; Simmons, 2001; Tang *et al.*, 2008) and also, in avian species (Crespo and Chin, 2004). It is well established that onions contain oxidative chemicals, such as n-propyl disulfide (Simmons, 2001; Cheeke, 1998; Cope, 2005). This oxidative chemical depletes the enzyme glucose 6-phosphate dehydrogenase within erythrocytes, thus diminishing the protective effect of the antioxidant glutathione by failure of reduction of oxidized glutathione. This results in formation of mixed disulfide linkages between globins chains of hemoglobin and glutathione, which precipitate within the cell, resulting in formation of Heinz bodies. Erythrocytes that contain Heinz bodies are removed from the circulation by the reticuloendothelial system, thus causing anemia. Damaged erythrocytes are removed from circulation or possibly lysing within circulation, causing haemoglobinemia and haemoglobinuria (Amagase *et al.*, 2001; Cope, 2005; Simmons, 2001).

On the other hand, onion has also been reported to have lowering affect on high blood pressure and antithrombotic effects. Thus, consumption of onion reported to prevent platelet-mediated cardiovascular disorders, such as thrombosis (Goldman *et al.*, 1995; Chen *et al.*, 2000; Briggs *et al.*, 2001). Onion has also been used in the treatment of hypercholesterolemia, arteriosclerosis and diabetes mellitus (Fattorusso *et al.*, 2002; Jelodar *et al.*, 2005; Lanzotti, 2006). In contrast, onion causes prolongation in the bleeding time and elevation in the cyclic AMP (Burnham, 1995; Jung *et al.*, 2002; Ernst, 2005; Pribitkim, 2005). Furthermore, tachycardia after ingestion of raw or lightly-cooked onions in a woman has also been reported (Arena *et al.*, 2000).

In a study, it was reported that onion poisoning cause increase in potassium and decrease in the sodium concentration (Simmons, 2001). Furthermore, dogs with genetically high erythrocyte reduced glutathione and potassium concentrations reported to be more susceptible to oxidant action of onions (Yamoto and Maede, 1992).

Although, the effects of onion on several vital functions have been studied widely, to the best of our knowledge, its effect on electrocardiography has not been

studied. It is known to effect heart indirectly but its reflection on Electrocardiography (ECG) has not been documented. Therefore, the main objective of the present study was to determine the effects of Onion Juice Administration (OJA) on ECG in dogs.

**MATERIALS AND METHODS**

In this study, 5 clinically healthy street dogs, 3 male and 2 female, weighing 10-20 kg and between 1-3 years old were used. The dogs were kept during the experiment at the University of YYU, Animal Hospital. During study, the animals were fed with their required diet and water *ad libitum*.

First of all, sufficient amount of onions minced then boiled in water for 15 min. Then supernatant were put into cooling. The dogs were not fed for 24 h before starting experiment. Then the prepared onion juice was given through oro-gastric tube of 400 g onion kg<sup>-1</sup> dose in 500 mL water. Blood samples were collected at 0 time (just before OJA) and 6th, 12th and 24th h after OJA. Packed Cell Volume (PCV) analysis and heart beats counts in the same times were to determine the efficacy of the onion poisoning. Furthermore, electrocardiogram of the animals was also taken as well at 0, 6th, 12th and 24th h after OJA.

The animals were treated as reported by Simmons (2001) according to their clinical condition. After recovery, the animals were set free to their natural environment.

For statistical analysis, Student's t test was used to determine the differences between the values obtained before and after treatment. For this purpose, the SPSS 12.0 software was used. Statistical significance was set at  $p < 0.05$ . All data were expressed as means  $\pm$  SEM.

**RESULTS**

**Haematology:** The PCV values of the animals before and after OJA were given in Fig. 1. PCV values decreased significantly 6th ( $p < 0.01$ ), 12th ( $p < 0.01$ ) and 24th ( $p < 0.001$ ) h after OJA. The decrease occurred gradually. This shows that the poisoning occurred after this application in all animals.

**Electrocardiography:** Electrocardiography findings are given in Table 1. Before and 6 h after OJA heart rates were in normal limits (Table 1). First degree heart block occurred 12 h after OJA. Aritmia was obvious at this time. P-Q interval was also increased. In some derivations bradycardia developed. The mean heart rate was approximately, 60 beats min<sup>-1</sup> (Fig. 2). The 24 h after OJA

**Table 1: ECG findings after OJA in dogs**

Parameters	Before	After OJA		
	OJA	6 h	12 h	24 h
Heart rate (Beats min <sup>-1</sup> )	90.2 $\pm$ 1.71	81.4 $\pm$ 3.48*	60.6 $\pm$ 1.93***	130.6 $\pm$ 3.53***
P-n	0.04 $\pm$ 0.01	0.05 $\pm$ 0.02	0.06 $\pm$ 0.03	0.03 $\pm$ 0.01
P-nv	0.13 $\pm$ 0.03	0.11 $\pm$ 0.04	0.12 $\pm$ 0.03	0.12 $\pm$ 0.04
PQsn interval	0.10 $\pm$ 0.02	0.12 $\pm$ 0.03	0.14 $\pm$ 0.02*	0.08 $\pm$ 0.03
QRSn	0.06 $\pm$ 0.02	0.05 $\pm$ 0.01	0.06 $\pm$ 0.02	0.04 $\pm$ 0.01
QRSnv	1.6 $\pm$ 0.15	1.6 $\pm$ 0.21	1.7 $\pm$ 0.19	0.20 $\pm$ 0.22***
Isn	0.06 $\pm$ 0.02	0.05 $\pm$ 0.02	0.06 $\pm$ 0.03	0.07 $\pm$ 0.01
Innv	1.15 $\pm$ 0.21	0.77 $\pm$ 0.28	0.15 $\pm$ 0.09***	0.20 $\pm$ 0.06***

Statistical importance with before and after OJA; \* $p < 0.05$ , \*\*\* $p < 0.01$ , \*\*\*\* $p < 0.001$

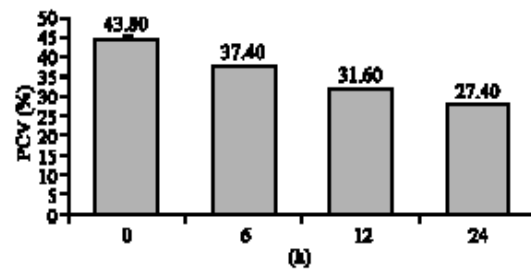


Fig. 1: PCV values changes after OJA




Fig. 2: Sinus bradycardia and first degree A-V blockage in the 12th h after OJA

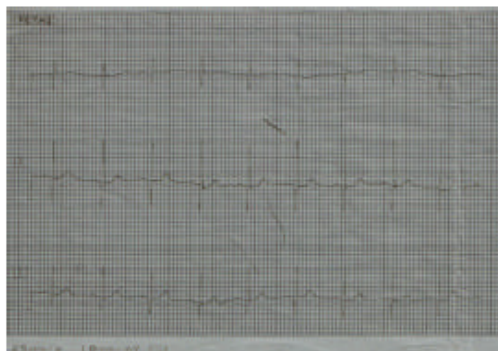

Fig. 3: Sinus bradycardia in the 24th h after OJA

tachycardia developed and the mean heart rate was 130 beats min<sup>-1</sup> (Fig. 3). ECG findings obtained at 12th h and at 24th h were not alike. Electrical axis of the heart before and after OJA was changed between +50° and ±85° being average 70°.

### DISCUSSION

Onion poisoning has been reported to cause erythrocyte degeneration through oxidative chemicals. Occurrence of intra-vascular and/or extra-vascular haemolysis in these cases has been well established. Decrease in PCV and anaemia are also well known signs of the onion poisoning (Jain, 1993; Simmons, 2001; Cheeke, 1998; Cope, 2005; Lee *et al.*, 2000). Similar findings were also, observed in the present study. However, the response of the heart in such conditions has not been studied.

First degree of heart block developed 12 h after OJA (P-Q interval changed from 0.10-0.14 sec (p<0.05)) in the present study. As a result, these heart beat reduced from 90-60 per min. This first degree heart block and bradycardia occurrence could be aroused from little increase in K<sup>+</sup> concentrations as a result of OJA (Simmons, 2001; Bonvini *et al.*, 2006). Unfortunately, there are no findings regarding to effect of OJA on ECG. Therefore, it is difficult to compare findings in the present study with other results.

Tachycardia also developed 24 h after OJA and PCV values decreased gradually from 43.8% (0 time) to 27.4% (24th h). Heartbeat rate increases by cardiovascular and respiratory centers in the medulla oblongata and pons due to O<sub>2</sub> need of tissues (Berne and Levy, 1993). OJA, in the present study, resulted in reduction in RBC and PCV forming anemia and therefore caused tachycardia.

### CONCLUSION

This is the first study to report the effects of OJA on ECG. In summary, OJA caused the anemia (reduction in the PCV values,) first degree heart block, tachycardia in dogs. Studies to be done on effects of OJA on ECG in different species could be useful for useful findings.

### REFERENCES

Agaoglu, Z.T., A. Ertekin, M. Yoruk, B. Baydas and E. Ceylan, 1998. The effect of onion (*Allium cepa*) on some hematological and biochemical parameters in dogs. YYU. Vet. Fak. Derg., 9 (1-2): 36-40. <http://vfdergi2.yyu.edu.tr/1998.html>.

Amagase, H., B.L. Petesch, H. Matsuura, S. Kasuga and Y. Itakura, 2001. Intake of garlic and its bioactive components. J. Nutr., 131: 955-962. PMID: 11238796. <http://jn.nutrition.org/cgi/reprint/131/3/955S>.

Arena, A., C. Cislighi and P. Falagiani, 2000. Anaphylactic reaction to the ingestion of raw onion. A case report. Allergol Immunopathol. (Madr), 28(5): 287-289. PMID: 11270091. [http://www.elsevier.es/revistas/ctl\\_servlet?\\_f=7064&articuloid=10017984](http://www.elsevier.es/revistas/ctl_servlet?_f=7064&articuloid=10017984).

Berne, R.M. and M.N. Levy, 1993. Physiology. 3rd Edn. Mosby Year Book, Missouri, pp: 361-562. ISBN: 0-8016-6465-9.

Bonvini, R.F., T. Hendiri and A. Anwar, 2006. Sinus arrest and moderate hyperkalemia. Ann. Cardiol. Angeiol. (Paris), 55 (3): 161-163. DOI: 10.1016/j.ancard.2005.10.001. PMID: 16792034.

Briggs, W.H., J.D. Folts, H.E. Osman and I.L. Goldman, 2001. Administration of Raw Onion Inhibits Platelet-Mediated Thrombosis in Dogs. J. Nutr., 131: 2619-2622. PMID: 11584080. <http://jn.nutrition.org/cgi/reprint/131/10/2619>.

Burnham, B.E., 1995. Garlic as a possible risk for postoperative bleeding. Plastic Recon. Surg., 95: 213. PMID: 7809259.

Cheeke, P.R., 1998. Natural Toxicants in Feeds, Forages and Poisonous Plants. 2nd Edn. Interstate Publishers, Inc. Danville, IL, pp: 3-79. ISBN: 0-8134-3128-X.

Chen, J.H., H. Chen, S.J. Tsai and C.J. Jen, 2000. Chronic consumption of raw but not boiled welsh onion juice inhibits rat platelet function. J. Nut., 130: 34-37. PMID: 10613763. <http://jn.nutrition.org/cgi/reprint/130/1/34>.

Cope, R.B., 2005. Allium species poisoning in dogs and cats. Vet. Med., 100: 562-566. <http://veterinarymedicine.dvm360.com/vetmed/Medicine/Toxicology-Brief-iAlliumi-species-poisoning-in-dog/ArticleStandard/Article/detail/174478>.

Crespo, R. and R.P. Chin, 2004. Effect of feeding green onions (*Allium ascalonicum*) to White Chinese geese (*Threskiornis spinicollis*). J Vet. Diagn. Invest., 16: 321-325. PMID: 15305744. <http://www.jvdi.org/cgi/reprint/16/4/321>.

Ernst, E., 2005. The efficacy of herbal medicine-on overview. Fundamental Clin. Pharmacol., 19: 405-409. DOI: 10.1111/j.1472-8206.2005.00335.x. PMID: 1601-1726.

Fattorusso, E., M. Iorizzi, V. Lanzotti and O. Tagliatalata-Scafati, 2002. Chemical Composition of Shallot (*Allium ascalonicum* Hort.). J. Agric. Food Chem., 50: 5686-5690. DOI: 10.1021/jf020396t. PMID: 1223-6699.

- Goldman, I.L., B.S. Schwartz and M. Kopelberg, 1995. Variability in blood platelet inhibitory activity of *Allium* (Alliaceae) species accessions. *Am. J. Bot.*, 82: 827-832. [http://grande.nal.usda.gov/ibids/index.php?mode2=detail&origin=ibids\\_references&therow=396783](http://grande.nal.usda.gov/ibids/index.php?mode2=detail&origin=ibids_references&therow=396783).
- Harvey, J.W. and D. Rackear, 1985. Experimental onion-induced hemolytic anemia in dogs. *Vet. Pathol.*, 22: 387-392. <http://www.vetpathology.org/cgi/content/abstract/22/4/387>.
- Jain, N.C., 1993. *Essentials of Veterinary Hematology*, Lea and Febiger, Philadelphia, pp: 19-53. ISBN: 0-8121-1437-X.
- Jelodar, G.A., M. Maleki, M.H. Motadayen and S. Sirus, 2005. Effect of fenugreek, onion and garlic on blood glucose and histopathology of pancreas of alloxan-induced diabetic rats. *Indian J. Med.*, 59: 64-69. PMID: 15738612. [http://www.indianjmedsci.org/emp/IndianJMedSci59264-5719301\\_155313.pdf](http://www.indianjmedsci.org/emp/IndianJMedSci59264-5719301_155313.pdf).
- Jung, Y.S., Kim, S.H. Lee, E.J. Baik, S.W. Park and C.H. Moon, 2002. Antithrombotic effect of onion in streptozotocin induced diabetic rat. *Prostaglandins, Leukotrienes and Essential Fatty Acids*, 66 (4): 453-458. DOI: 10.1054/plf.2002.0373. PMID: 12054917.
- Lee, K.W., O. Yamato, M. Tajima, M. Kuraoka, S. Omae and Y. Maede, 2000. Hematologic changes associated with the appearance of eccentrocytes after intragastric administration of garlic extract to dogs. *Am. J. Vet. Res.*, 61 (11): 1446-1150. DOI: 10.2460/ajvr.2000.61.1446. PMID: 11108195.
- Lanzotti, V., 2006. The analysis of onion and garlic. *J. Chromatography A*, 1112: 3-22. DOI: 10.1016/j.chroma.2005.12.016. PMID: 16388813.
- Pribitkim, E.A., 2005. Herbal medicine and surgery. *Semin Integr. Med.*, 3: 17-23. DOI: 10.1016/j.sigm.2005.01.005. [http://www.sciencedirect.com/science?\\_ob=MImg&\\_imagekey=B75KC-4G8FD2W-7-1&\\_cdi=13175&\\_user=736695&\\_orig=search&\\_coverDate=03%2F31%2F2005&\\_sk=999969998&view=c&wchp=dGLbVIW-zSkzS&md5=e82cda0da9241c06795fa88b01657c38&ie=/sdarticle.pdf](http://www.sciencedirect.com/science?_ob=MImg&_imagekey=B75KC-4G8FD2W-7-1&_cdi=13175&_user=736695&_orig=search&_coverDate=03%2F31%2F2005&_sk=999969998&view=c&wchp=dGLbVIW-zSkzS&md5=e82cda0da9241c06795fa88b01657c38&ie=/sdarticle.pdf).
- Simmons, D.M., 2001. Onion breath, *Vet. Technician*, 22: 424-427. [http://www.aspc.org/site/DocServer/vettech\\_0801.pdf?docID=349](http://www.aspc.org/site/DocServer/vettech_0801.pdf?docID=349).
- Tang, X., Z. Xia and J. Yu, 2008. An experimental study of hemolysis induced by onion (*Allium cepa*) poisoning in dogs. *J. Vet. Pharmacol. Ther.*, 31: 143-149. DOI: 10.1111/j.1365-2885.2007.00930.x. PMID: 18307506.
- Yamoto, O. and Y. Maede, 1992. Susceptibility to onion-induced hemolysis in dogs with hereditary high erythrocyte reduced glutathione and potassium concentrations. *Am. J. Vet. Res.*, 53 (1): 134-137. PMID: 1539905.