

## Experimental Trial of the Effect of Fumonisin B<sub>1</sub> and the PRRS Virus in Swine

<sup>1</sup>Carolina Moreno Ramos, <sup>1</sup>Ernesto Moreno Martínez, <sup>1</sup>Abel Ciprián Carrasco,  
<sup>1</sup>Jesus. H. Lara Puente, <sup>1</sup>Francisco Quezada, <sup>1</sup>Jorge Tortora Perez,  
<sup>2</sup>Isabelle P. Oswald and <sup>1</sup>Susana Mendoza Elvira  
<sup>1</sup>Facultad de Estudios Superiores Cuautitlan U.N.A.M.,  
Av. 1º de mayo, Campo 1, Col. Atlanta, Cuautitlan Izcalli, C.P. 54750, Mexico  
<sup>2</sup>Pharmacology and Toxicology Laboratory, UR 66,  
Nacional Institute of Agronomic Research INRA,  
180 Chemin de Tournefeuille, B.P. 3, 31931 Toulouse Cedex 9, France

**Abstract:** Fumonisin B<sub>1</sub> (FB<sub>1</sub>) belongs to a group of mycotoxins produced by fungi of the genus *Fusarium*. In swine farms, the presence of the Porcine Reproductive and Respiratory Syndrome Virus (PRRSV) causes significant economic losses in Mexican swine industry. In this experiment, the effect of the presence of FB<sub>1</sub> and PRRSV was evaluated in five groups of 5 pigs; Group A: Negative control; Group B: Inoculated with 12 ppm of FB<sub>1</sub> starting from day 0; Group C: Inoculated with PRRSV on day 8; Group D: Inoculated with PRRSV and 12 ppm of FB<sub>1</sub> starting from day 0, respectively and Group E: Inoculated with 12 ppm of FB<sub>1</sub> starting from day 0 and inoculated with PRRSV on day 8. Daily Weight Gain (DWG) and pathologic and histopathologic changes in the lung, liver and kidney were evaluated and the presence or absence of PRRSV was determined by the RT-PCR test in the groups treated. A negative slope effect was observed in weight gain in groups D and E (-0.103 and -0.37, respectively) indicating weight loss with the presence of PRRSV and FB<sub>1</sub>. Regarding the percentage of macroscopic lung lesions, it was found that group B had reddish consolidation, 1.4%; group C showed diffuse consolidation, 9.42%; group D had diffuse consolidation, 5.41% and reddish consolidation, 1.63% and group E had diffuse consolidation, 5.91% and reddish consolidation, 3.50%. The histopatologic findings in the lungs were: thickened alveolar septa with mononuclear infiltrate, with vascular changes and clean alveoli characteristic of interstitial pneumonia. In group D in which the pathogens were administered on day 0, moderate diffuse interstitial pneumonia was observed. Group E showed severe interstitial lung lesion. Polyploidy and binuclear cells were observed in the liver, suggesting mycotoxicosis in groups B, D and E. Another organ that showed alterations was the kidney in groups B, D, E and a mononuclear cell infiltrate was found in only one piglet in group C. Proliferative glomerulonephritis was observed in association with these damaged parts of nephrons as well as size-reduced, shrunk and atrophied glomeruli. On the other hand, the results obtained to prove the presence of PRRSV by the RT-PCR technique were negative for group A and group B and were positive for groups C, D and E, which were inoculated with PRRSV according to the experimental design. Based on the results obtained in this study, it could be observed that PRRSV and FB<sub>1</sub> have an additive effect in swine. It was also observed that group E had a greater lung damage histologically.

**Key words:** Fumonisin B<sub>1</sub>, PRRS virus, pneumonia, edema, pigs, France

---

### INTRODUCTION

Animal nutrition is based to a large extent on the consumption of grains and grain derivatives. These are harvested all year long under diverse climatic conditions, therefore, they are invaded by fungi both in the fields and in the warehouses. The main contaminating fungal species are *Aspergillus* sp. and *Penicillium* sp. (Christensen and Kaufmann, 1969). In recent years, the presence of

fumonisins in cereals has gained special importance from the point of view of health and animal productivity (Marasas, 2001). Fumonisins are a group of mycotoxins produced mainly by *Fusarium verticillioides* (*F. moniliforme*), one of the most common fungi found in corn and other cereals. Fumonisin B<sub>1</sub> (FB<sub>1</sub>) causes leukoencephalomalacia in equines (ELEM) it is nephrotoxic in rats, rabbits and sheep in addition to being hepatotoxic in all the species examined (Bolger *et al.*,

2001; WHO, 2000). In humans, it has been reported as a factor responsible for or contributing to the development of esophageal cancer (Rheeder *et al.*, 1992). In swine, it is responsible for porcine pulmonary edema, liver failure and cardiovascular toxicity which has a negative impact on production (Haschek *et al.*, 2001). Fumonisin toxicosis in swine was called Porcine Pulmonary Edema (PPE) following a fatal disease outbreak in swine, caused by the consumption of contaminated food from the 1989 corn harvest in the United States (Marasas, 2001).

The disease has been experimentally reproduced by feeding with corn contaminated with *F. verticillioides* and by the intravenous administration of fumonisin B<sub>1</sub>. A study conducted by Harrison *et al.* (1990) showed that pure FB<sub>1</sub>, at concentrations of 0.4 mg kg<sup>-1</sup> of body weight/4 days causes pulmonary edema in swine by intravenous injection. Gumprecht *et al.* (1998) developed pulmonary edema on day 3 in swine fed with food contaminated with 20 mg of FB<sub>1</sub> kg<sup>-1</sup> of body weight day<sup>-1</sup>. Fumonisin induce accumulation of membranous material in pulmonary endothelial cells, this change appears to be specific for this type of cells in swine (Haschek *et al.*, 2001).

The toxic effect of mycotoxins is difficult to prove. Based on the results obtained, fumonisins are considered as potential carcinogens within the IARC (International Agency for Research on Cancer) classification, class 2B (Zomborszky *et al.*, 2002). FB<sub>1</sub> is the one found more frequently as natural contaminant and accounts for >70% of the total fumonisins found, essentially in corn and corn by-products (Gimeno, 2008), this is of great importance due to the toxicity it may cause in swine.

Porcine Reproductive and Respiratory Syndrome (PRRS) is a viral disease in swine caused by a RNA virus of the *Arteriviridae* family. There is a great antigenic and genetic variability among different PPRSV isolates, especially among European and American isolates (Goyal, 1993).

Clinical manifestations include reproductive disorders in pregnant sows, such as estrus repetition, resorption and embryonal mortality as well as birth of weak piglets. However, this virus is also responsible for the development of respiratory problems, affecting piglets, rebreeding animals and slaughter animals as well as the productive and reproductive variables (Hill, 1990; Rossow, 1998). It is a highly infectious virus that replicates within the monocyte/macrophage cell line and the lung is a predominant site of viral multiplication (alveolar macrophages). It may also multiply in endothelial cells and spermatozoa (Fraile, 2004). The

clinical signs of PRRS vary considerably due to several causes, such as differences in the herd's susceptibility, environmental factors, the immune state and the viral strain as well as its combination with other viruses or bacteria that affect swine (Goyal, 1993). In Mexico, as in other countries, the problems associated with this disease have caused losses in porcine industry. In 1994, PRRS disease appeared in Mexico through swine imports from the United States.

Several farms from the states of Sonora, Jalisco, Aguascalientes and Guanajuato were affected, and 491 serum samples were analyzed (Correa *et al.*, 1994). It may be considered that the presence of FB<sub>1</sub> in food increases swine susceptibility to PRRSV and therefore, it may negatively affect swine farms (Gimeno, 2008).

The purpose of this research was to evaluate the possible additive effect of fumonisin B<sub>1</sub> and PRRSV in swine and to establish the morphologic alterations under controlled conditions.

## MATERIALS AND METHODS

### Evaluation of the concentration of aflatoxins and fumonisins in food

**Aflatoxin determination:** The quantification of aflatoxins was performed according to the method reported in AOAC 991.31 using monoclonal antibody columns for toxins B<sub>1</sub>, B<sub>2</sub>, G<sub>1</sub> and G<sub>2</sub> (Aflatest, VICAM Science Technology, 303 Pleasant St., Watertown, MA, USA).

**Fumonisin determination:** The quantification of fumonisins was performed by the monoclonal antibody column technique for fumonisins (Fumonitest, VICAM Science Technology, 303 Pleasant St., Watertown, MA, USA). For this, the extraction was carried out by placing 50 g of ground sample, 100 mL of 80% methanol and 5 g of NaCl in a blender glass jar and was homogenized in the blender for 1 min. Afterwards, it was filtered through whatman No. 1 paper, 10 mL were taken and diluted to a 50 mL volume with phosphate/0.1% tween-20 buffer solution.

The solution was filtered again with a 0.1 µm microfiber filter, 10 mL were taken and passed through the Fumonitest column. The column was subsequently flushed with 10 mL of phosphate/0.1% tween-20 buffer solution and a second flush was carried out by passing 10 mL of phosphate buffer solution through the column. Then, 1 mL of methanol (HPLC grade) was added to the column, which was collected and 1 mL of developer was added; it was homogenized and placed in the fluorometer (VICAM) and the reading was obtained 4 min later in ppm units (mg kg<sup>-1</sup>).

**Inoculi preparation**

**PRRS virus production:** African green monkey kidney MA-104 cells were seeded in 25 cm<sup>2</sup> Falcon dishes. Growth medium was added (10% EMEM<sup>®</sup> fetal bovine serum) and cells were subsequently incubated at 37°C for 48 h until an 80% confluence was achieved and were then inoculated with the reference strain of PRRSV (ATCC No. 2332) and adjusted to a concentration of 10<sup>4.3</sup> fluorescent foci TCID<sub>50</sub> mL<sup>-1</sup> (tissue culture infective dose) for piglet infection (Kim *et al.*, 1993).

**Fumonisin B<sub>1</sub>:** The toxin used was standard fumonisin B<sub>1</sub><sup>b</sup>, 5 and 10 mg presentation with a 98% purity. A stock was prepared at a concentration of 87 ppm in distilled water and was stored at 4°C. Administration of fumonisin B<sub>1</sub> to weanling pigs consisted of 12 ppm (mg kg<sup>-1</sup> of live weight) daily by oral route using a probe.

**Piglets:** About 25 newly weaned hybrid piglets of 29 days of age of both sexes with a weight of 5.8 kg from a farm free of PRRS were used.

**Experimental design:** Animals were randomly distributed into 5 groups. Each group was constituted by 5 pigs: Group A negative control. Group B intoxicated with 12 ppm of Fumonisin B<sub>1</sub> (FB<sub>1</sub>) starting from day 0 (start of the experiment).

Group C inoculated with the PRRS virus (PRRSV) (6 nebulizers with 6 mL each with a total of 36 mL for 30 min) on day 8. Group D: inoculated with PRRSV (6 nebulizers with 6 mL each with a total of 36 mL for 30 min) on day 0 and intoxicated with 12 ppm of FB<sub>1</sub> starting from day 0. Group E: Intoxicated with 12 ppm of FB<sub>1</sub> starting from day 0 and inoculated with PRRSV (6 nebulizers with 6 mL each with a total of 36 mL for 30 min) on day 8, said groups are shown in Table 1. Pigs were fed using food with a commercial composition of 16% of protein, 5.50% of fat and 5.50% of raw fibre in a serving of 250 g/pig/day. Water was administered *ad libitum* during the whole experimental period. The pigs had a 5 days adaptation period in the quarantine area of CENASA, consequently, the experimental work started when the piglets were 34 days of age and FB<sub>1</sub> was administered at doses of 12 ppm (mg kg<sup>-1</sup> p.v.) daily by oral route for 18 days to groups B, D and E. The PRRS virus was inoculated in group D only, at a dose of 36 mL (6 nebulizers with 6 mL each) for 30 min. with a concentration of 10<sup>4.3</sup> fluorescent foci TCID<sub>50</sub> mL<sup>-1</sup> (tissue culture infective dose). A nebulization chamber was used. Piglets were introduced into the nebulization chamber for a 30 min time interval, after which piglets were taken out of the nebulization chamber. Afterwards,

Table 1: Design and composition of the experimental groups

Groups	Treatments	Intoxication with FB <sub>1</sub> * -----	Challenge with PRRSV* -----	
		Day 0	Day 0	Day 8
A	Negative control	-	-	-
B	FB <sub>1</sub> control	+	-	-
C	PRRSV control	-	-	+D
	PRRSV <sub>1</sub>	+	+	-
E	FB <sub>1</sub>	+	-	+
	PRRSV			

FB<sub>1</sub> 12ppm; PRRSV 6 nebulizers with 6 mL each, with a total of 36 mL for 30 min

at 8 days following initiation of the experiment, groups C and E were inoculated with PRRSV in the same way as group D. All groups were individually placed in isolation units until the end of the experiment. During the experiment, the weight of the animals was recorded and their clinical condition was monitored. At the end of the experiment (18 days), all animals were slaughtered. Necropsy was performed and the observation of the macroscopic lesions present, as well as the collection of lung, liver and renal tissue samples for histopathologic evaluation were carried out.

**Temperature recording:** The body temperature of each piglet in all groups treated was measured every week by rectal route before management.

**Clinical evaluation:** Piglets were observed daily, considering any changes in their behavior and appearance, any respiratory problems, the consistency of feces, swollen appearance of eyelids and lacrimation, fluid at nostrils and appetite.

**Pathologic evaluation:** Piglets were slaughtered at the end of the experimental period. They were slaughtered according to NOM-033-ZOO-1995 standard. During necropsy, observations and recording of macroscopic lesions, as well as of the site form and size of the lesions were carried out according to the affected lobe. The determination of the extent of the pneumonic lesion was carried out based on the observation and recording of the dorsal and ventral view of the lungs. The percentage of lesion was calculated as indicated by Ciprian *et al.* (1988).

**Histological evaluation:** Lung, liver and kidney tissue samples were collected for microscopic examination and fixed in 10% neutral buffered formalin for 2-4 days. Samples were routinely processed and embedded in paraffin, sectioned at 4 µm and stained with Hematoxylin and Esosin (HE) (Harms *et al.*, 2001).

**RT-PCR test:** About 1 mL blood samples were collected directly from the jugular vein into EDTA-containing tubes

on days 0, 8, 16 to be processed by the nested RT-PCR technique in order to demonstrate the presence or absence of PRRSV nucleic acids.

**Evaluation of weekly weight gain:** The weight of all pigs in groups A-E was recorded in the morning during day 5 (acclimatization), day 0 (start of the experiment), 8 and 18 (end of the experiment).

**Statistical analysis:** In order to determine whether there was any statistical difference in body weight and lung lesion percentage in the different groups, a one-way Analysis Of Variance (ANOVA) was performed. The difference between measures was determined by the Tukey's test with a significance level of 95% using the Statgraphics Plus statistical program, version 5.0.

**RESULTS AND DISCUSSION**

**Evaluation of aflatoxin and fumonisin B<sub>1</sub> concentration in food:** In the evaluation of the aflatoxin and fumonisin B<sub>1</sub> concentration in the food used for consumption by pigs, the aflatoxin concentration was 3 ppb ( $\mu\text{g kg}^{-1}$ ) and the fumonisin B<sub>1</sub> concentration was 1 ppm ( $\text{mg kg}^{-1}$ ).

**Inoculi preparation:**

- PRRSV is the virus titer was standardized at a concentration of  $10^{4.3}$  fluorescent foci TCID<sub>50</sub> mL<sup>-1</sup>
- FB<sub>1</sub> the inoculum used was standardized at 12 ppm ( $\text{mg kg}^{-1}$ )

**Animal observation**

**Body weight evaluation:** The results are shown in Table 2, pigs in group B had a greater weight dispersion with values of Standard Deviation (SD) of up to 3.39 kg. On day 18, there was a greater dispersion in group D with a SD value of 4.35 kg. Although, the initial mean weight of pigs on day 5 was different, 4.17 for group C and 7.6 for group D. Table 3 shows the prediction equations where

control group A showed a 1.51 slope; groups D and E had negative slopes of -0.103 and -0.37, respectively. Group A showed a 29.6% weight gain; groups D and E had a 2.05 and 2.34% weight loss.

**Temperature recording:** The results obtained for the mean temperature of piglets are shown in Fig. 1. Pigs from Group A, negative control, showed a constant temperature of 39°C since day 7 until the end of the experiment; likewise, Group B remained within the normal temperature range. Pigs in Group C, which were inoculated with PRRSV and pigs in Groups D and E, which were also inoculated with the virus plus the toxin had hyperemia since day 14 until the end of the experiment.

**Clinical evaluation:** Piglets in group A showed no apparent clinical signs in the experimental period. Piglets in group B, intoxicated with FB<sub>1</sub> showed slight anorexia, depression, prostration and fluid stools. Piglets in group C, inoculated with PRRSV showed moderate anorexia, depression, swollen eyelids, fluid at nostrils, dyspnea, and rough hair. Piglets in group D, inoculated with PRRSV and FB<sub>1</sub> had moderate anorexia, depression, fluid at nostrils, sneezing and fluid stools. Piglets in group E, intoxicated with FB<sub>1</sub> and inoculated with PRRSV, showed moderate anorexia, depression, fluid at nostrils, sneezing and fluid stools.

**Pathologic evaluation:** At necropsy, observations were made of the macroscopic lung lesions of each pig. These lesions were reported as percentage of lung lesion, as shown in Fig. 2. The percentage of types of lung lesions in group B were red consolidation, 1.4%; group C which was inoculated with PRRSV only showed diffuse purple consolidation, 9.42%; group D showed diffuse purple consolidation, 5.41% and reddish consolidation, 1.63%; group E showed diffuse purple consolidation, 5.91% and

Table 2: Average body weights (mean +/- standard deviation) recorded during the experiment.

Treatment	Weight (kg)			
	Day 5	Day 0	Day 8	Day 18
Group A	6.3 +/- 0.57	6.93 +/- 0.60	8.0 +/- 1.01	1.0 +/- 1.0
Group B	6.25 +/- 2.06	7.5 +/- 2.38	7.25 +/- 3.39	7.17 +/- 2.61
Group C	4.17 +/- 1.25	4.67 +/- 1.61	4.4 +/- 1.23	5.7 +/- 3.29
Group D	7.6 +/- 0.55	7.4 +/- 0.42	7.18 +/- 1.12	7.33 +/- 4.35
Group E	6.7 +/- 1.30	6.4 +/- 1.19	6.08 +/- 1.39	6.35 +/- 2.91

Group A: Control; Group B: FB<sub>1</sub>; Group C: PRRSV; Group D: PRRSV-FB<sub>1</sub>; Group E: FB<sub>1</sub>-PRRSV

Table 3: Weight gain prediction equations, adjusted for linear behavior and weight gain in piglets receiving FB<sub>1</sub> and PRRSV

Statistical analysis	Group A	Group B	Group C	Group D	Group E
Prediction equation	y = 1.51, x + 4.26	y = 0.25, x + 6.41	y = 0.43, x + 3.65	y = -0.103, x + 7.63	y = -0.37, x + 6.72
R <sup>2</sup>	0.883	0.351	0.682	0.58	0.48
Mean weight gain	1.57	0.31	0.51	0.09	0.12
Percent of weight gain	29.6	15.7	6.38	- 2.05	- 2.34

Group A: Control; Group B: FB<sub>1</sub>; Group C: PRRSV; Group D: PRRSV-FB<sub>1</sub> and Group E: FB<sub>1</sub>-PRRSV

reddish consolidation, 3.50%. There were no apparent pathologic changes in the liver and kidney at necropsy in groups A-E.

**Histopathology evaluation:** Histopathologic results are shown in Table 4. Group A did not show any apparent changes. Group B showed slight interstitial pneumonia in the lung and only one pig showed severe hemorrhagic congestion and some edema. Polyploidy and fatty change in liver and proliferative glomerulitis in the kidney, as well as blind tubules with polyploidy and mononuclear infiltrate. Group C showed interstitial pneumonia, atelectasis and clear alveoli in the lungs. There were no changes in the liver and only one pig had an interstitial lesion in the kidney with mononuclear infiltrate and tubular lesion.

Groups D and E showed lesions in the lung due to moderate diffuse interstitial pneumonia and severe diffuse interstitial pneumonia, respectively and they showed the same lesions in the liver and kidney. The results of the histopathologic analysis show that group A had no apparent pathologic changes in the lung, as shown in Table 1.

In group D, piglets were treated with PRRSV and FB<sub>1</sub>. It should be emphasized that in this group, both pathogens were administered on day 0 at the start of the experiment. In this group, moderate diffuse interstitial pneumonia is shown in Fig. 3.

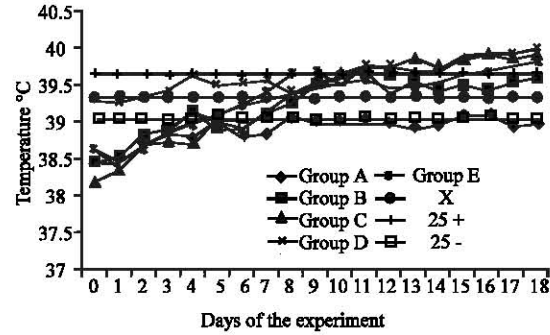


Fig. 1: Determination of body temperature in the different groups. Group A: Control; Group B: FB<sub>1</sub>; Group C: PRRSV; Group D: PRRSV-FB<sub>1</sub>; Group E: FB<sub>1</sub>-PRRSV

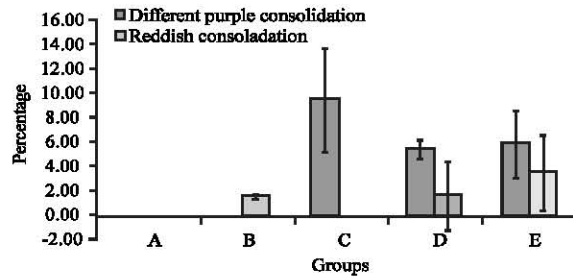


Fig. 2: Percentage of the different types of lung lesions. Group A: Control; Group B: FB<sub>1</sub>; Group C: PRRSV; Group D: PRRSV-FB<sub>1</sub>; Group E: FB<sub>1</sub>-PRRSV

Table 4: Histologic findings

Organs	Group A	Group B	Group C	Group D	Group E
<b>Lung</b>	Did not show any changes	Slight interstitial pneumonia. Congestion in one section and severe hemorrhagic congestion and some edema in another	Interstitial, pneumonia atelectasis, clear alveoli,scarce polymorphonuclear cells, negative BALT or scarce BALT activity	Moderate diffuse interstitial pneumonia, atelectasis and emphysema, hyperemia and slight hemorrhage with edema, clear alveoli with scarce activated macrophages, scarce polymorphonuclear cells,negative BALT or scarce BALT activity. One section showed exudative pneumonia with plenty of polymorphonuclear cells	Severe diffuse interstitial pneumonia, atelectasis and emphysema, hyperemia and slight hemorrhage, clear alveoli with scarce activated macrophages,scarce polymorphonuclear cells, negative BALT or scarce BALT activity
<b>Liver</b>	Did not show any changes	Polyploidy and fatty change	Did not show any changes	Polyploidy and binuclear cells	Polyploidy and binuclear cells
<b>Kidney</b>	Did not show any changes	Proliferative glomerulitis, nephrosis in reparative stage, blind tubules with polyploidy and mononuclear infiltrate, the lesion is apparently located in the proximal convoluted tubule.	Interstitial lesion with mononuclear infiltrate was present in only one bed, fibrosis and tubular lesion	Proliferative nephrosis in reparative stage, blind tubules with polyploidy and mononuclear infiltrate, the lesion is apparently located in the proximal convoluted tubule	Proliferative glomerulitis, nephrosis in reparative stage, blind tubules with polyploidy and mononuclear infiltrate, the lesion is apparently located in the proximal convoluted tubule.

Group A: Control; Group B: FB<sub>1</sub>; Group C: PRRSV; Group D: PRRSV-FB<sub>1</sub>; Group E: FB<sub>1</sub>-PRRSV

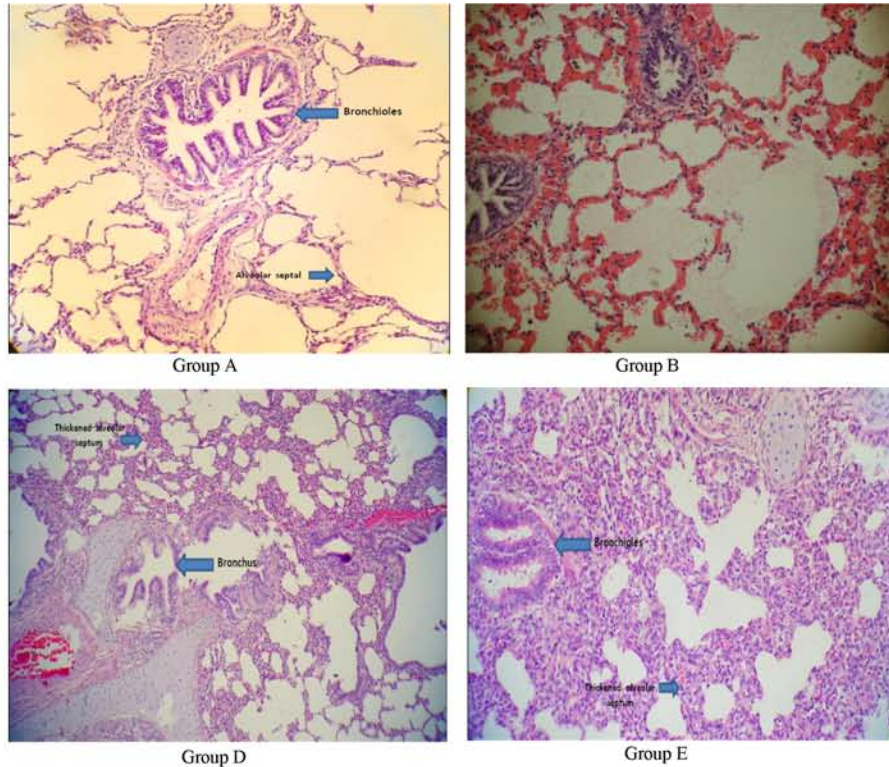


Fig. 3: Lung lesions. Group A. Lung of piglet from the control group, without apparent pathologic changes. 40X. Group B. Lung of piglet only intoxicated with 12 ppm of FB<sub>1</sub> by oral route for 18 days 20X. Group D. Lung of piglet inoculated with PRRSV and intoxicated with 12 ppm of FB<sub>1</sub> by oral route for 18 days, showing moderate diffuse interstitial pneumonia. 20X. Group E. Lung of piglet with 12 ppm of FB<sub>1</sub> by oral route for 18 days and inoculated with PRRSV 8 days after the start of the experiment, showing severe diffuse interstitial pneumonia

Group E in which FB<sub>1</sub> was administered first and was inoculated with PRRSV 8 days after the start of the experiment showed severe diffuse interstitial lung lesion (Fig. 3).

However, the dominant lesion in the lung was interstitial pneumonia, thickened alveolar septa with mononuclear infiltrate with vascular changes (hyperemia, slight hemorrhage) and clear alveoli without macrophages or with scarce macrophages. In general, there was no BALT activity. In group D, bacterial complication occurred in only one case with purulent exudative pneumonia.

The renal lesion was characterized by the presence of cells with basophilic cytoplasm in the tubules, suggestive of immature repair cells. These tubules showed polyploidy more markedly and most of the lesions observed had no lumen (aberrant, non-functional repair) and were located near the glomerulus and in the areas of straight interlobular tubules, hence, they probably correspond to the proximal convoluted tubule. In most cases, a

mononuclear cell infiltrate was observed in association with these damaged parts of the nephrons. At the glomerular level, swollen and very cellular glomeruli suggesting proliferative glomerulitis were seen; also, size-reduced, shrunk and atrophic glomeruli were present, although in lesser number. Some sections showed interstitial mononuclear infiltrates at the cortical level and rarely at medullary level. These lesions were more marked in groups B, D and E, however, they were not so frequent in group C. Hepatic polyploidy and the abundance of binuclear cells in the liver are suggestive of mycotoxicosis.

**RT-PCR test:** The results obtained to prove the presence of PRRSV by the nested RT-PCR molecular technique were negative for group A, negative control and group B, FB<sub>1</sub> only. Groups C, D and E, which were inoculated with PRRSV according to the experimental design had positive results. Mycotoxins cause great economic losses in farms due to the different diseases they produce in animals,

since they are present as contaminants in a great variety of cereals with which animal diets are prepared. Among mycotoxins, fumonisins have been associated with porcine pulmonary edema (Rene *et al.*, 1996).

The presence of these mycotoxins in grains is due to the fact that toxigenic fungi may develop both in the fields and in the warehouses (Moreno and Gutierrez, 1991). The concentrations of aflatoxins (3 ppb) and FB<sub>1</sub> (1 ppm) found in the food used in the experiment were very low and due to the short experimentation time, they did not affect experimental animals. In group A, negative control, which only received food, no macroscopic or microscopic lesions were found.

In this study, body temperature recordings showed that groups C, D and E inoculated with PRRSV in the incubation period developed an increase in temperature compared with control group A ( $p < 0.05$ ); however, group B inoculated with FB<sub>1</sub> only, did not have hyperemia. These results are consistent with a previously reported study, where pigs treated with low oral doses (equivalent to 5-8 ppm) of fumonisins contained in culture material for 20 days had temperatures of 39.5-39.8°C (Halloy *et al.*, 2005). On the other hand, in a study performed by Rossow *et al.* (1994) an increase in body temperature was seen in pigs of 1, 4 and 10 weeks of age inoculated with PRRSV. One of the characteristics in weanling pigs inoculated with PRRSV is the development of fever (Rosso, 1998). This is consistent with the results of this experiment.

The recording of the weight of the animals performed during this study showed an increase in weight in group A; as was to be expected in the prediction equation, there was a greater slope ( $m = 1.51$ ) indicating a greater rate of weight increase. In group C, a 0.43 slope was observed indicating a lower rate of weight gain; this value may be due to the weight dispersion occurred on the last day of the experiment. However, groups D and E showed a negative slope ( $m = -0.103$  and  $-0.37$ , respectively), indicating weight loss, which may be attributed to the effect of the virus plus the toxin, irrespectively of the order of inoculation.

The values for the R<sup>2</sup> coefficient were higher in group A, negative control (0.883) due to the lower weight variation during the study (standard deviation  $\pm 0.57$  to  $\pm 1.0$ ); the greater weight gain in average occurred in group A, with a value of 1.57 kg, which represented almost 30% of weight increase and the lower weight gain corresponded to groups D and E with a value of 2.05 and 2.34%, respectively; these results are consistent with those reported in the literature, since both PRRSV and FB<sub>1</sub> cause weight loss in the affected animals (Harrison *et al.*, 1990; Sierra *et al.*, 2000). In general, since there was no

weight gain in the groups treated with PRRSV and FB<sub>1</sub>, it was sufficient to observe the effect of these in swine. Maybe if the experimentation time had been longer, the weight gain parameter would have been more marked. However, in this study, a 5.75% weight gain could be observed in pigs in group B treated with FB<sub>1</sub> only, compared with control group A, which showed a 29.61% weight gain.

In other research, it has been reported that at doses of 1, 5, 10 and 20 and 40 ppm ( $\text{mg kg}^{-1}$  of food) of FB<sub>1</sub>, there is no effect on weight gain in pigs with initial weights of 8.5-10 kg (Zomborszky *et al.*, 2000, 2002).

Regarding the percentage of the different types of lesions, two different lesions occurred, diffuse purple consolidation and reddish consolidation ( $p < 0.05$ ). Pigs in group C, inoculated with PRRSV only as well as pigs in groups D and E, which were also infected with PRRSV showed diffuse purple consolidation lesions in pulmonary lobes compared with the pink color of lungs in control group A. These lesions shown are caused by PRRSV and are consistent with what has been reported by Halbur *et al.* (1996), Rossow (1998), Thacker *et al.* (1999) and Harms *et al.* (2001).

Reddish consolidation occurred where FB<sub>1</sub> was present (groups B, D and E). We believe that FB<sub>1</sub> may promote the development of reddish consolidation damage, which is very similar to that produced by bacterial agents. However, no bacterial agent was isolated, therefore, it is possible to consider that FB<sub>1</sub> may be capable of causing these lesions. In group D, it was observed that PRRSV replicated in the first stage causing lesions; consequently, the harmful effect of FB<sub>1</sub> was lower compared with group B. However, group E, in which FB<sub>1</sub> was administered on day 0 and was inoculated with PRRSV 8 days later showed a greater percentage of reddish consolidation effect compared with group D, achieving the same percentage as group B. Therefore, it may be assumed that the order of inoculation of the virus and the mycotoxin has an influence on the development of lung lesions.

In group C, moderate clinical signs of anorexia, depression, prostration, dyspnea, rough hair and swollen eyelids were observed. Pigs in groups D and E showed the same mild to moderate signs these signs are similar to what has been reported by Fraile (2004). The clinical presentation of PRRSV infection depends on the age of the infected pig usually, it may vary from one day to the next with increased anorexia over time (Goyal, 1993).

In a study performed by Rossow *et al.* (1994), it was observed that swollen eyelids or periorcular edema is a clinical sign present in young pigs exposed to PRRSV; they point out that edema may be caused by an increase

in local permeability or by an increase in efferent lymph pressure secondary to regional lymphadenopathy. On the other hand, microscopically, lung lesions found at necropsy in the groups in which pigs were inoculated with PRRSV (C, D and E) showed interstitial pneumonia, which is characteristic of this syndrome as reported by Ramírez *et al.* (2006). Lung lesions caused by PRRSV may vary quantitatively in severity but they are qualitatively similar (Rossow, 1998). Group B had slight interstitial pneumonia, characterized by a slight thickening of alveolar septa by macrophages; these observations are consistent with what has been described by Halloy *et al.* (2005). The most severe lesion was observed in group E, when animals consumed FB<sub>1</sub> and were subsequently inoculated with PRRSV, which may have been due to the fact that one of the alterations caused by fumonisins is immunosuppression, which may have contributed to the development of the virus causing a more severe lesion. Gimeno (2008) mentions the association of the consumption of food contaminated with more than 20 ppm of FB<sub>1</sub> with the appearance of PRRS disease in 8 groups of animals that had clinical signs of PRRSV disease.

Fumonisin cause hepatotoxicosis, pulmonary edema, heart problems, renal problems and immunosuppression (Gimeno, 2008) reduced food consumption, live weight gain and conversion index (Harrison *et al.*, 1990; Haschek *et al.*, 2001) in swine. It should be considered that FB<sub>1</sub> toxicity depends on the concentration, therefore, different degrees of contamination may cause alterations in swine. In this study with a low dose of 12 ppm of FB<sub>1</sub> and a short exposure time, little weight gain as well as mild to moderate macroscopic pathological changes in the lung were observed. However, histopathologic changes occurred in the lung, liver and kidney.

Zomborszky *et al.* (2000) have previously reported that weanling pigs fed with FB<sub>1</sub>-containing diets at concentrations of 10, 20 and 40 mg kg<sup>-1</sup> of food for 4 weeks had slight pulmonary edema at low doses, however, the animals that consumed food with high doses of 40 mg kg<sup>-1</sup> of FB<sub>1</sub> had severe pulmonary edema.

This is consistent with the results obtained under the experimental design proposed using a low dose of FB<sub>1</sub> (12 ppm) for 3 weeks (18 days) and only 2 pigs had slight pulmonary edema, therefore not all pigs in a group treated in the same way had the same degree of severity of the damage caused by FB<sub>1</sub> as could be observed. The time was short and the concentration was low because it was administered together with PRRSV, which has a harmful activity within a short time; animals started to deteriorate and die, therefore, all animals in all groups had to be slaughtered.

On the other hand, in this study, the lesions observed histologically in the kidney in groups B, D and E are suggestive of toxic processes, apparently in the proximal convoluted tubule, which may be associated with the presence of FB<sub>1</sub> and of which there are no previous reports in swine, only in rodents Ryley and Voss (2006). Therefore, it is suggested to carry out research focused on the evaluation of this effect. The changes observed may be more severe and extensive with higher doses and they could explain chronically the pulmonary edema that was not clearly observed in this research. Due to the results, it is suggested that glomerulonephritis and PRRSV may lead to hypoproteinemia and to the development of edema.

In group C, in which pigs were treated with PRRSV only, kidney lesions were also observed which was notable, since the presence of these alterations is not common in this pathology. Cooper *et al.* (1997) reported renal lesions associated with PRRSV infection that showed an inflammatory infiltrate observed in the renal cortex and medulla, as well as vascular and renal changes.

The results that determined the presence of PRRSV by nested RT-PCR were negative for group A, negative control and group B, FB<sub>1</sub> control. However, groups C, D and E had positive results because all of them were inoculated with PRRSV; these results are consistent with the experimental design proposed.

## CONCLUSION

The PRRS virus and fumonisins started to be studied by coincidence in the late 80s. Over time, it has been found that both agents affect the respiratory apparatus of swine; however, an association or interaction between the PRRS virus and any mycotoxin has not been documented in Mexico.

In this study, the most severe pulmonary lesion was observed when animals consumed fumonisin B<sub>1</sub> and were subsequently inoculated with PRRSV which may be associated to the fact that FB<sub>1</sub> caused immunodepression, favoring the development of PRRSV producing a more severe lesion.

It would also be appropriate to perform an investigation focused on the evaluation of the damage caused by FB<sub>1</sub> at renal level in swine, since this effect has only been reported in mice; on the other hand, the characteristic sign caused by this toxin is pulmonary edema, which was weakly observed in this investigation, since the dose administered was low and the exposure time was short for the development of the typical intoxication symptoms described in the literature for this toxin to occur.



## ACKNOWLEDGEMENTS

Researchers thank Rosalia Melendez for the statistical analysis, Juan Carlos del Rio for the histopathology studies, David Trujillo, Fernando Sotres and Draucin Celis for the technical research. This project was support for the grants: Cátedra: CON IN-39 and the PAPIIT IN209008. Sources and manufacturers are: (EMEM) Eagle's minimal essential medium. M0769. Sigma-Aldrich. Fumonisin B<sub>1</sub> (98% purity). F1147. Sigma-Aldrich.

## REFERENCES

- Bolger, M., R.D. Coker, M. Dinovi, D. Gaylor and M.O. Gelderblom *et al.*, 2001. Fumonisin. In safety evaluation of certain mycotoxins in food. World Health Org. Food Additives Ser., 47: 103-279.
- Christensen, C.M. and H.H. Kaufmann, 1969. Grain Storage the Role of Fungi in Quality Loss. University of Minnesota Press, Minneapolis.
- Ciprian, A., C. Pijoan, T. Cruz, J. Tortora, G. Colmenares, R. Lopez-Revilla and M. de la Garza, 1988. Mycoplasma hyopneumoniae increases the susceptibility of pigs to experimental *Pasteurella multocida* pneumonia. Can. J. Vet. Res., 52: 434-458.
- Cooper, V.L., R.A. Hesse and A.R. Doster, 1997. Renal lesions associated with experimental porcine reproductive and respiratory syndrome virus (PRRS) infection. J. Vet. Diagn. Invest., 9: 198-201.
- Correa, G.P., A.M. Coba, J. Weimersheimer, E.A.M. Anaya, F. Millian and J. Canto, 1994. Presence of antibodies against pig abortion and respiratory syndrome (PEARS) in imported and native pigs from several areas of Mexico. Proceedings of the 13th International Pig Veterinary Society Congress, (IPVSC'94), Bangkok, Thailand, pp: 521-521.
- Fraile, S.L., 2004. Neumonía virica producida por el virus del síndrome reproductivo. Lleida, [http://www.veterinaria.org/revistas/vetenfinf/vet\\_inf\\_inf\\_tripod/porcinos/PRRSrespiratorio.htm](http://www.veterinaria.org/revistas/vetenfinf/vet_inf_inf_tripod/porcinos/PRRSrespiratorio.htm).
- Gimeno, A., 2008. Las fumonisinas y sus efectos indeseables en la producción porcina. Albéitar: Publicación veterinaria independiente, No. 116, pp: 54-57, <http://dialnet.unirioja.es/servlet/articulo?codigo=2669558>.
- Goyal, S.M., 1993. Porcine reproductive and respiratory syndrome. J. Vet. Diagn. Invest., 5: 656-664.
- Gumprecht, L.A., V.R. Beasley, R.M. Weigel, H.M. Parker and M.E. Tumbleson *et al.*, 1998. Development of fumonisin-induced hepatotoxicity and pulmonary edema in orally dosed swine: Morphological and biochemical alterations. Toxicol. Pathol., 26: 777-788.
- Halbur, P.G., S.P. Prem, X.J. Meng, M.A. Lum, J.J. Andrews and J.A. Rathje, 1996. Comparative pathogenicity of nine US porcine reproductive and respiratory syndrome virus (PRRSV) isolates in a five-week-old cesarean-derived, colostrums-deprived pig model. J. Vet. Diagn. Invest., 8: 11-20.
- Halloy, D.J., P.G. Gustin, S. Bouhet and I.P. Oswald, 2005. Oral exposure to culture material extract containing fumonisins predisposes swine to the development of pneumonitis caused by *Pasteurella multocida* type A. Toxicology, 213: 34-44.
- Harms, P.A., S.D. Sorden, P.G. Halbur, S.R. Bolin, K.M. Lager, I. Morozov and P.S. Paul, 2001. Experimental reproduction of severe disease in CD/CD pigs concurrently infected with type 2 porcine circovirus and porcine reproductive and respiratory syndrome virus. Vet. Pathol., 38: 528-539.
- Harrison, L.R., B.M. Colvin, J.T. Greene, L.E. Newman and J.R. Jr. Cole, 1990. Pulmonary edema and hydrothorax in swine produced by fumonisin B<sub>1</sub>, a toxic metabolite of *Fusarium moniliforme*. J. Vet. Diagn. Invest., 2: 217-221.
- Haschek, W.M., L.A. Gumprecht, G. Smith, M.E. Tumbleson and P.D. Constable, 2001. Fumonisin toxicosis in swine: An overview of porcine pulmonary edema and current perspectives. Environ. Health Perspectives, 109: 251-257.
- Hill, H., 1990. Overview and history of mystery swine disease (swine infertility/respiratory syndrome). Proceeding of Mystery Swine Disease Committee Meeting, Oct. 6, Livestock Conservation Institute, Denver, Co, pp: 29-31.
- Kim, H.S., J. Kwang, I.J. Yoon, H.S. Joo and M.L. Frey, 1993. Enhanced replication of porcine reproductive and respiratory syndrome (PRRS) virus in a homogeneous subpopulation of MA-104 cell line. Arch. Virol., 133: 477-483.
- Marasas, W.F., 2001. Discovery and occurrence of the fumonisins: A historical perspective. Environ. Health Perspect., 109: 239-243.
- Moreno, M.E. and M.G. Gutierrez, 1991. La Biología de *Aspergillus flavus* Y La Producción de Aflatoxinas. Primera Edn., UNAM, Mexico, D.F., pp: 1-15.
- Ramírez, E., A. Ruiz, A. Islas, C. Lecocq, L. Carrasco and M. Quezada, 2006. Características hematológicas y patológicas de cerdos inoculados experimentalmente. Arch. Med. Vet., 38: 151-159.

- Rene, R.M., G.T. Miguel and R.P. Frank, 1996. Confirmación fisicoquímica de la fumonisina B1 en maíz y alimento para équidos que murieron leucoencefalomalacia. *Veterinaria Mexico*, 27: 111-113.
- Rheeder, J.P., W.F.O. Marasas, P.G. Thiel, E.W. Sydenham, G.S. Shepard and D.J. van Schalkwyk, 1992. *Fusarium moniliforme* and fumonisinas in corn in relation to human esophageal cancer in Transkei. *Phytopathology*, 82: 353-357.
- Rossow, K.D., 1998. Porcine, reproductive and respiratory syndrome. *Vet. Pathol.*, 35: 1-20.
- Rossow, K.D., E.M. Bautista, S.M. Goyal, T.W. Molitor and M.P. Murtaugh *et al.*, 1994. Experimental porcine reproductive and respiratory syndrome virus infection in one, four and 10 week old pigs. *J. Vet. Diag. Invest.*, 6: 3-12.
- Ryley, R.T. and K.A. Voss, 2006. Differential sensitivity of rat kidney and liver to fumonisina toxicity: Organ-specific differences in toxin accumulation and sphingoid base metabolism. *Toxicol. Sci.*, 92: 335-345.
- Sierra, N., R. Ramírez and D. Mota, 2000. Aislamiento del virus del PRRS en México: Estudio clínico, serológico y virológico. *Arch. Med. Vet.*, 32: 1-9.
- Thacker, E., P. Halbur, R. Ross, R. Thanawognuwech and B. Thacker, 1999. *Mycoplasma hyopneumoniae* potentiation of porcine reproductive and respiratory syndrome virus-induced pneumonia. *J. Clin. Microbiol.*, 37: 620-627.
- WHO, 2000. Environmental Health Criteria 219: Fumonisin B1. World Health Organization, Geneva, ISBN: 924 1572191, pp: 153.
- Zomborszky, K.M., F. Vetesi, I. Repa, F. Kovacs, A. Bata, P. Horn and A. Toth, 2000. Experiment to determine limits of tolerance for fumonisin B1 in weaned piglets. *J. Vet. Med. B Infect Dis. Vet. Public Health*, 47: 277-286.
- Zomborszky, K.M., F. Vetesi, P. Horn, I. Repa and F. Kovacs, 2002. Effects of prolonged exposure to low-dose fumonisin B1 in pigs. *J. Vet. Med. B Infect Dis. Vet. Public Health*, 49: 197-201.