

Survey of Sarcocystis Infection in Slaughtered Goats in Kerman Abattoir, Southeast of Iran

¹Mohammad Mirzaei Dehaghi, ^{2,3}Saeid Fathi and ^{2,3}Ehsan Norouzi Asl

¹Department of Pathobiology, ²Department of Veterinary Parasitology, School of Veterinary Medicine, Shahid Bahonar University of Kerman, Kerman, Iran

³Young Researchers Society, Shahid Bahonar University of Kerman, Kerman, Iran

Abstract: This study was conducted to determine the prevalence, distribution pattern and the *Sarcocystis* sp. involved in slaughtered goat in the Kerman, Iran by macroscopic and microscopic examination. The esophagus, heart, diaphragm and tongue were investigated. Of the 294 goats, 291 (98.97%) were diagnosed as positive for *Sarcocystis* species by the impression smear method and all 294 were positive by the digestion method. The prevalence of infection of the oesophagus was higher than that of other organs ($p < 0.05$). The infection rate increased with age, although this increase was not significant ($p > 0.05$). The infection rate was independent of sex being 12.58% in males and 14.62% in females ($p > 0.05$). There were no significant differences among the infection rates of the different organs. The sensitivity of the impression smear method compared with that of the digestion method in the diagnosis of infection was 92.85% in heart, 91.49% in oesophagus, 86.73% in tongue and 93.53% in diaphragm. The histopathological study showed a high frequency of microscopic Sarcocystis infection in goat slaughtered.

Key words: Prevalence, macroscopic examination, infection, sensitivity, impression, Sarcocystis infection

INTRODUCTION

Sarcocystis species are among the most common and widespread protozoan parasites of livestock and some species cause economic losses from clinical and subclinical disease and from condemnation and downgrading of carcasses (Huong *et al.*, 1997). They are obligate two host life cycle apicomplexan parasites based on a prey-predator relationship with a herbivorous or omnivorous as intermediate (prey) host and a carnivorous definitive (predator) host that frequently encyst in the skeletal and cardiac muscles of ruminants and to a lesser extent in the same musculature of equines, swine, birds, reptiles and humans (Dubey, 1976; Dubey *et al.*, 1989; Fayer, 2004). Ruminant intermediate hosts become infected by ingesting sporulated oocysts or sporocysts from the feces of infected carnivores (Dubey *et al.*, 1989). Goat breeding has an important role in many areas of the world not only for meat and milk production but also to make use of the natural pasture on mountains which is unsuitable for other species. There are three reported species of *Sarcocystis* in domestic goats: *Sarcocystis capracanis*, *Sarcocystis hircicanis* and *Sarcocystis capraefelis* (also referred to as *Sarcocystis moulei*). *S. capracanis* and *S. hircicanis* produce microscopic

sarcocysts while *S. capraefelis* produces macroscopic cysts. *S. capracanis* is the most pathogenic species in goats, causing fever, weakness, anorexia, weight loss, tremors, irritability, abortion and death (Dubey *et al.*, 1989).

Sarcocystosis has been reported in goat from various countries such as Iran (Shekarforoush *et al.*, 2005), India (Shastri, 1990; Singh *et al.*, 1992), Slovakia (Mala and Baranova, 1995), China (Wang *et al.*, 1996), Ethiopia (Woldemeskel and Gebreab, 1996), Nigeria (Kudi *et al.*, 1991), Sudan (Hussein and Warrag, 1985) and Jordan (Abo-Shahdad, 1996) by different methods (Weiland *et al.*, 1982). This research aimed to survey prevalence of Sarcocystis infection in slaughtered goats in Kerman, Iran.

MATERIALS AND METHODS

During April 2010 to October 2010, out of goat slaughtered for human consumption in Kerman abattoir, Kerman, Iran, 294 goats were investigated for the presence of macroscopic and microscopic Sarcocystis cysts in muscular tissues. The animals included 114 males and 180 females and their ages ranged from <1 to >3 years. The investigated goat were classified into groups

according to the age (<1, 1-2, 2-3, >3), sex and breed. Ages of the investigated cattle were assessed by visual inspection of teet.

Study area: The study was conducted in Kerman province, Southeast of Iran. Kerman is located at 30°17'13"N and 57°04'09"E southeast of Iran. The mean elevation of the city is about 1755 m above sea level. Kerman city has a hot and dry climate and the average annual rainfall is 135 mm. Because it is located close to the Kavir-e lut, Kerman has hot summers. Based on climate, soil and other geographical conditions, Kerman has different vegetation and agricultural type. Density of livestock animals in this area per square Kilometer is 33 livestock animals in 1 km² however, this density in cultivable lands is 505 livestock animals in 8 km².

Study design: This study was carried out on slaughtered goats in slaughter house of Kerman, Iran, during April to October 2010. The city of Kerman is located in South-East of Iran. Sarcocysts (macrocyts) were investigated in meat by direct observation.

The tongue, heart, oesophagus and diaphragm muscles, of each goat were inspected for the presence of macroscopic sarcocysts. Then the tongue, heart, oesophagus and approximately 100 g of the diaphragm were sampled for further study. In the laboratory, all tissue samples were sectioned to 2-3 mm slices and observed carefully for probable macroscopic cysts; any such cysts were removed. The sections were then examined by the impression smear method and the digestion method.

Impression smears: For the preparation of impression smears, the cut surface of each tissue was pressed on to a slide which was then fixed with absolute methanol and stained with Giemsa.

Peptic digestion: For the digestion method, 100 mL of digestion medium (2.5 g pepsin 700 FIP U g⁻¹ [Merck] and 10 mL hydrochloric acid in 1 L phosphate-buffered saline) was added to 50 g of each homogenised tissue sample and placed in a shaking waterbath at 37°C for 30 min. The suspension was then centrifuged for 10 min at 1500 g and a precipitate smear was prepared, fixed with absolute methanol stained with Giemsa and examined by light microscopy at ×400 and ×1000 for the presence of free bradyzoites (Shekarforoush *et al.*, 2005). The histopathological slid prepared of muscles.

The computer software, SPSS Version 9.0 for Windows (SPSS Inc., Chicago, IL, USA) was used for analysis. To compare relative frequency of infection

between different groups of sex, age and organs, χ^2 -test was used. Differences were considered significant when $p < 0.05$.

RESULTS AND DISCUSSION

The 61 of the 294 goats (20.74%) were diagnosed as being infected with macroscopic cysts. The prevalence of macroscopic cysts in different organs and age groups are shown in Table 1. The prevalence of infection of the oesophagus was higher than that of other organs ($p < 0.05$). The infection rate increased with age, although this increase was not significant ($p > 0.05$). The infection rate was independent of sex being 12.58% in males and 14.62% in females ($p > 0.05$). Of the 294 goats, 291 (98.97%) were diagnosed as positive for *Sarcocystis* species by the impression smear method and all 294 were positive by the digestion method (Table 2). There were no significant differences among the infection rates of the different organs. The sensitivity of the impression smear method compared with that of the digestion method in the diagnosis of infection was 92.85% in heart, 91.49% in oesophagus, 86.73% in tongue and 93.53% in diaphragm. The histopathological study showed a high frequency of microscopic *Sarcocystis* infection in goat slaughtered (Fig. 1).

Sarcocystis is worldwide in distribution. Parasites belonging to this genus have been reported from numerous mammals especially sheep, goat, cattle, buffaloes and pigs. They occur as elongated cylindrical bodies, sometimes large enough to be visible to the naked eye in striated muscle and sometimes in unstrained muscle. Several studies have been conducted in Iran to the prevalence of *Sarcocystis* sp. in ruminants, the rate of infection in sheep (6.67%) and goats (12.25%) in Khoram-Abad has been reported (Atashparvar *et al.*, 2001) and prevalence rate of 3.58% in Sheep and 0.13% in goats has been reported in Kerman (Radfar and Khosravi 2001). The prevalence of *Sarcocystis* sp. was 83.6% by gross and histopathological examinations in camels slaughtered in the Mashhad Slaughterhouse, Eastern Iran (Valinezhad *et al.*, 2008). In the present study, 61 of 294 goats (20.74%) were diagnosed as being infected by macroscopic *Sarcocystis* species cysts. In this study, the

Table 1: The prevalence of macroscopic sarcocysts in sheep slaughtered at Kerman slaughterhouse, Iran

Age (years)	No. of animals	Number (%) of infected organs			
		Tongue	Heart	Oesophagus	Diaphragm
<1	42	0.00	0	2 (4.760)	1 (2.38)
1-2	81	2 (2.46)	0	5 (6.170)	2 (2.46)
2-3	64	2 (3.12)	0	19 (29.680)	3 (4.68)
>3	107	5 (4.67)	0	35 (32.710)	7 (6.54)
Total	294	6 (3.06)	0	61 (20.740)	13 (4.42)

Table 2: The prevalence of microscopic sarcocysts in different organs and age groups of slaughtered goats in Kerman slaughterhouse, Iran

Age (years)	No. of animals	Number (%) of infected organs							
		Tongue		Heart		Oesophagus		Diaphragm	
		DM	ISM	DM	ISM	DM	ISM	DM	ISM
<1	42	42 (100.00)	41 (97.61)	40 (95.23)	31 (73.80)	42 (100)	42 (100.00)	42 (100)	38 (90.47)
1-2	81	77 (95.06)	70 (86.41)	74 (91.35)	71 (87.65)	81 (100)	77 (100.00)	81 (100)	79 (97.53)
2-3	64	64 (100.00)	56 (87.50)	64 (100.00)	64 (100.00)	64 (100)	53 (82.81)	61 (100)	64 (100.00)
>3	107	105 (98.13)	88 (82.24)	103 (96.26)	107 (100.00)	107 (100)	97 (90.65)	107 (100)	94 (87.85)
Total	294	290 (98.63)	255 (86.73)	281 (95.57)	273 (92.85)	294 (100)	269 (91.49)	294 (100)	275 (93.53)

DM: Digestion Method; ISM: Impression Smear Method

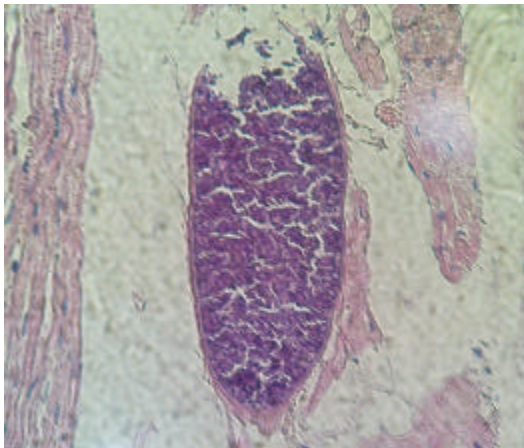


Fig. 1: A microscopic cyst of *Sarcocystis* sp. in the heart muscle of a goat. H and E×1000

prevalence of macroscopic cysts was lower than that of microscopic cysts and is shown in Table 1 and 2. This finding is in agreement with the previous findings of others researchers (Dubey *et al.*, 1989; Heydorn and Kirmsse, 1996; Shekarforoush *et al.*, 2005). Kudi *et al.* (1991) in Nigeria and Singh *et al.* (1992) in India reported no macroscopic cysts in examined goats but Abo-Shahdad (1996) in Jordan and Shekarforoush *et al.* (2005) in Iran reported macroscopic cysts in 11.7 and 16.6% of examined goats, respectively. The lower prevalence of macroscopic cysts in this study may be due to a lower frequency of *S. capraefelis* in the Kerman area, perhaps due to the lower probability of pastures being contaminated by cat faeces than dog faeces since dogs are used to shepherd sheep and goats. A lower diversity of definitive hosts of *S. capraefelis* compared with those of microscopic *Sarcocystis* species may also be involved. Most species of *Sarcocystis* transmissible by cats have been found less frequently than those transmissible via canids; this may be because cats are very poor producers of *Sarcocystis* species sporocysts or may be due to the longer time needed for sarcocysts to become infective (Dubey *et al.*, 1989; Shekarforoush *et al.*, 2005). The higher prevalence of macroscopic cysts in the oesophagus was in accordance with the previous findings by other researchers

(Heydorn and Kirmsse, 1996; Shekarforoush *et al.*, 2005). It seems that the oesophagus is the predilection site for *S. capraefelis* in goats. However, further investigation is needed to confirm this finding. Animals affected with sarcocystosis suffer from loss of weight, reduced milk production, anaemia, abortion and death in severe cases (Fard *et al.*, 2009). Results of this study showed a high frequency of microscopic *Sarcocystis* infection in goat slaughtered in the Kerman, Iran also no significant differences were observed between the infection rates of microscopic cysts in different organs. Several researchers such as Kudi *et al.* (1991) and Singh *et al.* (1992) reported the oesophagus to be the predilection site for microscopic cysts; this is not in accordance with the findings of the present study. Shekarforoush *et al.* (2005) also stated that there was no significant difference between the infection rates in different organs. Using the digestion method, it was found that all the goats were infected with sarcocysts. The higher prevalence of *Sarcocystis* species in the present study than in previous reports may be due to the diversity of definitive hosts of microscopic *Sarcocystis* species or to the higher prevalence of microscopic species and or to the higher probability of pasture contamination with dog faeces than cat faeces. Although, several researchers reported higher infection rates in older animals (Seneviratna *et al.*, 1975; Hussein and Warrag, 1985; Singh *et al.*, 1992; Abo-Shahdad, 1996; Shekarforoush *et al.*, 2005) in the present study the younger animals of the present study showed a lower prevalence rate of infection than the older ones but this difference was not significant. Furthermore, as reported by Shekarforoush *et al.* (2005) there was no significant difference between the prevalence of infection with microscopic cysts in males and females. This finding was in accordance with those reported by Haddadzadeh *et al.* (2004) and Ghorbanpoor *et al.* (2007) in water buffalo, Abo-Shahdad (1996) in sheep and goat, Shekarforoush *et al.* (2005) in goat and Valinezhad *et al.* (2008) in camel. Dubey *et al.* (1989) reported *S. capracanis* as being the most pathogenic species of *Sarcocystis* in goats. Despite this pathogenicity and the very high prevalence of microscopic *Sarcocystis* species in the Kerman area, no clinical findings associated with the parasite have been reported. The histopathological study showed a high

frequency of microscopic *Sarcocystis* infection in goat slaughtered. Among the three methods used in the present study, the digestion method was most able to diagnose microscopic sarcocysts. The impression smear and digestion methods are the only methods available to diagnose microscopic sarcocysts. Other methods such as isoenzyme electrophoresis and electron microscopy are needed to identify sarcocysts to species level.

CONCLUSION

Results of this study showed a very high frequency of *Sarcocystis* species infection in goat slaughtered in the Kerman, Iran. Further investigations to determine in better detail the biology, epidemiology, life cycle, ultrastructure and molecular differences of different species of *Sarcocystis* species in Iranian animals are highly recommended.

ACKNOWLEDGEMENTS

This study was funded by the Shahid Bahonar University of Kerman. Researchers also thank Mr. Aminzadeh and Mr. Ghaderpor for his technical support.

REFERENCES

- Abo-Shahdad, M.N., 1996. Age variation in the prevalence of sarcocystosis in sheep and goats from northern and central Jordan. *Preventive Vet. Med.*, 27: 135-140.
- Atashparvar, N., A. Soukhtezari and A.A. Asalani, 2001. Survey of *Sarcocystis* in sheep and goats in Khoram Abad. *Proceedings of the 3rd National Congress of Medical Parasitology (MP'01)*, Sari, Iran, pp: 251-251.
- Dubey, J.P., 1976. A review of *Sarcocystis* of domestic animals and of other coccidia of cats and dogs. *J. Am. Vet. Med. Assoc.*, 169: 1061-1078.
- Dubey, J.P., C.A. Speer and R. Fayer, 1989. *Sarcocystosis in Animals and Man*. 1st Edn., CRC Press, Boca Raton, Florida, pp: 1-145.
- Fard, S.R.N., M. Asghari and F. Nouri, 2009. Survey of *Sarcocystis* infection in slaughtered cattle in Kerman, Iran. *Trop. Anim. Health. Prod.*, 41: 1633-1636.
- Fayer, R., 2004. *Sarcocystis* spp. in human infections. *Clin. Microbiol. Rev.*, 17: 894-902.
- Ghorbanpoor, M., H. Hamidinejat, L. Nabavi, G.H. Khadjeh and M.R. Jalali, 2007. Evaluation of an ELISA for the diagnosis of sarcocystosis in water buffaloes. *Bull. Vet. Inst. Pulawy*, 51: 229-231.
- Haddadzadeh, H.R., M.R. Jalali, P. Khazraenia, M. Taheri and A. Rasekh, 2004. Serological study on sarcocystosis in slaughtered buffaloes (*Bubalus bubalis*) using IFAT compare with meat inspection finding in Ahvaz abattoir. *J. Faculty Vet. Med. Univ. Tehran*, 59: 183-184.
- Heydorn, A.O. and P. Kirmsse, 1996. Isolation and experimental transmission of *Sarcocystis moulei* Neveu-Lemaire, 1912. *Berl. Munch. Tierarztl. Wochenschr.*, 109: 440-445.
- Huong, L.T., J.P. Dubey and A. Uggla, 1997. Redescription of *Sarcocystis levinei* Dissanaiké and Kan, 1978 (Protozoa: Sarcocystidae) of the water buffalo (*Bubalus bubalis*). *J. Parasitol.*, 83: 1148-1151.
- Hussein, H.S. and M. Warrag, 1985. Prevalence of *Sarcocystis* in food animals in the Sudan. *Trop. Anim. Health Prod.*, 17: 100-101.
- Kudi, A.C., A.O. Aganga, V.C. Ogbogu and J.U. Umoh, 1991. Prevalence of *Sarcocystis* species in sheep and goats in northern Nigeria. *Rev. Elev. Med. Vet. Pays. Trop.*, 44: 59-60.
- Mala, P. and M. Baranova, 1995. Diagnosis of *Sarcocystis* infection in slaughter animals at veterinary meat inspection. *Vet. Med.*, 40: 97-100.
- Radfar, M.H. and A. Khosravi, 2001. Survey of *Sarcocystis* in sheep and goats in Kerman. *Proceedings of the 3rd National Congress of Medical Parasitology, (MP'01)*, Sari, Iran, pp: 287-287.
- Seneviratna, P., A.G. Edward and D.L. DeGiusti, 1975. Frequency of *Sarcocystis* spp. in Detroit, metropolitan area, Michigan. *Am. J. Vet. Res.*, 36: 337-339.
- Shastri, U.V., 1990. *Sarcocystis* infection in goats in Maharashtra. *Indian Vet. J.*, 67: 70-71.
- Shekarforoush, S.S., S.M. Razavi, S.A. Dehghan and K. Sarihi, 2005. Prevalence of *Sarcocystis* species in slaughtered goats in Shiraz, Iran. *Vet. Rec.*, 156: 418-420.
- Singh, L., P.M. Raisinghani, K.M.L. Pathak, D. Kumar and G.S. Manohar *et al.*, 1992. Epidemiology of *Sarcocystis capracanis* in goats at Bikaner, Rajasthan, India. *Indian J. Anim. Sci.*, 62: 1044-1045.
- Valinezhad, A., A. Oryan and N. Ahmadi, 2008. *Sarcocystis* and its complications in camels (*Camelus dromedaries*) of eastern provinces of Iran. *Korean J. Parasitol.*, 46: 229-234.
- Wang, M., H. Liu and W.F. Jia, 1996. A survey of *Sarcocystis* infection of animal carcasses in Beijing. *Chinese J. Vet. Med.*, 22: 17-19.
- Weiland, G., I. Reiter and J. Boch, 1982. Possibilities and limits of Serodiagnosis in sarcosporidia infections. *Berl. Munch. Tierarztl. Wochenschr.*, 95: 387-392.
- Woldemeskel, M. and F. Gebreab, 1996. Prevalence of sarcocysts in livestock of northwest Ethiopia. *J. Vet. Med. Ser. B*, 43: 55-58.