

## Histopathological Effects of Mid-Urethral Tapes: An Animal Study on Female Rats

<sup>1,2</sup>Sakineh Hajebrahimi, <sup>2,3</sup>Leila Roshanghar, <sup>4</sup>Darioush Mohajery,

<sup>1</sup>Mehdi Zeynali and <sup>2</sup>Mehran Mesgari

<sup>1</sup>Department of Urology, <sup>2</sup>Drug Applied Research Center,

<sup>3</sup>Department of Histology, <sup>4</sup>Department of Pathobiology,

Tabriz University of Medical Sciences, Tabriz, Iran

**Abstract:** The midurethral tapes available in market to be used for incontinence therapy need further to be studied on animal models using both photomicroscope and electron microscopy facilities. The aim of this study was to assess biomechanical and histopathologic effects of TOT, TVT and IVS and Mersilene tapes implanted in rat tissue. Thirty female Wistar rats, aged 10 weeks with an average weight of 220 g were randomly allocated into five groups (A-E) of 6 animals each. Groups A-E were assigned to receive one of the four brands of tapes designed to be used in anti-incontinence surgery and the last group received a sham surgery as control. After 6 and 12 weeks, they were assessed biomechanically and histologically using both photo microscopy and electron microscopy techniques. The rat tissue reacted differently to the types of midurethral tapes. Overall, regarding tissue compatibility, TOT and IVS are slightly better than TVT. Mersilene as a positive control showed lower compatibility and stability. TOT had base stability higher than other types.

**Key words:** Midurethral tapes, incontinence therapy, Wistar rats, compatibility, stability

---

### INTRODUCTION

Urinary incontinence among women is an important health problem leaving a significant impact on the quality of life of the affected patients as well as an economic burden on health care systems (Housley *et al.*, 2010). The use of sub-urethral slings in treating urinary incontinence dates back to 1900s (Rodriguez *et al.*, 2001). However, tension-free mid urethral tapes are substantially new in medicine (Ulmsten *et al.*, 1994; Ulmsten and Petros, 1995). Different tapes have been produced, used and investigated during the recent decade. Two groups of studies can be retrieved in literature reading these products; efficacy studies mainly being human studies and mechanistic-histological studies mainly being animal studies.

Regardless of study populations, most of these have been short-mid-term studies with very few of them conducted for a long-term evaluation. Other features of interest in the available literature is that most of the major studies have been initiated by industry rather than being researcher-initiated. Also most of the animal histological studies have solely used photo-microscopic methods. The aim of this study was to assess biomechanical and histopathologic effects of some midurethral tapes on Rat model using photo-electron-microscopy.

### MATERIALS AND METHODS

Thirty female Wistar rats, aged 10 weeks with an average weight of 220 g were randomly allocated into five groups (A-E) of 6 animals each. Groups A-E were assigned to receive one of the four brands of tapes designed to be used in anti-incontinence surgery as follows:

- A: Intravaginal Slingplasty (IVS)
- B: Transobturator vaginal Tape (TOT)
- C: Tension-free Vaginal Tape (TVT)
- D: Mersilene
- E: Control (Sham), without mesh placement

The tapes in a length of 1 cm were implanted sub-dermally in paravertebral area on the studied rats. Experimental groups were euthanized and tissue specimens collected from tape implanted regions of skin as well as the intact samples from control group were fixed in 10% buffered formalin, embedded in paraffin and 5 µm thick microscopic sections were prepared through hematoxylin-eosin staining method.

Inflammatory infiltrate and fibrosis assessed and subjectively graded as low, moderate and extensive. In addition, collagen filling of the tapes was subjectively

classified as good (>50%), partial (25-50) or minimal (<25%). For each group, a score for biocompatibility potential was developed, consisting of the summation of grades (1-3), respectively assigned to inflammatory infiltrate, fibrosis and collagen filling. With an ocular micrometer, the size of the tissue reaction around the tapes was evaluated. The average measurement for each tape was calculated. This parameter was also assigned a grade from 1-3. A thickness of 0.05-0.1 mm was considered as grade 1, 0.11-0.2 as grade 2 and above 0.21 mm as grade 3. Grades were inversely proportional to the severity of inflammatory infiltrate and fibrosis as well as thickness of tissue reaction and directly proportional to collagen filling.

Tapes shrinkage was assessed by measuring the average width of the tapes implanted into the rat skin using an ocular micrometer and calculating the percent of differences between the data's obtained and primary size of the tapes investigated.

**Electron microscopy:** Small pieces of 2-3 mm size were immersed in the Karnovsky's fixative (0.1 M paraformaldehyde and glutaraldehyde solution in cacodylate buffer, pH 7.3) for 4 h and thereafter washed with 0.1 M cacodylate buffer (pH 7.3). The samples were post fixed for 3 h at 4°C in 1% osmium tetroxide prepared in 0.1 M cacodylate buffer. The specimens were washed with distilled water and left in 1% aqueous uranyl acetate overnight. Subsequently, dehydration was carried out in ascending grades of alcohol, acetone and in pure acetone. Following dehydration, the specimens were embedded in Epon 812 at room temperature. Sections were cut on an LKB-Ultramicrotome with a glass knife. Thereafter, sections were mounted on 300 mesh copper grids, stained with 1% uranyl acetate and lead citrate and examined with a Phillips (FEI Tecnai 12 twin) Transmission Electron Microscope. Study was approved by the research committee in Tabriz University drug research center.

**RESULTS AND DISCUSSION**

**Biomechanical results:** Tissue reaction tissue thicknesses are shown in Table 1 and scores for biocompatibility potential of different tapes 6 weeks post implantation into the rat skin (Table 2). Width of the tapes implanted into rat skin after 6 months were 4.5, 4.7, 3.2 and 6.1 mm, respectively for tapes A-D. The figures were 3.9, 4.3, 3.2 and 4.9 mm after 12 weeks. Table 3 shows the shrinkage rate of the tapes implanted into rat skin.

Table 1: Tissue reaction thickness around the tapes implanted into rat skin (mm)

Weeks	A	B	C	D
6 weeks	0.2878	0.2675	0.2980	0.2852
12 weeks	0.1071	0.1315	0.2875	0.2380

Table 2: Scores for biocompatibility potential of different tapes 6-12 weeks post implantation into rat skin

Parameters	Weeks							
	A		B		C		D	
	6	12	6	12	6	12	6	12
Inflammatory infiltrate	1	2	2	2	2	2	1	2
Fibrosis	3	3	1	2	1	1	2	2
Tissue reaction thickness	1	2	1	2	1	1	1	1
Collagen filling	1	1	2	2	2	3	1	1
Biocompatibility potential	6	8	6	8	6	7	5	6

Table 3: Shrinkage rate of the tapes implanted into rat skin

Weeks	A	B	C	D
6 weeks	54/77	52.90	67/94	38/74
12 weeks	60.44	56.59	68/42	50.18

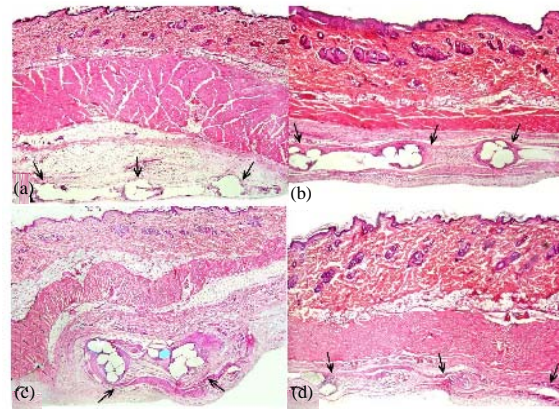


Fig. 1: Microscopic view of the tapes 6 weeks post implantation into rat skin. Photomicrograph showing the filaments tracks of the tapes investigated. Bundles of collagen fibers surrounded each filament as well as forming a contiguous layer (arrows) along the tapes border (hematoxylin and eosin ×40)

**Photomicroscope results:** The histological changes are shown in Fig. 1-5.

**Electron microscopy results:** Electron microscopy results of tissue reaction to TOT, IVS and TVT tapes are shown in Fig. 6 (6 weeks: Delicate Collagen fibers (C) are found between, Fibroblasts (F) and Tape filaments (T). Tape filament degradation (Td) is prominent. Collagen filling is minimal. Note the distended endoplasmic reticulum (er), secondary lysosomes (l) as well as clumping of dense bodies (db) and subcellular mitochondrial localization of

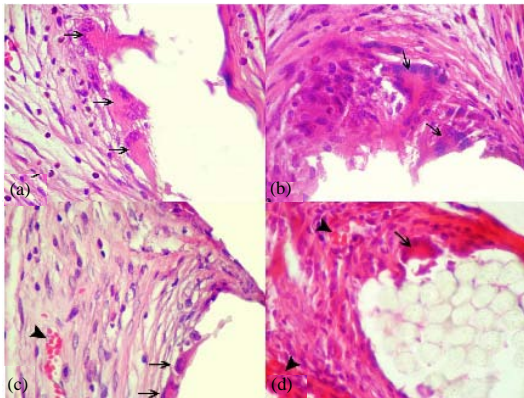


Fig. 2: Histologic appearance of tissue reaction around the tapes in experimental groups at 6 weeks post implantation into rat skin. (a) Extensive inflammatory infiltrate and relatively large foreign body giant cells (arrows). Minimal fibrosis and least amount of collagen filling. (b) Moderate inflammatory infiltrate and giant cells (arrows). Extensive amount of fibrosis and partial collagen filling. (c) Moderate inflammatory infiltrate and giant cells (arrows) along with small areas of hemorrhages (arrowhead). Severe fibrosis and moderate collagen filling (arrows). (d) Severe inflammatory infiltrate and giant cells (arrow) along with discrete foci of hemorrhages (arrowheads). Moderate fibrosis and low collagen filling (hematoxylin and eosin  $\times 400$ )

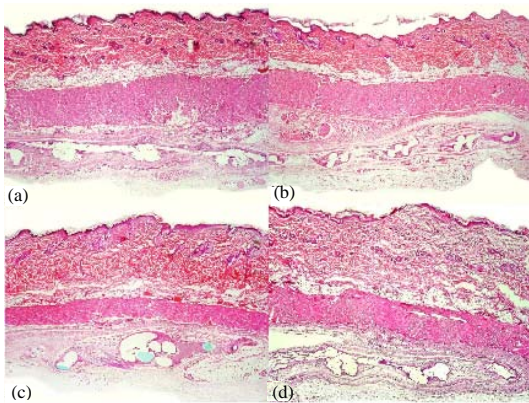


Fig. 3: Light photomicrographs of the tapes 12 weeks post implantation into rat skin. Shrinkage of C tape is prominent. Small remaining fragments of the filaments (arrows) are still detectable in C and D tapes (hematoxylin and eosin  $\times 40$ )

electron dense materials ( $\blacktriangleright$ ) in a Macrophage (Mac). Shriveling of neighboring fibroblast with pyknotic electron dense nucleus (pn) is prominent. A collapsed cell

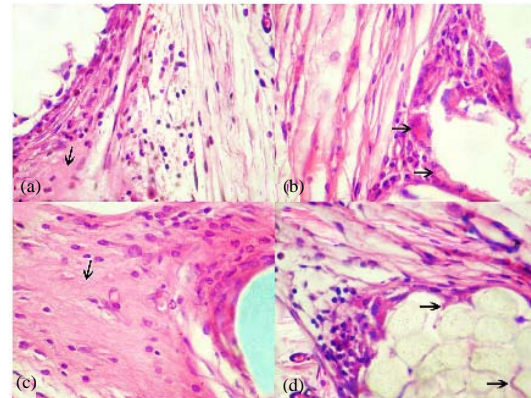


Fig. 4: Histologic appearance of tissue reaction around the tapes in experimental groups at 12 weeks post implantation into rat skin. (a) Moderate inflammatory infiltrate. Minimal fibrosis and low collagen filling (arrow). (b) Moderate inflammatory infiltrate and giant cells (arrows). Moderate amount of fibrosis and collagen filling. Foreign body giant cells adjacent to the filament are smaller than in the case of at 6 weeks post implantation. (c) Moderate inflammatory infiltrate. Severe fibrosis and good collagen filling. Bundles of collagen fibers surrounding filament appears to be more densely packed (arrow). (d) Moderate amount of inflammatory infiltrate. Moderate fibrosis and low collagen filling. Collagen fibers (arrows) penetrating between the filaments (hematoxylin and eosin  $\times 400$ )

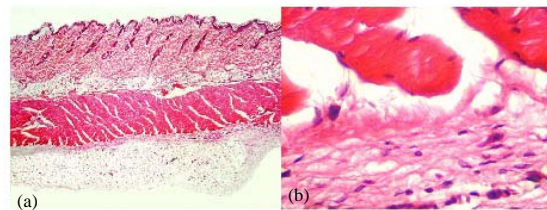


Fig. 5: Normal skin structure in control group with low (a) and higher (b) magnifications. Well presented muscle architecture, fat tissue, collagen bundles and fibroblasts. There is slightly inflammatory cell infiltration (hematoxylin and eosin  $\times 40$  and  $\times 400$ )

with shrinkaged nucleus (sn) and shrunk cytosol is considered in the illustration. Nuclear invagination (ni) is seen in a cell. There is a close contact ( $\rightarrow$ ) between tape particles and a fibroblast. Note well preserved compact fascicles (cf) of closely aligned myocytes (Uranyl acetate, Lead citrate). 12 weeks: Numerous fibroblasts (F) are seen in amorphous ground substances with wide intercellular

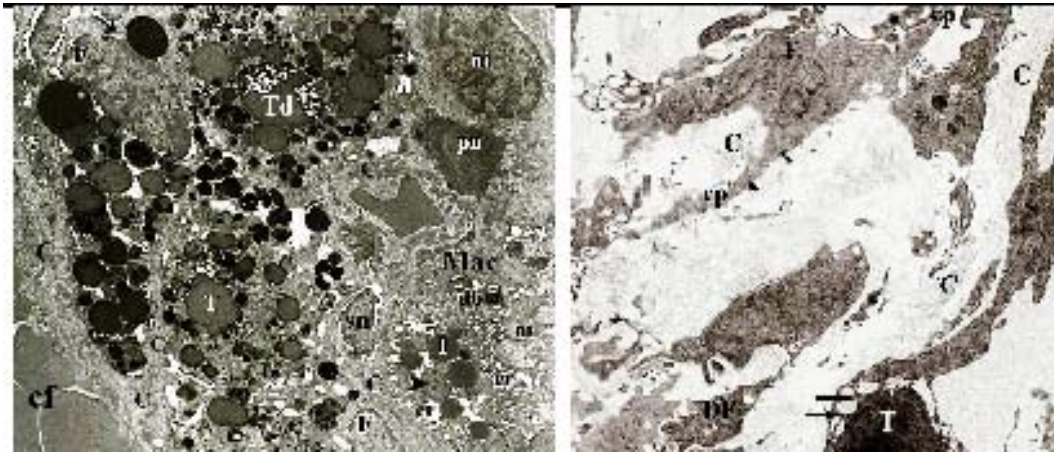


Fig. 6: Electron microscopy pictures for TOT tape (group A) after 6 weeks (a) and 12 weeks (b)

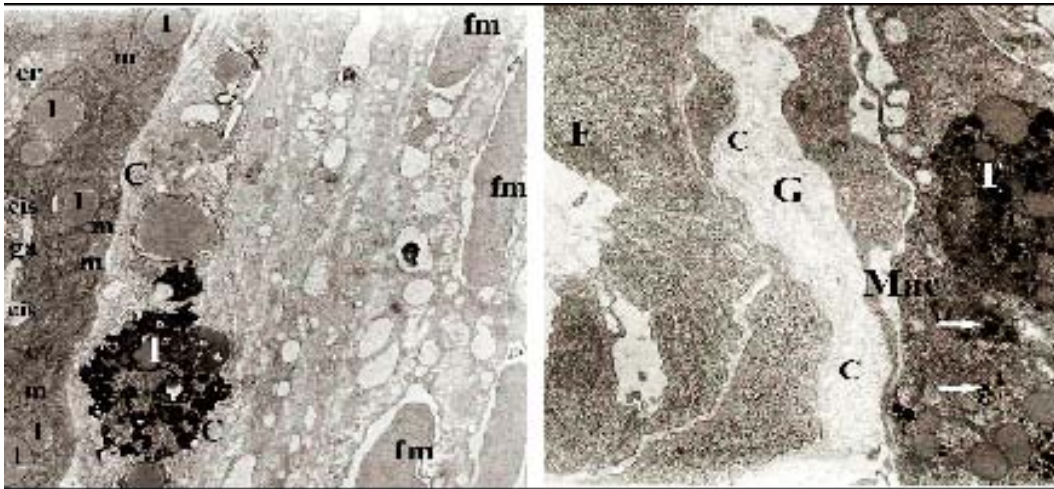


Fig. 7: Electron microscopy pictures for IVS tape (group B) after 6 weeks (a) and 12 weeks (b)

spaces. Some of these cells are collapsed and seems to be Degenerated (DF). Ground substance encompasses the cellular processes (cp) of fibroblasts and delicate Collagen fibers (C). Fibrosis and collagen filling are minimal. A portion of Tape particle (T) is seen in lower part of the electron micrograph. There are protrusion abutments (→) among the tape material and cellular processes (Uranyl acetate, Lead citrate).

In the Fig. 7 electron microscopy pictures for IVS tape (group B) after 6 weeks (a) and 12 weeks (b) (6 months: electron micrograph shows part of a cell (probably a macrophage), possessing abundant mitochondria (m), numerous lipid droplets (l), endoplasmic reticulum and golgi apparatus (ga) with distended cisternae (cis), adjacent to the tape materials (T). Collagen (C) fibers are seen in ground substances of areolar soft connective tissue between the cell and tape materials. Collagen filling is partial. Note fascicles of myocytes (fm) separated by

abundant edematous interstitium (Uranyl acetate, Lead citrate). 12 weeks: electron micrograph shows part of the Fibroblast (F) with its cellular processes. The spaces between the cells and their processes are filled with amorphous ground substance (G). Tape material (T) has been trapped by infiltrated Macrophage (Mac). Collagen (C) filling is moderate.

Electron micrograph illustrating residual tape particles appears to be partially absorbed (→) by this cell (Uranyl acetate, Lead citrate).

In Fig. 8 electron microscopy pictures for TVT tape (group B) after 6 weeks (a) and 12 weeks (b) (6 weeks: the interstitium is mostly comprised of collagen (C) fibers with its pine-needle appearance. Large amount of collagen fibers are mostly cross-sectioned (→). Elastin (E) is seen as small aggregates of dense amorphous material. Tape particle (T) is partially enveloped by a Fibroblast (F) (Uranyl acetate, Lead citrate). 12 weeks: excessive

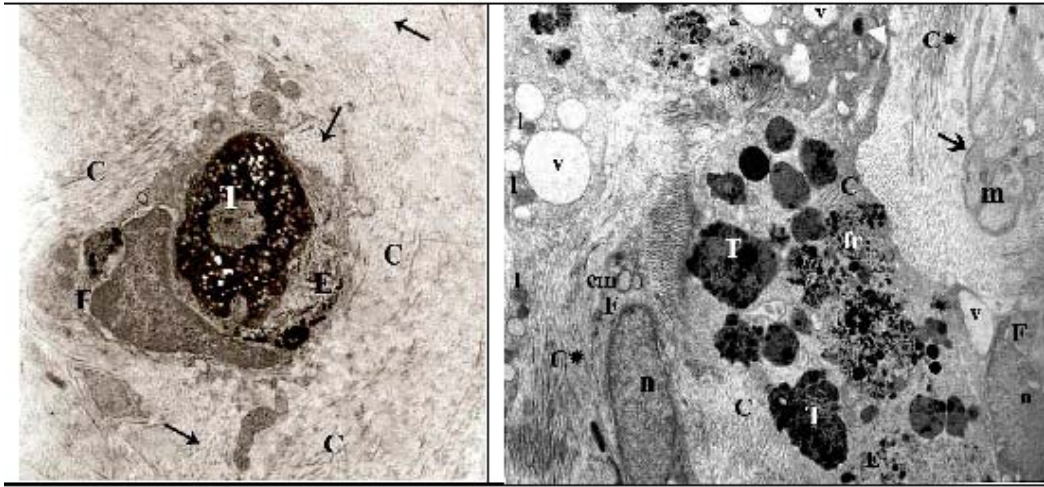


Fig. 8: Electron microscopy pictures for TVT tape (group B) after 6 weeks (a) and 12 weeks (b)

collagen (C) is observed between tape particles (T). Bundles of collagen also forming a contiguous layer (C\*) along the tapes border. Collagen filling is good. Features include tape lysis and fragmentation (fr), cytoplasmic vacuolation (v) and lipid droplets (l) in neighboring cells. Note the nuclei (n) of fibroblasts (F) and numerous empty mitochondria (em) consistent with fixation artifact. Part of a degenerative fibroblast like cell (→) is seen to be collapsed containing a large number of mitochondria (m) with subcellular mitochondrial localization of residues. These mitochondria have lost their cristae. Electron micrograph illustrating a residual tape particles appears to be partially absorbed by adjacent cell (▴) (Uranyl acetate, Lead citrate). Control group didn't show differences in outcome measures.

Animal studies are the cornerstone of future clinical trial studies in human. Also animal studies are of value for detailed assessments of drugs and interventions even when they are started to be used for human. Since, the time midurethral slings have been introduced into the field of urological surgery, the material and structure of slings has been of concern for the researchers.

In the study TVT showed the highest compatibility compared to IVS or TOT and both in photomicroscopy and electron microscopy collagen bundles orderly surrounded the tapes. This can be a clue for its stability and effect in treatment of incontinence. However, higher degree of fibrosis in this brand may explain the findings regarding its slightly lower tissue compatibility after 12 weeks compared to TVS and TOT. Mersilene used as a positive control showed lower histo-compatibility compared to TVT, TOT and IVS that could be explained by scarce existence of collagen around the tape. Mersilene was structurally quite different from the other three types.

Fibroblasts with lysozymes and apoptotic bodies were abundant in this group. Regarding the other three types, collagen aggregation and fibrosis after 12 weeks were little in group A and moderate in group B while in group C fair amount of collagen aggregation and substantially sever fibrosis was observed. A previous study comparing SIS (Small Intestinal Submucosal) and TVT tapes implanted in bladder tissue found fibrosis only among few in TVT group. Rechberger *et al.* (2003) compared multi and mono-filament tapes and found that propylene multi-filament tapes result in weaker tissue reaction and in this group collagen bundles are more dense and thicker around the tape.

In a previous study TVT and IVS were compared after 42 days of implanting them in the rectus fascia of 14 Wistar female rats. The researchers observed less densely packed bundles of collagen fibers and a slightly more intense inflammatory reaction for TVT compared with IVS mesh (Bogusiewicz *et al.*, 2006). Another study assessing urinary bladder histopathology induced by TVT and IVS finding that Inflammation was more intense in the IVS group as compared to the TVT (Atis *et al.*, 2009). TVT stiffness was found in another study to be significantly lower than that of IVS and other types investigated (Bazi *et al.*, 2007). In the study TOT stiffness was higher than other types. Other than the aforementioned studies on rats, one rabbit study didn't detect a difference between TVT and IVS but it seems that the short term evaluation period of one month can explain their finding rather than the animal type (Yildirim *et al.*, 2005). This explanation can also be inferred from the findings and previous studies.

Although, most studies in this regard are animal studies but few human studies have also tried to address the research question. In one study, biopsies from the paraurethral connective tissue were obtained

intraoperatively from 16 women with stress urinary incontinence who were operated on with the TVT procedure, 6 with mersilene as the sling material and 10 with prolene. Substantial inflammatory reaction with increased collagen extractability by pepsin was identified in patients where mersilene was used as the sling material.

### CONCLUSION

It is concluded that mersilene gives rise to a significant foreign-body reaction in the paraurethral connective tissue after surgery (Falconer *et al.*, 2001). Another human study although, not providing histological information but has found TVT to be preferable over suprapubic urethral support sling regarding efficacy and side effects (Lord *et al.*, 2006).

Overall it may be concluded that regarding tissue compatibility, TOT and IVS are slightly better than TVT. Mersilene as a positive control showed lower compatibility and stability. TOT had base stability higher than other types.

### REFERENCES

- Atis, G., S. Arisan, A. Ozagari, T. Caskurlu, A. Dalkilinc and E. Ergenekon, 2009. Tissue reaction of the rat urinary bladder to synthetic mesh materials. *Sci. World J.*, 9: 1046-1051.
- Bazi, T.M., R.F. Hamade, I.A.H. Hussein, K.A. Nader and A. Jurjus, 2007. Polypropylene midurethral tapes do not have similar biologic and biomechanical performance in the rat. *Eur.Urol.*, 51: 1364-1375.
- Bogusiewicz, M., A. Wrobel, K. Jankiewicz, A. Adamiak, P. Skorupski, J. Tomaszewski and T. Rechberger, 2006. Collagen deposition around polypropylene tapes implanted in the rectus fascia of female rats. *Eur. J. Obstet. Gynecol. Reprod. Biol.*, 124: 106-109.
- Falconer, C., M. Soderberg, B. Blomgren and U. Ulmsten, 2001. Influence of different sling materials on connective tissue metabolism in stress urinary incontinent women. *Int. Urogynecol. J.*, 12: S19-S23.
- Housley, S.L., C. Harding and R. Pickard, 2010. Urodynamic assessment of urinary incontinence. *Indian J. Urol.*, 26: 215-220.
- Lord, H.E., J.D. Taylor, J.C. Finn, N. Tsokos and J.T. Jeffery *et al.*, 2006. A randomized controlled equivalence trial of short-term complications and efficacy of tension-free vaginal tape and suprapubic urethral support sling for treating stress incontinence. *BJU Int.*, 98: 367-376.
- Rechberger, T., A. Wrobel, A. Adamiak, D. Skomra and E. Korobowicz *et al.*, 2003. Tissue reaction to polypropylene mono-or multi-filament tapes used in surgical techniques of stress urinary incontinence treatment. *Ginekol. Pol.*, 74: 1008-1013.
- Rodriguez, L.V., D.S. Blander and S. Raz, 2001. New millennium, new slings. *Curr. Urol. Rep.*, 2: 399-406.
- Ulmsten, U. and P. Petros, 1995. Intravaginal slingplasty (IVS): An ambulatory surgical procedure for treatment of female urinary incontinence. *Scand. J. Urol. Nephrol.*, 29: 75-82.
- Ulmsten, U., P. Johnson and P. Petros, 1994. Intravaginal slingplasty. *Zentralbl. Gynakol.*, 116: 398-404.
- Yildirim, A., E.K. Basok, T. Gulpinar, C. Gurbuz, E. Zemheri and R. Tokuc, 2005. Tissue reactions of 5 sling materials and tissue material detachment strength of 4 synthetic mesh materials in a rabbit model. *J. Urol.*, 174: 2037-2040.