

## A Case of Ventricular Foreign Body in a Goose (*Anser anser*) (Case Report)

<sup>1</sup>Zulfikar Kadir Saritas, <sup>1</sup>Kamuran Pamuk, <sup>1</sup>Musa Korkmaz,

<sup>2</sup>Turan Civelek and <sup>1</sup>M. Volkan Yaprakci

<sup>1</sup>Department of Surgery

<sup>2</sup>Department of Internal Medicine, Faculty of Veterinary Medicine,  
Afyon Kocatepe University, Afyonkarahisar, Turkey

**Abstract:** A 10 weeks old, male domesticated goose was presented to Afyon Kocatepe University, Faculty of Veterinary Medicine, Department of Surgery Clinics with the complaints of non-appetite, infirmity and sudden weight loss. In clinical examination, the goose had severe abdominal sensitivity and free of any bone fracture. In radiological examination, a foreign body which was suspected as nail was determined in the abdominal region. Under general anesthesia, surgery was performed with the midline incision of the abdomen and then ventriculotomy was done. Foreign body was removed as determined as nail. Incisions on ventriculus and abdomen were closed routinely. Postoperatively, antibiotherapy, pain control and diet management were considered. The goose recovered in a week and appetite was restored normally. This case report aimed to report a rarely encountered ventricular foreign body (nail) in a goose.

**Key words:** Goose, ventricular foreign body, surgical treatment, goose, antibiotherapy

### INTRODUCTION

The Gastrointestinal (GI) Foreign Bodies (FB) are usually seen in dogs and cats (Adamcak *et al.*, 2000). Particularly, the FB in avian species are seen in wild birds, ratites and in juvenile parrots that it is common in proventricular or ventricular region of ostriches (Adamcak *et al.*, 2000; Honnas *et al.*, 1991, 1993; Jacobson *et al.*, 1986). In birds, surgical interventions are infrequent due to complications usually observed during clinical examination, general anesthesia, surgical approach and postoperative care.

Furthermore, the size of the birds and anatomical difficulty make the surgical procedure more complex (Bush and Kennedy, 1978). Bailey *et al.* (2001) has reported the GI FBs in bustards with high rate of mortality (Bailey *et al.*, 2001). To the best of the knowledge, there is no reported FB cases in geese. Therefore, this case report aimed to determine rarely encountered ventricular foreign body (nail) in a goose.

**Description of the case:** A 10 weeks old, 2, 4 kg, male domesticated goose was presented to the faculty clinics. The owner informed that general condition of the goose was gradually worsening in last 10 days and water intake was decreased within a term debilitatiting the case to stand on foot. In clinical examination, none of any or bone fracture was found but the weight loss

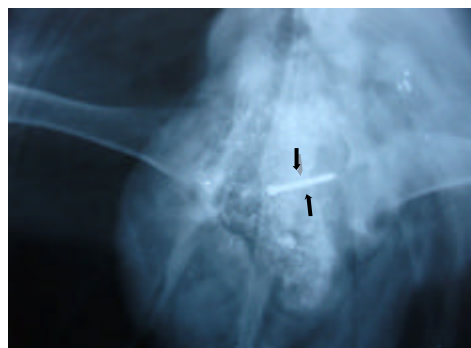

Fig. 1: The abdominal position of the FB in the case seen on ventro-dorsal X-ray (arrows)

sensitivity and in non-responsive stance. Abdominal palpation showed a sensitivity.

**Radiographical examination:** With considering the history and clinical symptoms a nail was found (Fig. 1) with contrast in the ventrodorsal position abdominal X-ray. Besides there was no skeletal disorder.

### MATERIALS AND METHODS

**Anesthesia:** About 5 mg kg<sup>-1</sup> xylazine HCl administrated i.m. for premedication. About 50 mg kg<sup>-1</sup> ketamine HCL administrated i.m. and general anesthesia achieved.




Fig. 2: Postoperative image of the extracted foreign body (nail)

**Surgery:** Under general anesthesia, the goose was positioned on dorsal recumbency and preparations were completed for surgery. The surgical area was bordered with drapes and midline incision was performed. The abdominal cavity was observed for adhesions and exudations and none encountered. The ventriculus was observed and found intact. Ventriculotomy was made as told before (Bush and Kennedy, 1978) and free body of the foreign object removed (Fig. 2). Ventricule and laparotomy incision closed in classical way (Bush and Kennedy, 1978).

**Postoperative care:** About 15 mg kg<sup>-1</sup> enrofloxacin i.m. administrated for a week time and within end of this period the recovery was fully achieved with the uncomplicated wound healing restoration of appetite and mobility.

## RESULTS AND DISCUSSION

The Gastrointestinal (GI) Foreign Bodies (FB) are oftenly seen in dogs and cats. In avian species, the foreign bodies are shown for in zoo birds, in ratites and in juvenile parrots (Adamcak *et al.*, 2000). Specially, ostriches are common to be seen to have proventricular and ventricular foreign bodies (Honnas *et al.*, 1991, 1993; Jacobson *et al.*, 1986) In the literature, there are records about FB in proventriculus and ventriculus in ostriches whereas none of metal FB case report was found in geese. Mostly, the reports was about extremity diseases of birds brought to Turkish clinics therefore, the study about FB in the ventriculus of a 10 weeks aged goose and it's surgical treatment was found to be unique in this area. In the study about FB in two bustards (Bailey *et al.*, 2001), it is underlined that ventricular FB has high rates of mortality which in one case had ventricular perforation. In the study, body of the nail was free inside the ventriculus and away from perforating the tissues. In previous studies, left lateral celiotomy method is used and

found easier exposition (Bailey *et al.*, 2001; Bush and Kennedy, 1978) in the study, median celiotomy was used to reach ventriculus and none of the difficulty in approach experienced.

In the pre-study made by Bush and Kennedy (1978) in pigeons, the approach to the lumen of the ventriculus, the incision made at the posterior end of the crop on the *M. intermedii* in one study group, in 2nd group it is made on aponeurosis. The three layers of ventriculus is sewn separately. In this case report, ventricular incision was made on *M. intermedii*.

In the same study (Bush and Kennedy, 1978), necropsies are made and it is shown that the aponeurosis approach group has developed the generalized peritonitis and the 2nd group on the incision made on *M. intermedii* seen with adhesions. According to the case, the postoperative 4th day, the patient started to take food and water at the 6th day, the gait returned to its normal state and in proceeding days fully recovery was achieved which was reported by the owner.

## CONCLUSION

As a result, the FB are commonly seen in birds. However, the publications about these cases are so limited. The aim in this study was to conduct the clinical case which brought to the clinics for the ventricular FB with the fellow practitioners.

## REFERENCES

- Adamcak, A., L.R. Hess and K.E. Quesenberry, 2000. Intestinal string foreign body in an adult umbrella cockatoo (*Cacatua alba*). J. Avian Med. Surg., 14: 257-263.
- Bailey, T.A., J. Kinne, J. Naldo, C.D. Silvanose and J.C. Howlett, 2001. Two cases of ventricular foreign bodies in the kori bustard (*Ardeotis kori*). Vet. Rec., 149: 187-188.
- Bush, M. and S. Kennedy, 1978. Ventriculostomy for removal of foreign bodies from sarus cranes. J. Am. Vet. Med. Assoc., 173: 1107-1110.
- Honnas, C.M., A. Blue-Mclendon, D.T. Zamos, E. Parson and J. Jensen, 1993. Proventriculotomy in ostriches: 18 cases (1990-1992). J. Am. Vet. Med. Assoc., 202: 1989-1992.
- Honnas, C.M., J. Jensen, J.L. Cornick, K. Hicks and B.S. Kuesis, 1991. Proventriculotomy to relieve foreign body impaction in ostriches. J. Am. Vet. Med. Assoc., 199: 461-465.
- Jacobson, E.R., G.W. Ellison, R. Mcmurphy, D.J. Heard and N. Ackerman, 1986. Ventriculostomy for removal of multiple foreign bodies in an ostrich. J. Am. Vet. Med. Assoc., 189: 1117-1119.