

Abomasal Ulceration in Buffaloes and Cattle: Clinico-Biochemical and Pathological Findings

¹M. Tharwat and ²A.F. Ahmed

¹Department of Animal Medicine, Faculty of Veterinary Medicine, Zagazig University, Zagazig, Egypt

²Department of Surgery, Faculty of Veterinary Medicine, Assiut University, 71526 Assiut, Egypt

Abstract: Although, abomasal ulceration is well studied in cattle, there is no data about the clinical and biochemical pictures of abomasal ulceration in buffaloes and native breed cattle. Objective was to describe the clinical, biochemical and pathological findings and response to medical treatment of abomasal ulceration in buffaloes and native breed cattle. Sixteen animals (buffaloes = 10, cattle = 6) were examined. They included 7 males (beef calves) and 9 females (dairy cows). Age range was 10 months to 8 years. All animals underwent a thorough clinical examination. Blood samples were taken for hematological and biochemical examinations. Animals were fed on high quality hay with no concentrates and treated with normal saline solution (5 L daily IV/5 days), oxytetracyclin (10 mg kg⁻¹ deep IM/7 days), Ranitidine (3 mg kg⁻¹ daily IM/7 days) and oral 50 g of sodium bicarbonate for 1 week. Results revealed that signs of abomasal ulceration disappeared in 9 animals (buffaloes = 5, cattle = 4, male = 7, female = 2). Response appeared after 1-2 weeks of treatment. No response to treatment was recorded in 7 animals (buffaloes = 5, cattle = 2, male = 0, female = 7) that were slaughtered and thoroughly examined at necropsy. At necropsy, abomasal ulceration was found along the greater curvature and on the most ventral part of the fundic region in 5 cases (buffaloes = 4, cattle = 1). Ulcers were non-bleeding, bleeding, perforating with localized peritonitis, perforating with diffuse peritonitis. Biochemical analysis revealed an increase in free fatty acids, segmented neutrophils, β -globulin and blood glucose.

Key words: Abomasal, buffaloes, cattle, necropsy, ulceration, blood glucose

INTRODUCTION

Abomasal ulceration is a common clinical problem in dairy cattle and occurs in lactating dairy cows during the 1st 6 weeks of lactation, mature bulls, hand-fed calves, veal calves and sucking beef calves (Radostits *et al.*, 2007). Intensive management and highly acidic diets contribute to the pathogenesis of abomasal ulceration. Stress although, a poorly defined entity also contributes in the recently fresh cow. Changing diet from milk to roughages is also a predisposing factor in weaning calves (Blowey, 2004; Constable *et al.*, 2005).

Shunting of a higher percentage of cardiac output to the fetus or to the highly lactating udder with concomitant decrease in abomasal perfusion and increase plasma cortisol may lead to abomasal ulceration (Constable *et al.*, 1992a). Prolonged use of Non Steroidal Anti-Inflammatory Drugs (NSAIDs) as a treatment of musculoskeletal disorders may develop abomasal ulceration. *Helicobacter pylori* and hair balls are present in some cases of abomasal ulceration (Dirksen, 1994; Radostits *et al.*, 2000). There are medical approach and occasionally surgical

treatment for abomasal ulceration (Radostits *et al.*, 2007). Medical approach includes blood transfusion, local coagulants, antibiotics and oral or systemic antacids (Ahmed *et al.*, 2002, 2005). Frequencies and types of abomasal ulceration in slaughtered buffaloes have been reported in abattoir studies (Misk *et al.*, 2003; Aligholi *et al.*, 2010; Ghadrddan-Mashhadi *et al.*, 2010).

Up to the researchers knowledge, there is no data about the clinical and biochemical pictures of abomasal ulceration in buffaloes and native breed cattle in Egypt. The aim of this study was to describe the clinical, biochemical and pathological findings as well as response to medical treatment of abomasal ulceration in water buffaloes (*Bubalus bubalis*) and native breed cattle.

MATERIALS AND METHODS

Animals, history and postmortem examinations: Sixteen animals (buffaloes = 10, cattle = 6) were examined. They included 7 males (beef calves) and 9 females (dairy) with age range between 10 months and 8 years. These animals were admitted to the Veterinary Teaching Hospital, Assiut

and Zagazig Universities, Egypt during the period from August 2004 to September 2006. Animals were admitted because of inappetance, abdominal pain, decreased milk production and tarry feces. They had been ill for 2-10 days before admission.

All animals underwent a thorough clinical examination as described previously (Rosenberger, 1990; Radostits *et al.*, 2000). Examination included general behavior and condition, auscultation of the heart, lungs, rumen and intestine, recording of heart rate, respiratory rate and rectal temperature, swinging auscultation, percussion auscultation of both sides of the abdomen and rectal examination. The owners were advised to feed only high quality hay and hold off concentrates for 2 weeks until clinical evidence of improvement exists. Animals were treated with normal saline solution (5 L daily, IV/5 days), oxytetracyclin (10 mg kg⁻¹, deep IM/7 days, terramycin LA, Pfizer), ranitidine (3 mg kg⁻¹ daily, IM/7 days, zantac® Injection: GlaxoSmithKline, Research Triangle Park, NC 27709, USA) and oral 50 g of sodium bicarbonate (Sigma-Aldrich, USA) for 1 week. Seven animals that did not respond to treatment were slaughtered and thoroughly examined at necropsy.

Hematological and biochemical examinations: Two blood samples were collected by puncture of the jugular vein into plain and EDTA-containing tubes. A complete blood count (hematocrit, total and differential leucocyte) was carried out on the first blood sample. After centrifugation

of the second blood sample, serum samples were collected and then frozen for later analysis of clinical chemistries. In the serum, the concentrations of total protein, albumin, calcium, phosphorus, glucose, Urea Nitrogen (UN), creatinine, total cholesterol, Non-Esterified Fatty Acids (NEFA), Beta-Hydroxy Butyric Acid (BHBA), sodium, potassium and chloride were determined using commercial kits (Bayer Diagnostics, Germany). The activities of enzymes aspartate aminotransferase and γ -glutamyl transpeptidase were also measured in serum samples. Serum proteins fractions were determined by electrophoresis (Electrophoresis Unit, Scie-plas Ltd. UK).

RESULTS AND DISCUSSION

Clinical signs were sudden onset of anorexia, tachycardia (90-100 min⁻¹), severely depressed milk production, abdominal pain, pale mucous membranes and melena. The feces were scant to diarrhea but black and tarry (Fig. 1A and B). Diagnosis of abomasal ulceration depended upon clinical signs, especially melena. Diagnosis was confirmed in some cases (n = 7) at necropsy.

Signs of abomasal ulceration disappeared in 9 animals (buffaloes = 5, cattle = 4, male = 7, female = 2). Response appeared after 1-2 weeks of treatment. No response to treatment was recorded in 7 animals (buffaloes = 5, cattle = 2, male = 0, female = 7). These animals were slaughtered and thoroughly examined. At necropsy,

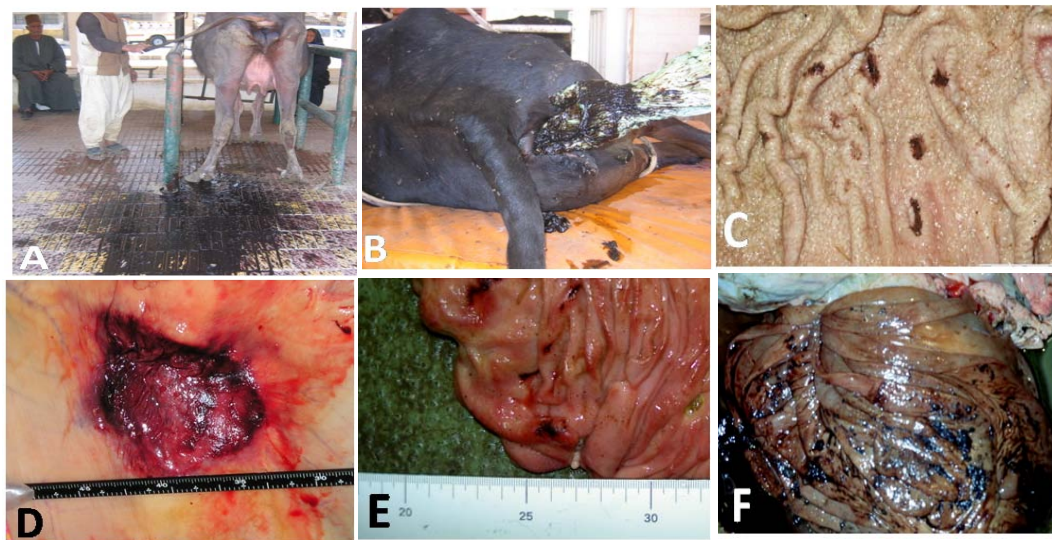


Fig. 1: A) Black tarry diarrhea in a buffalo cow; B) scanty black feces in a native breed cow; C) non perforating bleeding and non perforating abomasal ulcers at the pylorus in a cow; D) local abomasal serositis in a cow; E) non perforating bleeding ulcers at the fundus in a cow and F) intraluminal abomasal hemorrhage due to bleeding ulcer in a buffalo cow

Table 1: Hematological and biochemical findings in cattle and buffaloes with abomasal ulceration (n = 10)

Parameters	Finding at admission (mean±SD)
Hematocrit (%)	37±9
Leukocyte count (μL^{-1})	8250±3324
Segmented neutrophils (μL^{-1})	5050±527
Lymphocytes (μL^{-1})	3013±129
Total protein (g dL ⁻¹)	6.25±0.19
Albumin (g dL ⁻¹)	2.25±1.02
α -globulin (g dL ⁻¹)	0.68±0.06
β -globulin (g dL ⁻¹)	1.72±1.46
γ -globulin (g dL ⁻¹)	1.58±0.14
Aspartate aminotransferase (U L ⁻¹)	100±32
γ -glutamyl transferase (U L ⁻¹)	32±11
Calcium (mg dL ⁻¹)	7.6±1.3
Phosphorus (mg dL ⁻¹)	5.6±0.6
Glucose (mg dL ⁻¹)	94±20
Blood urea nitrogen (mg dL ⁻¹)	14±5
Creatinine (mg dL ⁻¹)	1.2±0.4
Total cholesterol (mg dL ⁻¹)	141±99
Sodium (mmol L ⁻¹)	141±5
Potassium (mmol L ⁻¹)	4±0.3
Chloride (mmol L ⁻¹)	97±5
Free fatty acids (mEq L ⁻¹)	0.64±0.15
β -hydroxy butyric acid (mmol L ⁻¹)	473±238

abomasal ulceration was found at the pylorus (Fig. 1C) and along the greater curvature and on the most ventral part of the fundic region (Fig. 1E) in 5 cases (buffaloes = 4, cattle = 1). Few cases had ulcers on the border between the fundic and pyloric region.

The ulcers were deep and well defined but occasionally, filled with blood clot or necrotic material. Non-perforating ulcer resulted in a minimal degree of intraluminal hemorrhage (Fig. 1F), focal abomasal thickening, or local serositis (Fig. 1D) was recorded in 4 cases. The ulcers measured from few millimeters to 4 cm in diameter and are either round or oval and found on the abomasal rugae with the longest dimension usually parallel to the long axis of the abomasum (Fig. 1E). Perforating ulcer resulted in acute localized peritonitis (n = 1) to the region of the perforation by adhesion of the involved portion of abomasum to adjacent viscera, omentum and the peritoneal surface (Fig. 2A and B). Also, perforating ulcer with leakage of abomasal contents and spread of digesta throughout the peritoneal cavity with diffuse peritonitis (Fig. 2C and D) was recorded in 2 cases.

Other postmortem findings in cases with abomasal ulcer included ruminal, reticular metal foreign objects and reticulo-omasal bleeding and ulceration (Fig. 3). Biochemical analysis revealed that there was an increase in free fatty acids, segmented neutrophils, β -globulin and blood glucose (Table 1).

The most obvious clinical signs of abomasal ulceration were anorexia and melena. Medical treatment was successful in 9/16 (56%) of the cases. There was a significant increase in free fatty acids. Non perforating (non bleeding and bleeding) and perforating ulcers with localized and diffuse peritonitis were found at necropsy.

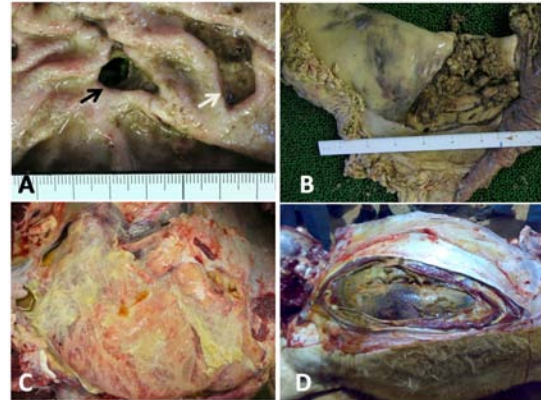


Fig. 2: A) Perforating (black arrow) and non perforating (white arrow) pyloric ulcer in the abomasums of a cow; B) local peritonitis and adhesion due to perforating ulcer in the previous cow; C) diffuse peritonitis and adhesions in a buffalo cow and D) leakage of abomasal contents with generalized peritonitis as a results of perforating abomasal ulcers in a cow

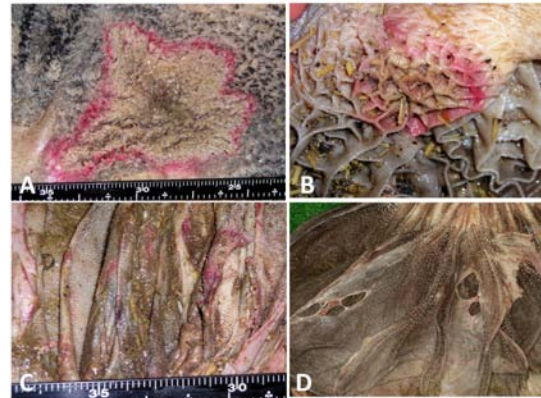


Fig. 3: A) Ruminal ulceration in a cow; B) reticular congestion in a cow; C) omasal congestion in a buffalo cow and D) omasal ulceration in a cow

Abomasal ulceration is common disease in cattle and is considered an added therapeutic challenge when present with other surgically manageable conditions. Animals with abomasal ulceration of the current study were buffalo cows, beef calves and dairy cows. Similar results have been reported (Radostits *et al.*, 2007). Some observers have found that acute hemorrhagic abomasal ulcers occur in high-producing mature dairy cows in early lactation or in cows 3-6 months after parturition (Radostits *et al.*, 2007).

The close relationship of the disease to parturition suggests that a combination of the stress of parturition,

the onset of lactation and high-level grain feeding is associated with acute ulceration in dairy cows (Constable *et al.*, 1992b). Presence of reticular foreign objects in animals of the present study could be considered as stress factor.

Acute bleeding ulcers occur occasionally in mature dairy and beef bulls (Radostits *et al.*, 2007). Beef calves with abomasal ulceration of the current study were fed a high concentrate ration for fattening which could be a predisposing factor for ulceration. Increased concentrates in ration has been reported to cause abomasal hyperacidity (Constable *et al.*, 1992b). Moreover, coarse roughages constituted a major part of ration for buffaloes and cows of the present study. It has been reported that ulcers may result from large, inadequately digested particles of hay or straw, passing from the rumen to the abomasum (Blowey, 2004). In addition, possible causes of primary abomasal ulceration have been reported to be abomasal hyperacidity in adult cattle, mechanical abrasion of the pyloric antrum due to the ingestion of coarse roughage, bacterial infections such as *Clostridium perfringens* Type A, concurrent stress as in cattle with severe inflammatory processes or in severe pain and abomasal hyperacidity in calves nursing their dams or calves hand-fed milk or milk-replacers (Radostits *et al.*, 2007). *Clostridium perfringens* Type A has been isolated from the abomasum of buffaloes with ulceration in an abattoir study (Mashhadi *et al.*, 2010).

In addition to other symptoms, melena was the characteristic sign of abomasal ulceration seen in the present study. It has been reported that abomasal ulcer in calves may hemorrhage, producing melena and anemia which is occasionally fatal (Blowey, 2004).

Moreover, the important clinical findings of hemorrhagic abomasal ulcers in cattle have been cited to be abdominal pain, melena and pale mucous membranes (Braun *et al.*, 1991; Radostits *et al.*, 2007). In the common clinical form of bleeding abomasal ulcers there has been a sudden onset of anorexia, mild abdominal pain, tachycardia, severely depressed milk production and melena (Braun *et al.*, 1991). However, melena has been reported to be almost a pathognomonic sign of an acute bleeding ulcer of the abomasum (Radostits *et al.*, 2007).

The treatment of abomasal ulcers in the current study was conservative medical approach with oral alkalinizing agent, systemic antacid, antibiotics and rehydrating fluid therapy. Such medical approach has been cited in different studies (Ahmed *et al.*, 2001; Blowey, 2004; Constable *et al.*, 2006). In another study, medical treatment has been reported to be effective in the treatment of cows with abomasal ulceration. Recovery has been reported to occur within a few days and cows'

general condition, appetite and defecation returned to normal (Braun *et al.*, 1991). Response to medical treatment appeared within 2 weeks in buffaloes and cattle of the current study.

The elevated concentrations of free fatty acids in animals of the present study if compared to other studies (Kaneko *et al.*, 1997; Radostits *et al.*, 2007) could be attributed to the decreased appetite in the studied buffaloes and cattle that resulted in fat mobilization for energy production. Abomasal ulceration of the present study was classified at necropsy, into non-perforating ulcer, ulcer causing severe blood loss, perforating ulcer with localized peritonitis and perforating ulcer with diffuse peritonitis. Similar classification has been cited (Blowey, 2004; Radostits *et al.*, 2007).

A descriptive epidemiology of fatal abomasal ulcers in Canadian beef calves has been reported that there is no sex or breed predisposition (Jelinski *et al.*, 1996a). The vast majority of fatal ulcers were perforating and the minority were hemorrhagic ones (Jelinski *et al.*, 1996b). Moreover, on post mortem of a calf, two large ulcers, one perforated with a white diphtheritic lining have been described, typically on the greater curvature of the abomasums (Blowey, 2004).

CONCLUSION

This study shows that clinical picture of abomasal ulceration in buffaloes and native breed cattle does not differ from that cited in other breeds of cattle. Biochemical analysis is not diagnostic. Response to medical treatment is fair. Prognosis is guarded in bleeding and perforating abomasal ulceration.

REFERENCES

- Ahmed, A.F., P.D. Constable and N.A. Misk, 2001. Effect of orally administered cimetidine and ranitidine on abomasal luminal pH in clinically normal milk-fed calves. *Am. J. Vet. Res.*, 62: 1531-1538.
- Ahmed, A.F., P.D. Constable and N.A. Misk, 2002. Effect of an orally administered antacid agent containing aluminum hydroxide and magnesium hydroxide on abomasal luminal pH in clinically normal milk-fed calves. *J. Am. Vet. Med. Assoc.*, 220: 74-79.
- Ahmed, A.F., P.D. Constable and N.A. Misk, 2005. Effect of orally administered omeprazole on abomasal luminal pH in dairy calves fed milk replacer. *J. Vet. Med. Ser. A*, 52: 238-243.
- Aligholi, R., R. Hobe-Naghi, S. Mizban and S. Ramin, 2010. Frequency and types of abomasal ulcers in slaughtered buffaloes in Urmia abattoir. *Proceedings of the 26th World Buiatrics Congress*, November 14-18, 2010, Santiago de Chile, Chile, pp: 1-2.

- Blowey, R.W., 2004. Digestive Disorders of Calves. In: Bovine Medicine: Diseases and Husbandry of Cattle, Andrews, A.H., R.W. Blowey, H. Boyd and R.G. Eddy (Eds.). 2nd Edn. Blackwell Science, New York, ISBN-13: 9780632055968, pp: 231-238.
- Braun, U., R. Bretscher and D. Gerber, 1991. Bleeding abomasal ulcers in dairy cows. *Vet. Rec.*, 129: 279-284.
- Constable, P.D., A.F. Ahmed and N.A. Misk, 2005. Effect of suckling cow's milk or milk replacer on abomasal luminal pH in dairy calves. *J. Vet. Internal Med.*, 19: 97-102.
- Constable, P.D., G. St-Jean, G.R. Koenig, B.L. Hull and D.M. Rings, 1992b. Abomasal luminal pressure in cattle with abomasal volvulus or left displaced abomasums. *J. Am. Vet. Med. Assoc.*, 201: 1564-1568.
- Constable, P.D., G.Y. Miller, G.F. Hoffsis, B.L. Hull and D.M. Ring, 1992a. Risk factors for abomasal volvulus and left abomasal displacement in cattle. *Am. J. Vet. Res.*, 53: 1184-1192.
- Constable, P.D., T. Wittek, A.F. Ahmed, T.S. Marshall, I. Sen and M. Nouri, 2006. Abomasal pH and emptying rate in the calf and dairy cow and the effect of commonly administered therapeutic agents. Proceedings of the 24th World Buiatrics Conference, October 15-19, 2006, Nice, France, pp: 1-15.
- Dirksen, G.U., 1994. Ulceration, dilatation and incarceration of the abomasum in calves: Clinical investigations and experiences. *Bovine Pract.*, 28: 127-135.
- Ghadrdan-Mashhadi, A.R., S. Esmailzadeh and M. Gandomi, 2010. Prevalence of different abomasal ulcers in buffaloes of Ahvas: An abattorial survey. *J. Vet. Res.*, 65: 351-356.
- Jelinski, M.D., C.S. Ribble, J.R. Campbell and E.D. Janzen, 1996a. Descriptive epidemiology of fatal abomasal ulcers in Canadian beef calves. *Prev. Vet. Med.*, 26: 9-15.
- Jelinski, M.D., C.S. Ribble, J.R. Campbell and E.D. Janzen, 1996b. Investigating the relationship between abomasal hairballs and perforating abomasal ulcers in unweaned beef calves. *Can. Vet. J.*, 37: 23-26.
- Kaneko, J.J., J.W. Harvey and M.L. Bruss, 1997. *Clinical Biochemistry of Domestic Animals*. 5th Edn., Academic Press, San Diego, California, ISBN-13: 9780123963055, Pages: 932.
- Mashhadi, A.R.G., M. Ghorbanpour, S. Kamali and R.N. Kohli, 2010. Role of *Clostridium perfringens* in causing abomasal ulcers in buffalo. *Pak. J. Biol. Sci.*, 13: 1113-1115.
- Misk, N.A., M.A. Semieka and A.F. Ahmed, 2003. Studies on omasal and abomasal disorders in cattle and buffaloes. *Egypt. Vet. Med. Assoc.*, 63: 331-350.
- Radostits, O.M., C.C. Gay, K.W. Hincheliff and P.D. Constable, 2007. *Veterinary Medicine: A Textbook of the Diseases of Cattle, Horses, Sheep, Pigs and Goats*. 10th Edn., Saunders Elsevier, St. Louis, Missouri, Pages: 708.
- Radostits, O.M., I.G. Mayhew and D.M. Houston, 2000. *Veterinary Clinical Examination and Diagnosis*. W.B. Saunders, London, ISBN-13: 9780702024764, Pages: 771.
- Rosenberger, G., 1990. *Clinical Examination of Cattle*. 3rd Edn., Paul Parey, Berlin and Munich, ISBN-13: 978-3826326523.