

Mast Cell Dynamics in the Digestive System During Infection by Muscovy Duck Reovirus

Quanxi Wang, Baocheng Wu, Changkang Wang and Fen Su
College of Animal Science, Fujian Agriculture and Forestry University,
Fuzhou, 350002 Fujian, China

Abstract: In order to investigate the influence of mast cell on young Muscovy duck digestive system infected muscovy duck reovirus, 60 healthy muscovy ducks at 5 days old were randomly divided into test group (30 ducks) and control group (30 ducks), the 2 groups were kept in the isolation room. The ducks of experiment group were injected 0.2 mL Muscovy duck reovirus (1% of TCID₅₀, TCID₅₀ = 10^{-3.7558}) by i.m on leg and the ducks of control group were treated with 0.2 mL normal saline. After infection 5, 10, 15, 20 and 25 days, the mast cell dynamics in liver, pancreas, esophagus, proventriculus, duodenum, jejunum, the ileum and cecum and rectum were recorded, respectively. The results showed that muscovy duck reovirus affect the mast cell quantity in the organ of digestive system, the mast cell number of the experiment group was higher than the control group at the earlier infection stage. With the time extended, the damage degree of virus to the organ of digestive system was different, the mast cell quantity in digestive system was different as well. It is concluded that in the process of the infection by muscovy duck reovirus, especially to digestive system, the mast cell played an important role.

Key words: Young muscovy duck, muscovy duck reovirus, mast cell, digestive system infection, liver, China

INTRODUCTION

Muscovy Duck Reovirus (MDRV) was first reported as the etiological agent of disease in South Africa (Kaschula, 1950) then happened in France (Gaudry *et al.*, 1972), Israel (Malkinson *et al.*, 1981) and so on. MDRV is an important poultry pathogen that happens in several diseases including viral arthritis/tenosynovitis, growth retardation, pericarditis, myocarditis, enteritis, hepatitis, bursal and thymic atrophy, osteoporosis, respiratory syndromes and sudden death (Robertson and Wilcox, 1986; Rosenberger and Olson, 1991; McNulty, 1993). MDRV could cause high morbidity and up to 50% mortality in young ducks (Malkinson *et al.*, 1981; Heffels-Redmann *et al.*, 1992) and the recovered ducks are markedly stunted in growth.

Since 1997, an infection disease was happened in muscovy duck in East-South of China which represented viral arthritis/tenosynovitis as the main clinical symptom and the main pathological change was a large number local necrosis in liver and spleen. In 2001, Professor WU attained a virus separated from the sick duck and confirmed the virus was Muscovy duck reovirus. Then the reovirus was reported separated from sick mule duck (Huang *et al.*, 2004) and goose (Wang *et al.*, 2003)

later on. Compared with different strain of reovirus, the Muscovy duck reovirus was different in antigenic structure, pathogenicity and host specificity and compared with avian reovirus, the muscovy duck reovirus has unique character such as pathogenicity or tissue tropism (Zhang *et al.*, 2005).

Mast cell distributes in all kind of organs, especially in the organ that could contact with external environment such as skin, windpipe and intestinal tract. The role of mast cell in those organs was guard for monitoring the pathogens inbreaking and starting the immunoreaction. It is known to all that mast cell plays an important role in hypersensitivity, especially in immediate hypersensitivity and it has some connection with the pathological and physiological process (Brockow *et al.*, 2002). In recent years, researchers found that mast cell played other important role in defense reaction of host against pathogen. It not only can recognize, engulf and kill the pathogen but also can tooling, present antigen and regulate immunoreaction (Zhou *et al.*, 2004).

Therefore, mast cell is the effector cell with which the host defenses against the infection by the virus, at the same time it becomes the site where the virus collects, copies and escapes from immune. Though the study of the direct effect of virus on mast cell is quite rare, the mast

cell is the target cell of virus. There are many mast cells distributed in the digestive system of duck which play an important role in the digestive system against the infection of pathogeny (Valsala, 1986). But in the various stage of infection, it parole different medium to carry out different function.

In this study, researchers injected Muscovy duck reovirus by i.m on leg and investigated the dynamics of mast cell in the various stage of infection in the digestive system by histochemistry method. Researchers want to know the variety of mast cell number in the various stage of infection in the digestive system, based on this we can preliminary attain the role of mast cell in the digestive system of duck infected by Muscovy duck reovirus.

MATERIALS AND METHODS

Cell and virus: The Muscovy duck reovirus B₃ train was used in this study. All the Muscovy duck reovirus isolates were propagated in Duck Embryo Fibroblasts (DEF). TCID₅₀ = 10^{-3.7558}.

Primary reagent: Toluidine blue presented by Beijing Jingkehongda Biotechnology Co. Ltd., in China.

Experimental design: About 5 days old muscovy ducks which were provided by the experimental duckery of Fujian Agriculture and Forestry University did not vaccinate the Vaccine of Muscovy duck reovirus and were free of Muscovy duck reovirus.

About 60 healthy muscovy ducks at 5 days old were randomly divided into test group (30 ducks) and control group (30 ducks), the 2 groups were kept in the isolation room. The ducks of experiment group were injected 0.2 mL Muscovy duck reovirus (1% of TCID₅₀, TCID₅₀ = 10^{-3.7558}) by i.m on leg and the ducks of control group were treated with 0.2 mL normal saline. After infection 5, 10, 15, 20 and 25 days, the dynamics of mast cell in liver, pancreas, esophagus, proventriculus, duodenum, jejunum, the ileum and cecum and rectum were recorded.

Collection of samples

Fixing solution: Carnoy's fixing solution was compounded of 10% glacial acetic acid, 30% chloroform and 60% absolute ethyl alcohol.

Collection of samples: Ducks were decapitated on the 5, 10, 15, 20 and 25th day after the injection of virus. Samples (liver, pancreas, oesophaguw, Gastric gland, duodenum, iejunum, caecum, rectum) were collected with the size of 1.5×1.5×0.5 cm from 6 ducks in each group, washed with physiological saline. The Intestinal contents were clean

out intestinal tract with physiological saline, too. The collected organs were fixed in Carnoy's fixing solution for 4 h at 4°C. Followed the method of routine histology, dehydration, transparence and embedding were completed. Samples were cut into 5 µm semiserial cross sections. Per tissue sample, one piece was picked up from each ten section, total 5 pieces from 50 sections.

Histochemical examination of mast cell

Preparation of staining fluid: The staining fluid of toluidine blue was prepared according to Welle *et al.* (1995). About 1.0 g toluidine blue dissolved in 80 mL distilled water and 0.6 g of potassium permanganate dissolved in 20 mL distilled water. The toluidine blue solution was boiled 10 min and the potassium permanganate solution was added dropwise into it then the mixture solution was boiled 10 min sequentially. Finally add the distilled water to 100 mL, let the mixed solution cooling and filter it, adjust pH to 1.0.

Toluidine blue staining for mast cell: The sections were dewaxed and exchanged out of water by the gradient of ethanol on base of conventional histological methods, staining fluid solution cover on the section for 30 sec, washed two time with distilled water, 3 min per time. Color separation was done by 95% alcohol and control the separational time by the microscope. When the metachromatic granule in the cytoplasm of mast cell was showed fuchsia, the color separation was stopped. The sections were dehydrated by the gradient of ethanol and were transparent through dipping in the dimethylbenzene. At last, the sections were sealed with a glass coverslip.

Analysis of tissue sections: To determine the number of mast cell, tissue sections were examined using the 40 stage objective of an LEICAR 2800 bright-field microscope, 5 microscope fields per section and 5 sections per tissue sample were examined. For each tissue section, mast cells in 5 microscope fields were counted and data expressed as the average number of mast cell per microscope field. The data was analyzed by t-test of SPSS10.0 statistical software. For each aspect examined, the Student t-test was applied to measure the statistical difference between group means. Means were considered different at p<0.05.

RESULTS AND DISCUSSION

The distribution of mast cell in digestive system: The histological results showed that mast cells were localized in all organs of duck digestive system. Tissues preserved in Carnoy's fluid and stained by toluidine blue revealed

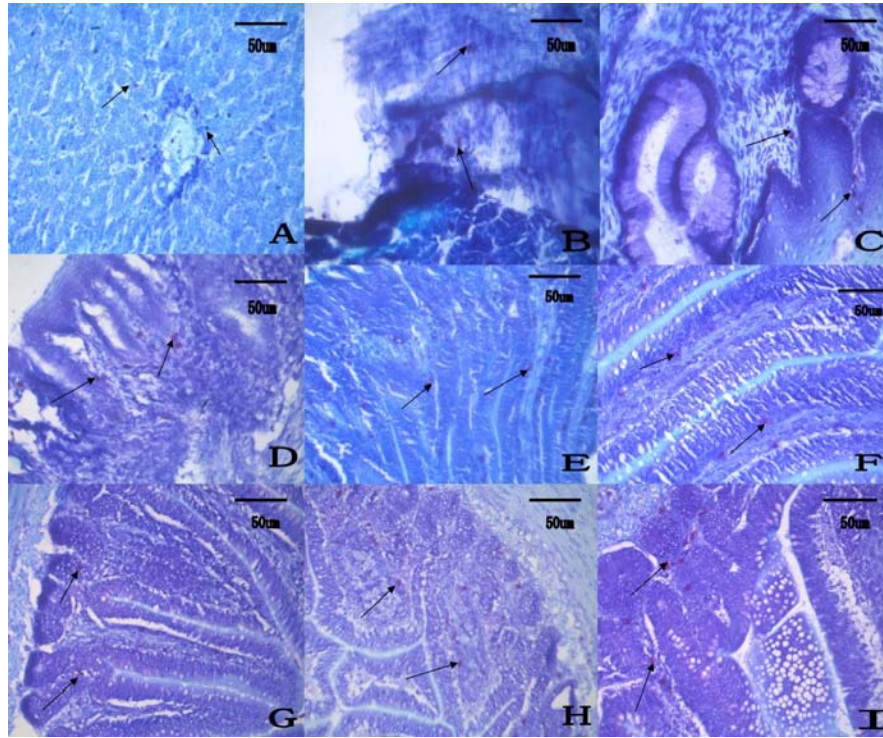


Fig. 1: The distribution of mast cell (arrows) in digestive system of duck; Mast cell was stained by toluidine blue, arrows showed mast cell, Scale bar = 50 μm , 400 \times . A-I were liver, pancreas, esophagus, glandular stomach, duodenum, jejunum, ileum, cecum, rectum, respectively

metachromatic character. The metachromatic granule in the cytoplasm of mast cell was showed fuchsia. The liver showed a few mast cell near central vein and the portal triads (Fig. 1A). Around blood vessels and catheter there were mast cells distributed in pancreas (Fig. 1B). The esophagus showed many mast cells, adjacent to esophageal glands and vessels (Fig. 1C). The glandular stomach also showed many mast cells distributed around gastric gland and vessels (Fig. 1D). In small intestine and large intestine the laminae propria revealed many mast cells (Fig. 1E-I) and the submucosa, muscularis and exosporium also showed some mast cells.

Effect on the number of mast cell in the liver and pancreas of young muscovy duck infected by reovirus:

There were more mast cells in the liver and pancreas of muscovy duck in the treatment group compared with control group at 5 and 10 days post-attack ($p < 0.01$). And for the both tissue, the number of mast cell was not different between treatment groups and control groups at 15, 20 and 25 days post-attack ($p > 0.05$). Similarly in the early infection stage of the young muscovy duck reovirus, the number of mast cell in the liver and pancreas was increased again the reovirus infection as the effector cell of immunity system. But at 15 days post-attack,

researchers found that the number of mast cell decrease compared with it at 15 days post-attack in liver and that was the least at 20 days post-attack in the treatment group. At 15 days post-attack the number of mast cell was the least in pancreas. On the contrary, researchers found that the number of mast cell in liver and pancreas present the trend as from less to more (Fig. 2a).

Effect on the number of mast cell in the esophagus and glandular stomach of young muscovy duck infected by reovirus:

In esophagus, mast cells were present around the esophageal glands and blood vessel. As shown in Fig. 2b, there were more mast cells in esophagus of experimental ducks ($p < 0.05$) at 5 days compared with the control. But the trend was change at 10 days post-attack, because the number of mast cell was significantly decreased compared with the control ($p < 0.05$) and the trend was continued to 20 days post-attack. Finally, researchers found that the number of mast cell in esophageal was no significantly different between treatment group and control group ($p > 0.05$). Infection of muscovy duck reovirus significantly increased the levels of mast cells compared with controls at 5 days post-attack ($p < 0.05$) and not significantly different between experiment group and control group ($p > 0.05$) at

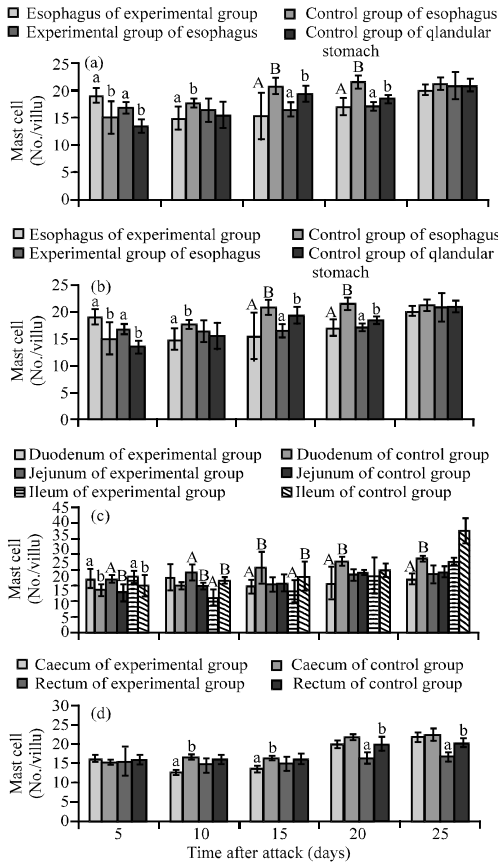


Fig. 2: Mast cell dynamics in the digestive system during infection by Muscovy duck reovirus; The difference between data with the different small letter within a column is significant ($p < 0.05$) and the difference between data with the different capital letter is very significant ($p < 0.01$); a) The number of mast cell in the liver and pancreas of experimental group and control group; b) The number of mast cell in the esophagus and glandular stomach of experimental group and control group; c) The number of mast cell in the small intestine of experimental group and control group; d) The number of mast cell in the colorectal of experimental group and control group

10 days post-attack in glandular stomach. However, the number of mast cell in treatment group significantly reduced compared with controls at 15 days post-attack ($p < 0.05$). At 20 and 25 days, no difference of mast cell number between the two groups was found ($p > 0.05$) (Fig. 2b).

Effect on the quantity of mast cells in the small intestine of young muscovy duck infected by reovirus: The small intestine of duck was consist of duodenum, jejunum,

ileum in which the lever of mast cell was observed. As shown in Fig. 2d, there were more mast cells in duodenum of experiment group than control group ($p < 0.05$) at 5 days post-attack but at post 10 days the difference was not observed ($p > 0.05$). At the same time, the lever of mast cell was significantly reduced in treatment group compared with control ($p < 0.01$) at 15, 20 and 25 days post-attack. In jejunum in experiment group compared with control group, though the number of mast cell were significantly increased ($p < 0.01$) at 5 and 10 days post-attack with reovirus, the difference was not observed at 15, 20 and 25 days ($p > 0.05$).

In ileum, the results were shown in Fig. 1G were scanty different in comparison with in duodenum and jejunum. There were more mast cells in ileum of experiment group compared with control ($p < 0.05$) at 5 days post-attack but the number reduced significantly ($p < 0.01$) at 10 days post-attack. The difference was not observed at 20 and 25 days post-attack with reovirus (Fig. 2c).

Effect on the number of mast cell in the colorectal of young muscovy duck infected for reovirus: In the test, researchers found that the number of mast cell in the cecum of experimental group duck at 5, 20 and 25 days after attack was not significantly different compared with control group. But at the 10 and 15 days, the number was significantly more than control group ($p < 0.05$).

The colon is too short to distinguish again rectum, so researchers did not detect the dynamic change of mast cell in it. But in rectum at 5 days after attack there was more mast cells compare with control group ($p < 0.05$). It was not different between two groups at 10 and 15 days ($p > 0.05$). Finally, we found that at 20 and 25 days, the number of mast cell in experiment group induced significantly compared with control group ($p < 0.05$) (Fig. 2d).

The aim of this study was to assess the interaction between MDRV infection and mast cell function in digestive system. The results suggest that MDRV infection alters mast cell populations. At the early stage of infection such as at 5 days postinfected, the mast cell number significantly increased compared with control group but at 10 or 15 days many organs in digestive system significantly decreased like liver, the small intestine duodenum. After 15 days postinfected, the mast cell populations in duodenum of infected duck still less than control group.

Mast cell was ubiquitously distributed throughout all organs with a striking predominance in the dermis or lamina propria of epithelial tissue in close apposition to vessels, appendages and nerves. Carnoy's fluid was the

best fixative for the demonstration of metachromasia of the mast cell granules of the duck. This is a feature similar to what has been reported in the chicken (Wight and Mackenzie, 1970). Valsala (1986) reached found that mast cells were seen in many of the organs in duck and were most numerous in the proventriculu.

Mast cell originates from CD₃₄⁺ stem cell in the bone marrow and is released from there into the circulation as unrecognizable precursors among adherent mononuclear cells. In the tissue, they assume their special characteristics, namely their display of specific electron-dense cytoplasmic granules which store histamine, glycosaminoglycans and the proteases tryptase and chymase (Czarnetzki *et al.*, 1995). Mast cells can respond to stimuli in their microenvironment via membrane receptors for molecules such as IgE (FcεRI), Stem Cell Factor (SCF) (encoded by the c-kit protooncogene), Nerve Growth Factor (NGF).

In the past, mast cell has been viewed primarily as effector cells of immediate type hypersensitivity reactions because of their ability to respond to allergens via their FcεR I receptor and since their mediators can induce all typical symptoms of immediate type allergic reactions. There is however, growing evidence that mast cells induce not only potentially harmful pathological reactions but that they play a fundamental role in tissue homeostasis, remodelling and repair.

In recent years, researcher have found that mast cell plays important role in the defense reaction against pathogen (Xu *et al.*, 2002). Mast cell not only can identify, engulf and kill the pathogen but also can process, present antigen and regulate the immunoreaction (Zhu, 1999). When mast cell was stimulated by pathogen and its secretion, it would release a lot of inflammatory medium such as histamine and startup local inflammatory reaction. So at the same time mast cell play cytophagy function, it recruits neutrophil granulocyte to help kill and clean out the pathogen (Marshall and Jawdat, 2004) first found a novel trypsin-type serine proteinase in pig lungs and demonstrated the possibility that pneumotropic Sendai and influenza A viruses utilize pig lung MCT to trigger their infectivity and for their multiplication in lungs. An endogenous inhibitor of porcine MCT, such as MPI which is secreted into the airway lumen (Mooren *et al.*, 1983; Ohlsson *et al.*, 1983), may regulate the enzyme activity and this viral infectivity *in vivo*. Therefore, researchers consider that mast cell would play a serial of function during virus infection and the virus can induce degranulation of mast cell. Kazuya Shirato studied the effect of RSV infection on mast cell function using the Human Mast Cell line (HMC-1).

In this study at the early stage of infection by MDRV, the mast cell number significantly increased

compared with control group which suggested that in this stage mast cell took part in fighting back MDRV actively, such as recognition and antigen-presentation and leading to inflammatory reaction (Xu *et al.*, 2002; Hu *et al.*, 2004). Especially, at 5 days postinfected mast cell populations in liver, pancreas, esophagus, glandular stomach, duodenum, jejunum and ileum significantly increased compared with control group and the clinical symptom as seriously diarrhea whose color was white or green was observed at 5 days postinfected. Researchers suggest that mast cell was stimulated by MDRV at the early infection then released superfluous inflammatory medium and cytokine which induced more inflammatory cell and released more inflammatory medium and cytokine, finally led to the unmanageable waterfall cascade reaction and organic damage. The superfluous LIPA and liposome released by mast cell in intestinal canal result in diarrhea. If the mast cell number increase, the probability of inflammatory reaction would raise and would not be benefit of the animal health.

In the past report, there were many inflammatory cells around liver cell and portal area primarily lymphocytes at 108 h after infected by MDRV and at 120 h afterinfected monocyte obviously infiltrated around blood vessel (Hu, 2004; Chen *et al.*, 2006). In this test, at 5 days (120 h) and 10 days afterinfected mast cell population in liver significantly increased compared with control group which suggested that the pathological changes in MDRV infected liver would have some connection with mast cell. However mast cell number sudden drop at 15 days in some organ of digestive system. Researchers consider that at the early stage of MDRV infection, the immune system including mast cell could actively cope with infection but the sudden increase of mast cells would release more digestive system leading to enteritis. The sudden drop of mast cell showed that MDRV could damage mast cell because MDRV could induce immunodepression.

It has been reported that IL-6 in combination with recombinant human SCF and some other cytokines is implicated in mast cell development from cord blood progenitors and induces chymase expression in all such mast cells earlier than tryptase expression. However, SCF and IL-6 do not promote complete maturation of human cultured mast cells from umbilical cord blood cells (Matsushima *et al.*, 2000). IL-6 is critical to the development of the acute-phase response during inflammation and has been shown to be necessary for the final stages of plasma cell development 41. Mast cells in both humans and rodents are able to produce IL-6 relatively rapidly compared with the more traditional sources of this cytokine, such as monocytes and macrophages (Van Snick, 1990). IL-6 is important in

inducing the expression of high-affinity receptors for IgE (Fc ϵ RI) (Ebisawa *et al.*, 1995). IL-6 is antiapoptotic for mast cells and IL-6 levels were significantly increased in the plasma of patients with systemic indolent mastocytosis (Brockow *et al.*, 2002).

Increasing IL-6 levels relate to greater erythema extent, lower mean arterial blood pressure and longer duration of symptoms. In the past study indicated that the content of IL-6 in the serum of experiment group ducks was lower than control group (Wang *et al.*, 2010). So researchers considered that the mast cell dynamics would be related with the lever of IL-6.

CONCLUSION

In this study, virus-infected cells were critical for degranulation during RSV infection; however, degranulation did not occur by direct RSV infection into mast cells. So virus and infected epithelial cell cooperate to induce degranulation. That is to say the degranulation of mast cell is induced by immunological and or non-immunological stimuli.

ACKNOWLEDGEMENTS

This researchers was supported by a Grant (No.: 2006J0298) from Fujian province Natural Science Foundation of China.

REFERENCES

- Brockow, K., C. Akin, M. Huber, L.M. Scott, L.B. Schwartz and D.D. Metcalfe, 2002. Levels of mast-cell growth factors in plasma and in suction skin blister fluid in adults with mastocytosis: Correlation with dermal mast-cell numbers and mast-cell tryptase. *J. Allergy Clin. Immunol.*, 109: 82-88.
- Chen, S.Y., Q.L. Hu, X.X. Cheng, S.L. Chen and B. Jiang *et al.*, 2006. Ultrastructure observation of muscovy ducks infected with muscovy duck reovirus. *Chinese J. Vet. Sci.*, 26: 662-664.
- Czarnetzki, B.M., J. Grabbe, G. Kolde, S. Kruger-Krasagakes, P. Welker and T. Zuberbier, 1995. Mast cells in the cytokine network: The what, where from and what for. *Exp. Dermatol.*, 4: 221-226.
- Heffels-Redmann, U., H. Muller and E.F. Kaleta, 1992. Structural and biological characteristics of reoviruses isolated from Muscovy ducks (*Cairina moschata*). *Avian Pathol.*, 21: 481-491.
- Hu, G., 2004. The function of mast cell. *Prog. Vet. Med.*, 25: 11-13.
- Hu, Q.L., S.Y. Chen and F.Q. Lin, 2004. The identification of muscovy duck reovirus. *J. Virol.*, 3: 242-247.
- Huang, Y., L.F. Cheng, W.Y. Li and S.H. Shi, 2004. Isolation and identification of reovirus in semi-muscovy duckling. *Chinese J. Vet.*, 1: 323-326.
- Kaschula, V.R., 1950. A new virus disease of the muscovy duck (*Cairina moschat* Linn.) present in Natal. *South Afr. Vet. Med. Assoc.*, 21: 18-26.
- Malkinson, M., K. Perk and Y. Weisman, 1981. Reovirus infection of young muscovy ducks (*Cairina moschata*). *Avian Pathol.*, 10: 433-440.
- Marshall, J.S. and D.M. Jawdat, 2004. Mast cells in innate immunity. *The J. Allergy Clin. Immunol.*, 114: 21-27.
- Matsushima, Y., O. Ishikawa, M. Kurosawa and Y. Miyachi, 2000. Stem cell factor and IL-6 do not promote complete maturation of human cultured mast cells from umbilical cord blood cells: An ultrastructural study. *J. Dermatol. Sci.*, 24: 4-13.
- McNulty, M.S., 1993. Reovirus. In: *Virus Infections of Birds*, McFerran, J.B. and M.S. McNulty (Eds.). Elsevier Science Publishers, Netherlands, pp: 181-193.
- Mooren, H.W., J.A. Kramps, C. Franken, C.J. Meijer and J.A. Dijkman, 1983. Localisation of a low-molecular-weight bronchial protease inhibitor in the peripheral human lung. *Thorax*, 38: 180-183.
- Ohlsson, M., M. Rosengren, H. Tegner and K. Ohlsson, 1983. Quantification of granulocyte elastase inhibitors in human mixed saliva and in pure parotid secretion. *Hoppe-Seylers Z. Physiol. Chem.*, 364: 1323-1328.
- Robertson, M.D. and G.E. Wilcox, 1986. Avian reovirus. *Vet. Bull.*, 56: 154-174.
- Rosenberger, J.K., N.O. Olson, 1991. Reovirus Infections. In: *Diseases of Poultry*, Calnek, B.W., H.J. Barnes, C.W. Beard, W.M. Reid and H.W. Yoder (Eds.). 9th Edn., Iowa State University Press, Ames Iowa, pp: 639-647.
- Valsala, K.V., B. Jarplid and H.J. Hansen, 1986. Distribution and ultrastructure of mast cells in the duck. *Avian Dis.*, 30: 653-657.
- Van Snick, J., 1990. Interleukin-6: An overview. *Annu. Rev. Immunol.*, 8: 253-278.
- Wang, G., Y. Wang, J. Wang, G. Zhu, W. Yan *et al.*, 2003. Isolation and identification of one goose reovirus strain. *China Poult.*, 25: 8-10.
- Wang, Q., B. Wu, G. Li and Y. Huang, 2010. Effects of duck infected by muscovy duck reovirus on humoral immunity function. *Sci. Agric. Sinica*, 43: 424-429.
- Welle, M.M., S.M. Proske, I.T. Harvima and N.M. Schechter, 1995. Demonstration of tryptase in bovine cutaneous and tumor mast cell. *J. Histochem. Cytochem.*, 43: 1139-1140.
- Wight, P.A. and G.M. Mackenzie, 1970. The mast cells of *Gallus domesticus*. II. Histochemistry. *Acta Anat.*, 75: 263-275.

- Xu, L.R., D.H. Gao and D.Z. Ou, 2002. Mast cell of poultry. *J. Vet. Med.*, 38: 32-35.
- Zhang, W.X., L.Z. Zhao, Y.H. Zhao and X.S. Gan, 2005. The observation of mast cell in toad digestive trace. *J. Henan Normal Univ.*, 33: 176-178.
- Zhou, J.X., D.H. Gao and Y.L. Bi, 2004. The progress of animal mast cell heterogenicity. *Guizhou Anim. Sci. Vet. Med.*, 28: 11-12.
- Zhu, Y.H., 1999. The function of Mast cell in infection and immune. *Abroad Med.: Immune*, 2: 96-98.