

Clinicopathological Effects of Various Levels of Dietary *Ambrosia maritima* on Wistar Rats

S.E.M. Barakat, F.A. Al-Hizab and A.O. Bakheit
Department of Pathology, Veterinary Medicine and Animal Resources,
King Faisal University, P.O. Box 1757, 31982 Al-Ahsa, Saudi Arabia

Abstract: The present study deals with the clinicopathological and biochemical effect of *A. maritima* on male Wistar rats. *Ambrosia maritima* is claimed to have several medicinal properties and used as a traditional medicine for the treatment of various disorders. The plant was fed to rats at 2 and 10% of the standard diet for 4 weeks. A 2% *A. maritima* was not toxic to rats during the experiment. However, mild increase in body weight, fatty cytoplasmic vacuolation, centrolobular individual cell necrosis and mild enteritis were observed in rats fed a diet containing 10% *A. maritima*. These findings were accompanied by alteration of serum Aspartate aminotransferase (AST), Alanine aminotransferase (ALT) and no changes were observed in the activities of ALP, concentrations of total protein, urea, total bilirubin, HDL and LDL. The concentrations of cholesterol and glucose were significantly decreased in the serum of rats fed 2 and 10% *A. maritima*.

Key words: *Ambrosia maritima*, clinicopathology, hepatotoxicity, enteritis, serum, body weight

INTRODUCTION

Recently, the use of herbal medicines have become indispensable and considered as essential part of the primary health care in human and veterinary medicine. The use of some plants constituents such as essential oils, terpenes, sesquiterpenes, quinines and alkaloids in the treatment of various animals disorders have been investigated (Oliver-Bever, 1986; Bakheit and Adam, 1995). Furthermore, the effect of some plants extracts on diabetes in different animal species have been studied (El-Batran *et al.*, 2006; Al-Rawi, 2007; Abdollahi *et al.*, 2010).

Ambrosia maritima (Fig. 1) is a member of the family Asteraceae and is locally known as Damesisa. The plant grows abundantly in Central Sudan where it is claimed to have several medicinal properties. Many researchers have studied the use of *A. maritima* as anthelmintic (El-Sawy *et al.*, 1984; Abadome *et al.*, 1994; Geerts *et al.*, 1994) and as antispasmodic (Ghazanfar, 1994). The effect of the whole plant or infusion of *A. maritima* on eggs, larvae and pupae of *Anopheles pharoensis* has been demonstrated.

In Sudan, dry *A. maritima* shoots are used in traditional medicine for the treatment of gastrointestinal disturbances and used as antidiabetic (El-Ghazali, 1986). *A. maritima* shoot is used in some African countries as a molluscicide (El-Sawy *et al.*, 1989;



Fig. 1: *Ambrosia maritima* L. damsissa

Abou Basha *et al.*, 1994). The objective of the present study was to investigate the pathological, haematological and biochemical effects of various levels of dietary *Ambrosia maritima* to male Wistar rats.

MATERIALS AND METHODS

Animals: All experiments were carried out with male Wistar albino rats weighing from 75-130 g purchased from the Animal House of Medicinal and Aromatic Plants Research Institute. They were housed under standard experimental condition in cages within the premises of

Medicinal and Aromatic Plants Research Institute. They were given 2 weeks adaptation period with free access to diet (Table 1) and water.

The plant material and preparation: *Ambrosia maritima* was obtained from the local market (Tayman for herbal Medicine), Khartoum Sudan and has been dried, crushed and grounded into powder then the powder mixed with the diet for 4 weeks.

Experimental design

Rats and diets: Eighteen male Wistar rats were obtained from the Aromatic Herbs and Medicinal Plants Research Institute (A.H.M.P.R.I), Khartoum, reared within the premises of the Institute under illumination at night and early morning with feed and drinking water provided *ad libitum*. The rats were allotted at random to 3 groups each of 6 rats. Group 1 was fed untreated diet and served as control. *Ambrosia maritima* was thoroughly mixed with the normal diet and fed to rats at 2% w/w (Group 2) and 10% w/w (Group 3) for 4 weeks.

Rats from each group were slaughtered at week 4 to identify gross lesions and specimens of the liver, intestines, kidneys, spleen and heart were immediately fixed in 10% neutral buffered formalin and processed for histopathology. Blood samples were collected at slaughter for hematology and serum analysis.

Growth changes: Average body weight and weight gain for each group of rats were measured weekly throughout the 4 weeks period.

Biochemical parameters: Blood samples were collected at slaughter in dry test tubes and serum was separated and stored at -20°C until analyzed for the activities of Aspartate aminotransferase (AST), Alanine aminotransferase (ALT) and Alkaline Phosphatase (ALP) and for the concentrations of glucose, total protein, albumin, globulin, bilirubin total, triglyceride, cholesterol, Low Density Lipoprotein (LDL) and High Density Lipoprotein (HDL) and urea. All parameters were evaluated using commercial kits (Biosystem S.A, Barcelona Spain).

Table 1: Percent (%) composition of normal diet* fed to rats

Ingredients	Percentage
Protein	22.5
Starch	59.2
Granulated sugar	05.0
Cellulose powder	03.0
DL. methionine	00.3
Corn oil	05.0
Superconcentrates	05.0

*Manufactured by Animal Wealth Development Company

Hematological parameters: Blood samples were collected in dry test tubes containing EDTA (Ethylene Diamine Tetra Acetic acid) and examined for Hemoglobin concentration (Hb), Red Blood Cell (RBC) counts, Packed Cell Volume (PCV), mean corpuscular volume, Mean Corpuscular Hemoglobin (MCH), Mean Corpuscular Hemoglobin Concentration (MCHC) and total White Blood Cell (WBC) counts (Schalm *et al.*, 1975).

Pathological examinations: Post-mortem examinations were conducted on all rats to identify gross lesions and specimens of intestine, liver, spleen, kidneys and heart were fixed in 10% neutral buffered formalin, embedded in paraffin wax, sectioned of 5 µm and stained with Haematoxylin and Eosin (H&E) for histopathological examinations (Fig. 2 and 3).

Statistical analysis: All the grouped data were statistically evaluated with SPSS 7.5 Software. Hypothesis testing methods included one way Analysis of Variance (ANOVA) followed by least significant difference test. p-value of <0.05 was considered to indicate statistical significance. All the results were expressed as mean±SD for six animals in each group (Snedecor and Cochran, 1989).

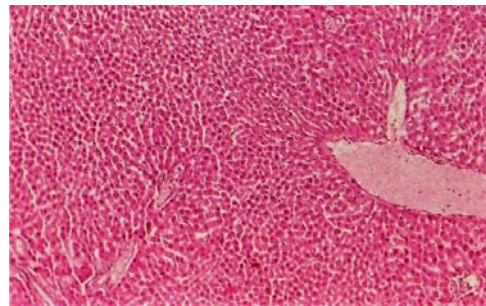


Fig. 2: Hepatocellular fatty change and individual cell necrosis of liver of rats in Group 3 (H&E×10)

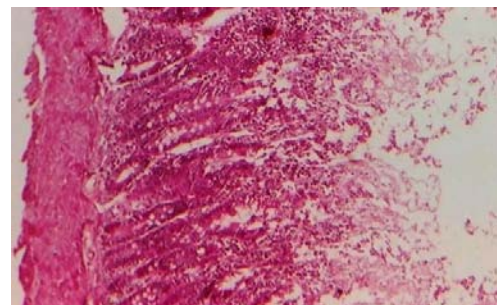


Fig. 3: Congestion and detachment of some intestinal mucosa in rats in Group 3 (H&E×10)

RESULTS AND DISCUSSION

Changes in growth: The effects of treatment with diets consisting of 2 and 10% *A. maritima* on body weight and weight gain of the rats are shown in Table 2. The rats on diet containing 2% *A. maritima* (Group 2) showed a moderate change in growth over the 4 weeks feeding period. The rats fed a diet containing 10% *A. maritima* (Group 3) had higher growth than the control (Group 1) and rats on 2% *A. maritima* diet (Group 2). None of the rats in all groups had showed clinical signs or died during the feeding period.

Pathological changes: Neither gross lesions nor microscopic changes were seen in the vital organs of the rats on the 2% *A. maritima* diet (Group 2) or of the control rats (Group 1). In the rats on the 10% *A. maritima* diet (Group 3), there were fatty cytoplasmic vacuolations and individual-cell necrosis in the hepatic centrilobular zone, mild, intestinal congestion and desquamation with no significant lesions in other tissues.

Hematological changes: No significant changes were observed in the values of RBC, WBCs, Hb, PCV and MCH in all treated and control groups. The value of MCV in group 2 and 3 was higher ($p < 0.05$) than the control group. Rats in Group 2 and 3 had lower values in MCHC than control (Group 1) (Table 3).

Serobiochemical changes: These data are shown in Table 4. In the rats on the 2 and 10% *A. maritima* diets (Group 2 and 3), there were increases in the activities of ALP. No significant changes in the concentration of total protein, urea, total bilirubin, HDL and LDL. The concentration of cholesterol and triglyceride were significantly lower ($p < 0.001$) in Group 2 and 3. Group 3 had lower cholesterol while no changes in triglyceride

level than control (Group 1) and Group 2. Glucose was significantly decreased in rats fed 2 and 10% *A. maritima* with diet.

In this study, researchers attempted to evaluate the pathological and biochemical effect of the medicinal plant *A. maritima* to Wistar rats in order to justify its use in folk medicine. No clinical signs were observed in all treated animals; this might be due to that the selected level of doses is not lethal and relatively safe or non toxic to rats. This is in agreement with the findings of Ojewole (2006). Interestingly, the mean body weight gain of rats fed 2 and 10% *A. maritima* shoot for 4 weeks was significantly elevated. This increase in mean body weight gain may be due to the presence of slight vital organ damage and high protein content in *A. maritima* but no exact proximate analysis of the plant is available. This is in agreement with Bakhiet and Adam (1996) and Abuelgasim *et al.* (2007) and who has observed a growth promoter effect in Wistar rats fed 2% *Francoeuria crispa* leaf for 8 weeks. The pathological and serobiochemical data were indicative of plant constituent affecting the liver, kidneys and intestine. However, the mechanism whereby these plant constituents injured vital organs cannot be stated from the present study. The damage to these organs probably contributed to the altered AST and ALT activities.

The enzymes ALT/AST are released when injury involves organelles such as mitochondria (Rajagopal *et al.*, 2003). As a result, the establishment of liver injury in this study caused both plasma membrane and organelle membrane damage. Rajesh and Latha (2004) also reported that the elevated activities of these enzymes were indicative of cellular leakage and loss of the functional integrity of the cell membranes.

No significant changes were observed in the values of RBC, WBCs, Hb, PCV and MCH in all treated and control groups. The slight anaemia observed in rats in Group 2 and 3 after 4 weeks of treatment was apparently normocytic normochromic. Previous investigations showed macrocytic normochromic anaemia in rats fed 10% Citrullus colocynthis fruits (Al-Qarawi and Adam, 2003).

The results of the present study indicate that the concentration of cholesterol and triglyceride were significantly lower ($p < 0.001$) in rats in Group 2 and 3.

Table 2: Growth changes in rats fed different dietary levels of *A. maritima* for 4 weeks

Treatment groups	Body weight (g) at start of expt.	Body weight (g) at end of expt.	Weight gain at end of expt. (g)
1 (control)	81.60±2.02	93.46±1.8	11.80
2 (2% w/w <i>A. maritima</i>)	85.83±5.82	99.30±4.5	13.47
3 (10% w/w <i>A. maritima</i>)	83.47±5.30	109.33±2.2	25.86

Values are means±SE

Table 3: Hematological changes in Rats fed different dietary levels of *A. maritima* for 4 weeks

Groups	RBCs ($\times 10^6$ mm)	WBCs ($\times 10^3$ mm)	Hb (g dL ⁻¹)	PCV (%)	MCV (m ³)	MCH (pg)	MCHC (%)
1 (control)	6.25±0.5	7.82±1.52	12.60±0.70	35.40±2.60	56.65±4.60	20.61±0.900	35.59±1.42
2 (2% w/w <i>A. maritima</i>)	6.46±0.9	6.02±0.80	12.20±1.50	39.38±8.40	60.90±2.90*	18.80±0.900	30.98±2.20*
3 (10% w/w <i>A. maritima</i>)	6.83±0.6	6.20±2.00	13.30±1.60	41.67±4.42	61.00±2.40*	19.45±0.800	31.90±1.60*

Values are means±SE

Table 4: Serobiochemical changes in rats fed different dietary levels *A. maritima* for 4 weeks

Groups	Triglyceride	Total protein	Urea	Glucose (mg dL ⁻¹)	Bilirubin total	Cholesterol	HDL	LDL	AST	ALT	ALP
1 control	28.3±1.0	7.14±1.2	36.37±0.5	102.3±0.1	0.23±0.2	50.0±1.70	49.8±9.00	94.66±13.2	39.8±1.60	35.5±15.20	112.0±1.8
2 (2% w/w <i>A. maritima</i>)	24.1±3.5	8.23±2.2	45.10±1.4	93.90±0.2	0.20±0.2	38.6±1.00	50.8±6.10	88.00±4.00	93.6±2.00	44.33±6.20	126.8±2.2
3 (10% w/w <i>A. maritima</i>)	27.6±3.0	6.32±4.7	41.10±1.2	84.80±0.3	0.18±0.2	33.0±0.12	45.08±2.4	91.36±5.40	123.4±140	57.6±1.080	117.5±1.6

Values are means±SE

Moreover the concentration of glucose was significantly decreased in rats fed 2 and 10% *A. maritima* with diet.

CONCLUSION

It could be concluded that *Ambrosia maritima* shoots are able to decrease both the blood glucose and cholesterol levels in rats. The hypoglycaemic effect of medicinal plants have been investigated by several researchers as Lin (1992), Gray and Flatt (1998) and Machado *et al.* (2000). These study findings lend pharmacological credence to the suggested folkloric, ethnomedical uses of this plant in the management and/or control of diabetes mellitus and obesity in some rural communities in Sudan and they can be recommended for use as a natural supplementary herbal remedy in patients suffering from diabetes mellitus. More research on this finding is required not only because of the limited experimental data but also because of the lack of information on the effects of the chronic consumption of *A. maritima*. Furthermore, investigations into the appropriate isolation, characterization and concentration of the active constituents in *A. maritima* are deemed necessary for elucidating their modes of action.

ACKNOWLEDGEMENT

The researchers are grateful to ESESCO for interest in the research and financial support.

REFERENCES

Abadome, F., S. Geerts and V. Kumar, 1994. Evaluation of the activity of *Ambrosia maritima* L. against schistosoma mansoni infection in mice. *J. Ethnopharmacol.*, 44: 195-198.
 Abdollahi, M., A.B.Z. Zuki, Y.M. Goh, A. Rezaeizadeh and M.M. Noordin, 2010. The effects of *Momordica charantia* on the liver in streptozotocin-induced diabetes in neonatal rats. *J. Biotechnol.*, 9: 5004-5012.

Abou Basha, L.M., M.H. El-Sayad, A.F. Allam and M.M. Osman, 1994. The effect of *Ambrosia maritima* (Damsissa) on the viability of *Lymnaea cailliaudi*. An experimental study. *J. Egypt Soc. Parasitol.*, 24: 513-517.
 Abuelgasim, A.I., A.O.F. Elrahman and M. Galal, 2007. Toxicopathological effects of *Ambrosia maritima* L. (Compositae) extracts in rats. *Vet. Res.*, 1: 71-75.
 Al-Qarawi, A.A. and S.E.I. Adam, 2003. Effect of combination of *Capsicum frutescens* and *Citrullus colocynthis* on growth, haematological and pathophysiological parameters of rats. *Phyther. Res.*, 17: 92-95.
 Al-Rawi, M.M., 2007. Effect of *Trifolium* sp. flower extracts on the status of liver histology of streptozotocin-induced diabetic rats. *Saudi J. Biol. Sci.*, 14: 21-28.
 Bakhiet, A.O. and S.E.I. Adam, 1995. Therapeutic utility, constituents and toxicity of some medicinal plants: A Review. *Vet. Hum. Toxicol.*, 37: 225-228.
 Bakhiet, A.O. and S.E.I. Adam, 1996. Effect of *Ambrosia maritima* L. On Bovans-type chicks. *J. Herbs Spices Med. Plants*, 4: 51-61.
 El-Batran, S.A.E.S., S.E. El-Gengaihi and O.A. El-Shabrawy, 2006. Some toxicological studies of *Momordica charantia* L. on albino rats in normal and alloxan diabetic rats. *J. Ethnopharmacol.*, 108: 236-242.
 El-Ghazali, G.E.B., 1986. Medicinal Plants of the Sudan, Part I: Medicinal Plants of Erkowit. Khartoum University Press, Khartoum, Sudan.
 El-Sawy, M., J. Duacun and T. Marshall, 1984. The mulluscicidal properties of *Ambrosia maritima* L. (Compositae) 2. Results from a field trial using dry plant material. *Tropenmed Parasitol.*, 35: 100-104.
 El-Sawy, M.F., J. Duncan, S. Amer, H. El-Ruweini and N. Brown, 1989. The molluscicidal properties of *Ambrosia maritima* L. (Compositae). 4. Temporal and spatial distribution of *Biomphalaria alexandrina* in Egyptian village irrigation systems with reference to schistosomiasis transmission control. *Trop. Med. Parasitol.*, 40: 103-106.

- Geerts, S., K. van Blerk and L. Triest, 1994. Effect of *Ambrosia maritime* on *Anopheles stephensi* and *Aedes aegypti*. *J. Ethnopharmacol.*, 42: 7-11.
- Ghazanfar, S., 1994. Handbook of Arabian Medicinal Plants. CRC Press, Boca Raton, USA., Pages: 265.
- Gray, A.M. and P.R. Flatt, 1998. Actions of the traditional anti-diabetic plant, *Agrimony eupatoria* (agrimony): Effects on hyperglycaemia, cellular glucose metabolism and insulin secretion. *Br. J. Nutr.*, 80: 109-114.
- Lin, C.C., 1992. Crude drugs used for the treatment of diabetes mellitus in Taiwan. *Am. J. Chin. Med.*, 20: 269-279.
- Ojewole, J.A.O., 2006. Analgesic, antiinflammatory and hypoglycaemic effects of ethanol extract of *Zingiber officinale* (Roscoe) rhizomes (Zingiberaceae) in mice and rats. *Phytother. Res.*, 20: 764-772.
- Oliver-Bever, B., 1986. Medicinal Plants in Tropical West Africa. Cambridge University Press, New York, USA., ISBN-13: 9780521268158, Pages: 375.
- Rajagopal, S.K., P. Manickam, V. Periyasamy and N. Namasivayam, 2003. Activity of *Cassia auriculata* leaf extract in rats with alcoholic liver injury. *J. Nutr. Biochem.*, 14: 452-458.
- Rajesh, M.G. and M.S. Latha, 2004. Preliminary evaluation of the antihepatotoxic activity of Kamilari, a polyherbal formulation. *J. Ethnopharmacol.*, 91: 99-104.
- Schalm, O.W., N.C. Jain and G.H. Carroll, 1975. Veterinary Haematology. 3rd Edn., Lea and Febiger, Philadelphia, PA, USA.
- Snedecor, G.W. and W.G. Cochran, 1989. Statistical Methods. 8th Edn., Iowa State University Press, USA., Pages: 03.