

Chronic Peritonitis in Buffaloes and Cattle: Clinical, Hematological, Ultrasonographic Findings and Treatment

¹M. Tharwat, ²A.F. Ahmed and ³O.S. El-Tookhy

¹Department of Animal Medicine, Faculty of Veterinary Medicine,
Zagazig University, Zagazig, Egypt

²Department of Surgery, Radiology and Anesthesiology,
Faculty of Veterinary Medicine, Assiut University, Assiut, Egypt

³Department of Surgery, Radiology and Anesthesiology,
Faculty of Veterinary Medicine, Cairo University, Cairo, Egypt

Abstract: Objectives of the present study were to describe the clinical, hematological, ultrasonographic findings and treatment of chronic peritonitis in water buffaloes (*Babalis babalis*) and Egyptian native breed cattle. Fifteen animal (water buffaloes, n = 7 and native breed cattle, n = 8) with signs of chronic peritonitis. All animals underwent a thorough clinical examination and complete blood count and biochemistry panel were investigated. Ultrasonographic examination was carried out in standing position using 3.5 and 5.0 MHz sector transducers. Eleven cases were treated medically and four surgically through ultrasonographic guided needle aspiration. Despite clinical signs were nonspecific, seven different lesions in the peritoneum of buffaloes and cattle were identified ultrasonographically; reticular abscess with/out peritoneal effusion, ruptured reticular abscess, purulent peritonitis, peritoneal abscess, fibrinous peritonitis and adhesions due to traumatic reticuloperitonitis. There were significant neutrophilic leukocytosis, hypoalbuminemia and hyperglobulinemia. Diagnosis was confirmed in five cases via necropsy. Full recovery was achieved in all surgically treated animals whereas slaughtering was recommended for all medically treated cases. In conclusion, ultrasonography is feasible diagnostic tool for identifying different forms of chronic peritonitis in bovine. Clinical signs and laboratory findings are nonspecific. Surgical intervention is a valuable choice of treatment.

Key words: Abdomen, ultrasound, buffalo, cattle, peritonitis, Egypt

INTRODUCTION

Peritonitis is a common disease in cattle, less common in horses and rarely if ever identified clinically in sheep, pigs or goats (Radostits *et al.*, 2000). There are general signs applicable to all species and most forms of the disease in a general way. In addition, there are special findings peculiar to individual species and to various forms of the disease.

Unfortunately, the clinical signs were reported to be nonspecific and the disease needs further diagnostic tool to confirm the diagnosis. Currently, ultrasonography is an integral part of contemporary bovine medicine (Braun, 2004) and is routinely used as a noninvasive diagnostic tool for the investigation of bovine gastrointestinal disorders, the most common of which are traumatic reticuloperitonitis, left and right abomasal displacement, ileus of the small intestine and dilatation and displacement of the cecum (Braun, 2009a). Ultrasonography of the peritoneum has been used in examination of the peritoneum and reticulorumen in water buffaloes

(Abdelaal *et al.*, 2009) more extensively in cattle (Braun, 2004, 2008, 2009a), horses (Reef, 2003; Stewart, 2006; Radostits *et al.*, 2007) and small animals (Negrini *et al.*, 2003). Transabdominal ultrasonography has been cited to be the best method to assess the extent of peritoneal reaction/abscessation caused by a penetrating reticular foreign body (Braun, 2008).

The aim of the present study was to describe the clinical, hematological, ultrasonographic findings of chronic peritonitis in water buffaloes (*Babalis babalis*) and Egyptian native breed cattle and state the significance of surgical intervention using ultrasound guided needle aspiration of some cases.

MATERIALS AND METHODS

Animals, history and clinical examinations: The present study was conducted on 15 female animals (water buffaloes, n = 7 and native breed cattle, n = 8), weighing 480-620 kg (530±60 kg) and aging 4-7 years (average = 6 years). History revealed that all cases had

been unwell for 2-4 weeks prior to admission. On admission, all animals went through a detailed clinical examination as described in previous reports (Rosenberger, 1990; Radostits *et al.*, 2000) which included general behavior and body condition, auscultation of the heart, lungs, rumen and intestine, measurement of heart rate, respiratory rate and rectal temperature, swinging auscultation, percussion auscultation of both sides of the abdomen and rectal examination.

Hematological and biochemical analyses: Two blood samples were collected by puncture of the jugular vein, one on EDTA and the other without an anticoagulant. A complete blood count (hematocrit, haemoglobin, total and differential leucocytes) was carried out. After centrifugation of the second blood sample, serum samples were collected and frozen for later analysis of clinical chemistry. Commercial kits were used to determine the serum concentrations of total protein, albumin, calcium, phosphorus, glucose, Non-Esterified Fatty Acids (NEFA), β -Hydroxybutyric Acid (BHBA), Urea Nitrogen (UN), creatinine, total cholesterol, sodium, potassium and chloride. The serum activities of Aspartate

aminotransferase (AST), γ -Glutamyl Transferase (GGT), Creatine Kinase (CK) and Lactate Dehydrogenase (LDH) were also measured in serum samples. Serum protein fractions were determined by electrophoresis.

Ultrasonographic examination and aspiration technique:

Ultrasonographic examination was carried out while the animals were standing position using 3.5 and 5.0 MHz sector transducers (Pie Medical 240 Parus, The Netherlands). In preparation for ultrasonography, the abdomen were clipped, shaved, washed with water and soap then wiped with alcohol and then the coupling gel was then applied. Abdominal ultrasonography was carried out as described in earlier report (Mohamed and Oikawa, 2007; Braun, 2009a). The peritoneum, rumen, reticulum, omasum, abomasum, spleen, small and large intestines, liver, pancreas and right kidney were examined.

Medicinal treatment: Animals were treated with penicillin streptomycin 40.000 IU kg⁻¹ BW IM/14 days (Pen and Strep, Norbrook Laboratories, UK), flunixin meglumine 2.5 mg kg⁻¹ BW IV/7 days (Finadyne, Intervet/Schering-Plough Animal Health, UK) and Ringer solution (large

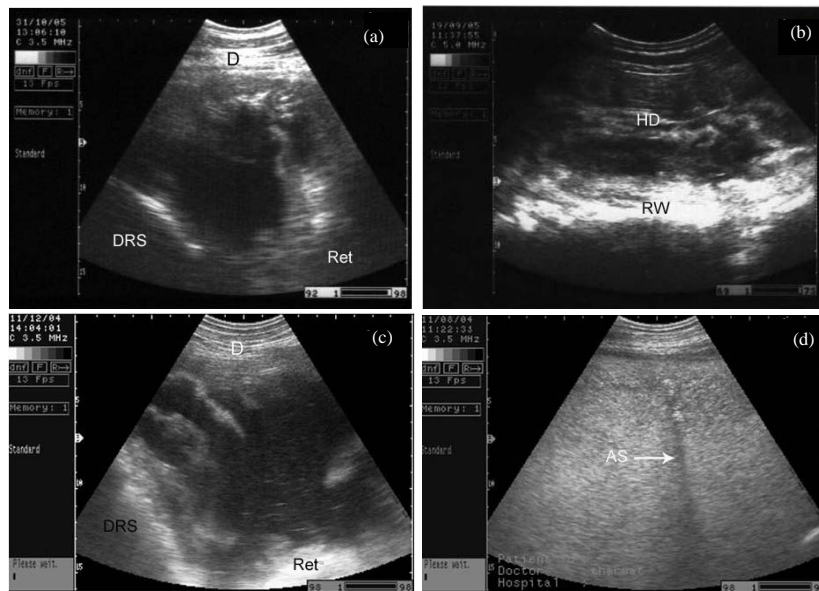


Fig. 1: Abdominal ultrasonograms in buffaloes and cows with chronic peritonitis; a) The left ventral abdomen showing heterogeneous deposits with fluid pockets in a buffalo between left ventral abdominal wall and ruminal wall (fibrinous peritonitis); b, c) The left of the sternum visualizing massive effusions among the reticulum, dorsal ruminal sac and diaphragm in 2 cows (peritoneal effusion). The effusion in b is anechoic while in c is heterogeneous with fibrin sheets; d) The right ventral abdomen in a cow demonstrating massive amount of hyperechoic fluid with acoustic shadowing (arrow) due to calcified pus (purulent peritonitis). All images were taken using a 3.5 MHz sector transducer. RW = Ruminal Wall; DRS = Dorsal Ruminal Sac; Ret = Reticulum; D = Diaphragm; AS = Acoustic Shadowing; HD = Heterogeneous Deposits

animals: 5 L daily). In addition in cases with constipation, animals were drenched 2 L of liquid paraffin/3 days. In animals with diarrhea, animals were drenched oral sulphonamide mixture with tannic acid as astringent/4 days.

Surgical intervention: After sterilization by standard surgical disinfection technique, the examined area was infiltrated with 10 mL procaine HCl 2%. About 10 min later, with the point of a scalpel blade, a small incision was made immediately adjacent to the transducer through the skin of the abdominal wall. A 14 G×170 mm spinal needle (Kurita Co., Ltd, Tokyo, Japan) was advanced through the skin and guided ultrasonographically towards the abscess and with a slight thrust was pushed through the lesion. The end of the needle within the lesion was usually visible in the ultrasonograms. The stylet was then withdrawn and the contents were aspirated percutaneously (Fig. 1a-d).

Statistical analysis: Data of the hematological and biochemical parameters were statistically analyzed using Student t-test.

RESULTS AND DISCUSSION

Clinical, hematological and biochemical findings: Physical condition was moderate to poor in all animals. Diseased cases showed signs of anorexia (n = 10), chronic weight loss (n = 12), recurrent tympany (n = 8), chronic diarrhea and/or constipation (n = 9), decreased milk production (n = 13) and recumbency (n = 4). Rectal temperature varied from 37.5-40°C. Heart rate was ranged from 50-97 beats min⁻¹ and the respiratory rate was between 16 and 45 breaths min⁻¹. Ruminal motility was either reduced or completely absent. Scanty feces was reported in five buffaloes and six cattle. Hematologically, there was a significant neutrophilic leukocytosis (p<0.05). Biochemical findings showed that animals suffered from hypoalbuminemia (p<0.05) and hyperglobulinemia (p<0.01, Table 1).

Ultrasonographic findings: Lesions were classified according to ultrasonographic findings into fibrinous peritonitis (buffalo = 1), reticular abscess alone (buffaloes = 2, cattle = 2) and with peritoneal effusion (cattle = 3), purulent peritonitis (cattle = 1), adhesions due to traumatic reticuloperitonitis (buffaloes = 4), ruptured reticular abscess with accumulation of pus in the peritoneal cavity (cattle = 1) and peritoneal abscess (cattle = 1). Fibrinous peritonitis were shown at the sonogram as heterogeneous deposits of echogenic and

Table 1: Hematological and biochemical findings in buffaloes and cows with chronic peritonitis

Parameters	Findings on admission (n = 15)	Reference values #
Haematocrit (%)	32±6	24-46
Leukocyte count (mL)	13550±1626*	4000-12000
Hemoglobin (g dL ⁻¹)	12±2	8.0-15.0
Neutrophils (mL)	8537±3659*	600-4000
Lymphocytes (mL)	4472±3388	2500-7500
Total protein (g dL ⁻¹)	8.3±0.3	5.7-8.1
Albumin (g dL ⁻¹)	1.3±0.2*	2.1-3.6
α-globulin (g dL ⁻¹)	0.9±0.5	0.75-0.88
β-globulin (g dL ⁻¹)	0.7±0.1	0.8-1.1
ε-globulin (g dL ⁻¹)	5.4±0.7**	1.69-2.27
Glucose (mg dL ⁻¹)	88±47	45-75
Aspartate aminotransferase (UL ⁻¹)	113±22	43-127
γ-glutamyl transferase (UL ⁻¹)	15±14	15-39
Calcium (mg dL ⁻¹)	9±2	9.7-12.4
Phosphorus (mg dL ⁻¹)	8±2	3.9-9.2
Blood urea nitrogen (mg dL ⁻¹)	37±44	6.0-27
Creatinine (mg dL ⁻¹)	1.0±0.5	1.0-2.0
Total cholesterol (mg dL ⁻¹)	66±41	65-220
Sodium (mmol L ⁻¹)	137±8	132-152
Potassium (mmol L ⁻¹)	3.3±1.3	3.9-5.8
Chloride (mmol L ⁻¹)	93±17	95-110
Free fatty acids (mEq L ⁻¹)	0.41±0.46	0.07-0.15
β-hydroxy butyric acid (mmol L ⁻¹)	267±177	100-400
Creatine kinase (U L ⁻¹)	204±131	39-260
Lactate Dehydrogenase (LDH) (U L ⁻¹)	1899±1243	520-1300

#Kaneko *et al.* (1997) and Radostits *et al.* (2007); Data are expressed as mean±SD; *p<0.05; **p<0.01

anechoic materials between the rumen and left abdominal wall (Fig. 1a). Peritoneal effusion appeared as echogenic areas of fibrinous tissue deposits interspersed with hypoechogenic areas of fluid pockets (Fig. 1b, c). Purulent peritonitis appeared as homogenous echogenic contents with acoustic shadowing (Fig. 1d). Traumatic reticuloperitonitis appeared as thick corrugated reticular wall with echogenic deposits between the rumen and abdominal wall (buffalo = 1, Fig. 2b) and between the reticulum and abdominal wall (buffaloes = 2). Anechoic compartments of peritoneal fluids were also shown within the fibrin deposits (Fig. 2a and c). Reticular and peritoneal abscesses appeared ultrasonographically as anechoic contents surrounded by echogenic line representing the capsule (Fig. 2d). Echogenic contents were also shown. The diameter of the abscess ranged from 5-25 cm.

Treatment with success evaluated as complete recovery was achieved in 4 cases that underwent surgical aspiration using sonar-guided intervention. Eleven cases did not response to treatment and therefore were slaughtered. Five of the slaughtered cases were examined thoroughly post-mortem.

Necropsy findings: Ultrasonographic findings were confirmed in 5 cases on necropsy. A cow with peritoneal effusion and reticular abscess (Fig. 3a), a buffalo with fibrinous peritonitis (Fig. 3b), a cow with ruptured reticular

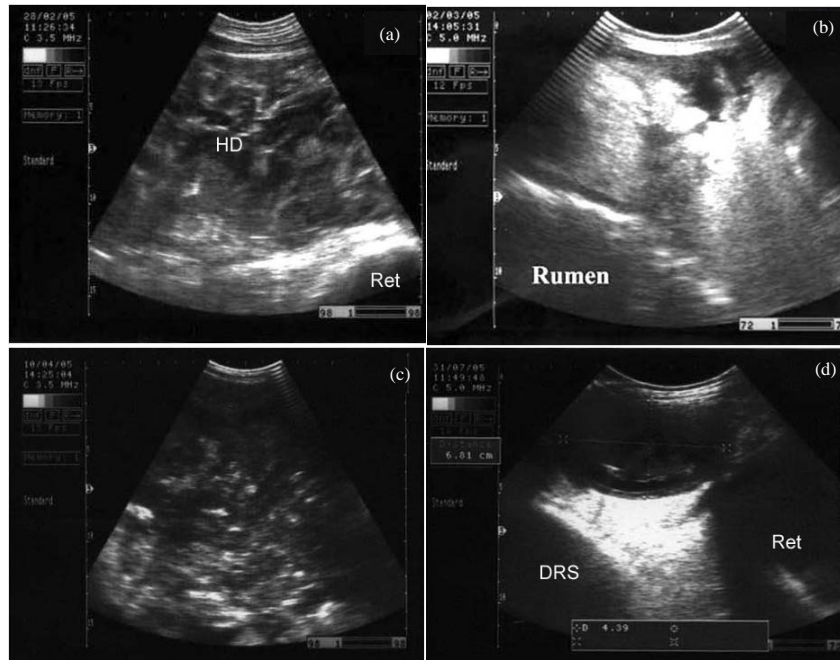


Fig. 2: Abdominal ultrasonograms in 4 buffaloes with chronic peritonitis; a) Between left ventral abdominal wall and the reticulum showing heterogeneous deposits with fluid pockets (traumatic reticuloperitonitis); B) The left ventral abdomen visualizing massive hyperechoic deposits with fluid pockets (traumatic reticuloperitonitis); c) The left ventral abdomen demonstrating massive amount of hyperechoic fibrin deposits with fluid pockets (ruminal adhesions); d) was taken at the left ventral thorax showing reticular abscessation with heterogeneous contents and anechoic capsule (reticular abscess). Ret = Reticulum; HD = Heterogeneous Deposits; DRS = Dorsal Ruminal Sac

abscess (Fig. 3d and f), a cow with purulent peritonitis (Fig. 3c and e) and a buffalo with traumatic reticuloperitonitis and reticular abscesses.

Seven different lesions in the peritoneum of buffaloes and cattle were diagnosed ultrasonographically; fibrinous peritonitis, reticular abscess with/out peritoneal effusion, purulent peritonitis, adhesions due to traumatic reticuloperitonitis, ruptured reticular abscess with accumulation of pus in the peritoneal cavity and peritoneal abscess. Clinical signs were very nonspecific. Ultrasonographic diagnosis was confirmed in five cases on necropsy.

Painful lesions involving the lungs (pleurisy, pneumonia), heart (endocarditis) and peritoneum (traumatic reticulitis, focal peritonitis) have been cited to be difficult to differentiate on clinical examination alone (Radostits *et al.*, 2007; Scott, 2008).

A significant neutrophilic leukocytosis, hypoalbuminemia and hyperglobulinemia were the obvious hematological and biochemical changes. They may help in diagnosis of peritonitis. It has been reported that total and differential leukocyte count is a useful aid in the diagnosis of peritonitis and in assessing its severity

(Radostits *et al.*, 2007). Currently, modern portable ultrasound machines provide the veterinary practitioner with an inexpensive, non-invasive tool to examine certain internal structures (Braun, 2008; Scott, 2008). The ultrasonographic techniques have been used for examination of the reticulorumen (Braun, 2009a) for diagnosis of abdominal and thoracic abscesses (Mohamed and Oikawa, 2007) for diagnosis of traumatic pericarditis in cattle (Schweizer *et al.*, 2003; Braun, 2008) and have been evaluated to be the method of choice for imaging and characterizing pericardial effusion (Buczinski, 2009). Results of the present study revealed that clinical signs of chronic peritonitis were not sufficient to reach a diagnosis while ultrasonography was effective in reaching a precise diagnosis. Medical treatment was not successful.

The ultrasonograms of the peritoneal effusion in buffaloes and cattle of the present study was similar to the result of another study in cattle (Braun, 2003). It has been cited that peritoneal effusion might be considerable and extended to the caudal abdomen and depending on the fibrin and cell content, the fluid may be anechoic or hypoechogenic. Fibrinous deposits have

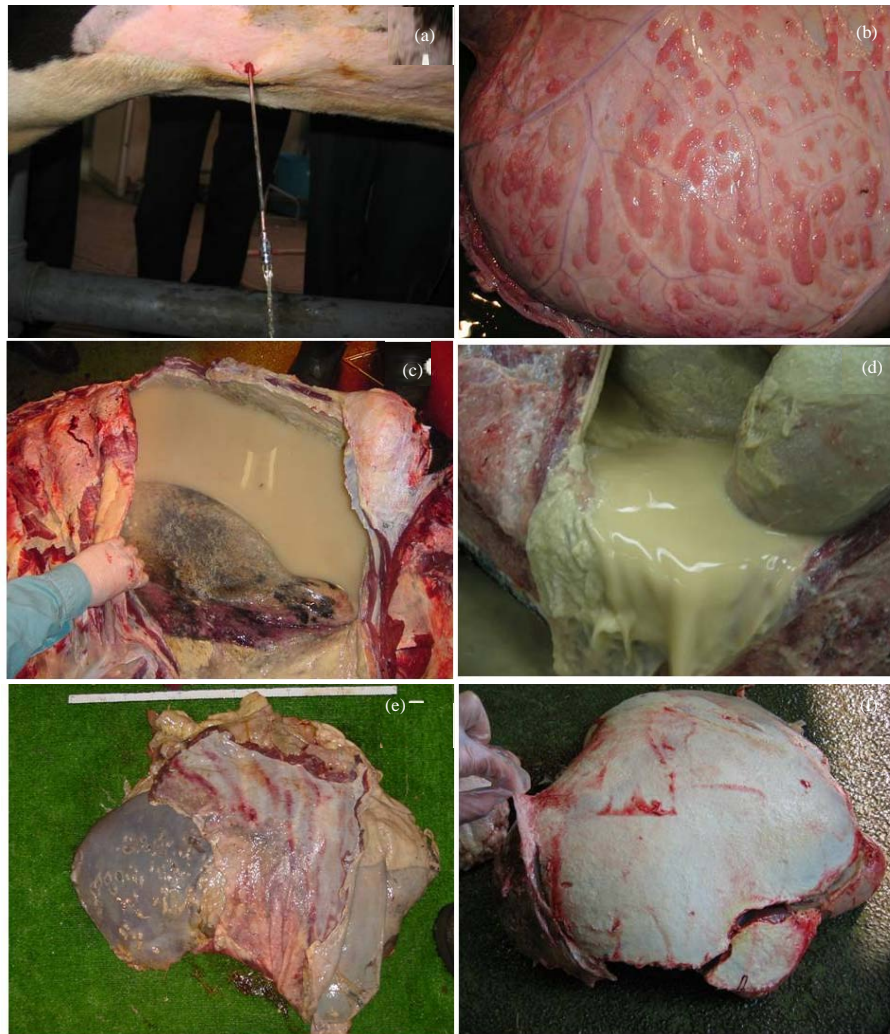


Fig. 3: Abdominocentesis of: a) A cow with peritoneal effusion; b) A buffalo with fibrinous peritonitis; c) A cow with purulent peritonitis 30 days after rumenotomy operation; d) A cow with ruptured reticular abscess and pus fills the peritoneal cavity; e) Liver of the case in (c) covered with fibrin sheath; f) Another liver of the case in (d) covered with fibrin sheath

been reported to be easily identified in the fluid and sometimes, bands of fibrin are shown within the effusion (Braun, 2003).

In another study, acute local, chronic local, acute diffuse peritonitis, reticular abscesses, thoracic abscesses and pericarditis have been detected as sequelae of traumatic reticuloperitonitis in cows and buffaloes (Abdelaal *et al.*, 2009). It has been cited that perforation of the reticular wall by a sharp foreign body initially produces an acute local peritonitis that may recover, spread to cause acute diffuse peritonitis, become persistent to cause chronic peritonitis or may extend beyond the peritoneum and cause involvement of other

organs such as pericardium to cause acute pericarditis (Radostits *et al.*, 2007). The sonographic picture of the reticular abscesses has been described in cattle (Braun *et al.*, 1998) which was similar to the results of the present study. Additionally, it has been reported that it is possible to drain abscesses through an ultrasound guided transcutaneous incision (Braun *et al.*, 1998). However, the abscess must be immediately adjacent to and attached to the abdominal wall and the intercostal space over the abscess must be large enough (Braun, 2003). In the current study, the surgical intervention using ultrasound-guided aspiration of reticular abscesses was successful. Reticular abscesses were shown at the caudoventral

aspect of the reticulum in the animals of the present study. Results of another study have found that reticular abscesses in cattle are usually caudoventral to the reticulum but may be cranial or lateral to the reticulum (Braun *et al.*, 1998).

Chronic peritonitis and adhesions in animals of the present study was possibly a sequellae of traumatic reticuloperitonitis. Traumatic reticuloperitonitis and its sequellae have been reported to be well-recognized conditions in bovines (Ward and Ducharme, 1994; Braun, 2009a, b). The syndrome has been cited to be extremely common in the developing countries possibly due to the unorganized small-scale farming and the unsatisfactory standards of animal management and feeding (Saleh *et al.*, 2008). Traumatic reticuloperitonitis is a relatively common reason for abdominal surgery in cattle and buffaloes (Abdelaal *et al.*, 2009).

In cattle with traumatic reticuloperitonitis, ultrasonography has been used to identify morphological changes in the region of the cranial, ventral or caudal reticular wall (Braun *et al.*, 1993). Fibrinous deposits found at the ultrasonograph of animals of the present study were found between the reticulorumen and abdominal wall. The caudoventral reticular wall has been reported to be the most frequently affected, often in association with the craniodorsal blind sac of the rumen. Deposits of fibrinous tissue interspersed with fluid pockets have been frequently seen on the reticular serosa (Braun, 2003).

Necropsy findings were confirmative for the ultrasonographic findings in buffaloes and cattle of the present study. Postmortem examination and other diagnostic tools have been used to confirm the ultrasonographic findings in cattle and buffaloes with thoracic and abdominal abscesses (Mohamed, 2010), traumatic pericarditis (Braun, 2008; Scott, 2008; Mohamed, 2010) and sequellae of traumatic reticuloperitonitis (Abdelaal *et al.*, 2009).

CONCLUSION

This study shows that ultrasonography is feasible diagnostic tool for different forms of chronic peritonitis in buffaloes and cattle. Clinical signs and laboratory findings are nonspecific. Necropsy findings confirmed the sonographic findings. Surgical intervention has a better success rate than medicinal treatment.

REFERENCES

Abdelaal, A.M., M. Floeck, S. El-Maghawry and W. Baumgartner, 2009. Clinical and ultrasonographic differences between cattle and buffaloes with various sequellae of traumatic reticuloperitonitis. *Vet. Med.*, 54: 399-406.

Braun, U., 2003. Ultrasonography in gastrointestinal disease in cattle. *Vet. J.*, 166: 112-124.

Braun, U., 2004. Diagnostic ultrasonography in bovine internal diseases. Proceedings of the 23rd World Buiatrics Congress, July 11-16, 2004, Quebec, Canada, pp: 11-16.

Braun, U., 2008. Clinical findings and diagnosis of thrombosis of the caudal vena cava in cattle. *Vet. J.*, 175: 118-125.

Braun, U., 2009a. Traumatic pericarditis in cattle: Clinical, radiographic and ultrasonographic findings. *Vet. J.*, 182: 176-186.

Braun, U., 2009b. Ultrasonography of the gastrointestinal tract in cattle. *Vet. Clin. North Am. Food Anim. Pract.*, 25: 567-590.

Braun, U., M. Gotez and O. Marmier, 1993. Ultrasonographic findings in cows with traumatic reticuloperitonitis. *Vet. Rec.*, 133: 416-422.

Braun, U., U. Iselin, C. Lischer and E. Fluri, 1998. Ultrasonographic findings in five cows before and after treatment of reticular abscesses. *Vet. Rec.*, 142: 184-189.

Buczinski, S., 2009. Cardiovascular ultrasonography in cattle. *Vet. Clin. North Am. Food Anim. Pract.*, 25: 611-632.

Kaneko, J.J., J.W. Harvey and M.L. Bruss, 1997. *Clinical Biochemistry of Domestic Animals*. 5th Edn., Academic Press, San Diego, California, ISBN-13: 9780123963055, Pages: 932.

Mohamed, T. and S. Oikawa, 2007. Ultrasonographic characteristics of abdominal and thoracic abscesses in cattle and buffaloes. *J. Vet. Med. A.*, 54: 512-517.

Mohamed, T., 2010. Clinicopathological and ultrasonographic findings in 40 water buffaloes (*Bubalus bubalis*) with traumatic pericarditis. *Vet. Rec.*, 167: 819-824.

Negrini, S., S. Valentini, G. Spinella and M. Fedrigo, 2003. Peritoneal ultrasonography in dogs and cats. *Vet. Res. Commun.*, 27: 411-414.

Radostits, O.M., C.C. Gay, K.W. Hinchcliff and P.D. Constable, 2007. *Veterinary Medicine: A Textbook of the Diseases of Cattle, Sheep, Pigs, Goats and Horses*. 10th Edn., WB Saunders Co., London, Toronto, ISBN-10: 0702027774.

Radostits, O.M., I.G. Mayhew and D.M. Houston, 2000. *Veterinary Clinical Examination and Diagnosis*. W.B. Saunders, London, ISBN-13: 9780702024764, Pages: 771.

Reef, V.B., 2003. Recent Advances in Equine Abdominal Ultrasonography of the Foal. Proceedings of the 8th Congress on Equine Medicine and Surgery, February 1, 2003, International Veterinary Information Service, Ithaca, New York, USA.

Rosenberger, G., 1990. *Die Klinische Untersuchung des Rindes*. 3rd Edn., Paul Parey, Berlin and Munich.

- Saleh, M.A., H.Z. Rateb and N.A. Misk, 2008. Comparison of blood serum proteins in water buffaloes with traumatic reticuloperitonitis and sequellae. *Res. Vet. Sci.*, 85: 208-213.
- Schweizer, T., T. Sydler and U. Braun, 2003. Cardiomyopathy, endocarditis valvularis thromboticans and pericarditis traumatica in cows-clinical and echocardiographical findings in three cases. *Schweiz Arch Tierh.*, 145: 425-430.
- Scott, P., 2008. The role of ultrasonography as an adjunct to clinical examination in cattle practice. *Irish Vet. J.*, 61: 256-260.
- Stewart, A.J., 2006. Actinobacillus pleuritis and peritonitis in a quarter horse mare. *Vet. Clin. North Am. Equine Pract.*, 22: e77-93.
- Ward, J.L. and N.G. Ducharme, 1994. Traumatic reticuloperitonitis in dairy cows. *J. Am. Vet. Med. Assoc.*, 204: 874-877.