

## Comparison of Classic, Theranekron and Classic-Plus Theranekron Treatment on the Foot and Mouth Disease Lesions in Cattle in Van, Diyarbakir and Ankara Regions in Turkey

<sup>1</sup>Erkan Duz, <sup>2</sup>Hasan Icen, <sup>3</sup>Neval B. Arserrim, <sup>4</sup>Firat Cakmak,  
<sup>5</sup>Bahtiyar Bakir and <sup>6</sup>Ersin Uysal

<sup>1</sup>Department of Animal Health, Gevas Occupational High School,  
Yuzuncu Yil University, Van, Turkey

<sup>2</sup>Department of Internal Medicine, <sup>3</sup>Department of Microbiology,  
Veterinary Faculty, Dicle University, Diyarbakir, Turkey

<sup>4</sup>Provincial Directorate of Agriculture, Diyarbakir, Turkey

<sup>5</sup>Healty Services Vocational Collage, Gazi University, Golbasi, Ankara, Turkey

<sup>6</sup>Department of Computer Tech. Programs,  
Diyarbakir Vocational School, Dicle University, Diyarbakir, Turkey

---

**Abstract:** The study compared the influence of *Tarantula cubensis* extract 1:100/D2 (Theranekron<sup>®</sup>, Richter Pharma, Austria) and classic treatment (daily injection of flunixin meglumin, oxytetracycline, washing the mucosa and feet lesions with 10% sodium bicarbonate and antibiotic spray for 3 consecutive days) for the oral, hoof and mammary lesions treatment in foot and mouth disease in cattle. Ninety mixed breed cattle with foot and mouth diseases were used. Clinical symptoms included fever inappetance oral, hoof and mammary lesions. The cattle were divided into three groups. The first group, the second and the third were treated with classic, theranekron and theranekron plus classic treatments respectively. About 48 h after theranekron and theranekron plus classical application, recovery occurred and body temperature, appetite returned to normal more rapidly than that of the group on which only classical treatment methods were used.

**Key words:** FMD, cattle, oral, hoof, mammary, lesions, Theranekron

---

### INTRODUCTION

Foot and mouth disease is a highly contagious viral infection in domestic and wild cattle, sheep, goats and pigs. It spread not only with direct contact between infected and susceptible animals and but also indirectly with windborne spread and dissemination of the virus from animal contaminated products (Davies, 2002; Alexandersen *et al.*, 2003) and through birds and rodents. They carry it to distant with their wings. Movement of animals is the main reason for spreading the said disease (Abdalla *et al.*, 2005).

It is characterized by the formation of vesicles followed by erosions in the mucosa of the mouth, external nares and skin between and above the hoof and on the teats, fever, depression, off feed, excessive salivation, smacking of lips, drooling and mastitis (Kitching, 2002). Its incubation period is 1-5 days or longer. Virus can be separated into seven immunologically and serologically distinct types, namely Types O, A and C, Southern

African Territories (SAT-1-SAT-3) and Asia-1 (Icen *et al.*, 2011; Dukpa *et al.*, 2011; Grubman and Baxt, 2004). There is no cross-protection between virus types (Gurhan *et al.*, 1999). In most outbreaks, the morbidity rate approaches 100% (Lotfollahzadeh *et al.*, 2007). Since, foot and mouth disease has a viral origin, recovery from the disease takes long time and results significant economic losses which is caused by high morbidity in adult and high mortality in young animals and loss of production in others (Senturk and Yalcin, 2008). Diseases that have a viral origin may benefit from alternative medicine such as homeopathy. Many topical and systemic formulas were applied treat open wounds but most products which were applied on domestic animals either did not affect wound healing or inhibit rather than enhancing it (Sardari *et al.*, 2007; Stampa, 1986). Theranekron<sup>®</sup> (Richterpharma, Wels, Austria) is an alcoholic extract of the venom of *Tarantula cubensis* which remains active in pharmaceutical compounds for a considerable time. Many systematic effects such as antiphlogistic, demarcative,

necrotizing action were described for Theranekron (Stampa, 1986; Aldabagah *et al.*, 2011) but there are few reports on Theranekron effects about wound healing in farm animals. Several researchers described the homeopathic effects of Theranekron (Stampa, 1986).

In a study Theranekron was used in cattle, horses, sheep, goats and dogs (Albay *et al.*, 2010). Data gained from a research literature and surveillance study also, confirmed that Theranekron can be successfully applied on cows for demarcation of necrotic tissue, enhanced granulation of infection, necrotic wounds and especially for the retention of placenta and pododermatitis circumscripta (Gurubulak *et al.*, 2010). In dogs, Theranekron was used for conservative therapeutic intervention in cases of mammary tumors and oral papillomatosis (Aldabagah *et al.*, 2011).

This study has been conducted to evaluate comparison of classic treatment methods and therapeutic effects of theranekron and classic treatment plus theranekron on the foot and mouth disease lesions in cattle in Van, Diyarbakir and Ankara regions.

## MATERIALS AND METHODS

Ninety bovine cases with symptoms of vesicles in the mouth, on the feet and on the teats, fever and drop in milk yield as a result of FMD constituted the materials of this study. In this study, 30 naturally infected cattle of 3-5 age group were collected from Diyarbakir, 30 cattle with the said qualifications collected from Van Gevas and 30 cattle with the same qualifications were collected from Ankara. The treatment was immediately started so as to get virologic results. The cattle were divided into 3 groups and encountered to three different treatment options. The 1st group was treated with classic treatment while the 2nd and 3rd groups were treated with theranekron and Theranekron+classic treatment methods, respectively. Classic treatment method includes daily injection of antiinflammatory (flunixin meglumin, Fluvil Vilsan 1.1 mg kg<sup>-1</sup>, IM), antibiotic (oxytetracycline, Primamycin LA, Pfizer, 20 mg kg kg<sup>-1</sup>, IM) washing the mucosa and feet lesions with 10% sodium bicarbonate and antibiotic spray (Tiamphenicol+Cetrimide+Gention Viole, Piyedif Aerosol, CevaDif). In 2nd group *Tarantula cubensis* extract (Theranekron, 1:100/D2, 5 mL, SC, Richter Pharma, Austria) and in third group theranekron and classic treatment method were applied. All of the animals had observed before treatment and they were also observed within 48 h after the application of drugs on the 5th day after the application of the drugs and on the 10th day after application of rugs and clinical signs of animals were recorded. Clinical examinations (heart rate and rectal

temperature) and visual scoring of appetite (No = 1, little = 2, good = 3, very good = 4) oral, hoof and mammary lesions (0 = complete healing (no lesion), 1 = slightly, 2 = moderately and 3 = severely) were performed before treatment and within 48 h after the application of drug on the 5th and 10th days after treatment in all animals. For virological analysis samples were sent to Foot and Mouth Institute by provincial directorate of agriculture.

**Statistical analysis:** Mean values of heart rate and rectal temperature of infected cattle in all groups were statistically analyzed by using the t-test and median values of oral, hoof and mammary lesions in three groups were analyzed by Mann-Whitney U test using the Statistical Software SPSS 15. The p<0.05 was considered to be significant.

## RESULTS AND DISCUSSION

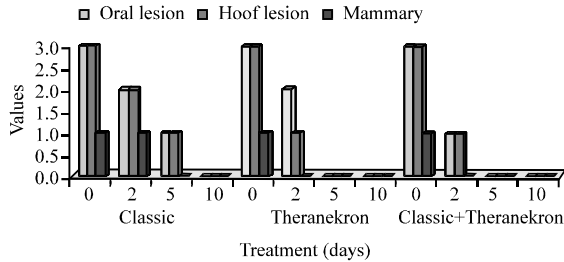
Affected animals showed symptoms of loss of appetite, fever oral lesions, excessive salivation, lameness due to feet lesions and unwilling to move or get up. Ulcers were most commonly detected in mouth interdental space and on mammary glands. The mean value of heart rate in all groups during study was not significantly different while significant decrease in the rectal temperature was observed in all group 48 h after the treatment compared to the values obtained before treatment. Appetite in Theranekron and Classic plus Theranekron Treated group were completely fine after 48 h while in classic treatment group they were slightly fine after 48 h and completely fine on the 5th day. Vesicles in mucosa membranes of mouth in classic treatment group decreased and disappeared in the 10th day while in theranekron and classic plus theranekron treated group, it disappeared during 48 h after treatment. Hoof lesions in Theranekron and Classic plus Theranekron Treated groups recovered slightly after 48 h and completely on the 5th day. But in classic treatment group they recovered slightly in 5 days and completely in 10 days. Mammary lesions in Theranekron and Classic plus Theranekron Treated group recovered completely in 48 h meanwhile in classic treatment group they recovered slightly after 48 h and completely in 5 days as shown in Table 1 and Fig. 1. Results of virologic analysis were positive O and A for Diyarbakir region asail for Van region and A for Ankara region.

Foot and mouth disease is a highly contagious, usually non-fatal viral disease of domestic and wild cloven-hoofed animals but may also affect certain other species. It is widely distributed throughout the world. Animals recovered from the disease may remain as carriers of the infectious virus for an extended period of time

**Table 1: Classic and Theranekron and Classic treatment plus theranekron treatment on the foot and mouth disease lesions**

Symptoms	Classic treatment (n = 30) (days)				Theranekron treatment (n = 30) (days)				Classic + Theranekron (n = 30) (days)			
	0	2	5	10	0	2	5	10	0	2	5	10
Heart rate	80+2.0	75+ 1.9	72+1.05	74+1.1	78+2.2	72+1.7	70+1.08	741+2.2	82+2.2	75+1.7	76+1.2	74+1.1
Fever	39.8+0.7	38.5+0.4*	39.0+0.2*	39.1+0.4*	39.8+0.8	38.8+0.6*	39.1+0.4	38.6+0.6	40.1+0.4	38.2+0.6*	38.5+0.6*	38.8+0.3*
Oral lesion	3 (1-3)	2 (1-3)	1 (1-2)*	0 (0)**	3 (2-3)	2 (1-2)*	0 (0-1)**	0 (0)**	3 (2-3)	1 (1-2)	0 (0-1)**	0 (0)**
Hoof lesion	3 (1-3)	2 (1-3)	1 (1-3)*	0 (0-1)**	3 (1-3)	1 (1-2)*	0 (0-1)**	0 (0)**	3 (1-3)	1 (0-2)*	0 (0-2)**	0 (0)**
Mammary lesion	1 (1-2)	1 (0-1)	0 (0)*	0 (0)*	1 (0-2)	0 (0-1)*	0 (0)*	0 (0)*	1 (0-2)	0 (0-1)*	0 (0)*	0 (0)*
Appetite	1 (1-2)	2 (1-2)	3 (2-3)*	4 (2-4)*	1 (1-2)	3 (2-3)*	3 (3)*	4 (3-4)**	1 (1-2)	3 (2-4)*	4 (3-4)**	4 (3-4)**

\*p<0.05, \*\*p<0.01



**Fig. 1: Classic and Theranekron and Classic treatment plus Theranekron treatment on the foot and mouth disease lesions**

(Longjam *et al.*, 2011; Stenfeldt *et al.*, 2011). FMD resulted in serious losses, predominantly among high-producing livestock raised under increasingly intensive systems (Sugiura *et al.*, 2001). As the economic effects of the disease and the difficulties about controlling it became apparent, concerted efforts for eradicating it were undertaken (Howlander *et al.*, 2004; Suttmoller *et al.*, 2003). For this reason there are vaccines available but there are limitations to their usage. This is a main case because the virus is continuously mutating; therefore, different strains are produced (Garland, 1999). Many countries decide to destroy all infected animals and those which have been in contact with these animals. In addition in most of developed countries, the immediate response to an outbreak, especially if it is localized is stamping out which is carried out as quickly as possible. A quarantine area should immediately be declared and enforced around the affected area (Remond *et al.*, 2002). FMD has been one of the most important diseases causing significant economic losses in the Turkish livestock sector. Together with production losses, export restrictions for several agricultural products cause additional losses to the Turkish economy (Klein *et al.*, 2006). In Turkey, the immediate response for FMD can be setting a quarantine zone within 3 km<sup>2</sup>, disinfection, burning exit and entrance, ring vaccination, stamping out. The animals which are in the quarantine zone should be treated with classic treatment until they are recover completely. In fact, there is no specific treatment for FMD. Also, the treatment of FMD is primarily only considered for endemic areas.

Considerations in these endemic regions include quarantine, local eradication, virus typing and revaccination of at-risk and contact animals. Appropriate supportive care should include soft feeds and antimicrobials to prevent secondary bacterial infection. Although, most adults survive, weight loss, loss of milk production and abortion may eventually lead to culling (Anderson and Rings, 2009). Some of the drug solutions that have been used for treatment of bovine foot and oral ulcer as a result of FMD include copper sulphate, oxytetracycline with gentian violet spray and formalin and trichloroacetic acid spray (Aldabagah *et al.*, 2011; Sardari *et al.*, 2007). Little success has been reported for the use of these solutions. Also, homeopathy is used as an alternative treatment. In this study, the effects of Theranekron on the treatment of oral, hoof and mammary lesions of FMD were determined. Some reports stated that Theranekron has beneficial effects for the recovery of cow hoof oral and vaginal injuries (Stampa, 1986; Mwiine *et al.*, 2010). In this study, significant differences were observed in oral, hoof and mammary lesion and fever and appetite (p<0.05). Present treatment schedule is in agreement with Lotfollahzadeh *et al.* (2007) and also with theranekron treatment applied by Sardari *et al.* (2007).

**CONCLUSION**

According to the results of the this study, Theranekron and Theranekron plus classic treatment resulted in rapid recovery within 48 h after drug application in oral, hoof and mammary lesions of FMD more than only classic treatment and thus may be regarded as an adjunct remedy in the treatment of FMD by means of being practicing by veterinarians in endemic area. In addition, the vaccines must be type-specific and should be repeated 2 or 3 times a year.

**REFERENCES**

Abdalla, A., S. Beare, L. Cao, G. Garner and A. Heaney, 2005. Foot and mouth disease: Evaluating alternatives for controlling a possible outbreak in Australia. ABARE a Report 5.6, Canberra, April 2005.

- Albay, M.K., S. Sahinduran, M. Kale, M.C. Karakurum and K. Sezer, 2010. Influence of *Tarantula cubensis* extract on the treatment of the oral lesions in cattle with bluetongue disease. *Kafkas Univ. Vet. Fak. Derg.*, 16: 593-596.
- Aldabagah, I.I., O.S. Al-Obaddy and I.H. Al-Sadi, 2011. Trichloroacetic acid spray for the treatment of foot ulcers of foot and mouth disease in cattle. *Pak. Vet. J.*, 32: 136-137.
- Alexandersen, S., Z. Zhang, A.I. Donaldson and A.J.M. Garland, 2003. Review: The pathogenesis and diagnosis of foot-and-mouth disease. *J. Comp. Pathol.*, 129: 1-36.
- Anderson, D.E. and M. Rings, 2009. Current Veterinary Therapy, Food Animal Practice. 5th Edn., W.B. Saunders Company, London, pp: 4-5.
- Davies, G., 2002. Foot and mouth disease. *Res. Vet. Sci.*, 73: 195-199.
- Dukpa, K., I.D. Robertson and T.M. Ellis, 2011. The seroprevalence of foot-and-mouth disease in the sedentary livestock herds in four districts of Bhutan. *Prev. Vet. Med.*, 100: 231-236.
- Garland, A.J.M., 1999. Vital elements for the successful control of foot-and-mouth disease by vaccination. *Vaccine*, 17: 1760-1766.
- Grubman, M.J. and B. Baxt, 2004. Foot and mouth disease. *Clinical Microbiol. Rev.*, 17: 465-493.
- Gurhan, S.I., B. Gurhan, G. Aynagoz, N. Unal and G. Unver, 1999. Characterization of monoclonal antibodies against foot and mouth disease virus and determination of antigenic variations in field strains. *Tr. J. Vet. Anim. Sic.*, 23: 403-408.
- Gurubulak, K., S. Yildiz, E. Beytut, S. Bademkiran and M. Pancarci *et al.*, 2010. Efficacy of UT forte and theranekron on retained placenta in cows. *Indian Vet. J.*, 87: 1267-1269.
- Howlader, M.M.R., A.T.M. Mahbub-E-Elahi, S. Habib, M.J.U. Bhuyian, M.A.B. Siddique, M.A. Hai and M.G. Hossain, 2004. Foot and mouth disease in baghabari milk shed area and its economic loss in Bangladesh. *J. Biological Sci.*, 4: 581-583.
- Icen, H., S. Sekin, A. Simsek, A. Kochan and S. Tunik, 2011. The Efficacy of *Tarantula cubensis* Extract (Theranekron) in Treatment of Canine Oral Papillomatosis. *Asian J. Anim. Vet. Adv.*, 6: 744-749.
- Kitching, R.P., 2002. Clinical variation in foot and mouth disease: Cattle. *Rev. Sci. Tech.*, 21: 499-504.
- Klein, J., U. Parlak, F. Ozyoruk and L.S. Christensen, 2006. The molecular epidemiology of Foot-and-mouth disease virus serotypes A and O from 1998 to 2004 in Turkey. *BMC Vet. Res.*, 2: 1-13.
- Longjam, N., R. Deb, A.K. Sarmah, T. Tayo, V.B. Awachat and V.K. Saxena, 2011. A brief review on diagnosis of foot-and-mouth disease of livestock: Conventional to molecular tools. *Vet. Med. Int.*, 10.4061/2011/905768.
- Lotfollahzadeh, S., M. Alizadeh and M. Dezfouli, 2007. A study on therapeutic effects of Theranekron (*Tarantula cubensis* poison extract) on the Foot and Mouth Disease (FMD) lesions in cattle. Proceedings of the 7th National Veterinary Internal Medicine Congress, September 1-4, 2007, Kemer-Antalya, Turkey.
- Mwiine, F.N., C. Ayebazibwe, S. Alexandersen, W.O. Mukani, A.R.O. Ademun and K. Tjornehoj, 2010. Seroepidemiological investigation of foot-and-mouth disease virus serotypes in cattle around Lake Mburo National Park in South-Western Uganda. *J. Vet. Med. Anim. Health*, 2: 46-54.
- Remond, M., C. Kaiser and F. Lebreton, 2002. Diagnosis and screening of foot-and-mouth disease. *Comparative Immunol. Microbiol. Infectious Dis.*, 25: 309-320.
- Sardari, K., E.G. Kakhki and M. Mohri, 2007. Evaluation of wound contraction and epithelialization after subcutaneous administration of Theranekron® in cows. *Comp. Clin. Pathol.*, 16: 197-200.
- Senturk, B. and C. Yalcin, 2008. Production losses due to endemic foot-and-mouth disease in cattle in Turkey. *Turk. J. Vet. Anim. Sci.*, 32: 433-440.
- Stampa, S., 1986. A field trial comparing the efficacy of sulphamonomethoxine, Penicillin and *Tarantula* poison in the treatment of pododermatitis circumscripta of cattle. *J. S. Afr. Vet. Assoc.*, 2: 91-93.
- Stenfeldt, C., P.M. Heegaard, A. Stockmarr, K. Tjornehoj and G.J. Elsham, 2011. Analysis of the acute phase responses of Serum Amyloid A, Haptoglobin and Type 1 Interferon in cattle experimentally infected with foot-and mouth disease virus serotype O. *Vet. Res.*, 42: 66-66.
- Sugiura, K., H. Ogura, K. Ito, K. Ishikawa, K. Hoshino and K. Sakamoto, 2001. Eradication of foot and mouth disease in Japan. *Rev. Sci. Tech. Off. Int. Epiz.*, 20: 701-713.
- Sutmoller, P., S.S. Barteling, R.C. Olascoaga and K.J. Sumption, 2003. Control and eradication of foot-and-mouth disease. *Virus Res.*, 91: 101-144.