

A Case of Colic Associated with Streptococcal Disseminated Infection in a Mare

Fulvio Laus, Vincenzo Cuteri, Emanuele Paggi, Anna Rita Attili,
Matteo Cerquetella, Silvia Preziuso and Beniamino Tesei
School of Veterinary Medical Sciences, University of Camerino,
93/95 Via Circonvallazione, 62024 Matelica (MC), Italy

Abstract: Abscessation of mesenteric lymph nodes and other tissues following *Streptococcus equi* subsp. *equi* infection is one of the most insidious complication of strangles. In fact, in a small percentage of cases, the infection may spread from respiratory tract to other organs causing significant source of pain, loss of condition and death. This type of infection, known as bastard strangles is uncommon but has a greater chance of resulting in death. Spreading may be hematogenous via lymphatic channels or via close association with a septic focus which results in abscesses in lymph nodes and other organs of the thorax and abdomen. Intermittent colic pain is expression of the abdominal cavity involvement. In the present study, researchers described clinical, instrumental, laboratory and pathological features of a severe colic case, unresponsive to treatment, determined by a *Streptococcus equi* subsp. *equi* disseminated infection in a pregnant mare, severely involving the abdominal viscera. Although, not usually study, bastard strangles demonstrated to be a potential sequelae to *S. equi* subspecies *equi* infections in the horse also in case of atypical strangles. Prompt recognition of atypical manifestations and sequelae to *S. equi* are needed to identify, treat and improve the prognostic outcome.

Key words: Horse, strangles, abscesses, PCR, streptococcus, sequelae

INTRODUCTION

Colic is one of the most common reason for horses hospitalization and represent a diagnostic challenge for veterinarians. Among the so called atypical colic, the abscessation of mesenteric lymph nodes and other tissues following *Streptococcus equi* subsp. *equi* infection is one of the most insidious. This is a chronic, progressive syndrome and clinical signs can develop months after infection (Slater, 2007).

Streptococcal infection are still one of the most significant cause of respiratory diseases in horse, highly contagious and with a wide distribution (Slater, 2007). In a small percentage of cases, the infection may spread from respiratory tract to other organs causing significant source of pain, loss of condition and death (Sweeney *et al.*, 1987). This type of infection known as bastard strangles is uncommon but has a greater chance of resulting in death (Sweeney *et al.*, 1987; Bell and Smart, 1992).

Although, strangles predominantly involves the upper airways including the guttural pouches and associated lymph nodes, metastasis to other locations occasionally occurs. Spread may be hematogenous, via lymphatic channels or via close association with a septic

focus which results in abscesses in lymph nodes and other organs of the thorax and abdomen. Metastasis to the brain has also been recorded (Spoomakers *et al.*, 2003).

Intermittent colic pain is expression of the abdominal cavity involvement. In the present study researchers described clinical, instrumental, laboratory and pathological features of a severe colic case, unresponsive to treatment, determined by a *Streptococcus equi* subsp. *equi* disseminated infection in a pregnant mare, severely involving the abdominal viscera.

MATERIALS AND METHODS

An 8 years old Appaloosa pregnant mare, 400 kg in weight was referred to this hospital because of intense abdominal pain. The owners report that during the earlier week the mare was disorexic and in the last few days she showed some low intensity clinical signs, recurrent abdominal pain associated with reddish colored urine. Starting from the day before the animal became completely anorexic and signs of abdominal discomfort start to be more severe and frequent.

At clinical examination the mare was in poor nutrition state and signs of dehydration, persistent skinfold and

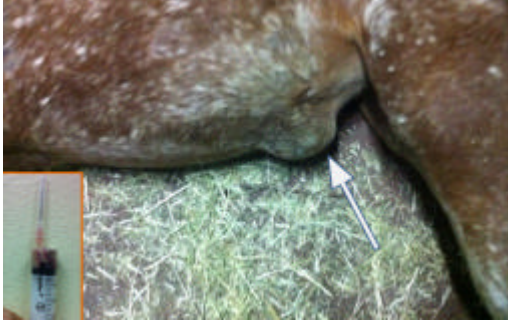

Fig 1: Ventral subcutaneous abscess and macroscopic aspect of the content (window)

dryness of mucous membranes were present. The horse was hypothermic (35.7°C), mucous membranes were slightly pale and toxic, the heart rate was 58 beats/min whereas the respiratory rate was 28 breaths/min. Arterial pulse checked at maxillary artery was accelerated and weak. Because of this critical status the mare was hospitalized.

In the ventral part of abdominal region, at level of the umbilical scar, an hemispherical swelling of about 15 cm in diameter was present. At palpation the swelling was normally warm, not painful and firm (Fig. 1). Fine needle aspiration revealed the presence of very thick purulent material mixed with blood (Fig. 1). An aliquote was used for microbiological analysis.

At rectal examination there were no abnormalities of the gastrointestinal tract except for the completely empty descending colon. On the left side of the abdominal cavity, laterally to the aorta and positioned slightly caudal and medial to the caudal pole of the left kidney, a big mass were detected. The mass was as large as a rugby ball, firm and with a smooth surface and laterally was in contact with the spleen. At palpation the mare showed severe signs of induced pain. The fetus was live and in good condition with an estimated age of 7 months.

Trans-rectal ultrasonographic examination revealed the mass as a collection of heterogeneous fluid with anechoic areas containing small hyperechoic, fluctuant particles and more echoic areas probably representatives of more consolidate or organized material (Fig. 2). The same appearance was displayed by the transcutaneous window at left paralumbar fossa level. A little amount of anechoic fluid was present in peritoneal cavity. Ultrasonographic diagnosis of retroperitoneal, pararenal abscess was made. Ultrasonography confirmed that the abscess was in contact with the caudal pole of the left kidney and spleen. Small hypoechoic areas were ultrasonographically detected on the right lobe of the liver. Blood samples for emocromocitometric and

Table 1: The results of blood and serum analysis

Parameters	Values
WBC (K μL^{-1})	32.000
NEU (%)	94.200
Lym (%)	1.680
Mono (%)	3.950
Eos (%)	0.010
Baso (%)	0.160
RBC (M μL^{-1})	7.750
HGB (g dL^{-1})	11.100
HCT (%)	32.500
MCV fL	41.900
MCH pg	14.300
MCHC(g dL^{-1})	34.200
RDW (%)	22.300
PLT (K μL^{-1})	201.000
MPV fL	7.190
PCT (%)	0.150
PDW 10 (GSD)	18.300
Glu (mg dL^{-1})	117.700
AST (UI L^{-1})	2118.000
BUN (mg dL^{-1})	322.300
GGT (UI L^{-1})	2179.000
AIP (UI L^{-1})	51.940
Crea (mg dL^{-1})	12.180
TP (g dL^{-1})	10.160
Total. bilir. (mg dL^{-1})	8.529
Dir. bilir. (mg dL^{-1})	4.937
Ind. bilir. (mg dL^{-1})	3.592

hematochemical analysis were collected. In the following tables the results of blood and serum analysis are shown in Table 1.

Severe signs of infection were highlighted by the marked increasing of white blood cells number and the raising in percentage of neutrophil cells. The significant alteration of some ematochemical parameters (especially creatinine, AST, BUN and bilirubine) were indicative of renal and liver dysfunction. A presumptive diagnosis of colic caused by disseminated streptococcal infection involving the liver and the kidney was made. The owner was asked about past respiratory infections or other symptoms referable to the so-called atypical strangles. He referred that from 7-8 months before, the mare had an episode characterized by fever, anorexia, mild depression and nasal discharge. In that context, the mare had been treated with antibiotic therapy allowing a slow and gradual improvement. In the earlier years several cases of strangles occurred in the stable.

A therapy for pain control was then implemented with a first administration of butorphanol tartrate (0.05 mg kg^{-1} IV) followed by flunixin meglumine (1.1 mg kg^{-1} IV). Penicillin G (9000 UL kg^{-1}) and dihydrostreptomycin sulfate (15 mg kg^{-1}) has been intramuscularly administrated.

For few minutes the pain condition seemed to improve slightly but it started again with more intensity than before and became not controllable even after a new administration of butorphanol tartrate (0.05 mg kg^{-1} IV)

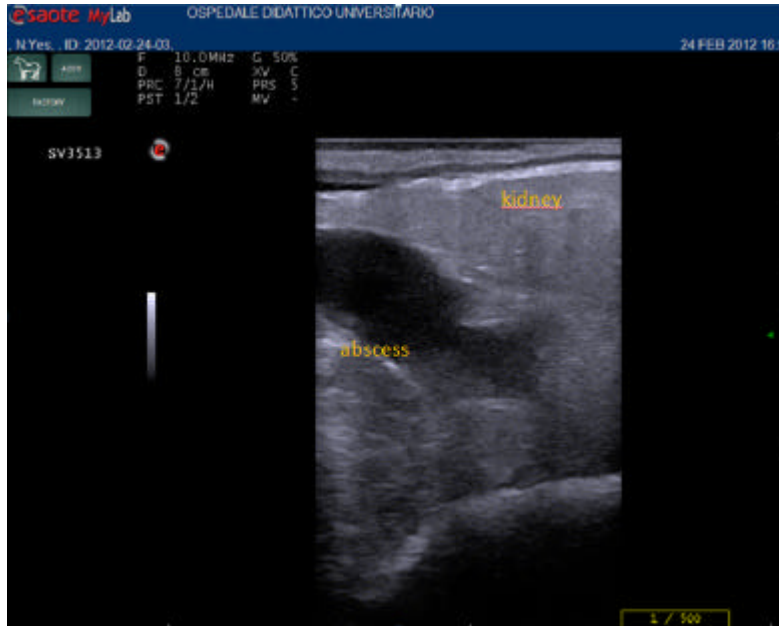


Fig. 2: Trans-rectal ultrasonographic appearance of left kidney and abscess

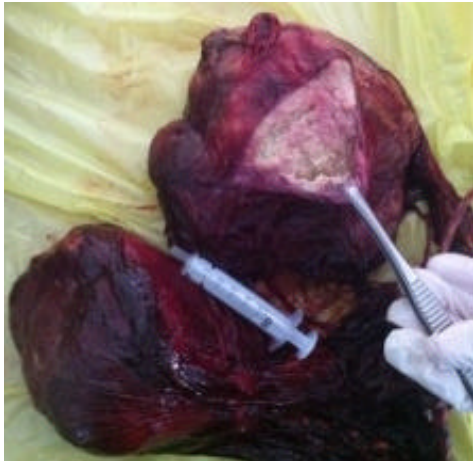

Fig. 3: Mesenteric abscesses

and morphine sulfate ($0.3 \text{ mg kg}^{-1} \text{ IM}$). After few hours the mare has been euthanatized on owner request.

At post mortem examination the ventral subcutaneous abscess did not show any communication with the abdominal cavity. The pararenal abscess contained both fluid and more dense purulent material; it was in contact with the left kidney that was larger than contralateral, decreased in consistency and showed severe signs of congestion on cut surface.

Two enlarged mesenteric lymph nodes (about 12 cm in diameter) contained inspissated pus were evidenced (Fig. 3). The liver had small disseminated abscesses on its

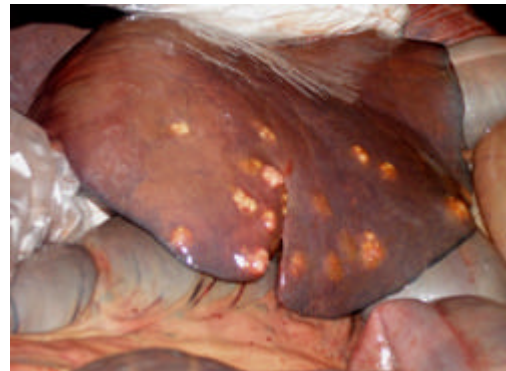


Fig. 4: Small abscesses on diaphragmatic surface of the liver

diaphragmatic surface that showed a more dense purulent content (Fig. 4). The lateral compartment of the left guttural pouches contained purulent material (Fig. 5).

Histological examination of the kidney revealed signs of severe pyelonephritis, widely and uniformly affecting the area under the renal pelvis but also extending to the tubular areas. At the level of the cortex signs of interstitial nephritis were observed with severe loss of glomerular tissue other than edema and necrosis in the juxta-glomerular portion. All abscesses, urine and the guttural pouches content was sampled to perform bacteriological examination and PCR.

Two aliquots of $200 \mu\text{L}$ of purulent material aspirated from renal pelvis, pararenal, omental, mass ventral

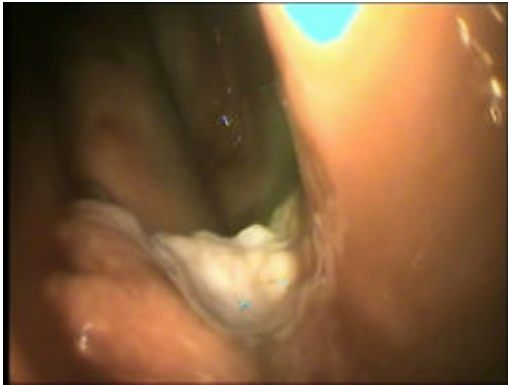

Fig. 5: Purulent material in the left guttural pouches

abscesses and urine sample were cultured on Tryptone Soya Broth (Oxoid, Milan, Italy) for 6 h under aerobic and anaerobic conditions and then subcultured on Columbia blood Agar with and without Streptococcus Selective Supplement, MacConkey Agar, Mannitol Salt Agar (Oxoid, Milan, Italy) for 24-48 h at 37°C under aerobic and anaerobic conditions. Biochemical characterization was achieved using the commercial Rapid ID32 Strep (RapID™ System, Oxoid, Milan, Italy) and API 20 Strep Systems (bioMerieux, Italy) according to the manufacturers instructions.

Gram-positive, facultative anaerobic coccus-shaped organisms were isolated in pure culture from the renal pelvis, pararenal, omental and mass ventral abscesses while urine sample resulted negative. Bacterial colonies grew on sheep blood agar as beta-hemolytic, mucoid, small (0.5-3 mm), white/gray colonies after 24 h of incubation at 37°C. The isolates were catalase and CAMP test negative and gave a positive reaction for Lancefield group C but negative reactions for the other Lancefield groups tested. All isolates displayed identical biochemical profiles that corresponded to an identification of *Streptococcus equi* subsp. *equi*.

For PCR, DNA has been purified from 20 mg of each abscesses sample and from 300 µL urine by the Genomic DNA Isolation kit (Norgen Biotek, Thorold, ON, Canada) following the manufacturers instruction and suspending the DNA in a 100 µL final volume. The DNA was tested by PCR with primers specific for the beta-haemolytic streptococci *S. equi* subsp. *equi*, *S. equi* subsp. *zooepidemicus* and *S. dysgalactiae* subsp. *equisimilis* (Laus *et al.*, 2007). To verify the absence of PCR inhibitors, universal bacterial primers flanking a fragment of the bacterial *16S rRNA* gene were used as control (forward 5-AGA GTT TGA TCM TGG CTC AG-3 and reverse 5-GCT GCC TCC CGT AGG AGT-3). A multiplex PCR protocol was used as recently described

(Prezioso and Cuteri, 2011). When the PCR products were run on 2% agarose gel, three bands were clearly evident. The internal control band was present in all the samples tested. Furthermore, the PCR products of the fthis abscesses showed both the 235 and the 520 bp bands, demonstrating the presence of *S. equi* subsp. *equi* in all abscess samples but not in the urine. *S. equi* subsp. *equi* was identified also by multiplex PCR on DNA purified from the beta-haemolytic streptococcal colonies cultured on blood agar.

RESULTS AND DISCUSSION

In the present case, a severe colic due to disseminated infection caused by *Streptococcus equi* subsp. *equi* was diagnosed. *Ante mortem* diagnosis was made on the basis of clinical features (subcutaneous abscesses and masses detected at rectal examination) and ultrasonographic appearance of the masses. Microbiological and PCR investigations confirmed a disseminated *S. equi* subspecies *equi* infection. The presence of the fetus made not possible to palpate the enlarged mesenteric lymph nodes. Renal involvement was ascertained by means of palpation, ultrasonography and abnormal color of urine and was confirmed by the high value of creatinine in serum. Hepatic lesions were not enough diffuse to cause the onset of related clinical symptoms but liver enzymes were abundantly higher than normal.

Strangles is a common infectious disease of equidae. Animals affected by the classic form show fever, depression, anorexia, nasal discharge and abscessation of submandibular and retropharyngeal lymph nodes. In some cases, the drainage of retropharyngeal abscesses in the guttural pouches can lead to the formation of empyema. Complication includes purpura hemorrhagica, an immune mediated aseptic vasculitis and bastard strangles, the metastatic dissemination of infection to abdominal and thoracic tissue. Besides to these well known forms, exists the possibility of a transient self-limiting infection, very similar to viral infections of the upper respiratory tract, called atypical strangles being clinically characterized by pyrexia, depression, lymph node enlargement and nasal discharge (Grant *et al.*, 1993; Slater, 2007). This study describe it could be possible that the abscessation of lymph nodes was misdiagnosed during the episode of atypical strangles occurred some months before hospitalization. This assumption is confirmed by the fact that post-mortem examination revealed the empyema of guttural pouch, probably resulting from fistulization of the retropharyngeal lymph nodes, normally not detectable because of the deeper position, even if increased in

volume (Slater, 2007). Despite bastard strangles is believed to not develop following this milder form of strangles (Slater, 2007), it is possible to assume that in this case there may be an exception and the mare develop not only the dissemination but also acquired the state of long term carrier study by Newton *et al.* (1997, 2000). Nevertheless, the purulent material in the guttural pouch was firm and inspissated, it did not form chondroids yet.

From the history study, the time of first infection dates back to the time of fertilization or conception, events that can cause stress to the animal and predispose to a deficiency of the immune system, facilitating the spread of infection. However, it has been speculated that other factors may influence the severity of the disease such as the bacterial strain, earlier exposures and genetic factors (Slater, 2007). In this study, the PCR band corresponding to the gene codifying for the pathogenic factor *SeeI* was very strong, especially in comparison with the *sodA* band, suggesting the presence of a high amount of this gene in the abscesses. Strangle-like diseases caused by streptococci different from *S. equi* subsp. *equi* have also been study (Bone *et al.*, 1963; Laus *et al.*, 2007). In the study clinical case no other microorganisms were isolated.

Collection of respiratory samples for bacteriological examination and PCR are recommended to recognized atypical strangles and prevent spread of infection to other horses and sequelae like dissemination or guttural pouches empyema. Culture of nasal swabs, nasal washes or pus aspirated from abscesses remains the gold standard for detection of *S. equi* (Sweeney *et al.*, 2005). Culture may, however, be unsuccessful during the incubation and early clinical phases. *S. equi* is normally not present on the mucosa until 24-48 h after the onset of fever and so horses monitored by daily measuring of rectal temperatures during an outbreak may be recognized early and isolated to limit transmission of *S. equi*.

The prevalence of metastatic abscessation is generally low. However, in a study in which outbreaks of strangles on 2 farms were investigated, 7 out of 25 (28%) developed metastatic abscessation. Of these, euthanasia was performed in 5 horses, 4 of which had neurologic signs and confirmed cerebral abscesses. (Spoomakers *et al.*, 2003).

A high infectious dose, the virulence of the strains involved, differences in host susceptibility or other unidentified factors could be explain the incidence of complications (Valberg *et al.*, 1996; Divers *et al.*, 1992; Whelchel and Chaffin, 2009).

Despite *S. equi* is highly host adapted and infections of humans have rarely been confirmed, cases of *S. equi*

infection in debilitated humans have been study. Animal handlers, caretakers, veterinary practitioners, pathologists and equine postmortem attendants should take particular care to avoid unnecessary contamination from infectious horses, especially avoiding respiratory and oral contamination by purulent material (Sweeney *et al.*, 2005).

CONCLUSION

Bastard strangles is potential sequelae to *S. equi* subspecies *equi* infections in the horse also in case of atypical strangles. Prompt recognition of atypical manifestations and sequelae to *S. equi* are needed to identify, treat and improve the prognostic outcome.

REFERENCES

- Bell, R.J. and M.E. Smart, 1992. An unusual complication of strangles in a pony. *Can. Vet. J.*, 33: 400-401.
- Bone, J.F., E.J. Catcott, A.A. Gabel, L.E. Johnson and W.F. Riley, 1963. Strangles (Distemper). In: *Equine Medicine and Surgery*, Bone, J.F. (Ed.), 1st Edn., American Veterinary Publications, Wheaton, Illinois, pp: 173-180.
- Divers, T.J., J.F. Timoney, R.M. Lewis and C.A. Smith, 1992. Equine glomerulonephritis and renal failure associated with complexes of group-C streptococcal antigen and IgG antibody. *Vet. Immunol. Immunopathol.*, 32: 93-102.
- Grant, S.T., A. Efstratiou and N. Chanter, 1993. Laboratory diagnosis of strangles and the isolation of atypical *Streptococcus equi*. *Vet. Rec.*, 133: 215-216.
- Laus, F., S. Preziuso, A. Spaterna, F. Beribe, B. Tesei and V. Cuteri, 2007. Clinical and epidemiological investigation of chronic upper respiratory diseases caused by β -haemolytic Streptococci in horses. *Comp. Immunol. Microbiol. Infect. Dis.*, 30: 247-260.
- Newton, J.R., J.L. Wood, K.A. Dunn, M.N. DeBrauwere and N. Chanter, 1997. Naturally occurring persistent and asymptomatic infection of the guttural pouches of horses with *Streptococcus equi*. *Vet. Rec.*, 140: 84-90.
- Newton, J.R., K. Verheyen, N.E. Talbot, J.F. Timoney, J.L. Wood, K.H. Lakhani and N. Chanter, 2000. Control of strangles outbreaks by isolation of guttural pouch carriers identified using PCR and culture of *Streptococcus equi*. *Equine Vet. J.*, 32: 515-526.

- Preziuso, S. and V. Cuteri, 2011. A multiplex polymerase chain reaction assay for direct detection and differentiation of β -hemolytic *Streptococci* in clinical samples from horses. *J. Equine Vet. Sci.*, (In Press). 10.1016/j.jevs.2011.11.001.
- Slater, J., 2007. Bacterial Infection of the Equine Respiratory Tract. In: *Equine Respiratory Medicine and Surgery*, McGorum, B.C., P.M. Dixon, N.E. Robinson and J. Schumacher (Eds.). Elsevier, Philadelphia.
- Spoormakers, T.J., J.M. Ensink, L.S. Goehring, J.P. KOeman, F. Ter Braake, R.H. van der Vlugt-Meijer and A.J. van den Belt, 2003. Brain abscesses as a metastatic manifestation of strangles: Symptomatology and the use of magnetic resonance imaging as a diagnostic aid. *Eq. Vet. J.*, 35: 146-151.
- Sweeney, C.R., J.F. Timoney, J.R. Newton and M.T. Hines, 2005. *Streptococcus equi* infections in horses: Guidelines for treatment, control and prevention of strangles. *J. Vet. Int. Med.*, 19: 123-134.
- Sweeney, C.R., R.H. Whitlock, D.A. Meirs, S.C. Whitehead and S.O. Barningham, 1987. Complications associated with *Streptococcus equi* infection on a horse farm. *J. Am. Vet. Med. Assoc.*, 191: 1446-1448.
- Valberg, S., P. Bullock and W. Hogetvedt, 1996. Myopathies associated with *Streptococcus equi* infections in horses. *Proc. Am. Ass. Equine Practnrs.*, 42: 292-293.
- Whelchel, D.D. and M.K. Chaffin, 2009. Sequelae and complications of *Streptococcus equi Subspecies equi* infections in the horse. *Equine. Vet. Educ.*, 21: 135-141.