

Effect of a Probiotic *Enterococcus faecium* Strain on the Number of Intestinal Mucosal Immune Cells of Young Yaks

^{1,2,3}Hongxing Zheng, ³Shanshan Qi, ²Jianxi Li, ²Zhiqiang Yang and ³Yongji Wang

¹Faculty of Veterinary Medicine, Gansu Agricultural University, Lanzhou, 730070 Gansu, China

²Lanzhou Institute of Husbandry and Pharmaceutical Sciences of CAAS, Lanzhou, 730050 Gansu, China

³Shaanxi University of Technology, Hanzhong, 723000 Shaanxi, China

Abstract: The intention of this study was to describe the effects of oral administration of the probiotic bacterium *Enterococcus faecium* SF68 on the number of intestinal mucosal immune cells of young yaks to improve the understanding of the underlying mechanisms of this probiotic. The histology, histochemistry and cell counting methods were used. The number of Intraepithelial Lymphocytes (IELs), Goblet Cells (GCs), plasma cells and mast cells were counted, recorded and compared with the control group. Statistical analysis showed that the number of those intestinal mucosal immune cells were all increased in the probiotic group, compared with the control group and the difference was statistically significant ($p < 0.05$). The distribution tendency of those cells in small intestine was that: the number of intraepithelial lymphocytes, goblet cells and mast cells was gradually reduced from duodenum to ileum in two groups whereas the number of plasma cells was gradually increased from duodenum to ileum. The results indicated that the probiotic bacterium *Enterococcus faecium* SF68 has intense influence on the number of mucosal immune cells in small intestine of young yaks, the hyperplasia of those cells can strengthen the anti-infections ability of yaks. The results will facilitate the understanding of the underlying mechanisms of this probiotic.

Key words: Young yaks, probiotics, *Enterococcus faecium*, immune cells, number

INTRODUCTION

The intestinal microflora play a crucial role in host defense as demonstrated by their ability to modulate both innate and acquired immunity at the local as well as systemic levels (Isolauri *et al.*, 2001; Macfarlane and Cummings, 2002). Due to these immunological properties, specific strains of Lactic Acid Bacteria (LAB), defined as probiotics have raised considerable interest in recent years. When ingested as a feed supplement in sufficient numbers, probiotics are live microorganisms that beneficially affect the gastrointestinal balance, going far beyond the conventional nutritional effect (Penner *et al.*, 2005). Many studies report positive effects of probiotic supplementation on the performance and health of animals. Despite the fact that several studies have shown disease prevention or immune enhancement resulting from oral administration of probiotics (Biloo *et al.*, 2006; Cong *et al.*, 2003; Galdeano and Perdigon, 2006), few studies are available on their specific effects on the gut defense mechanisms, the mechanisms underlying the immune modulating properties of probiotics are not fully understood.

Enterococcus faecium (strain NCIMB10415; SF68) is a LAB with inhibitory effects against important enteropathogens including enterotoxigenic *Escherichia coli*, salmonellae, shigellae and clostridia (Lewenstein *et al.*, 1979). Therefore, it was suggested that this bacterium might be useful as an anti-diarrheal agent. In fact, the efficacy of SF68 in the treatment of antibiotic-associated as well as acute diarrhea in humans was later demonstrated (Wunderlich *et al.*, 1989). It was shown recently that *E. faecium* SF68 stimulates both the mucosal and the systemic immune system in dogs. More specifically, oral administration of SF68 increases intestinal IgA production and improves the immune response to canine vaccine (Benyacoub *et al.*, 2003), it was suggested that greater production of mucosal IgA when SF68 is fed may have an important protective effect against intestinal pathogens (Benyacoub *et al.*, 2003; Bybee *et al.*, 2011). To date, no studies have assessed the protective effect of SF68 on intestinal mucosal immune cells, most of the studies pay more attention on intestinal IgA, the intestinal mucosal immune cells (intraepithelial lymphocytes, goblet cells, plasma cells and mast cells) were not involved. The objective of this study was to

determine the effects of *E. faecium* SF68 on the number of intestinal mucosal immune cells of young yaks. This study will provide the basic information to further study on the gastrointestinal mucosal immunity of yak and the mechanisms of mucosal protection of this probiotic.

The yak (*Bos grunniens*) is a bovine species living in cold plateaus with high altitude >3 km above sea level. There are approximately 1.3 million yaks in China, accounting for 90% of the yak population in the world. Nearly all yaks in China are distributed throughout the Qing-Tibet Plateau, especially in Gansu province, Qinghai province and Tibet. The yak is one of the most important domesticated beasts in Gansu, Qinghai and Tibet. However, there is little information about probiotics in yaks if *E. faecium* SF68 has obviously positive effect on yak and enhance the Yak's defense system, growth performance will be improved, diarrhea, mortality and morbidity will also be decreased.

MATERIALS AND METHODS

Study animals: All experimental procedures were approved by the welfare authority of Tianzhu county of Gansu province.

A group of 20 healthy young yaks (1-1.5 years) was randomly divided into two groups, 1 of which (probiotic group) was supplemented with the probiotic strain *E. faecium* SF68 (NCIMB 10415; Cylactin, Roche) while the other group of 10 yaks remained untreated (control group). *E. faecium* SF68 was provided to the probiotic group as a feed supplement at a concentration of 2×10^9 CFU kg^{-1} feed. The probiotic group received the food supplemented with *E. faecium* SF68 for 28 days then the animals were anesthetized with sodium pentobarbital and were then exsanguinated. Researchers investigated the small intestine of the probiotic group and the control group, the abdomen was incised and the small intestine was taken out. Tissues were taken for histology from duodenum, distal jejunum and terminal ileum and they were fixed in a solution of 4% paraformaldehyde in 0.1 M phosphate buffer (pH 7.4) for 18 h at 4°C and processed routinely for wax histology, paraffin sections were stained by the following methods: hematoxylin and eosin, Periodic Acid-Schiff, Unna-Pappenheim methyl green-pyronin and toluidine blue, those staining methods were used to show Intraepithelial Lymphocytes (IELs), goblet cells, plasma cells and mast cells.

Cell count

Method: IELs and goblet cells were counted using the same standard microscope. The total number of IELs and goblet cells per 100 epithelial cells were counted at 400x

magnification on haematoxylin/eosin stained slides and Periodic Acid-Schiff stained slides and the mean number was recorded for each case. Results were expressed as IELs/100 villus epithelial cells and GCs/100 villous epithelium cells. The number of plasma cells and mast cells per 5 fields at a magnification of 400x was counted under light microscopy. These results were assessed semi quantitatively by two researchers and the average count was used as the final score.

Statistical analysis: All the data were analysed using Independent t-test and one way ANOVA (SPSS for Windows Version 11.5). The statistical analysis was based on the comparison between the groups (using independent t-test) and comparison within the groups (using one way ANOVA). Differences were considered statistically significant where $p < 0.05$.

RESULTS

The comparison of the number of IELs in the probiotic group and the control group:

As shown in Table 1, Fig. 1 and 2, the number of IELs in small intestine of young yak in the probiotic group was more than control group. The difference between two groups was statistically significant ($p < 0.05$). The number of IELs in duodenum, jejunum and ileum increased by 58.40, 47.35 and 33.01% in the probiotic group compared with the control group. The

Table 1: Number of intraepithelial lymphocytes in small intestinal of young yak in the control and probiotic groups ($\bar{x} \pm s$)

Groups	IELs/100 villous epithelium cells			
	Duodenum	Jejunum	Ileum	Small intestine
Control group	22.21±2.98 ^{aa}	17.15±2.79 ^{ba}	14.36±2.46 ^{ca}	17.94±3.35 ^a
Probiotic group	35.18±3.56 ^{ab}	25.27±3.08 ^{bb}	19.10±2.93 ^{cb}	25.71±4.02 ^b

The data with different capital letter within the same row or column differ significantly ($p < 0.05$). The capital letter (A-C) represent different small intestine segment in the same group, lowercase (a, b) represent the same small intestine segment in different group

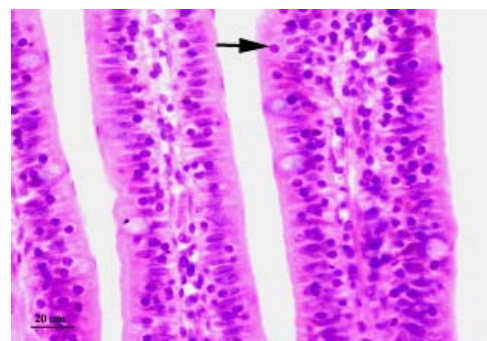


Fig. 1: Light photomicrograph of the IELs in small intestine of young yak in the control group (H&E, bar = 20 μm). The arrow points to the IEL

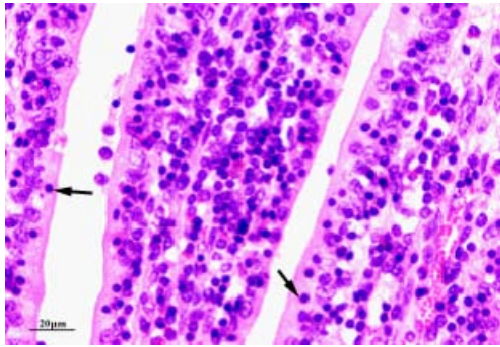


Fig. 2: Light photomicrograph of the IELs in small intestine of young yak in the probiotic group (H&E, bar = 20 μm). The arrow points to the IEL.

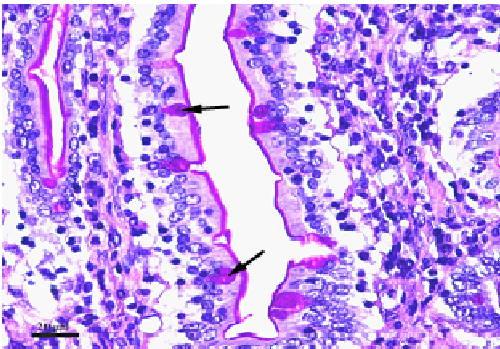


Fig. 3: Light photomicrograph of the goblet cells in small intestinal epithelium of young yak in the control group (Periodic Acid-Schiff stain, bar = 20 μm). The arrow points to the goblet cell.

Table 2: Number of goblet cells in small intestinal of young yak in the control and probiotic groups ($\bar{x} \pm s$)

Groups	GCs/100 villous epithelium cells			
	Duodenum	Jejunum	Ileum	Small intestine
Control group	17.25±2.23 ^{Aa}	14.31±1.88 ^{Ba}	12.01±1.93 ^{Ca}	14.47±3.12 ^a
Probiotic group	21.16±3.02 ^{Ab}	18.01±2.05 ^{Bb}	15.24±2.03 ^{Cb}	18.18±3.24 ^b

The data with different capital letter within the same row or column differ significantly ($p < 0.05$). The capital letter (A-C) represent different small intestine segment in the same group, lowercase (a, b) represent the same small intestine segment in different group

present investigation indicated that the number of IELs was gradually reduced from duodenum to jejunum in two groups.

The comparison of the number of goblet cells in the probiotic group and the control group: As shown in Table 2, Fig. 3 and 4, the number of epithelial goblet cells in small intestine of yak in the probiotic group was more than the control group. The difference between two groups was statistically significant ($p < 0.05$). The number

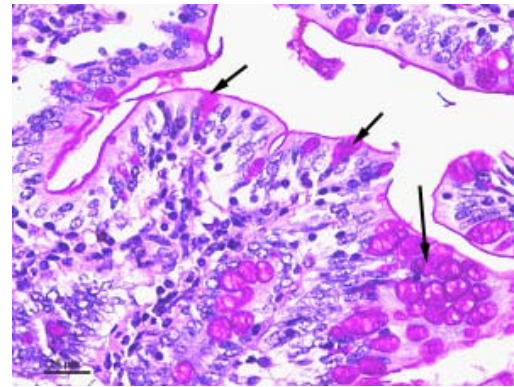


Fig. 4: Light photomicrograph of the goblet cells in small intestinal epithelium of young yak in the probiotic group (Periodic Acid-Schiff stain, bar = 20 μm). The arrow points to the goblet cell.

Table 3: Number of plasma cells in small intestinal of young yak in the control and probiotic groups ($\bar{x} \pm s$)

Groups	Plasma cells/HPF			
	Duodenum	Jejunum	Ileum	Small intestine
Control group	12.05±1.98 ^{Ba}	22.81±3.57 ^{Aa}	24.40±3.26 ^{Aa}	19.54±3.09 ^a
Probiotic group	17.96±2.34 ^{Bb}	31.02±3.14 ^{Ab}	34.59±4.17 ^{Ab}	28.02±4.01 ^b

The data with different capital letter within the same row or column differ significantly ($p < 0.05$). The capital letter (A-C) represent different small intestine segment in the same group, lowercase (a, b) represent the same small intestine segment in different group

of epithelial goblet cells in duodenum, jejunum and ileum increased by 22.67, 25.86 and 26.89% in the probiotic group compared with the control group. From duodenum to jejunum, the number of epithelial goblet cells was gradually reduced in two groups and the difference was statistically significant ($p < 0.05$).

The comparison of the number of plasma cells in the probiotic group and the control group: As shown in Table 3, Fig. 5 and 6, the number of plasma cells in small intestine of yak in the probiotic group was more than the control group and the difference between two groups was statistically significant ($p < 0.05$). At the same time, the number of plasma cells in duodenum, jejunum and ileum increased by 49.05, 35.99 and 41.76% in the probiotic group compared with the control group. The number of plasma cells was gradually increased from duodenum to jejunum in two groups and the number of plasma cells in duodenum and jejunum was significantly different ($p < 0.01$) whereas there was no difference in the number of plasma cells in jejunum and ileum ($p > 0.05$). Histological observation found that plasma cells were mainly distributed in the lamina propria of small intestine, there were few plasma cells in the solitary lymphoid nodule and aggregated lymphoid nodules.

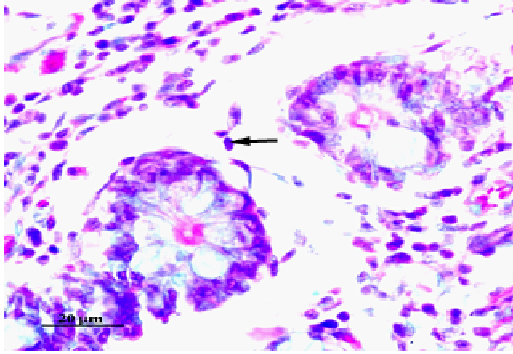


Fig. 5: Light photomicrograph of the plasma cells in small intestine of young yak in the control group (Unna-Pappenheim methyl green-pyronin stain, bar = 20 µm). The arrow points to the plasma cell

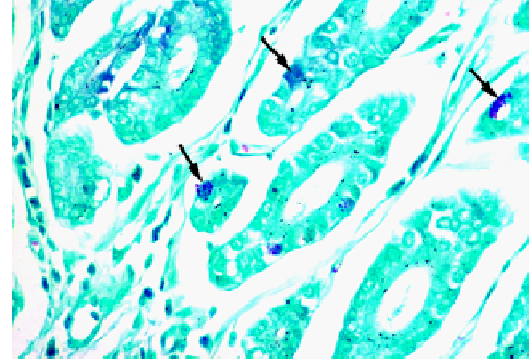


Fig. 8: Light photomicrograph of the mast cells in small intestine of young yak in the probiotic group (toluidine blue stain, bar = 20 µm). The arrow points to the mast cell

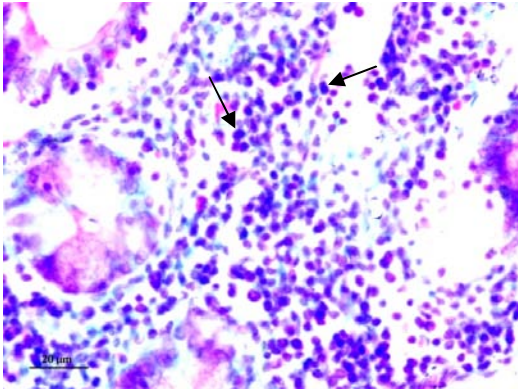


Fig. 6: Light photomicrograph of the plasma cells in small intestine of young yak in the probiotic group (Unna-Pappenheim methyl green-pyronin stain, bar = 20 µm). The arrow points to the plasma cell

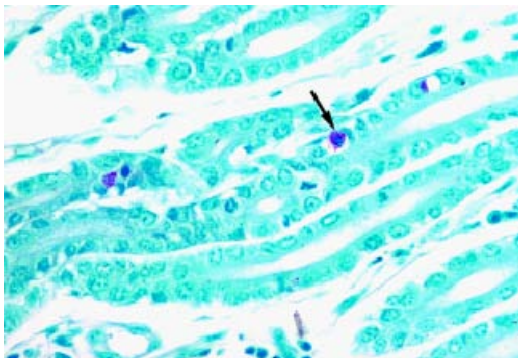


Fig. 7: Light photomicrograph of the mast cells in small intestine of young yak in the control group (toluidine blue stain, bar = 20 µm). The arrow points to the mast cell

Table 4: Number of mast cells in small intestinal of young yak in the control and probiotic groups ($\bar{x} \pm S$)

Groups	Mast cells/HPF			
	Duodenum	Jejunum	Ileum	Small intestine
Control group	30.01±5.05 ^{Aa}	24.47±3.32 ^{Ba}	18.12±2.94 ^{Ca}	23.49±3.17 ^a
Probiotic group	38.12±5.19 ^{Ab}	31.52±4.34 ^{Bb}	25.03±3.04 ^{Cb}	31.08±4.21 ^b

The data with different capital letter within the same row or column differ significantly ($p < 0.05$). The capital letter (A-C) represent different small intestine segment in the same group, lowercase (a, b) represent the same small intestine segment in different group

The comparison of the number of mast cells in the probiotic group and the control group: The number of mast cells in the infected and normal group is shown in Table 4, Fig. 7 and 8, researchers found that the number of mast cells in the probiotic group was higher than the control group and the difference between two groups was statistically significant ($p < 0.05$). The number of mast cells in duodenum, jejunum and ileum increased by 27.02, 28.81 and 38.13% in the probiotic group compared with the control group. The number of mast cells was gradually decreased from duodenum to jejunum in two groups and the difference was statistically significant ($p < 0.01$). Histological observation demonstrated that mast cells were mainly distributed around the intestinal gland, blood vessels and lymphatic vessels.

DISCUSSION

This is the first report of the effects of oral administration of the probiotic bacterium *Enterococcus faecium* SF68 on the number of intestinal mucosal immune cells of young yaks, the results of this study showed that all the immune cells (intraepithelial lymphocytes, goblet cells, plasma cells and mast cells) in small intestine of yak were increased in the probiotic group.

The intestinal tract is the crossroad between the needs of nutrient absorption and host defense (MacDonald and Monteleone, 2005). It has been suggested that the gut has the most important role in the maintenance of homeostasis of the body (MacDonald and Monteleone, 2005). As a complicated immune system tissue, the intestinal tract plays a critical role in the first line of defense against ingested pathogens. The main site of the mucosal immune system in the intestine is referred to as gut-associated lymphoid tissue and immune associated cells including IELs, goblet cells, plasma cells and mast cells are involved in many processes to prevent pathogen invasion (Oswald, 2006). The collaboration of those immunocompetent cells and probiotic help the animals to compete against all kinds of infectious pathogens (Blum and Schiffrin, 2003).

There are several publications that provide experimental and clinical support for the use of probiotics in the maintenance of gut homeostasis, particularly in the prevention of intestinal infections and inflammatory conditions (Gill, 2003; Isolauri, 2003; Rioux and Fedorak, 2006). The ability of *Enterococci* sp. such as *E. faecalis* and *E. faecium* strains to modulate both innate and acquired immune responses was reported earlier in different species (Basualdo *et al.*, 2007; Vahjen *et al.*, 2007). Furthermore, the safe use of *E. faecium* SF68 as a probiotic for humans and animals was investigated extensively and confirmed recently (Benyacoub *et al.*, 2005; Broom *et al.*, 2006; Simpson *et al.*, 2009) whereas most of the studies pay more attention on intestinal IgA, the intestinal mucosal immune cells (intraepithelial lymphocytes, goblet cells, plasma cells and mast cells) were not involved.

The gastrointestinal tract plays the key role in uptake of fluids and nutrients and at the same time it forms the main protective barrier between the sterile environment of the body and the outside world (Artis, 2008). The Intestinal Intraepithelial Lymphocytes (IELs) form the first line of the host immune defence system and play an essential role against infections caused by certain microorganisms or parasite (Guk *et al.*, 2003; Inagaki-Ohara *et al.*, 2006). This study found that the number of IELs in small intestine of yak in the probiotic group was more than normal group, at the same time, numerous investigators have demonstrated that raised IELs are often seen after feeding a probiotic. Dalloul examined the effects of feeding a lactobacillus-based probiotic on the intestinal IEL subpopulations and any subsequent enhancement of intestinal immunity against coccidiosis, they found that the number of IELs in the probiotic group was more than the control group, they also found that IELs sustain the epithelial barrier function against coccidiosis infection, during coccidiosis infection,

IEL increased production of gamma Interferon (IFN-gamma) and Tumor Necrosis Factor alpha (TNF-alpha) and decreased Transforming Growth Factor beta (TGF-beta) production. These results suggest that IEL play important multifunctional roles in protection of the epithelium against infections. The increased number of IELs in small intestine of young yaks in this research indicate that *E. faecium* SF68 has the function of immune stimulation, oral administration of *E. faecium* SF68 can enhance the intestinal mucosal immunity.

The study find that the number of epithelial goblet cells in small intestine of yak in the probiotic group was more than the control group. Researchers know that goblet cell can secrete mucins, mucins are the major protein components of the protective mucus barrier that cover epithelial surfaces in the gastrointestinal tract. This barrier is considered a first line of defense against colonization by gut pathogens (Harrison *et al.*, 1999). Mahdavi found using different levels of probiotic caused highly significant increase ($p < 0.01$) in goblet cell numbers, they provide the probiotic feed containing *Bacillus subtilis* (CH201) and *Bacillus licheniformis* (CH200) to hens for 12 weeks, the number of intestinal goblet cells markedly increased in the probiotic group. Another research also found that the dietary probiotic significantly increase the number of goblet cells and mucins throughout the small intestine compared with the other groups in chickens (Smirnov *et al.*, 2005). Goblet cell mucins play a key role in mucosal defence, it seem as the selective barrier for the intestinal pathogens, thus the increase in the number of goblet cells seem to be an unspecific defensive mechanism. The hyperplasia of epithelial goblet cells in small intestine of yaks show that *E. faecium* SF68 has the function of immune stimulation, oral administration of *E. faecium* SF68 can reinforcement of the intestinal mucosal barrier against infection.

The study found that the number of plasma cells in each part of the small intestine in the probiotic group was more than that of the control group and the difference between two groups was statistically significant. The main founction of plasma cells is to produce Immunoglobulin A (IgA), most of the IgA in the gut is generated by B cells in the PP germinal centers (McGhee, 2005; Mestecky and Elson, 2008). On epithelial surfaces, the main specific immune defense of the host is the protection afforded by secretory IgA antibodies. In a study of Benyacoub *et al.* (2003), young dogs were administered with the probiotic *Enterococcus faecium* from weaning to 1 year of age. Fecal IgA tended to be higher for the probiotic group and plasma IgA was significantly higher for the probiotic group. Also, the probiotic group showed higher levels of vaccine-specific (canine-distemper virus) IgG and IgA. The mucosal

immune system forms the largest part of the entire immune system, containing about three quarters of all lymphocytes and producing grams of secretory IgA daily to protect the mucosal surface from pathogens (Macpherson, 2006). A great deal of IgA secreted by plasma cells can prevent the pathogens inhabiting.

The probiotic group showed apparently higher number of mast cells in each part of the small intestine than that of the control group. The increase of mast cell in the intestinal mucosa is known to play an important role in host defense against infections (Caldwell *et al.*, 2004; Zareie *et al.*, 2006). Some studies indicate that intestinal mucosal mast cells play an important role in the local mucosal immune response (Caldwell *et al.*, 2004; Morris *et al.*, 2004). Mast cells are important immunocompetent cells in the intestinal mucosal immune response that exert multifunctional roles by releasing prestored and *de novo* synthesized mediators such as histamine, proteases, serotonin and others (Metcalf *et al.*, 1997).

Bybee *et al.* (2011) found that cats and dogs fed *E. faecium* SF68 had fewer episodes of diarrhea compared with controls, they suggests the probiotic may have beneficial effects on the gastrointestinal tract but the underlying mechanisms of this effect was not discussed. The present research supported that the specific effects on the gut defense mechanisms was that *E. faecium* SF68 has intense influence on the number of mucosal immune cells, the increased intestinal mucosal immune cells can enhance the defense system of the body so, the diarrhea, mortality and morbidity will be decreased.

Since, the gastrointestinal mucosa is the surface of contact with probiotics, it seems evident that the first effects of probiotics relate to digestive function. The research indicates that *E. faecium* SF68 have very few effects on the main physiological functions of the gastrointestinal tract which are digestion, absorption and propulsion. The main action of *E. faecium* SF68 can be summarized as a reinforcement of the intestinal mucosal barrier against infections.

CONCLUSION

The present study suggests that the probiotic bacterium *Enterococcus faecium* SF68 has intense influence on the number of mucosal immune cells (IELs, goblet cells, plasma cells and mast cells) in small intestine of young yaks, the hyperplasia of those cells can strengthen the anti-infections ability of yaks. The main action of *E. faecium* SF68 can be summarized as a reinforcement of the intestinal mucosal barrier and increase the number of intestinal mucosal immune cells.

ACKNOWLEDGEMENTS

Researchers would like to thank the Jianxi Li and Zhiqiang Yang for their great help in the guidance of the study. This study was supported by The National Natural Sciences Foundation of China (31072162) and Lanzhou Insitute of Husbandry and Pharmaceutical Sciences of CAAS, Qilihe district, jiangouyan 335#, Lanzhou, Gansu 730050, China.

REFERENCES

- Artis, D., 2008. Epithelial-cell recognition of commensal bacteria and maintenance of immune homeostasis in the gut. *Nat. Rev. Immunol.*, 8: 411-420.
- Basualdo, J., M. Sparo, P. Chiodo, M. Ciarmela and M. Minvielle, 2007. Oral treatment with a potential probiotic (*Enterococcus faecalis* CECT 7121) appears to reduce the parasite burden of mice infected with *Toxocara canis*. *Ann. Trop. Med. Parasitol.*, 101: 559-562.
- Benyacoub, J., G.L. Czarnecki-Maulden, C. Cavadini, T. Sauthier, R.E. Anderson, E.J. Schiffrin and T. von der Weid, 2003. Supplementation of food with *Enterococcus faecium* (SF68) stimulates immune functions in young dogs. *J. Nutr.*, 133: 1158-1162.
- Benyacoub, J., P.F. Perez, F. Rochat, K.Y. Saudan and G. Reuteler *et al.*, 2005. *Enterococcus faecium* SF68 enhances the immune response to *Giardia intestinalis* in mice. *J. Nutr.*, 135: 1171-1176.
- Biloo, A.G., M.A. Memon, S.A. Khaskheli, G. Murtaza, K. Iqbal, M. Saeed Shekhani and A.Q. Siddiqi, 2006. Role of a probiotic (*Saccharomyces boulardii*) in management and prevention of diarrhoea. *World J. Gastroenterol.*, 12: 4557-4560.
- Blum, S. and E.J. Schiffrin, 2003. Intestinal microflora and homeostasis of the mucosal immune response: Implications for probiotic bacteria? *Curr. Issues Intest. Microbiol.*, 4: 53-60.
- Broom, L.J., H.M. Miller, K.G. Kerr and J.S. Knapp, 2006. Effects of zinc oxide and *Enterococcus faecium* SF68 dietary supplementation on the performance, intestinal microbiota and immune status of weaned piglets. *Res. Vet. Sci.*, 80: 45-54.
- Bybee, S.N., A.V. Scorza and M.R. Lappin, 2011. Effect of the probiotic *Enterococcus faecium* SF68 on presence of diarrhea in cats and dogs housed in an animal shelter. *J. Vet. Intern. Med.*, 25: 856-860.
- Caldwell, D.J., H.D. Danforth, B.C. Morris, K.A. Ameiss and A.P. McElroy, 2004. Participation of the intestinal epithelium and mast cells in local mucosal immune responses in commercial poultry. *Poult. Sci.*, 83: 591-599.

- Cong, Y., A. Konrad, N. Iqbal and C.O. Elson, 2003. Probiotics and immune regulation of inflammatory bowel diseases. *Curr. Drug Targets Inflamm. Allergy*, 2: 145-154.
- Galdeano, C.M. and G. Perdigon, 2006. The probiotic bacterium *Lactobacillus casei* induces activation of the gut mucosal immune system through innate immunity. *Clin. Vacc. Immunol.*, 13: 219-226.
- Gill, H.S., 2003. Probiotics to enhance anti-infective defences in the gastrointestinal tract. *Best Pract. Res. Clin. Gastroenterol.*, 17: 755-773.
- Guk, S.M., T.S. Yong and J.Y. Chai, 2003. Role of murine intestinal intraepithelial lymphocytes and lamina propria lymphocytes against primary and challenge infections with *Cryptosporidium parvum*. *J. Parasitol.*, 89: 270-275.
- Harrison, G.B., H.D. Pulford, T.K. Gatehouse, R.J. Shaw, A. Pfeffer and C.B. Shoemaker, 1999. Studies on the role of mucus and mucosal hypersensitivity reactions during rejection of *Trichostrongylus colubriformis* from the intestine of immune sheep using an experimental challenge model. *Int. J. Parasitol.*, 29: 459-468.
- Inagaki-Ohara, K., F.N. Dewi, H. Hisaeda, A.L. Smith and F. Jimi *et al.*, 2006. Intestinal intraepithelial lymphocytes sustain the epithelial barrier function against *Eimeria vermiformis* infection. *Infect. Immun.*, 74: 5292-5301.
- Isolauri, E., 2003. Probiotics for infectious diarrhoea. *Gut.*, 52: 436-437.
- Isolauri, E., Y. Sutas, P. Kankaanpaa, H. Arvilommi and S. Salminen, 2001. Probiotics: Effects on immunity. *Am. J. Clin. Nutr.*, 73: 444-450.
- Lewenstein, A., G. Frigerio and M. Moroni, 1979. Biological properties of SF68, a new approach for the treatment of diarrhoeal diseases. *Curr. Ther. Res.*, 26: 967-981.
- MacDonald, T.T. and G. Monteleone, 2005. Immunity, inflammation and allergy in the gut. *Sci.*, 37: 1920-1925.
- Macfarlane, G.T. and J.H. Cummings, 2002. Probiotics, infection and immunity. *Curr. Opin. Infect. Dis.*, 15: 501-506.
- Macpherson, A.J., 2006. IgA adaptation to the presence of commensal bacteria in the intestine. *Curr. Top Microbiol. Immunol.*, 308: 117-136.
- McGhee, J.R., 2005. Peyer's patch germinal centers: The elusive switch site for IgA. *J. Immunol.*, 175: 1361-1362.
- Mestecky, J. and C.O. Elson, 2008. Peyer's patches as the inductive site for IgA responses. *J. Immunol.*, 180: 1293-1294.
- Metcalf, D.D., D. Baram and Y.A. Mekori, 1997. Mast cells. *Physiol. Rev.*, 77: 1033-1079.
- Morris, B.C., H.D. Danforth, D.J. Caldwell, F.W. Pierson and A.P. McElroy, 2004. Intestinal mucosal mast cell immune response and pathogenesis of two *Eimeria acervulina* isolates in broiler chickens. *Poult. Sci.*, 83: 1667-1674.
- Oswald, I.P., 2006. Role of intestinal epithelial cells in the innate immune defence of the pig intestine. *Vet. Res.*, 37: 359-368.
- Penner, R., R.N. Fedorak and K.L. Madsen, 2005. Probiotics and nutraceuticals: Non-medicinal treatments of gastrointestinal diseases. *Curr. Opin. Pharmacol.*, 5: 596-603.
- Rioux, K.P. and R.N. Fedorak, 2006. Probiotics in the treatment of inflammatory bowel disease. *J. Clin. Gastroenterol.*, 40: 260-263.
- Simpson, K.W., M. Rishniw, M. Bellosa, J. Liotta and A. Lucio *et al.*, 2009. Influence of *Enterococcus faecium* SF68 probiotic on giardiasis in dogs. *J. Vet. Intern. Med.*, 23: 476-481.
- Smimov, A., R. Perez, E. Amit-Romach, D. Sklan and Z. Uni, 2005. Mucin dynamics and microbial populations in chicken small intestine are changed by dietary probiotic and antibiotic growth promoter supplementation. *J. Nutr.*, 135: 187-192.
- Vahjen, W., D. Taras and O. Simon, 2007. Effect of the probiotic *Enterococcus faecium* NCIMB10415 on cell numbers of total *Enterococcus* spp., *E. faecium* and *E. faecalis* in the intestine of piglets. *Curr. Issues Intest Microbiol.*, 8: 1-7.
- Wunderlich, P.F., L. Braun, I. Fumagalli, V. D'Apuzzo and F. Heimet *et al.*, 1989. Double-blind report on the efficacy of lactic acid-producing *Enterococcus* SF68 in the prevention of antibiotic-associated diarrhoea and in the treatment of acute diarrhoea. *J. Int. Med. Res.*, 17: 333-338.
- Zareie, M., K. Johnson-Henry, J. Jury, P.C. Yang and B.Y. Ngan *et al.*, 2006. Probiotics prevent bacterial translocation and improve intestinal barrier function in rats following chronic psychological stress. *Gut*, 55: 1553-1560.