

## Evaluation of the Oro-Nasal Immunization Route of Rabbits against *Pseudomonas aeruginosa* Keratitis

<sup>1</sup>A.M. Al-Aalim, <sup>2</sup>H.I. Al-Sadi and <sup>1</sup>N.S. Mechael

<sup>1</sup>Department of Microbiology, <sup>2</sup>Department of Pathology and Poultry Diseases, College of Veterinary Medicine, University of Mosul, Mosul, Iraq

**Abstract:** The purpose of this study was to evaluate the oro-nasal route of immunization of rabbits against *Pseudomonas aeruginosa* keratitis. A local strain of *P. aeruginosa* that was previously isolated from human infected wounds was used in both preparation of vaccine, immunization and experimental animal infection. Animal infection was assessed using conventional clinical, bacteriological and pathological techniques. Immunized animals showed rapid bacterial clearance in comparison with non-immunized rabbits. Nonimmunized rabbits challenged with *P. aeruginosa* developed hyperemia of the conjunctiva, edema and suppurative inflammation at 24 h postchallenge. A single peripheral ring infiltrate covered 50-75% of the corneal diameter and 75% of stroma was involved with moderate to severe density. A moderate to severe anterior chamber reaction was seen. These changes increased in severity up to 96 h postchallenge and at this stage almost complete opacity was observed. In comparison, immunized rabbits showed complete or incomplete ring infiltrates at the periphery with moderate densities. Mild to moderate anterior chamber response and some hypopyon were also seen. At 96 h postchallenge, a 50% opacity was seen. These results were substantiated histopathologically. It was concluded that oro-nasal immunization provided moderate protection against *P. aeruginosa* keratitis in rabbits.

**Key words:** Evaluation, oro-nasal route, immunization, rabbits, *Pseudomonas aeruginosa*, keratitis

---

### INTRODUCTION

*Pseudomonas aeruginosa* is an opportunistic bacterial pathogen capable of causing a severe corneal infection which commonly leads to extensive corneal scarring and corneal perforation (Pillar, 2001; Hazlett, 2004). The pathogenesis of this infection has been suggested to include colonization of the cornea, the induction of a number of pro-inflammatory cytokines such as Tumor Necrosis Factor (TNF- $\alpha$ ) and Interleukin (IL)-1 $\beta$  and the migration of Polymorphonuclear leukocytes (PMNs) into the cornea to clear the pathogen. Influx of PMNs has been attributed to induction of chemokines responsible for attracting PMNs such as Macrophage Inflammatory Protein (MIP)-2 (Pillar and Hobden, 2002). Both the colonizing bacteria (*Pseudomonas*) and the host (release of cytokines) have been implicated in the resultant pathologic damage in *Pseudomonas* keratitis (Rudner *et al.*, 2000).

It has been shown that *P. aeruginosa* produces extracellular factors that are damaging to ocular tissues. Among these factors are a number of proteases (alkaline protease, staphylolytic protease, elastase and protease

IV), a heat-labile and heat-stable hemolysin, phospholipase C and toxins (Fleiszig and Evans, 2002; Pillar and Hobden, 2002). A number of these factors have been found to have damaging effects on the cornea when applied exogenously to the eye (Engel *et al.*, 1998) or have been linked to ocular virulence (O'Callaghan *et al.*, 1996). The Exotoxin (ETA) has been shown to be critical factor in *Pseudomonas* keratitis (Pillar and Hobden, 2002). Exogenous application of ETA has led to ocular damage in the form of keratitis in mice (Hazlett *et al.*, 2007) and corneal ulceration in rabbits (Pillar and Hobden, 2002). Additionally, ETA has proven to be toxic to murine and human PMNs and to inhibit in vitro phagocytosis and killing of *P. aeruginosa* by PMNs (Miyazaki *et al.*, 1995). Efficacious vaccines against *P. aeruginosa* infection have not been developed till now (Jang *et al.*, 1999; Schaad *et al.*, 1991) even though some recent novel approaches show some promise (Hemachandra *et al.*, 2001; Shiao *et al.*, 2000; Sokol *et al.*, 2000; Thomas *et al.*, 2000). Failure in the development of a vaccine against *P. aeruginosa* infection has been due in part to an incomplete understanding of the optimal *P. aeruginosa* antigens for the vaccine as well as of the host immune

mechanisms that mediate protective immunity against this pathogen (Cripps *et al.*, 1995; Davis *et al.*, 1996; Gilligan, 1991). Mechanisms of protection against bacterial infection may include recruitment of phagocytic cells, specific B- and T-cell responses and the presence of antigen-specific antibodies. It has been shown previously that passive immunization using passive transfer of monoclonal antibodies to outer membrane proteins of *P. aeruginosa* and immune sera produced during corneal infection can provide partial protection against the infection (Moon *et al.*, 1988). Similarly, active immunization with lipopolysaccharide and elastase can provide some degree of protection of the cornea against bacterial infection (Kreger *et al.*, 1986). These studies and others (Inoue *et al.*, 1990) suggest that good protection may be obtained through manipulation of the formulation of vaccines and immunization routes and schedules. The purpose of this study was to evaluate the oro-nasal route in providing significant protection against *P. aeruginosa* keratitis.

## MATERIALS AND METHODS

**Animals:** About 3-4 months old rabbits were used in this study. Eye swabs were taken from each rabbit for bacteriological culture prior to the study and rabbits that were not carrying *P. aeruginosa* were used.

**Bacterial strain:** A local strain of *P. aeruginosa* that was isolated from human infected wounds was used. The isolate was identified through morphological, cultural and biochemical tests and identification of the isolate was confirmed by the API 20 E system. Bacteria were grown in 10 mL of tryptone soy broth overnight at 37°C, harvested and washed three times in sterile Phosphate-Buffered Saline (PBS) and resuspended in PBS prior to use.

**Antigen:** Antigen was prepared following the procedure described by Thakur *et al.* (2001) and it involved exposing *P. aeruginosa* ( $6.5 \times 10^5$  cfu mL<sup>-1</sup>) to 1% (wt./vol) paraformaldehyde in PBS for 2 h at 37°C. After incubation, the bacteria were washed three times in sterile PBS. For oro-nasal immunization, paraformaldehyde-killed bacteria were suspended in PBS to a concentration of  $6.5 \times 10^5$  cfu mL<sup>-1</sup>.

**Immunization:** Protocol of immunization was done according to that described by Cripps *et al.* (1994). In the present study, 8 apparently healthy adult rabbits of local breeds were allocated into two groups. A total of 4 rabbits (group 1) were immunized by the combined oro-nasal immunization and 4 rabbits (group 2) were infected with

*P. aeruginosa* without immunization. To accomplish the combined oro-nasal immunization, paraformaldehyde-killed bacteria ( $6.5 \times 10^5$  cfu mL<sup>-1</sup>) suspended in PBS were administered orally daily on days 1-3 and then days 7-10 in the volume of 0.5 mL. Simultaneously, a similar dose of killed bacteria vaccine was given intranasally on the same days. Following completion of the oro-nasal immunization, a booster dose of 5 µL of vaccine (paraformaldehyde-killed bacteria suspended in PBS) was applied onto the corneal surface.

**Animal infection:** At the end of the immunization schedule and after the administration of the booster dose, the left and right corneas of the rabbit were scratched using a 26 gauge needle. The scratched corneas were then challenged topically with  $6.5 \times 10^5$  cfu /0.1 mL live *P. aeruginosa* (Adlard *et al.*, 1998).

**Clinical examination:** Animals were examined at 24, 48, 72 and 96 h postinfection to grade the severity of infection. Grading the severity was done according to corneal infiltrate density, grades 0-4 where 0 corresponding to non, 1 corresponding to very slight (iris detail visible), corresponding to slight (iris detail partly obscured), corresponding to moderate (iris detail not visible) and corresponding to severe (opaque), extent of infiltrates, epithelial defect size and edema severity. The reaction of the anterior chamber was assessed on the basis of the presence or absence of fibrinous membrane and the presence or absence of hypopyon.

**Bacterial count:** Clearance of *P. aeruginosa* from infected corneas was assessed as the number of viable bacteria at the 24, 48, 72 and 96 h postinfection. Swabs were collected from the eyes and serial dilutions were plated onto nutrient agar plates. Plates were incubated for 18 h at 37°C and the results were expressed as the mean cfu/0.1 mL of eye (Cruickshank *et al.*, 1975).

**Histopathology:** Rabbits were sacrificed at 24, 48, 72 and 96 h postinfection and the whole eyes were excised and fixed in 10% formalin for 48 h. Following fixation, tissues of the eyes were washed, dehydrated, cleared in xylol, embedded in paraffin wax, sectioned at 5-6 µm thickness and stained with hematoxylin and eosin and examined with a light microscope (Kiernan, 1999).

## RESULTS AND DISCUSSION

Control non-immunized rabbits challenged with *P. aeruginosa* developed edema, accumulation of thick viscid white exudate (pus) along the lower eyelid and over

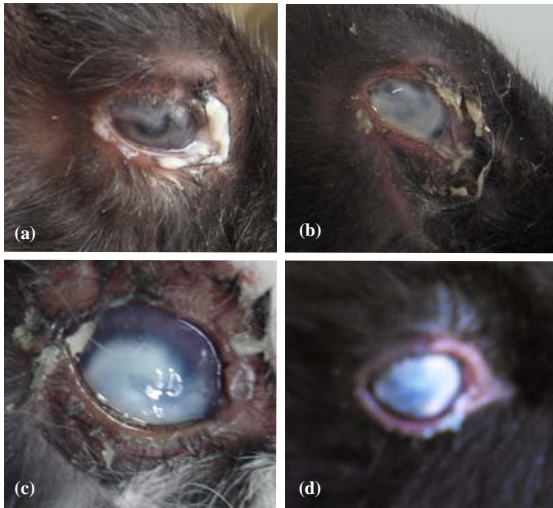

Fig. 1: Rabbit eyes; a) 24; b) 48; c) 72 and d) 96 h after topical challenge with *P. aeruginosa* (non-immunized group)

the conjunctiva and the appearance of peripheral ring infiltrate over the cornea at 24 h postchallenge (Fig. 1a). The infiltrate covered 50-70% (grade 3) of the corneal diameter and involvement of 75% (grade 3) of the stroma with moderate to severe density (grade 3-4). There was ulceration of 25% (grade 1) of the corneal epithelial thickness. At 48 h postchallenge, dryness of exudate was noted and the ring infiltrate covered the cornea completely (100%) (Fig. 1b). Most of the dried exudate was sloughed from the eyelids at 72 h postchallenge. At this period, the ring infiltrate covered 75% of the cornea in some of the animals and 100% in others (Fig. 1c). At 96 h postchallenge, the ring of infiltrate was seen covering 100% of the cornea and only remnants of the exudate were seen in the eyelids (Fig. 1d). Severe redness of the conjunctiva was seen at this stage. In comparison, the eyes of the unchallenged control animals were perfectly normal. The corneas of the most (75%) of the oro-nasally immunized animals were normal 24 h after challenge. In the rest of the animals (25%) infected corneas were edematous, a few stromal infiltrates covered 25% (grades 1.5-2.0) of the corneal diameter and 40% of infected corneas had stromal involvement (grades 2-2.5) with mild densities (grades 2-2.5). A fibrinous reaction (grade 2) was observed in the anterior chambers (Fig. 2a). Similar changes were also observed at 48, 72 and 96 h (Fig. 2b-d). Histologically, a Massive Polymorphonuclear (PMN) infiltration extending from the limbus and conjunctiva to the mid-periphery of the corneal stroma was seen in nonimmunized (control) rabbits at 24 h postchallenge. Similar but less severe changes were observed at 48, 72

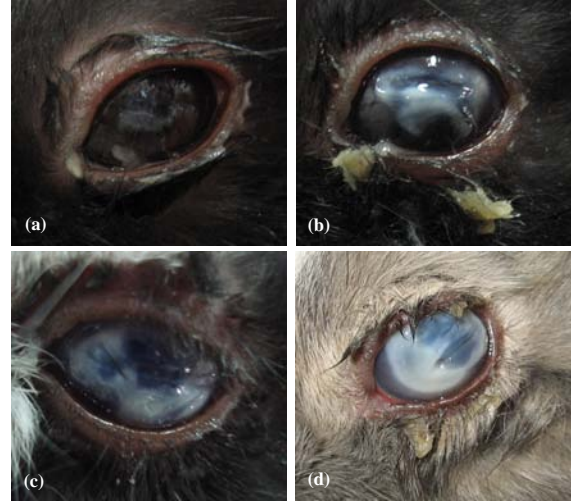

Fig. 2: Rabbit eyes; a) 24; b) 48; c) 72 and d) 96 h after topical challenge with *P. aeruginosa* (immunized group)

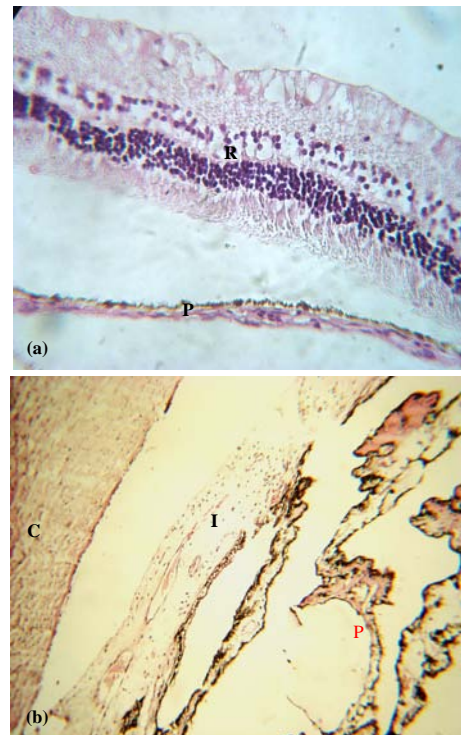


Fig. 3: a) Light micrograph of part of the eye of a control rabbit and an immunized rabbit; b) 72 h after challenge with *P. aeruginosa*. The normal arrangement of the various layers of the Retina (R) and the pigmented and nonpigmented epithelium of the ciliary Process (P). H and E,  $\times 370$ ; note edema of the Cornea (C) and mild infiltration of inflammatory cells in the Iris stroma (I) and the ciliary Process (P). H and E,  $\times 90$

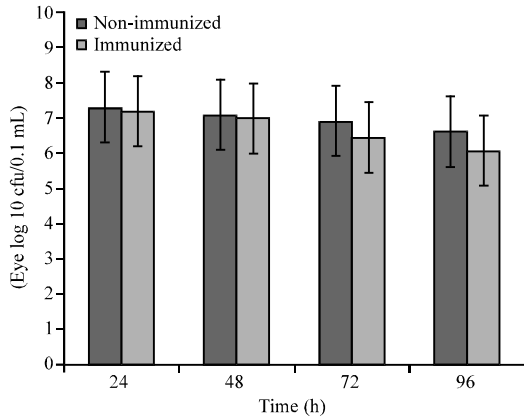


Fig. 4: Viable bacterial counts of non-immunized and immunized rabbits eyes

and 96 h postchallenge. In comparison, the eyes of the control rabbits were completely normal (Fig. 3a). Immunized rabbits challenged with the local isolate of the *P. aeruginosa* showed focal infiltrations of PMN in the stroma at 24 h postchallenge. These infiltrations were more extensive and involved >50% of the cornea at 48, 72 and 96 h postchallenge (Fig. 3b). Results of the viable bacterial counts of the infected eyes from nonimmunized and immunized animals at 24, 48, 72 and 96 h are shown in (Fig. 4). Bacterial clearance from cornea was more rapid in immunized than in nonimmunized rabbits and reached the peak after 96 h postchallenge. In the present study, it was found that the immunization route modulates the inflammatory response to ocular *P. aeruginosa* infection, thus affecting the severity of keratitis and adverse pathology. This finding is in accordance with that of others using different immunization routes such as ocular topical, oral, nasal and intra-Peyer's patch (Thakur *et al.*, 2001). This latter study showed that immunization affects both the rate of bacterial clearance and the profile of cytokines produced in response to ocular infection with nasal immunization resulting in the most significant level of protection.

Furthermore, it was suggested that the degree of protection afforded by immunization may depend upon the rapid recruitment of PMNs, the induction of antigen-specific IgA and balanced production of proinflammatory and immunosuppressive cytokines and that T-cell responses may influence these events (Thakur *et al.*, 2001). Hazlett *et al.* (2007) found that IL-33 promotes aTh2-type immune response and reduces inflammation by polarizing the Macrophage (MO) production of anti-inflammatory mediators in the cornea. Hazlett *et al.* (2010) reported that Langerhans cell/MO recognition of microbial LPS regulates IL-12p40 (and CD1d) driven IFN- $\gamma$

production by NKT cells that IFN- $\gamma$  is required to optimally activate NK cells to produce IFN- $\gamma$  and that depletion of both NKT/NK cells results in earlier corneal perforation. Wu *et al.* (2009) found that PMN infiltration was increased at 1 day postinfection by silencing both defensins or mBD3 but not mBD2 alone. iNOS expression was elevated by silencing mBD2 but it was reduced after silencing mBD3 or both defensins.

Additionally, cell sources of mBD2 (Macrophages, PMN and fibroblasts) and mBD3 (PMN) in corneal stroma were identified by dual label immunostaining after infection. Collectively, the data provide evidence that mBD2 and mBD3 together promote resistance against corneal infection.

In this study, bacterial clearance was found to be greater in immunized than non-immunized rabbits. A similar finding has been reported by others (Thakur *et al.*, 2001). Clearance of bacteria from the ocular surface has been proposed to be due to the combined actions of PMNs and secretory IgA. Immunization has been found to induce increased level of antigen-specific IgA in tears and IgG in serum (Thakur *et al.*, 2001). In other disease settings, the rate of PMNs recruitments has been shown to be associated with early bacterial clearance such as enhanced respiratory clearance of non-typable haemophilus influenzae following mucosal immunization (Buret *et al.*, 1994; Foxwell *et al.*, 1998).

Masinick *et al.* (1997) have found that secretory IgA can significantly inhibit *P. aeruginosa* binding to the wounded mouse cornea *in vitro*, thereby protecting against keratitis. Mun *et al.* (2009) found that Surfactant Protein D (SP-D) can contribute to the clearance of *P. aeruginosa* from the healthy ocular surface and that proteases can compromise that clearance. They also suggested that SP-D degradation *in vivo* is a mechanism by which *P. aeruginosa* proteases could contribute to virulence. Weimer (2009) found that mice immunized with OprF 311-341-Opr1-Flagellins had a significantly lower bacterial burden 3 days postchallenge and cleared the infection at a significantly faster rate than OprF-Opr1 immunized mice. In addition, mice that were passively immunized with OprF-311-341-Opr1-Flagellins monkey immune plasma had significantly less bacteria inflammation and lung damage throughout the infection compared to control immunized mice. Based on these results, it has been suggested that OprF311-341-Opr1-A- and B-Flagellin fusion proteins have substantial potential as a vaccine against nonmucoid *P. aeruginosa* which appears to be the phenotype that initially colonizes CF (Cystic Fibrosis) patients.

Persistence of PMNs in the nonimmune animals during the later stage of infection has been also

demonstrated by others in rats (Thakur *et al.*, 2001) and has been proposed to contribute to corneal scarring and perforation. Host-produced proteolytic enzymes particularly Matrix Metalloproteinases (MMPs) are well known now to contribute to corneal damage. In the present study, immunization of rabbits against *P. aeruginosa* corneal infection achieved a rapid resolution of PMN infiltrates.

### CONCLUSION

Application of the oro-nasal route of immunization of rabbits against *P. aeruginosa* keratitis provided protection but this protection was incomplete. Further studies are needed to elucidate the best modification of the immunization route that provides the complete protection against *P. aeruginosa* keratitis.

### ACKNOWLEDGEMENT

The researchers extend thanks to Prof. Dr. M.Y. Al-Attar for reviewing the manuscript and to the College of Veterinary Medicine, University of Mosul for support.

### REFERENCES

- Adlard, P.A., S.M. Kirov, K. Sanderson and G.E. Cox, 1998. *Pseudomonas aeruginosa* as a cause of infectious diarrhoea. *Epidemiol. Infect.*, 121: 237-241.
- Buret, A., M.L. Dunkley, G. Pang, R.L. Clancy and A.W. Cripps, 1994. Pulmonary immunity to *Pseudomonas aeruginosa* in intestinally immunized rats: role of alveolar macrophages, tumor necrotic factor and interleukin-1 $\alpha$ . *Infect. Immunity.*, 62: 5335-5343.
- Cripps, A.W., M.L. Dunkley and R.L. Clancy, 1994. Mucosal and systemic immunizations with killed *Pseudomonas aeruginosa* protect against acute respiratory infection in rats. *Infect. Immunity*, 62: 1427-1436.
- Cripps, A.W., M.L. Dunkley, R.L. Clancy and J. Kyd, 1995. Pulmonary immunity to *Pseudomonas aeruginosa*. *Immunol. Cell Biol.*, 73: 418-424.
- Cruickshank, R., J.P. Duguid, B.P. Marmion and R.H.A. Swain, 1975. *Medical Microbiology*. 12th Edn., Churchill Livingstone, Edinburgh, London and New York.
- Davis, P.B., M. Drumm and M.W. Konstan, 1996. Cystic fibrosis. *Am. J. Respir. Crit. Care Med.*, 154: 1229-1256.
- Engel, L.S., J.M. Hill, J.M. Moreau, L.C. Green, J.A. Hobden and R.J. O'Callaghan, 1998. *Pseudomonas aeruginosa* protease IV produces corneal damage and contributes to bacterial virulence. *Invest. Ophthalmol. Vis. Sci.*, 39: 662-665.
- Fleiszig, S.M.J. and D.J. Evans, 2002. The pathogenesis of bacterial keratitis: Studies with *Pseudomonas aeruginosa*. *Clin. Exp. Optomet.*, 85: 271-276.
- Foxwell, A.R., J.M. Kyd and A.W. Cripps, 1998. Characterization of immunological response in clearance of nontypable *Haemophilus influenzae* from the lung. *Immunol. Cell Biol.*, 76: 323-331.
- Gilligan, P.H., 1991. Microbiology of airway disease in patients with cystic fibrosis. *Clin. Microbiol. Rev.*, 4: 35-51.
- Hazlett, L.D., 2004. Corneal response to *Pseudomonas aeruginosa* infection. *Progress Retinal. Eye Res.*, 23: 1-30.
- Hazlett, L.D., Q. Li, J. Liu, S. McClellan, W. Du and R.P. Barret, 2007. NKT cells are critical to initiate an inflammatory response after *Pseudomonas aeruginosa* ocular infection in susceptible mice. *J. Immunol.*, 179: 1138-1146.
- Hazlett, L.D., S.A. McClellan, R.P. Barret, X. Huang and Y. Zhang *et al.*, 2010. IL-33 shifts macrophage polarization, promoting resistance against *Pseudomonas aeruginosa* keratitis. *Invest. Ophthalmol. Vis. Sci.*, 51: 1524-1532.
- Hemachandra, S., K. Kamboj, J. Copfer, G. Pier, L.L. Green and J.R. Schreiber, 2001. Human monoclonal antibodies against *Pseudomonas aeruginosa* lipopolysaccharide derived from transgenic mice containing megabase human immunoglobulin loci are opsonic and protective against fatal *Pseudomonas sepsis*. *Infect. Immunity*, 69: 2223-2229.
- Inoue, Y., Y. Ohashi, Y. Shimomura, R. Manabe, M. Yamada, S. Ueda and S. Kato, 1990. Herpes simplex virus glycoprotein D: protective immunity against murine herpetic keratitis. *Invest. Ophthalmol. Vis. Sci.*, 31: 411-418.
- Jang, I.J., I.S. Kim, W.J. Park, K.S. Yoo and D.S. Yim *et al.*, 1999. Human immune response to a *Pseudomonas aeruginosa* outer membrane protein vaccine. *Vaccine*, 17: 158-168.
- Kiernan, J.A., 1999. *Histological and Histochemical Methods: Theory and Practice*. 3rd Edn., Butterworth Heinemann Publication, Oxford, Pages: 112.
- Kreger, A.S., D.M. Lyerly, L.D. Hazlett and R.S. Berk, 1986. Immunization against experimental *Pseudomonas aeruginosa* and *Serratia marcescens* keratitis. vaccination with lipopolysaccharide endotoxins and proteases. *Invest. Ophthalmol. Vis. Sci.*, 27: 932-939.

- Masinick, S.A., C.P. Montgomery, P.C. Montgomery and L.D. Hazlett, 1997. Secretory IgA inhibits *Pseudomonas aeruginosa* binding to cornea and protects against keratitis. Invest. Ophthalmol. Vis. Sci., 38: 910-918.
- Miyazaki, S., T. Matsumoto, K. Tateda, A. Ohno and K. Yamaguchi, 1995. Role of exotoxin A in inducing severe *Pseudomonas aeruginosa* infection in mice. J. Med. Microbiol., 43: 169-175.
- Moon, M.M., L.D. Hazlett, R.E.W. Hancock, R.S. Berk and R. Barrett, 1988. Monoclonal antibodies provided protection against ocular *Pseudomonas aeruginosa* infection. Invest. Ophthalmol. Vis. Sci., 29: 1277-1284.
- Mun, J.J., C. Tam, D. Kowbel, S. Hawgood, M.J. Barnett, D.J. Evans and S.M.J. Fleiszig, 2009. Clearance of *Pseudomonas aeruginosa* from a healthy ocular surface involves surfactant protein D and is compromised by bacterial elastase in a murine null-infection model. Infect. Immunity, 77: 2392-2398.
- O'Callaghan, R.J., L.S. Engel, J.A. Hobden, M.C. Callegan, L.C. Green and J.M. Hill, 1996. *Pseudomonas* keratitis. The role of an uncharacterized exoproteins, protease IV, in corneal virulence. Invest. Ophthalmol. Vis. Sci., 37: 534-543.
- Pillar, M.G., 2001. *Pseudomonas aeruginosa* exotoxin and ocular virulence. Ph.D. Thesis, Wayne State University, Detroit, Michigan, USA.
- Pillar, M.C. and J.A. Hobden, 2002. *Pseudomonas aeruginosa* exotoxin A and keratitis in mice. Invest. Ophthalmol. Vis. Sci., 43: 1437-1444.
- Rudner, X.L., K.A. Kernacki, R.P. Barrett and L.D. Hazlett, 2000. Prolonged elevation of IL-1 in *Pseudomonas aeruginosa* ocular infection regulates macrophage inflammatory protein-2 production, polymorphonuclear neutrophil persistence and corneal perforation. J. Immunol., 164: 6576-6582.
- Schaad, U.B., A.B. Lang, J. Wedgwood, A. Ruedeberg, J.U. Que, E. Furer and S.J.J. Cryz, 1991. Safety and immunogenicity of *Pseudomonas aeruginosa* conjugate A vaccine in cystic fibrosis. Lancet, 338: 1236-1237.
- Shiau, J.W., T.K. Tang, Y.L. Shih, C. Tai, Y.Y. Sung, J.L. Huang and H.L. Yang, 2000. Mice immunized with DNA encoding a modified *Pseudomonas aeruginosa* exotoxin A develop protective immunity against exotoxin intoxication. Vaccine, 19: 1106-1112.
- Sokol, P.A., C. Kooi, R.S. Hodges, P. Cachia and D.E. Woods, 2000. Immunization with a *Pseudomonas aeruginosa* elastase peptide reduces severity of experimental lung infections due to *P.aeruginosa* or *Burkholderia cepacia*. J. Infect. Dis., 181: 1682-1692.
- Thakur, A., J. Kyd, M. Xue, M.D.P. Willcox and A. Cripps, 2001. Effector mechanism of protection against *Pseudomonas aeruginosa* keratitis in immunized rats. Infect. Immunity, 69: 3295-3304.
- Thomas, L.D., M.L. Dunkly, R. Moore, S. Reynolds, D.A. Bastin, J.M. Kyd and A.W. Cripps, 2000. Catalase immunization from *Pseudomonas aeruginosa* enhances bacterial clearance in the rat lung. Vaccine, 19: 348-357.
- Weimer, E.T., 2009. Development of flagellin-based multivalent vaccine against *Pseudomonas aeruginosa*. Ph.D. Thesis, Microbiology and Immunology, Winston-Salem, NC.
- Wu, M., S.A. McClellan, R.P. Barrett, Y. Zhang and L.D. Hazlett, 2009. B-defensins 2 and 3 together promote resistance to *Pseudomonas aeruginosa* keratitis. J. Immunol., 183: 8054-8060.