

## Induced Protection against Challenged *Schistosoma mansoni* Infection in Mice Immunized with Soluble Egg Antigen

<sup>1</sup>Magda M. Sanad, <sup>2</sup>Jamila S. Al-Malki and <sup>3</sup>Areej G. Al-Ghabban

<sup>1</sup>Department of Zoology, College of Science,  
Female Center for Scientific and Medical Colleges,  
King Saud University, Riyadh, Saudi Arabia

<sup>2</sup>Department of Biology, College of Science, Taif, Saudi Arabia

<sup>3</sup>Tabuk Universities, Tabuk, Saudi Arabia

**Abstract:** Schistosomiasis is a parasitic disease causing serious chronic morbidity in tropical countries. Even though an effective treatment exists, it does not prevent re-infection and the development of an effective vaccine still remains the most desirable means of control for this disease. The possible applicability of immunization with a partially purified Soluble Egg Antigen (SEA, 100-137 kDa) for protection against *Schistosoma mansoni* infection in challenged mice was evaluated by histological and immunohistochemical studying of schistosomula-associated inflammatory reactions and deposition of schistosomal antigens in lung tissues. Schistosomula and inflammatory foci were counted in lung sections by histologic scoring for 25 days Post-Infection (PI). In control non-immunized mice, schistosomula number reached its peak earlier (day 7), decreased rapidly and worms were barely detectable on day 25. In immunized mice, the number reached its peak later (day 9), decreased gradually and many worms were still retained in the lungs until day 25. Mild pulmonary cellular reaction was noticed in control mice while in immunized ones, evident mononuclear cellular infiltration with inflammatory foci appeared earlier (day 7) and significantly increased on subsequent days and was most probably of Delayed Type Hypersensitivity (DTH). Schistosomal antigen deposition in lung tissues was markedly augmented in immunized mice. The present study indicates that immunization with this SEA caused augmentative pulmonary response against challenge infection, represented by inducing anamnestic inflammation in lung tissues with consequent blocking of migration of lung schistosomula and more deposition of schistosomal antigens with more stimulation of the immune response. So, this type of antigen may be useful for the composition of a vaccine against schistosomiasis.

**Key words:** *Schistosoma mansoni*, soluble egg antigen, vaccine-lung, histopathology, immunohistochemistry, Saudi Arabia

---

### INTRODUCTION

Helminth parasites of the genus *Schistosoma* are the causative agents of schistosomiasis, a major medical and veterinary problem in the tropics. It affects approximately 200 million of individuals in >70 countries with an estimated 280,000 deaths per year and 500-600 million are at risk (WHO, 2002). The digenetic blood fluke, *Schistosoma mansoni* is one of the major causative agents. Parasite eggs are trapped in the liver and intestine where they induce granuloma formation and fibrosis, the main cause of morbidity and mortality in schistosomiasis (Boros, 1989). Chemotherapy is an important control strategy against this parasitic disease (Harder, 2002), however, it has not reduced the endemicity (Bergquist, 1995) and rapid reinfection demands frequent treatment

(Ismail *et al.*, 1999). Therefore, prophylactic vaccination would have a major impact on the control of this infection (Bergquist, 2002). Variant levels of protection against challenge infection with *Schistosoma mansoni* were described by immunization with either non-living larval schistosomes or soluble membrane-free schistosome extracts (James *et al.*, 1985), Paramyosin (Sm97) a non-surface parasite antigen (Pearce *et al.*, 1988), glutathione-S-transferase (P26, 28) and GP18 (Sher *et al.*, 1989), purified adult worm antigen (Smithers *et al.*, 1989), heavily irradiated cercariae or schistosomula (Strand, 1995) and antioxidant enzymes (LoVerde *et al.*, 2004). During the last decades, schistosome research with recent genomic information has changed significantly and the publication of the *S. mansoni* transcriptomes (Verjovski-Almeida *et al.*, 2003) together with the advent

---

**Corresponding Author:** Magda M. Sanad, Department of Zoology, Faculty of Science,  
Female Center for Scientific and Medical Colleges, King Saud University, P.O. Box 305601, 11361 Riyadh,  
Saudi Arabia

of entire *S. mansoni* genome sequencing, all boosted by advances in bioinformatics, have markedly changed the schistosome vaccine research field. Recombinant protein form (22.6 kDa) antigen (Pacífico *et al.*, 2006), stomatin and recombinant stomatin like protein 2, Sm StoLP-2 (Farias *et al.*, 2010) and the chimeric antigen Sm-TSP-2/5B (Pearson *et al.*, 2012) have been described. However, there is still no effective vaccine with 100% protection level against schistosomiasis

In the present study using the partially purified Soluble Egg Antigen (SEA) of *S. mansoni* for immunization, the role of the lung, being the major site of parasite elimination in normal mice (Dean and Mangold, 1992) in inducing resistance against challenge infection was studied by histological and immunohistochemical methods.

## MATERIALS AND METHODS

**Animals and parasite maintenance:** Fifty laboratory-bred Swiss albino mice, 6-8 weeks old were experimentally infected with 200 cercariae/mouse by tail immersion technique. All procedures in the present study including euthanasia procedure were conducted in accordance with the National Institute of Health Guide for the Care and Use of Laboratory Animals, Institute for Laboratory Animal Research (NIH Publications No. 80-23; 1996) and the Ethical Guidelines of the Experimental Animal Care Center (College of Pharmacy, King Saud University, Saudi Arabia).

**Preparation of SEA:** Viable *S. mansoni* eggs were obtained from livers by potassium hydroxide digestion technique (Doenhoff *et al.*, 1981). Crude SEA was prepared from viable eggs (Dunne *et al.*, 1981) and fractionated by gel chromatography using sephadex G 200 (Gravey *et al.*, 1977). Three peaks were obtained, the second peak of 2.3 mg mL<sup>-1</sup> protein content and 100-137 k Daltons molecular weight, proved to be more protective was used for immunization.

**Immunization of mice, challenge infections, histopathological and immunohistochemical studies:** Immunization of 30 mice was done by intradermal injection twice weekly for 4 weeks (0.1 mL antigen with 5×10<sup>6</sup> CFU of BCG/mouse). In unimmunized age-matched control group (30 mice), phosphate buffered saline with BCG was administered using the same immunization protocol. About 1 week after the last day of immunization, both groups were challenged with 150 *S. mansoni* cercariae/mouse and sacrificed at days 5, 7, 9, 12, 18 and 25 post-challenge (5 mice/group/day). Identical samples from each lung were collected, fixed in 10% formol saline,

processed to paraffin wax, sectioned (4 μ thickness) and subjected for: Hematoxylin-Eosin (HE) staining for detection of schistosomula and pulmonary cellular reactions using the light microscope (10×objective). Schistosomula found in 20 sections of lung/mouse (prepared at intervals of at least 30 μ apart in depth) were counted and the mean numbers at each time point were determined and compared. Inflammatory lung foci, presumed to result from parasite destruction (Von Lichtenberg *et al.*, 1977) were counted and statistically compared in the same manner (Kirkwood, 1989). Immunohistochemical staining by the Indirect Immunoperoxidase (IIP) test (Kiernan, 1981) for detection of schistosomular antigens in lung tissues using purified hyperimmune rabbit's serum against schistosomular antigen and peroxidase-conjugated anti-rabbit IgG (Sigma).

**Preparation of schistosomular antigen:** *S. mansoni* cercariae (Egyptian strain), liberated from infected *Biomphalaria alexandrina* snails were transformed to schistosomula by the method of Clegg and Smithers (1972). Obtained schistosomula were resuspended in Earle's lactalbumin containing 1% fetal calf serum at a concentration of 5×10<sup>5</sup> mL<sup>-1</sup> and disrupted ultrasonically until no intact parasite remained. The homogenate was stored at -20°C until use. Protein concentration was estimated by the method of Lowry *et al.* (1951) and found to be 25 mg mL<sup>-1</sup>.

**Preparation of hyperimmune rabbit's serum against schistosomular antigen:** Anti-schistosomular antiserum was prepared in New Zealand white rabbit according to the method of Hassan *et al.* (1992). Seven biweekly doses, each of 0.5 mL schistosomular antigen plus 0.5 mL complete Freund's adjuvant were injected at 2 intramuscular and subcutaneous sites on the rabbit's back. About 1 week after the last injection, the rabbit was bled and the serum was separated. Gamma globulin fraction was separated according to Hudson and Hay (1980) by ammonium sulphate and caprylic acid. The antiserum was also purified as described by Hassan *et al.* (1995) using protein-A sepharose chromatography.

## RESULTS AND DISCUSSION

Results of the present study showed that there was a striking difference in clearance of both schistosomula and inflammatory foci between the control and immunized mice (Table 1). On the 5th and 7th post-challenge days, fewer worms were detected in the lungs of immunized mice in comparison to those detected in the lungs of control mice with insignificant difference (p>0.05). This may be

Table 1: Histological scoring of schistosomula and inflammatory foci in the lungs of mice immunized with partially purified SEA versus unimmunized control. All challenged with normal cercariae

Days post-challenge	No. of lung schistosomula*±SD			No. of inflammatory foci*±SD		
	Control	Immunized	p-value**	Control	Immunized	p-value**
5	14.4±1.7	11.8±1.5	p>0.050	0	0	0
7	18.4±1.7	16.4±1.6	p>0.050	0	12.8±2.1	p<0.001
9	10.2±1.8	20.8±1.1	p<0.001	4.6±0.9	20.2±3.2	p<0.001
12	4.8±0.8	16.8±1.2	p<0.001	10.4±1.1	31.6±2.2	p<0.001
18	2.0±0.7	11.2±0.8	p<0.001	5.2±0.8	42.8±3.5	p<0.001
25	0.8±0.4	7.6±0.4	p<0.001	1.8±0.8	53.3±2.8	p<0.001

\*Number counted in 20 lung sections/mouse. Number of mice sacrificed per time interval = 5, \*\*p>0.05: insignificant; p<0.001: highly significant

due to the partial immune parasite killing in the skin (Von Lichtenberg *et al.*, 1985). On day 9, the number of challenge worms in immunized mice reached its peak and clearance occurred slowly. On the same day, fewer worms were detected in control mice (p<0.001) and clearance occurred rapidly. On day 9, the number of challenge worms in immunized mice reached its peak clearance occurred slowly compared to control mice which contained less worms (p<0.001) and clearance occurred rapidly. By day 25, most worms in control mice had migrated from the lungs while most of those in immunized mice remained in the lungs. This indicates that the rate of elimination of schistosomula was much slower from the lungs of immunized mice than from those of control mice. By day 25, most worms in control mice had migrated from the lungs while most ones in immunized mice were retained in the lungs. So, the rate of elimination of schistosomula from the lungs of immunized mice was much slower than from control mice. This pattern of schistosomula clearance in immunized mice was similar to that reported by Wilson and Coulson and Dean and Mangold (1992) using attenuated cercariae as a vaccine.

The inflammatory foci resulted from challenge worms appeared earlier in immunized mice (day 7) and were more numerous on subsequent days with a highly significant difference (p<0.001) in comparison with the control group. This, most probably, indicates increased challenge parasite disintegration in immunized mice on the assumption that inflammatory lung foci represent parasite destruction (Von Lichtenberg and Byram, 1980) or the product of non-specific responses to tissue damage caused by the parasites (Crabtree and Wilson, 1986).

The method used in the present study for counting lung schistosomula and inflammatory foci, i.e., the histologic estimates within 20 sections/mouse taken at 30 μ intervals may provide marginally reliable or objective method for estimating results in control versus immunized mice. The known method for counting schistosomula by mincing and incubation (Smithers and Gammage, 1980) was not performed being reported to be more tedious and having 30% failure of schistosomula emergence from tissue snips (Dean *et al.*, 1984).

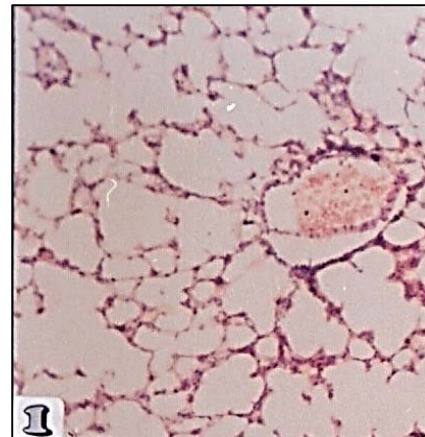


Fig. 1: Lung section from normal uninfected unimmunized mouse showing thin blood vessel wall and the thin interalveolar septa with absence of cellular infiltration (H&E, X150)

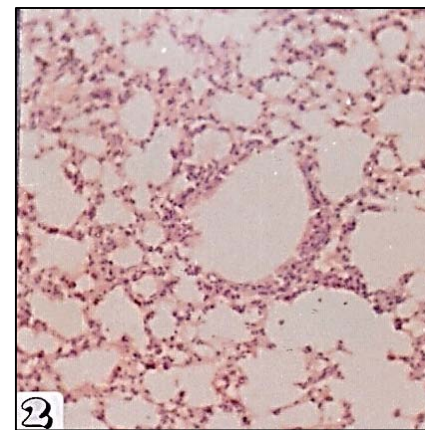


Fig. 2: Lung section from control unimmunized mouse, 12 days post-infection, showing mild diffuse mononuclear cellular infiltration (H&E, X150)

The pulmonary cellular reaction (Fig. 1-6) was quite different in both groups (Table 2). In immunized mice, perivascular cellular infiltrations were evident as early as day 7 and from day 9 onwards, mononuclear cellular

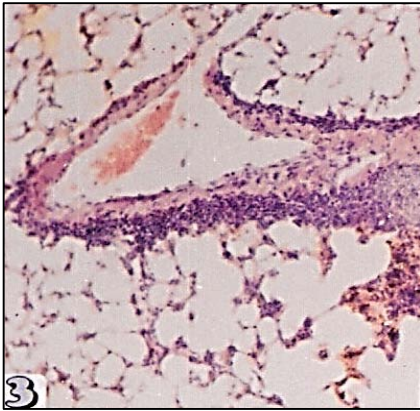


Fig. 3: Lung section from immunized mouse, 7 days post-challenge with normal cercariae showing moderate peri-vascular mononuclear cellular infiltration (H&E, X150)

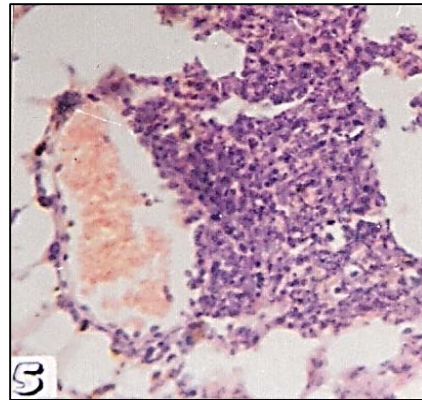


Fig. 5: Lung section from immunized mouse, 12 days post-challenge infection showing marked perivascular focal mononuclear infiltration (H&E, X300)

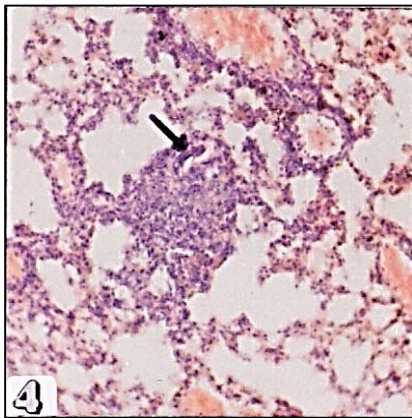


Fig. 4: Lung section from immunized mouse, 12 days post-challenge infection showing moderate mononuclear cellular infiltration, perivascular and in the alveolar septa with one schistosomulum (arrow) entrapped within focal cellular aggregation (H&E, X150)

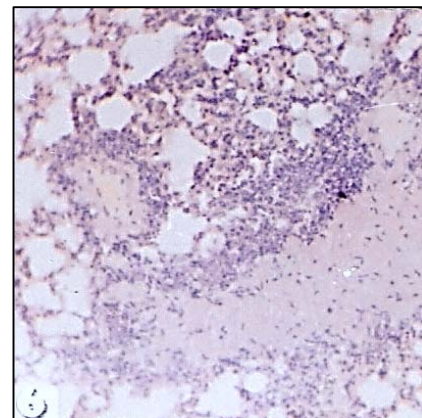


Fig. 6: Lung section from immunized mouse, 18 days post-challenge infection showing marked diffuse mononuclear cellular infiltration with enlargement of the interstitium (H&E, X150)

Table 2: Pulmonary cellular reactions in mice immunized with partially purified SEA versus unimmunized control. All challenged with normal cercariae

Days post-challenge	Pulmonary cellular reactions*					
	Control mice			Immunized mice		
	Perivascular	Alveolar septa	Foci	Perivascular	Alveolar septa	Foci
5	-	-	-	±	-	-
7	-	-	-	++	+	+
9	+	+	±	++	++	++
12	+	++	++	+++	+++	+++
18	-	++	+	++	++++	++++
25	-	+	±	++	++++	++++

- = Absent; + = Mild; ++ = Moderate; +++ = Marked; ++++ = Intense

infiltrations and inflammatory foci were increasing throughout the alveoli. By contrast, the reaction was evident on days 12 and 18 in control mice and the number and size of the foci were significantly ( $p < 0.001$ ) less. In other words, the cellular reaction in immunized mice was of greater magnitude and rapid in appearance (anamnestic response). Such inflammatory reactions in immunized mice seem to delay or to block schistosomula migration by impeding their movement, destroying the vascular pathway (Crabtree and Wilson, 1986) or deflecting the parasites into the alveoli, trachea and gastrointestinal tract (Dean and Mangold, 1992).

The mononuclear cellular composition (lymphocytes and macrophages) of infiltrations and foci suggests a

Table 3: Schistosomal antigen deposition in the lungs of mice immunized with partially purified SEA versus unimmunized control. All challenged with normal cercariae

Days	Schistosomal antigen deposition*											
	Intravascular		Perivascular		Blood vessels		Alveolar septa		Inflammatory cells		Foci	
	Cont. mice	Imm. mice	Cont. mice	Imm. mice	Cont. mice	Imm. mice	Cont. mice	Imm. mice	Cont. mice	Imm. mice	Cont. mice	Imm. mice
5	++	+	+	+	+	+	-	-	-	-	-	-
7	++	++	++	++	++	++	++	++	-	++	-	±
9	++	++	++	++	++	++	++	+++	±	+++	±	++
12	++	+	++	+	++	+	+++	++++	+	++++	+	++++
18	++	+	++	+	++	+	++	++++	++	++++	+	++++
25	++	+	++	+	++	+	++	+++	+	+++	±	+++

\*Control; <sup>1</sup>Immunized; - = No antigen, negative reaction; + = Little antigen, weak reaction; ++ = Moderate antigen, moderate reaction; +++ = Marked antigen, strong reaction; ++++ = Excess antigen, intense reaction

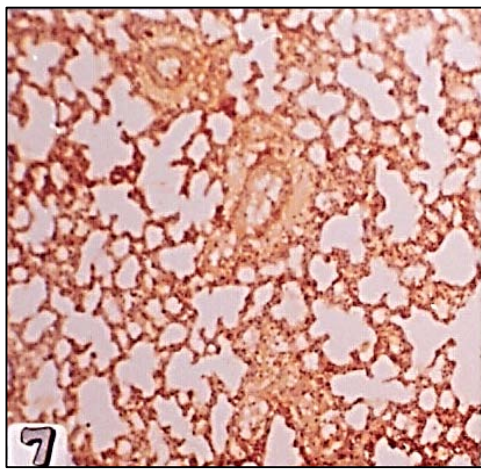


Fig. 7: Lung section from control unimmunized mouse, 7 days post challenge infection showing antigen deposition intravascular (++) , perivascular (++) and in the alveolar septa (++) (Immunoperoxidase, X150)

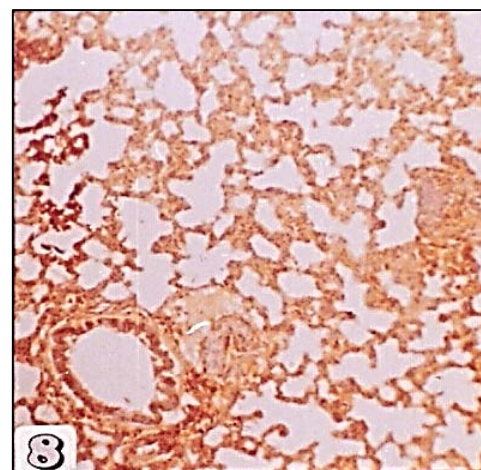


Fig. 8: Lung section from control unimmunized mouse, 9 days post-infection showing antigen deposition in the interalveolar septa (++) and bronchioles (+++) (Immunoperoxidase, X150)

Delayed Type Hypersensitivity (DTH) response and implies that the induced protective lung phase in immunized mice is T-cell dependent. Hernandez *et al.* (1997) declared that granulomatous inflammation is strictly dependent on CD4+ T helper (Th) cells specific for Schistosome Egg Antigens (SEA). Williams *et al.* (2001, 2005) indicated that the egg-induced immunopathology is mediated by CD4+ T helper cells sensitized to schistosome egg antigens. Cass *et al.* (2007) reported that they were able to identify the *S. mansoni* egg secretome, a complex array of 188 proteins in addition to 32 novel Egg Secreting Proteins (ESP). They added that ESP profoundly influence the Th1/Th2-cytokine environment and serve as the focus of the host immunoinflammatory response.

Deposition of schistosomular antigens in lung tissues (Table 3) was detected as early as day 7 in both

control and immunized mice (Fig. 7-12). These antigens represent excretory-secretory products of lung stages.

However, the level of deposited antigens was steadily increasing by time in the immunized group and this might indicate more parasites sequestration in the lungs and more production of antigens. Also, it might be due to dead or disintegrated parasites within the inflammatory foci. The cellular infiltrates also showed positive reaction due to diffusion of schistosomular antigens into their cytoplasm. Obviously, on days 18 and 25, circulating antigens from extra-pulmonary (hepatic) stages might share in the positivity of the reaction. These results might indicate that antigen deposition in lung tissue of immunized mice was markedly augmented and this will be consequently recognized by a subset of T-cells, release of more lymphokines and attraction of more macrophages at the site of antigens, i.e., exaggerated T-cell response will result (Wakelin, 1984).

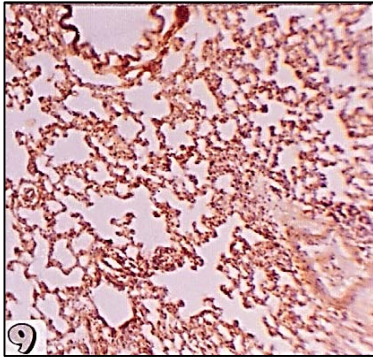


Fig. 9: Lung section from control unimmunized mouse, 12 days post-infection showing antigen deposition intravascular (++), perivascular (++), alveolar septa (+++), bronchioles (+++) and inflammatory cells (Immunoperoxidase, X100)

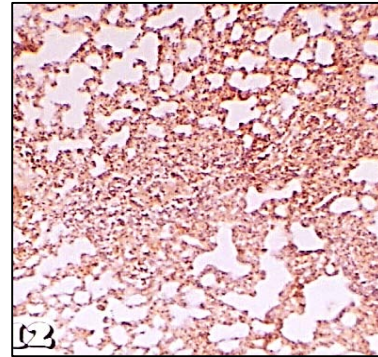


Fig. 12: Lung section from immunized mouse, 25 days post-challenge infection showing antigen deposition in the interveolar septa (+++), inflammatory cells (+++) and foci (+++) (Immunoperoxidase, X100)

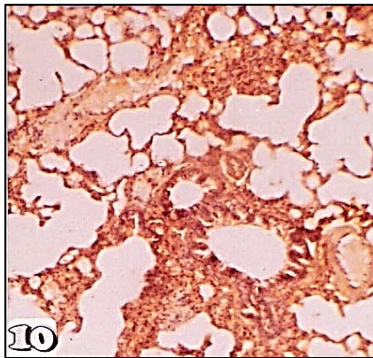


Fig. 10: Lung section from immunized mouse 12 days post-challenge infection showing antigen deposition intravascular (+), blood vessel (+), intraveolar septa (+++), in the bronchioles (+++), in the inflammatory cells and foci (+++) (Immunoperoxidase, X150)

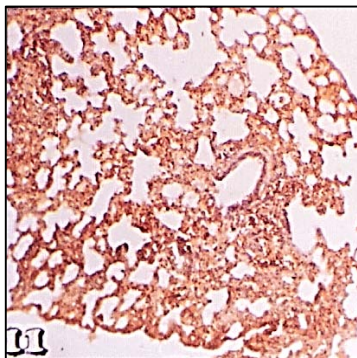


Fig. 11: Lung section from immunized mouse, 18 days post-challenge infection showing antigen deposition in the interalveolar septa, inflammatory cells and foci (++++) (Immunoperoxidase, X100)

## CONCLUSION

Results of the present research indicate that in mice immunized with SEA fraction of molecular weight 100-137 k Daltons, the process of lung resistance is markedly augmented by significant sequestration of lung stages, significant increase in inflammatory foci, anamnestic immune response of DTH and increased deposition of antigens in lung tissues. In other words, this SEA fraction by stimulating a controlled inflammation in lung tissues with consequent blocking in schistosomula migration and therefore may be a good candidate antigen for the composition of a vaccine against schistosomiasis.

## ACKNOWLEDGEMENTS

This research project was supported by a grant from the Research Center of the Center for Female Scientific and Medical Colleges, Deanship of Scientific Research, King Saud University.

## REFERENCES

- Bergquist, N.R., 1995. Schistosomiasis vaccine development: Approaches and prospects Mem. Inst. Oswaldo. Cruz., 90: 221-227.
- Bergquist, N.R., 2002. Schistosomiasis: From risk assessment to control. Trends Parasitol., 18: 309-314.
- Boros, D.L., 1989. Immunopathology of *Schistosoma mansoni* infection. Clin. Microbiol. Rev., 2: 250-250.
- Cass, C.L., J.R. Johnson, L.L. Califf, T. Xu and H.J. Hernandez *et al.*, 2007. Proteomic analysis of *Schistosoma mansoni* egg secretions Mol. Biochem. Parasitol., 155: 84-93.

- Clegg, J.A. and S.R. Smithers, 1972. The effects of immune rhesus monkey serum on *Schistosoma mansoni* during cultivation *in vitro*. *Int. J. Parasitol.*, 2: 79-98.
- Crabtree, J.E. and R.A. Wilson, 1986. The role of pulmonary cellular reactions in the resistance of vaccinated mice to *Schistosoma mansoni*. *Parasite Immunol.*, 8: 265-285.
- Dean, D.A. and B.L. Mangold, 1992. Evidence that both normal and immune elimination of *Schistosoma mansoni* take place at the lung stage of migration prior to parasite death. *Am. J. Trop. Med. Hyg.*, 47: 238-248.
- Dean, D.A., B.L. Mangold, J.R. Georgi and R.H. Jacobson, 1984. Comparison of *Schistosoma mansoni* migration patterns in normal and irradiated cercariae-immunized mice by means of autoradio-graphic analysis. *Am. J. Trop. Med. Hyg.*, 33: 89-96.
- Doenhoff, M.J., S. Pearson, D.W. Dunne, Q. Bickle, S. Lucas, J. Bain and O. Hassounah, 1981. Immunological control of hepatotoxicity and parasite egg excretion in *Schistosoma mansoni* infection: Stage specificity of the reactivity of immune serum in T-cell deprived mice. *Trans. R. Soc. Trop. Med. Hyg.*, 75: 41-53.
- Dunne, D.W., S. Lucas, Q. Bickle, S. Pearson, L. Madgwick, J. Bain and M.J. Doenhoff, 1981. Identification and purification of an antigen (W1) from *Schistosoma mansoni* eggs which is putatively hepatotoxic in T-cell deprived mice. *Trans. R. Soc. Trop. Med. Hyg.*, 75: 54-71.
- Farias, L.P., F.C. Cardoso, P.A. Miyasato, B.O. Montoya and C.A. Tararam *et al.*, 2010. *Schistosoma mansoni* stomatin like protein-2 is located in the tegument and induces partial protection against challenge infection. *PloS. Negl. Trop. Dis.*, Vol. 4. 10.1371/journal.pntd.0000597.
- Gravey, J.S., N.E. Cremer and D.H. Sussdorf, 1977. *Methods in Immunology* 3rd Edn., Addison-Wesley publishing company Inc. New York, pp: 126-132.
- Harder, A., 2002. Chemotherapeutic approaches to schistosomes: Current knowledge and outlook. *Parasitol. Res.*, 88: 395-397.
- Hassan, M.M., A.M. Farghaly, R.A. Darwish, N. Shoukrany, I.A. El-Hayawan and A.K. Nassar, 1995. Detection of Giardia antigen in stool samples before and after treatment. *J. Egypt. Soc. Parasitol.*, 25: 175-182.
- Hassan, M.M., M.A. Badawi and M. Strand, 1992. Circulating Schistosomal antigen diagnosis and assessment of cure in individuals infected with *S. mansoni*. *Am. J. Trop. Med. Hyg.*, 46: 737-744.
- Hernandez, H.J., Y. Wang, N. Tzellas and M.J. Stadecker, 1997. Expression of class II, but not class I, major histocompatibility complex molecules is required for granuloma formation in infection with *Schistosoma mansoni*. *Eur. J. Immunol.*, 27: 1170-1176.
- Hudson, L. and F.C. Hay, 1980. Ion Exchange Chromatography. In: *Practical Immunology*, Hudson, L. and F.C. Hay (Eds.). 2nd Edn., Blackwell Scientific Publication, Oxford, London, USA.
- Ismail, M., S. Botros, A. Metwally, S. William and A. Farghally *et al.*, 1999. Resistance to praziquantel direct evidence from *Schistosoma mansoni*. *Am. J. Trop. Med. Hyg.*, 60: 932-935.
- James, S.L., E.J. Pearce and A. Sher, 1985. Induction of protective immunity against *Schistosoma mansoni* by a non living vaccine. I. Partial characterization of antigens recognized by antibodies from mice immunized with soluble schistosome extracts. *J. Immunol.*, 134: 3432-3438.
- Kiernan, J.A., 1981. *Histological and Histochemical Methods: Theory and Practice*. Pergamon Press, Frankfurt, Germany.
- Kirkwood, R., 1989. *Essentials of Medical statistics*. Blackwell Scientific Publication, London, USA.
- LoVerde, P.T., C. Carvalho-Queiroz, R. Cook, 2004. Vaccination with antioxidant enzymes confers protective immunity against challenge infection with *Schistosoma mansoni*. *Mem. Inst. Oswaldo. Cruz.*, 99: 37-43.
- Lowry, O.H., N.J. Rosebrough, A.L. Farr and R.J. Randell, 1951. Protein measurement with the Folin phenol reagent. *J. Biol. Chem.*, 193: 265-275.
- Pacifico, L.G., C.T. Fonseca, L. Chiari, S.C. Oliveira, 2006. Immunization with *Schistosoma mansoni* 22.6 kDa antigen induces partial protection against experimental infection in a recombinant protein form but not as DNA vaccine. *Immunobiology*, 211: 97-104.
- Pearce, E.J., S.L. James, S. Hieny, D.E. Lanar, and A. Sher, 1988. Induction of protective immunity against *Schistosoma mansoni* by vaccination with schistosome paramyosin (Sm97), a non-surface parasite antigen. *Proc. Natl. Acad. Sci.*, 85: 5678-5682.
- Pearson, M.S., D.A. Pickering, H.J. McSorley, J.M. Bethony and L. Tribotet *et al.*, 2012. Enhanced protective efficacy of a chimeric form of the schistosomiasis vaccine antigen Sm-TSP-2. *PloS Negl. Trop. Dis.*, Vol. 6. 10.1371/journal.pntd.0001564.

- Sher, A., S.L. James, R. Correa-Oliveira, S. Hieny and E. Pearce, 1989. Schistosome vaccines: Current progress and future prospects. *Parasitology*, 98: S61-S68.
- Smithers, S.R. and K. Gammage, 1980. The recovery of *Schistosomula mansoni* from the skin, lungs and hepatic portal system of native mice and mice previously exposed to *S. mansoni*. Evidence for two phases of parasite attrition in immune mice. *Parasitology* 80: 289-300.
- Smithers, S.R., F. Hackett, P.O. Ali and A.J. Simpson, 1989. Protective immunization of mice against *Schistosoma mansoni* with purified adult worm surface membranes. *Parasite Immunol.*, 11: 301-318.
- Strand, M., 1995. Development of a vaccine against schistosomiasis Proceeding of the SRP International Conference on schistosomiasis March 12-16, 1995, Johns Hopkins University. Marriott Hotel, Cairo, Egypt.
- Verjovski-Almeida, S., R. DeMarco, E.A. Martins, P.E. Guimaraes and E.P. Ojopi *et al.*, 2003. Transcriptome analysis of the acoelomate human parasite *Schistosoma mansoni*. *Nat. Genet.*, 35: 148-157.
- VonLichtenberg, F. and J.E. Byram, 1980. Pulmonary cell reactions in natural and acquired host resistance to *Schistosoma mansoni* *Am. J. Trop. Med. Hyg.*, 25: 1286-1300.
- Von Lichtenberg, F., A. Sher and S. McIntyre, 1977. A lung model of schistosome immunity in mice *Am. J. Pathol.*, 84: 105-124.
- VonLichtenberg, F., R. Correa-Oliveira and A. Sher, 1985. The fate of challenge schistosomula in the murine anti-schistosome vaccine model *Am. J. Trop. Med Hyg.*, 34: 96-106.
- WHO., 2002. TDR Strategic direction for research: Schistosomiasis. World Health Organization, Geneva, Switzerland.
- Wakelin, D., 1984. Immunity to parasites. 1st Edn., Edward Arnold Publishers Ltd., London, USA.
- Williams D.L., H. Asahi, T.T. Oke , J. Lopes da Rosa, M.J. Stadecker, 2005. Murine immune responses to a novel schistosome egg antigen, SmEP25 *Int. J. Parasitol.*, 35: 875-882.
- Williams, D.L., H. Asahi, D.J. Botkin and M.J. Stadecker, 2001. Schistosome Infection Stimulates Host CD4+ T Helper Cell and B-Cell Responses against a Novel Egg Antigen, Thioredoxin Peroxidase *Infect. Immun.*, 69: 1134-1141.